

Spontaneous Regression of Pineal Region Arachnoid Cyst: A Case Report and Review of Literature

Abstract

Arachnoid cyst is a rare benign cerebrospinal fluid-filled cyst that can develop anywhere in the brain along the arachnoid membrane and usually unaccompanied by the anomalous development of the brain structure. These cysts are usually located in the middle cranial fossa. However, they are also denoted in other regions. Arachnoid cysts are mostly asymptomatic and diagnosed incidentally. Spontaneous regression of arachnoid cysts in different anatomical regions of the brain has been reported in the literature. However, to the best of our knowledge, this is the first case reporting an unusual spontaneous regression of arachnoid cyst in the pineal region in a 3-year-old child presented to our hospital with hydrocephalus without alarming signs and was treated conservatively as the patient was stable, and the cyst showed spontaneous regression. A comprehensive review of the literature regarding spontaneous regression of arachnoid cysts has been collected and discussed in this article.

Keywords: Arachnoid cyst, benign, incidental, pineal region, spontaneous regression

Introduction

Arachnoid cysts are a rare benign congenital central nervous system lesions which consist of cerebrospinal fluid (CSF) and surrounded by histologically normal layers of arachnoid membrane in the absence of connection with the ventricular system.^[1,2] They account for only 1% of all intracranial space-occupying lesions and usually unaccompanied by the anomalous development of the brain structure. In general, arachnoid cysts are asymptomatic, and detection is mostly incidental.^[1,3]

Most arachnoid cyst cases are sporadic with a negative family history.^[4] However, familial cases of arachnoid cysts have been reported in the medical literature, suggesting that genetic predisposition may play a role in some patients.^[5] In familial cases, inheritance could be autosomal recessive.^[4]

They are frequently located in the middle cranial fossa (MCF). However, they are also denoted to be seen in the suprasellar, quadrigeminal cistern, cerebral convexity, posterior fossa, and interhemispheric fissure.^[1-3]

This is an open access journal, and articles are distributed under the terms of the Creative Commons Attribution-NonCommercial-ShareAlike 4.0 License, which allows others to remix, tweak, and build upon the work non-commercially, as long as appropriate credit is given and the new creations are licensed under the identical terms.

For reprints contact: reprints@medknow.com

These lesions are usually located in the MCF and mostly develop in the left side of the brain with male predominance by a rate of 3/1.^[1,2]

On computed tomography (CT) scans magnetic resonance imaging (MRI), they appear extraaxial, well-circumscribed, simple cystic lesions. They are isodense to CSF on CT and isointense to CSF on all MR image sequences.^[6]

Although most cases of arachnoid cysts remain limited and asymptomatic,^[2] sometimes, they might manifest when they are located in the MCF and large enough to cause signs and symptoms related to intracranial mass effect or disruption of CSF dynamics.^[1] Infrequently, more serious life-threatening complications may occur such as cystic rupture, intracystic bleeding, or seizure attacks, making arachnoid cysts not so benign as commonly believed.^[2]

The posterior fossa region is the second most common region for those lesions, since they are often detected in the cerebellar or cerebellopontine region.^[7] It is necessary to differentiate those located infratentorially from other posterior fossa

**Ahmed Ammar,
Abdulrazaq
Abdulmohsen
Alojan,
Alaa Nabil
Turkistani,
Majd Mohammed
Alrayes**

*Department of Neurosurgery,
King Fahad University Hospital,
Imam Abdulrahman Bin Faisal
University, Dammam,
Saudi Arabia*

Address for correspondence:

*Prof. Ahmed Ammar,
Department of Neurosurgery,
King Fahad University Hospital,
Imam Abdulrahman Bin
Faisal University, Dammam,
Saudi Arabia.*

E-mail: ahmed@ahmedammar.com

*Dr. Abdulrazaq Abdulmohsen
Alojan,*

*Department of Neurosurgery,
King Fahad University Hospital,
Imam Abdulrahman Bin
Faisal University, Dammam,
Saudi Arabia.*

E-mail: dr_aujan@hotmail.com

Access this article online

Website: www.asianjns.org

DOI: 10.4103/ajns.AJNS_289_19

Quick Response Code:



How to cite this article: Ammar A, Alojan AA, Turkistani AN, Alrayes MM. Spontaneous regression of pineal region arachnoid cyst: A case report and review of literature. Asian J Neurosurg 2020;15:155-8.

Submission: 16-09-2019 **Accepted:** 20-12-2019
Published: 25-02-2020

lesions, such as Dandy–Walker syndrome variant, mega cisterna magna, abscesses, and cystic tumors.^[8,9]

Case Report

A 3-year-old boy product of cesarean section at 38 weeks of gestation with a relatively large head sought medical advice at our hospital at the age of 4 months as a case of hydrocephalus. Prenatal ultrasound revealed a brain cyst with mild ventricular dilatation. No maternal history of oligo or polyhydramnios. No history of vomiting or signs of increased intracranial pressure, and the patient was feeding well. He was active, moving all limbs, and pupils were equally reactive bilaterally. The anterior fontanelle was flat and soft, and he was developmentally appropriate to age. Brain MRI [Figure 1] showed a well-defined cystic lesion measuring 2 cm × 2.8 cm × 3.2 cm in its maximum transverse, anterior-posterior and craniocaudal dimensions exerting mass effect over the brain stem anteriorly and causing lateral and third ventricular dilatation. Findings are suggestive of pineal region arachnoid cyst. He was planned for surgery, yet repeated MRI brain [Figure 2] showed regression of both ventricles size and the arachnoid cyst which follows the CSF signal intensity with no evidence of pathological enhancement, bleeding, and no diffusion restriction. The patient has been managed conservatively with close observation and follow-up. Since then, the patient remains asymptomatic, and he developed normally with no neurological deficits. The last MRI follow-up showed further regression of ventricular dilatation and arachnoid cyst size with no signs of intracystic bleeding or subdural collection.

Discussion

The rupture of arachnoid cysts is a very uncommon sequela of the arachnoid cysts formation.^[2] Two mechanisms have been proposed that explain such phenomena. The first mechanism is due to mild head injury that can tear the wall of the arachnoid cyst, causing a flap valve mechanism leading to communication with subarachnoid space. The second proposed mechanism even in patients with no known trauma, the cyst spontaneously resolves into the subdural space following a sudden transient intracranial pressure increase during a Valsalva maneuver.^[1,10]

Most patients present with symptoms of high ICP such as nausea, vomiting, headache, seizure, and rarely diplopia from VI nerve palsy.^[11] Parsch *et al.* in 1997 reported subdural hemorrhage in 2.43% and subdural hygroma in 0.46% of patients with arachnoid cyst noted on MRI.^[12] In addition, intracystic bleeding may occur inside the arachnoid cyst as reported by Hong in 2008.^[13]

MRI is the modality of choice in the detection of arachnoid cysts because of its ability to demonstrate the exact location, extent, and relationship of the arachnoid cyst to the adjacent brain or spinal cord.^[14]

Most arachnoid cysts are found incidentally and can be managed conservatively; however, prophylactic surgical treatment is usually not recommended except in symptomatic candidate where surgery is considered or in the coexistence of mass effect or midline shift. In addition, surgical intervention is considered in cases of epilepsy, severe headache, or neurological deficit proved to be caused by a tense arachnoid cyst. Different neurosurgical options include craniotomy and excision of the cyst, endoscopic fenestration, and cystoperitoneal shunt are the procedures performed in symptomatic arachnoid cyst depending upon the size, location, and clinical presentation. Recent advances in neurosurgical techniques in neuroendoscopy continue to favor fenestration over shunt insertion as a method of choice for initial cyst decompression.^[15] It is very important to reduce the risk of recurrence of the arachnoid cyst in which the outer and inner walls must be opened, fenestrated in several points, if removal of the cyst wall is difficult. However, cystoperitoneal shunt is the preferred procedure in patients with raised intracranial pressure,^[16] and craniotomy for cyst excision is adopted to treat well-circumscribed cysts that have been also reported. While in the context of cyst rupture, cyst either decreases or disappears after subdural evacuation.^[17]

Spontaneous regression of arachnoid cysts in different anatomical regions of the brain has been reported in the literature. A literature-based review was performed using the PubMed search engine of the National Library of Medicine and National Institutes of Health. The following keywords were searched: “arachnoid cyst,” “spontaneous

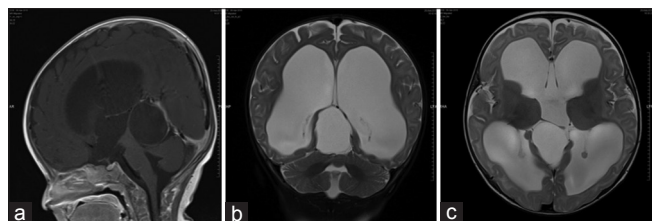


Figure 1: Magnetic resonance imaging brain (a) T1 sagittal view (b) T2 coronal view, (c) T2 axial view showed a large pineal region arachnoid cyst measuring 2 cm × 2.8 cm × 3.2 cm in dimensions with secondary significant ventricular dilatation and hydrocephalus

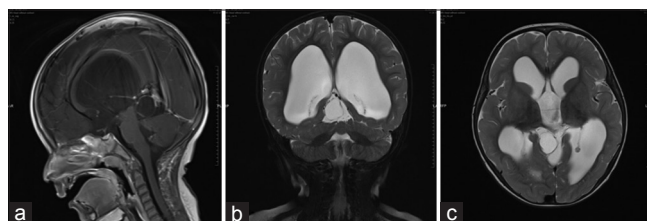


Figure 2: Magnetic resonance imaging brain (a) T1 sagittal view, (b) T2 coronal view, (c) T2 axial view showed a significant reduction in size (3 years) after follow-up, measuring 1.8 cm × 2 cm × 2 cm in dimensions with reduction of ventricular size

regression,” “spontaneous resolution,” and “spontaneous reduction.” The relevant literature were carefully studied, and the results were summarized in [Table 1]. Twenty-two cases were reviewed and included; different parameters were studied and analyzed, and the results were as follows: the male-to-female ratio was 16:5 with male predominance, the median age was 12 years of age, most cysts were located at the MCF (six cases), and the median duration of the cyst to resolve was 3.5 years. Most of the cases were asymptomatic upon the time of diagnosis. The reason for the spontaneous resolution of the cyst remains unclear, where different cases reported certain incidents which have been followed by cyst resolution; those incidents include head trauma,^[33] cesarean delivery,^[35] and suppurative meningitis.^[19]

According to the case reported by Bristol *et al.*,^[26] arachnoid cysts have also been associated with other intracranial tumors, where the cyst has completely resolved initially without any history of trauma or surgical intervention; interestingly, the cyst returned and became larger than it was. This observation, where the cyst return after it disappears, is also reported by Arunkumar *et al.*, in which his patient had a midline posterior fossa arachnoid cyst that decreased in size initially, but then the cyst enlarged with worsening in the patient’s neurological status.^[28]

Conclusion

Spontaneous regression of arachnoid cysts has been reported in different cases and different anatomical regions. Yet, this is the first case describes a spontaneous regression of arachnoid cyst in the pineal region. Although different mechanisms have been suggested in the literature, in our case, we are in favor of the flap contrary one valve mechanism which allows one-way flow of the CSF to get out of the cyst and gradually decreases the cyst internal pressure leading into cyst regression with time. Incidental arachnoid cysts in the context of asymptomatic presentation should be followed with serial MRI and close clinical follow-up, thus surgical management should be deferred as long as the arachnoid cysts remain asymptomatic. This fact should be emphasized in the management’s plan of incidental and asymptomatic arachnoid cysts.

Declaration of patient consent

The authors certify that they have obtained all appropriate patient consent forms, including intraoperative images, patients imaging scans, and clinical data to be published in this journal. The authors certify that this article has gained an Institutional Review Board certificate from the IRB committee at Imam Abdulrahman Bin Faisal University, Dammam, Saudi Arabia.

Table 1: Literature-based review summarizing the spontaneous regression of arachnoid cyst

Location	Number of cases	References	Gender	Age	Time from diagnosis till regression	Preceding event
Middle fossa	6	[18]	Male	14 years	18 months	
		[19]	Male	2 months	2 months	Suppurative meningitis
		[20]	Male	3 years	2 years	-
		[21]	Male	7 years	18 months	
		[22]	Male	NA	-	-
		[23]	Female	8 years	7 years	-
Prepontine	1	[24]	Female	Infant	5 years	
Suprasellar	1	[25]	Male	5 years	15 years	-
Suprasellar, prepontine	1	[26]	Male	5 years	1 month	-
Posterior fossa supracerebellar	1	[27]	Male	7 months	-	-
Posterior cranial fossa	1	[7]	Male	43 years	2 months	-
Posterior fossa	1	[28]	Male	41 years	-	-
Temporal	2	[29]	Male	13 years	10 years	-
		[30]	Male	4 years	7 years	-
Prepontine and suprasellar cisterns	1	[31]	Female	NA	2 years	-
Temporofrontal	2	[32]	Male	1.5 years	5.5 years	-
		[33]	Male	23 years	6 months	Trauma
Cerebral convexity	1	[34]	Female	1 year	2 years	-
Meckel’s cave	1	[35]	Female	32 years	7 months	Cesarean delivery
Sylvian fissure	2	[36]	Male	7 years	2 years	-
		[34]	Male	10 years	2 years	-
Supratentorially	1	[37]	-	NA	13.5 weeks	-

NA – Not available

Financial support and sponsorship

Nil.

Conflicts of interest

There are no conflicts of interest.

References

- Vega-Sosa A, de Obieta-Cruz E, Hernández-Rojas MA. Intracranial arachnoid cyst. *Cir Cir* 2010;78:551-6.
- Hamada H, Hayashi N, Umemura K, Kurosaki K, Endo S. Middle cranial fossa arachnoid cyst presenting with subdural effusion and endoscopic detection of tear of the cyst-case report. *Neurol Med Chir (Tokyo)* 2010;50:512-4.
- Sprung C, Armbruster B, Koeppen D, Cabraja M. Arachnoid cysts of the middle cranial fossa accompanied by subdural effusions-experience with 60 consecutive cases. *Acta Neurochir (Wien)* 2011;153:75-84.
- Arachnoid Cyst. Orphanet; April, 2005. Available from: http://www.orphanet.net/consor/cgi-bin/OC_Expphp?Ing=EN&Expert=2356. [Last accessed on 2019 Jul 12].
- Wang Y, Cui J, Qin X, Hong X. Familial intracranial arachnoid cysts with a missense mutation (c. 2576CT) in RERE: A case report. *Medicine (Baltimore)* 2018;97:e13665.
- Jafrani R, Raskin JS, Kaufman A, Lam S. Intracranial arachnoid cysts: Pediatric neurosurgery update. *Surg Neurol Int* 2019;10:15.
- Russo N, Domenicucci M, Beccaglia MR, Santoro A. Spontaneous reduction of intracranial arachnoid cysts: A complete review. *Br J Neurosurg* 2008;22:626-9.
- Arai H, Sato K. Posterior fossa cysts: Clinical, neuroradiological and surgical features. *Childs Nerv Syst* 1991;7:156-64.
- Ammar A. Hydrocephalus: What Do We Know? and What Do We Still Not Know? Cham: Springer International Publishing; 2017.
- Cullis PA, Gilroy J. Arachnoid cyst with rupture into the subdural space. *J Neurol Neurosurg Psychiatry* 1983;46:454-6.
- Khilji MF, Jeswani NL, Hamid RS, Al Azri F. Spontaneous arachnoid cyst rupture with subdural hygroma in a child. *Case Rep Emerg Med* 2016;2016:6964713.
- Parsch CS, Krauss J, Hofmann E, Meixensberger J, Roosen K. Arachnoid cysts associated with subdural hematomas and hygromas: Analysis of 16 cases, long-term follow-up, and review of the literature. *Neurosurgery* 1997;40:483-90.
- Hong JC, Kim MS, Chang CH, Kim SH. Arachnoid cyst with spontaneous intracystic hemorrhage and chronic subdural hematoma. *J Korean Neurosurg Soc* 2008;43:54-6.
- Morbée L, Lagae P, Jeannin P, Baelde N, De Mey J. Spontaneous disappearance of arachnoid cyst after head trauma. *J Belg Soc Radiol* 2015;99:107-8.
- Pradilla G, Jallo G. Arachnoid cysts: Case series and review of the literature. *Neurosurg Focus* 2007;22:E7.
- Albuquerque FC, Giannotta SL. Arachnoid cyst rupture producing sub-dural hygroma and intracranial hypertension: case reports. *Neurosurgery* 1997;41:951-6.
- Mori K, Yamamoto T, Horinaka N, Maeda M. Arachnoid cyst is a risk factor for chronic subdural hematoma in juveniles: Twelve cases of chronic subdural hematoma associated with arachnoid cyst. *J Neurotrauma* 2002;19:1017-27.
- Beltramello A, Mazza C. Spontaneous disappearance of a large middle fossa arachnoid cyst. *Surg Neurol* 1985;24:181-3.
- Yoshioka H, Kurisu K, Arita K, Eguchi K, Tominaga A, Mizoguchi N, *et al.* Spontaneous disappearance of a middle cranial fossa arachnoid cyst after suppurative meningitis. *Surg Neurol* 1998;50:487-91.
- Liu Z, Li J, Xu J. Teaching neuroimages: Spontaneous resolution of a giant intracranial arachnoid cyst. *Neurology* 2016;86:e199-200.
- Inoue T, Matsushima T, Tashima S, Fukui M, Hasuo K. Spontaneous disappearance of a middle fossa arachnoid cyst associated with subdural hematoma. *Surg Neurol* 1987;28:447-50.
- McDonald PJ, Rutka JT. Middle cranial fossa arachnoid cysts that come and go. Report of two cases and review of the literature. *Pediatr Neurosurg* 1997;26:48-52.
- Rakier A, Feinsod M. Gradual resolution of an arachnoid cyst after spontaneous rupture into the subdural space. Case report. *J Neurosurg* 1995;83:1085-6.
- Dodd RL, Barnes PD, Huhn SL. Spontaneous resolution of a prepontine arachnoid cyst. Case report and review of the literature. *Pediatr Neurosurg* 2002;37:152-7.
- Moon KS, Lee JK, Kim JH, Kim SH. Spontaneous disappearance of a suprasellar arachnoid cyst: Case report and review of the literature. *Childs Nerv Syst* 2007;23:99-104.
- Bristol RE, Albuquerque FC, McDougall C, Spetzler RF. Arachnoid cysts: Spontaneous resolution distinct from traumatic rupture. Case report. *Neurosurg Focus* 2007;22:E2.
- Pandey P, Tripathi M, Chandra PS, Singh VP, Mehta VS. Spontaneous decompression of a posterior fossa arachnoid cyst: A case report. *Pediatr Neurosurg* 2001;35:162-3.
- Arunkumar MJ, Haran RP, Chandy MJ. Spontaneous fluctuation in the size of a midline posterior fossa arachnoid cyst. *Br J Neurosurg* 1999;13:326-8.
- Weber R, Voit T, Lumenta C, Lenard HG. Spontaneous regression of a temporal arachnoid cyst. *Childs Nerv Syst* 1991;7:414-5.
- Przybylo HJ, Radkowski MA, Przybylo J, McLone D. Spontaneous resolution of an asymptomatic arachnoid cyst. *Pediatr Neurosurg* 1997;26:312-4.
- Goksu E, Kazan S. Spontaneous shrinkage of a suprasellar arachnoid cyst diagnosed with prenatal sonography and fetal magnetic resonance imaging: Case report and review of the literature. *Turk Neurosurg* 2015;25:670-3.
- Yamauchi T, Saeki N, Yamaura A. Spontaneous disappearance of temporo-frontal arachnoid cyst in a child. *Acta Neurochir (Wien)* 1999;141:537-40.
- Seizeur R, Forlodou P, Coustans M, Dam-Hieu P. Spontaneous resolution of arachnoid cysts: Review and features of an unusual case. *Acta Neurochir (Wien)* 2007;149:75-8.
- Cokluk C, Senel A, Celik F, Ergür H. Spontaneous disappearance of two asymptomatic arachnoid cysts in two different locations. *Minim Invasive Neurosurg* 2003;46:110-2.
- Jacob M, Gujar S, Trobe J, Gandhi D. Spontaneous resolution of a Meckel's cave arachnoid cyst causing sixth cranial nerve palsy. *J Neuroophthalmol* 2008;28:186-91.
- Adilay U, Guclu B, Tiryaki M, Hicdonmez T. Spontaneous resolution of a sylvian arachnoid cyst in a child: A case report. *Pediatr Neurosurg* 2017;52:343-5.
- Elbers SE, Furness ME. Resolution of presumed arachnoid cyst in utero. *Ultrasound Obstet Gynecol* 1999;14:353-5.