

# No. 2 in zone 2: a case report of penetrating neck trauma in a child

Rami Jason Bustami,<sup>1</sup> Alex Moses,<sup>1</sup> Ahmad Saeed Imam,<sup>1</sup> Ross Morgan<sup>2</sup>

► Additional material is published online only. To view please visit the journal online ([http://dx.doi.org/10.1136tsaco-2019-000333](http://dx.doi.org/10.1136/tsaco-2019-000333))

<sup>1</sup>College of Medicine, University of Central Florida, Orlando, Florida, USA

<sup>2</sup>Pediatric Surgery, Arnold Palmer Hospital for Children, Orlando, Florida, USA

## Correspondence to

Mr Rami Jason Bustami, College of Medicine, University of Central Florida, Orlando, FL 32837, USA; [rjbustami@knights.ucf.edu](mailto:rjbustami@knights.ucf.edu)

## INTRODUCTION

Penetrating neck trauma is common in adults but is rare in the pediatric population. Reports on penetrating neck trauma in the pediatric population is sparse. We describe the case of a 9-year-old boy presenting with a pencil penetrating the neck, discuss management, and review the literature.

## CASE PRESENTATION

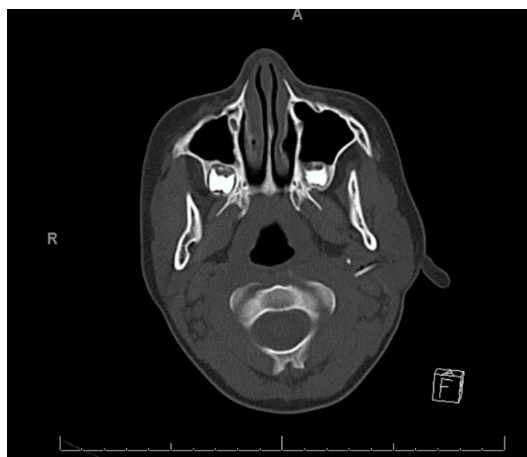
A 9-year-old boy with no medical history presented to the trauma bay by emergency medical services (EMS) approximately 45 min after falling onto a Number 2 (No. 2) pencil which penetrated the left preauricular space. The pencil was stabilized with gauze and tape by EMS prior to arrival. In the trauma bay, the patient denied loss of consciousness, profuse bleeding, headache, dizziness, lightheadedness.

## PHYSICAL EXAMINATION

Vital signs were stable. The patient was lying supine in an EMS stretcher with the dull end of a No. 2 pencil protruding from the left preauricular space, pointing caudally and posteriorly. Pencil was stabilized in gauze and tape. No active bleeding was present. Patient was awake, alert, and oriented. The patient had full range of motion of the mandible.

## WORKUP AND TREATMENT

Initial evaluation was performed with CT without contrast ([figure 1](#)). On poor visualization of the associated vasculature within the carotid sheath, a CT with contrast was performed. The radiologist reported no rupture of the blood vessels ([figure 2](#)).



**Figure 1** The initial CT without contrast was performed and showed the hyperdense graphite possibly compromising vascular structures within the neck.

The patient was subsequently taken to the operating room. The child was placed under general anesthesia with appropriate preparation in the supine position. Gauze and tape were removed, and the pencil was visualized pulsating at its location (online supplementary video 1). Pencil was grasped and removed. Wound was packed, sterile dressing placed. The patient's postoperative course was uneventful. He was discharged 2 days later. At 2 weeks follow-up, the patient was in good health and wound site was healing appropriately with mild scarring.

## DISCUSSION

Penetrating neck traumas have been studied extensively in adults but are under-reported in the pediatric population. In fact, only one pediatric cervical zone 2 penetrating trauma was found when reviewing the literature.<sup>1</sup> A study in 2016 using the National Trauma Data Bank found that pediatric penetrating neck trauma has an incidence of 0.28%.<sup>2</sup> This makes studying pediatric neck trauma difficult. Much is adopted from adult experiences.<sup>3</sup>

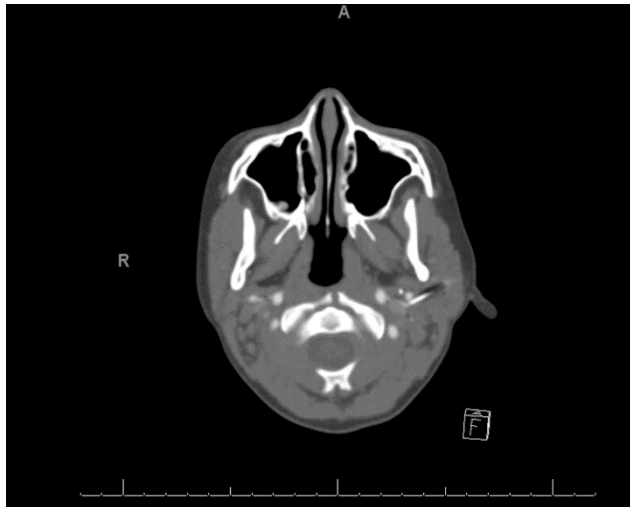
Currently, there are two diagnostic approaches used to assess the need for surgical intervention in penetrating neck trauma: zone-based approach and no-zone approach. The zone-based approach is an older approach, which decides management strategy based on zone, whereas the newer no-zone approach uses CT angiography after the patient's hemodynamic stability is determined.

More recent literature indicates that the no-zone approach can adequately identify aerodigestive and vascular injuries in penetrating neck wounds, although avoiding invasive diagnostic procedures used in the zone-based approach.<sup>4,5</sup> Additionally, in favor of the no-zone approach, there have been reports of a 100% sensitivity and 95% specificity for CT angiogram in adults with zone 2 penetrating traumas; however, these cases had direct zone 2 penetration.<sup>6</sup>

Against the favor of the zone-based approach, penetrating neck traumas externally entering a specific zone of the neck are not confined internally to that same zone. Low *et al* found that there was a high incidence of non-correlation between the location of the external injury and damaged internal structures.<sup>7</sup> Case in point, our case describes a zone 3 penetrating trauma that, due to the directionality of the penetration, almost compromised zone 2 structures (internal jugular vein, carotid artery, vertebral artery, esophagus, larynx, trachea, thyroid, thoracic duct, and major cervical nerves).<sup>8</sup>

© Author(s) (or their employer(s)) 2019. Re-use permitted under CC BY-NC. No commercial re-use. See rights and permissions. Published by BMJ.

**To cite:** Bustami RJ, Moses A, Imam AS, *et al*. *Trauma Surg Acute Care Open* 2019;4:e000333.



**Figure 2** The subsequent CT with contrast was then performed, which showed the hyperdense graphite, with point touching the internal jugular vein and abutting the external carotid artery, but without evidence of vascular rupture.

We used the no-zone approach to assess our patient. We assessed for any vascular or aerodigestive injury that required surgical intervention. Hall *et al* described seven indications for immediate surgical exploration, which include expanding hematomas, significant bleeding or signs of shock, subcutaneous emphysema, bruit, thrill, crepitus, or dysphagia.<sup>9</sup> If these signs are not evident, the literature recommends confirmatory imaging to rule out major structural compromise. On performing the CT without contrast, there was recommendation for an immediate CT angiogram due to the proximity to vital structures within the carotid sheath. This sequence demonstrates the importance of considering zone 2 structures, even in a zone 3 penetration, if directionality and mechanism of the penetrating injury make this transition possible. As such, we recommend immediate performance of a CT angiogram when there is a possible extension of injury to zone 2 structures.

Also, of note, this case provides useful information about the visibility of a Number 2 pencil on CT scans. The detail of the graphite within the pencil has a hyperdense quality that is distinguishable from neighboring soft tissue. However, the wood in the pencil was poorly visualized. This is congruent with the results found from a large animal foreign body imaging study in 2010.<sup>10</sup>

## CONCLUSION

Penetrating trauma to the neck is an uncommon emergency in the pediatric population. Penetrating neck trauma due to a pencil is exceedingly rare. Rapid identification, proper workup and subsequent removal in the operating room can prevent significant blood loss, disfigurement, or death.

**Contributors** RB is the primary author of the case report. AM, ASI and RM are co-authors in the report. RM is the faculty advisor for the report.

**Funding** The authors have not declared a specific grant for this research from any funding agency in the public, commercial or not-for-profit sectors.

**Competing interests** None declared.

**Patient consent for publication** Not required.

**Provenance and peer review** Not commissioned; externally peer reviewed.

**Open access** This is an open access article distributed in accordance with the Creative Commons Attribution Non Commercial (CC BY-NC 4.0) license, which permits others to distribute, remix, adapt, build upon this work non-commercially, and license their derivative works on different terms, provided the original work is properly cited, appropriate credit is given, any changes made indicated, and the use is non-commercial. See: <http://creativecommons.org/licenses/by-nc/4.0/>.

## REFERENCES

- Hewett KM, Mellick L. A case of penetrating neck trauma in a child. *Pediatr Emerg Care* 2012;28:49–51.
- Stone ME, Farber BA, Olorunfemi O, Kalata S, Meltzer JA, Chao E, Reddy SH, Teperman S. Penetrating neck trauma in children: an uncommon entity described using the National trauma data bank. *J Trauma Acute Care Surg* 2016;80:604–9.
- Cotton BA, Nance ML. Penetrating trauma in children. *Semin Pediatr Surg* 2004;13:87–97.
- Shiroff AM, Gale SC, Martin ND, Marchalik D, Petrov D, Ahmed HM, Rotondo MF, Gracias VH. Penetrating neck trauma: a review of management strategies and discussion of the 'No Zone' approach. *Am Surg* 2013;79:23–9.
- Munera F, Danton G, Rivas LA, Henry RP, Ferrari MG. Multidetector row computed tomography in the management of penetrating neck injuries. *Semin Ultrasound CT MR* 2009;30:195–204.
- Azuaje RE, Jacobson LE, Glover J, Gomez GA, Rodman GH, Broadie TA, Simons CJ, Bjerke HS. Reliability of physical examination as a predictor of vascular injury after penetrating neck trauma. *Am Surg* 2003;69:804–7.
- Low GMI, Inaba K, Chouliaras K, Branco B, Lam L, Benjamin E, Menaker J, Demetriades D. The use of the anatomic 'zones' of the neck in the assessment of penetrating neck injury. *Am Surg* 2014;80:970–4.
- Kim MK, Buckman R, Szeremeta W. Penetrating neck trauma in children: an urban hospital's experience. *Otolaryngol Head Neck Surg* 2000;123:439–43.
- Hall JR, Reyes HM, Meller JL. Penetrating zone-II neck injuries in children. *J Trauma* 1991;31:1614–7.
- Aras MH, Miloglu O, Barutcuoglu C, Kantarci M, Ozcan E, Harorli A. Comparison of the sensitivity for detecting foreign bodies among conventional plain radiography, computed tomography and ultrasonography. *Dentomaxillofac Radiol* 2010;39:72–8.