



Case Report

Video-Assisted Intubating Stylet Technique for Difficult Intubation: A Case Series Report

Pei-Juan Tsay ¹, Chih-Pin Yang ¹, Hsiang-Ning Luk ^{1,2,*} , Jason Zhensheng Qu ³  and Alan Shikani ^{4,5}

¹ Department of Anesthesia, Hualien Tzuchi Hospital, Hualien 97002, Taiwan; juliatsay@tzuchi.com.tw (P.-J.T.); dingisfun903@tzuchi.com.tw (C.-P.Y.)

² Bio-Math Laboratory, Department of Financial Engineering, Providence University, Taichung 43301, Taiwan

³ Department of Anesthesia, Critical Care and Pain Medicine, Massachusetts General Hospital, Harvard Medical School, Boston, MA 02114, USA; JQU@mgh.harvard.edu

⁴ Division of Otolaryngology-Head and Neck Surgery, LifeBridge Sinai Hospital, Baltimore, MD 21215, USA; ashikani@marylandent.com

⁵ Division of Otolaryngology-Head and Neck Surgery, MedStar Union Memorial Hospital, Baltimore, MD 21218, USA

* Correspondence: lukairforce@gmail.com

Abstract: Induction of anesthesia can be challenging for patients with difficult airways and head or neck tumors. Factors that could complicate airway management include poor dentition, limited mouth opening, restricted neck motility, narrowing of oral airway space, restricted laryngeal and pharyngeal space, and obstruction of glottic regions from the tumor. Current difficult airway management guidelines include awake tracheal intubation, anesthetized tracheal intubation, or combined awake and anesthetized intubation. Video laryngoscopy is often chosen over direct laryngoscopy in patients with difficult airways because of an improved laryngeal view, higher frequency of successful intubations, higher frequency of first-attempt intubation, and fewer intubation attempts. In this case series report, we describe the video-assisted intubating stylet technique in five patients with difficult airways. We believe that the intubating stylet is a feasible and safe airway technique for anesthetized tracheal intubation in patients with an anticipated difficult airway.

Keywords: difficult airway; intubating stylet; video laryngoscopy; craniofacial tumor; hypopharyngeal cancer; tonsillectomy; radiation fibrosis



Citation: Tsay, P.-J.; Yang, C.-P.; Luk, H.-N.; Qu, J.Z.; Shikani, A. Video-Assisted Intubating Stylet Technique for Difficult Intubation: A Case Series Report. *Healthcare* **2022**, *10*, 741. <https://doi.org/10.3390/healthcare10040741>

Academic Editor: Federico Longhini

Received: 28 March 2022

Accepted: 14 April 2022

Published: 15 April 2022

Publisher's Note: MDPI stays neutral with regard to jurisdictional claims in published maps and institutional affiliations.



Copyright: © 2022 by the authors. Licensee MDPI, Basel, Switzerland. This article is an open access article distributed under the terms and conditions of the Creative Commons Attribution (CC BY) license (<https://creativecommons.org/licenses/by/4.0/>).

1. Introduction

A difficult airway is always challenging for the airway operator. The incidence of failed tracheal intubation varies from 0.1% to 11% depending on patients' conditions and clinical scenarios [1,2]. Difficult airway guidelines have been developed and periodically revised to provide recommendations for clinicians. In clinical practice, video-laryngoscopes, fiberoptic bronchoscopes, supraglottic devices, or combined tools techniques are commonly used for elective/routine and emergency tracheal intubation [3–5].

A plethora of clinical studies have shown the advantages of commercial video-laryngoscopes over conventional direct laryngoscopes [6,7]. The comparisons were made in different clinical scenarios (e.g., elective and emergency intubation), distinct environments (e.g., operating rooms and intensive care units), various patients' conditions (e.g., adult, pediatrics, pregnancy, anesthetized or awake), and airway status (normal airway, expected and unanticipated difficult airway). The comparison parameters include the time taken to intubate, the success rate of the first attempt, the overall success rate, alternative rescue methods, and the complications rate.

In the past decades, since the video-assisted rigid intubating stylet was designed by Shikani [8] and modified by Levitan [9], numerous articles have been published detailing the safety and advantages of the Shikani video-assisted optical stylet tracheal intubation

method both in routine and unanticipated difficult airway management [10,11]. In this case series report, the objective was to share our experience using the Shikani video-assisted intubating stylet technique in five anticipated but challenging, difficult airway situations. There are four different brands of intubating stylets in our hands (Figure 1) and each of them suits its purpose perfectly. In this case series report, all the tracheal intubations were performed using the Video Intubation Light Stylet because of its unique feature of wireless transmission of the images onto a separate screen. Video Intubation Light Stylet (Trachway) is the same product as the Clarus Video System (CVS) and Optiscope Video Stylet (Clarus Medical LLC, Minneapolis, MN, USA) under different brand names. The airway operator was the same one for all these five cases, who is a certified anesthesiologist with 40 years of experience (including 16 years and 6 years of experience with video laryngoscopy and the intubating stylet technique, respectively). In an anesthetized human subject without anticipated airway problems, tracheal intubation using Video Intubation Light Stylet was shown to be smooth, swift, and accurate (Figure 2 and Supplementary Material Video S1).

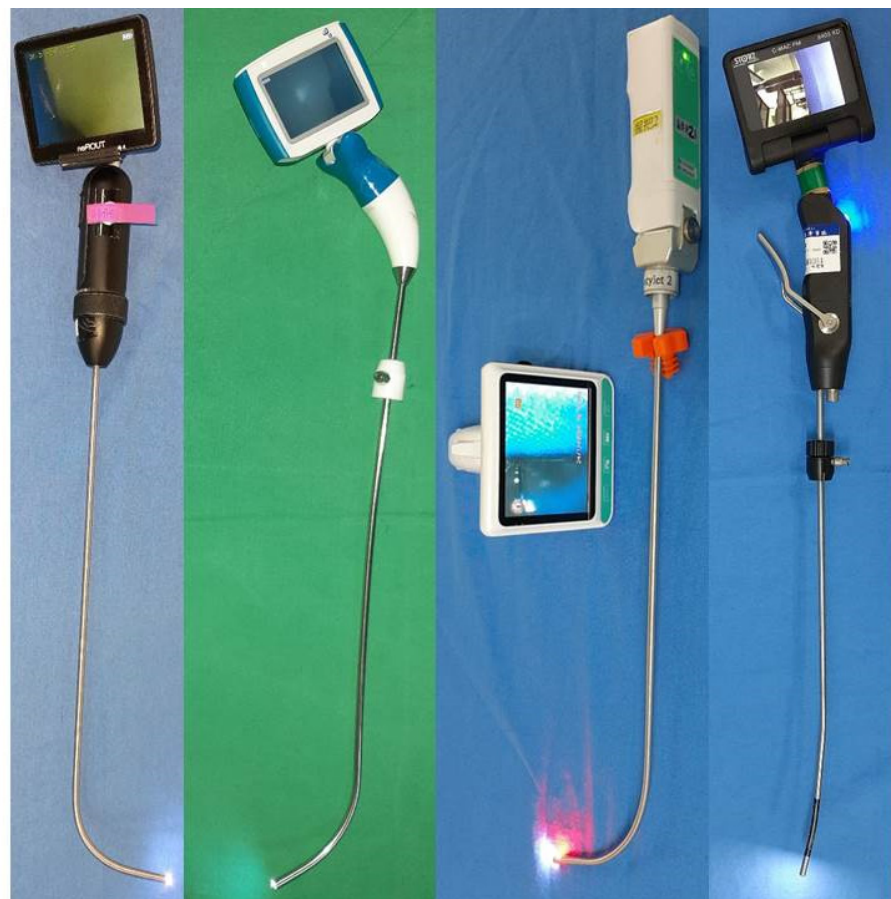

Figure 1. The video-assisted intubating stylets we routinely use for tracheal intubation. From left to right: Tuoren (Tuoren Kingtaek Video Intubating stylet, Henan Tuoren Medical Device Co., Changyuan City, Xinxiang, China); UE TRS video stylet (Zhejiang UE Medical Corp., Taizhou, China); Video Intubation Light Stylet (Markstein Sichtec Medical Corp., Taichung, Taiwan); C-MAC[®] VS (Video Stylet) (KARL STORZ SE & Co. KG, Tuttlingen, Germany).

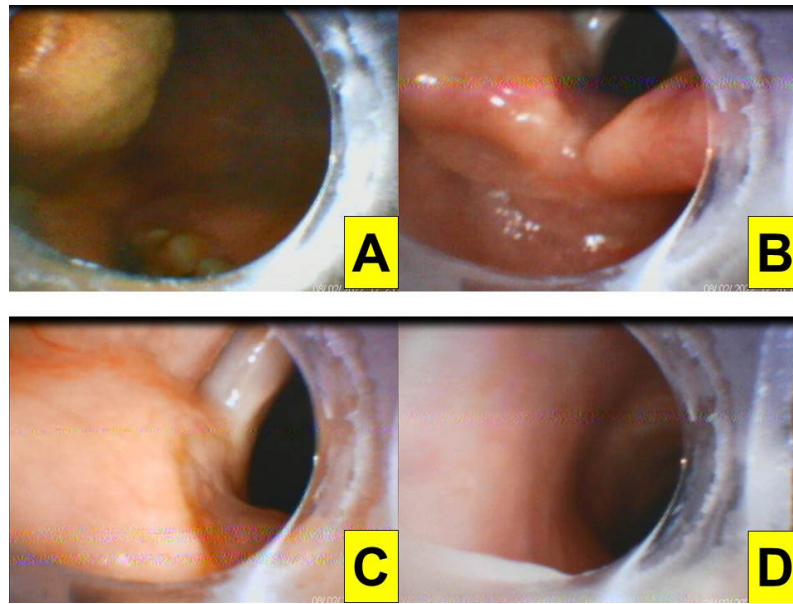


Figure 2. Views obtained through the video-assisted intubating stylet technique. (A) Oral pharynx; (B) glottis; (C,D) tracheal lumens. Time to intubate (from lip to trachea) is 7 s (see also the video clip in the Supplementary Material Video S1).

2. Cases Presentation

2.1. Case 1: Giant Cemento-Ossifying Fibroma

A 26-year-old man (158 cm, 52 kg, body mass index [BMI] 20.8 kg/m²) was referred to our medical center for an oculofacial tumor for four years. The preoperative tumor biopsy indicated a diagnosis of cemento-ossifying fibroma. A combined operation with wide excision, free fibular flap, and vastus lateralis muscle flap was scheduled in 2021. Because the tumor was extensive (14 cm × 11 cm × 10 cm in size) and invaded the left eye, nose, paranasal sinus, maxilla, and oral cavity, the flexible fiberoptic intubation through the nasotracheal path was impossible (Figure 3A–C). An awake surgical tracheostomy was refused by the patient as the first choice. After evaluation of the airway and ventilation status, oral tracheal intubation with the Shikani video-assisted intubating stylet technique was performed. The surgeons stood by for the possibility of surgical airway intervention. The patient first received pre-medication and high-flow nasal cannula oxygenation, followed by routine induction agents for anesthesia (glycopyrrolate, lidocaine, fentanyl, propofol, and succinylcholine). Tracheal intubation was planned using the video-assisted intubating stylet technique (with the Video Intubation Light Stylet). Although the oral cavity space was not wide enough, the stylet still could reach the epiglottis and then slipped under it. Eventually, a clear and full-size glottis view was obtained and the endotracheal tube was smoothly and swiftly railroaded into the trachea (Figure 3D). The tracheal intubation was confirmed, secured and mechanical ventilation was initiated without complications. The whole intubation process is demonstrated in Supplementary Material Video S2.

2.2. Case 2: Enlarged Palatine Tonsils

A 12-year-old girl (158 cm, 95 kg, BMI 38.0 kg/m²) was diagnosed with obstructive sleep apnea syndrome (OSAS) caused by enlarged tonsils (grade 3) and a redundant uvula. She was scheduled to undergo uvulo-palato-pharyngoplasty (UPPP) under general anesthesia in 2021. Routine vital signs monitoring was implemented, and anesthesia was induced with fentanyl, lidocaine, propofol, and rocuronium. Oral tracheal intubation was performed using the Shikani video-assisted intubating stylet technique (with the Video Intubation Light Stylet) with a 6.5 mm diameter endotracheal tube. Due to copious saliva and secretion in her oropharyngeal cavity, a suction tube was applied to clear the airway

before tracheal intubation. The epiglottis was reached, and a clear glottic view was obtained without difficulty (Figure 4). The whole process of tracheal intubation was smooth and swift (as shown in Supplementary Material Video S3).

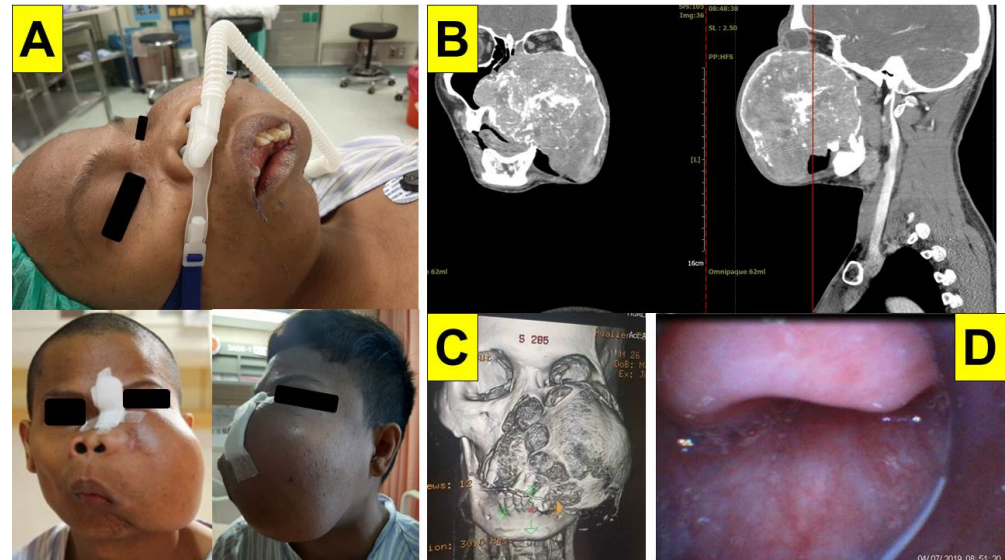


Figure 3. Case 1 (cemento-ossifying fibroma). (A) preoperative facial photos of the fibroma from different angles; (B) CT scan images of the fibroma; (C) preoperative computerized tomography face three-dimensional reconstruction of frontal view; (D) view of epiglottis from intubating stylet camera. (See also the video clip in Supplementary Material Video S2).

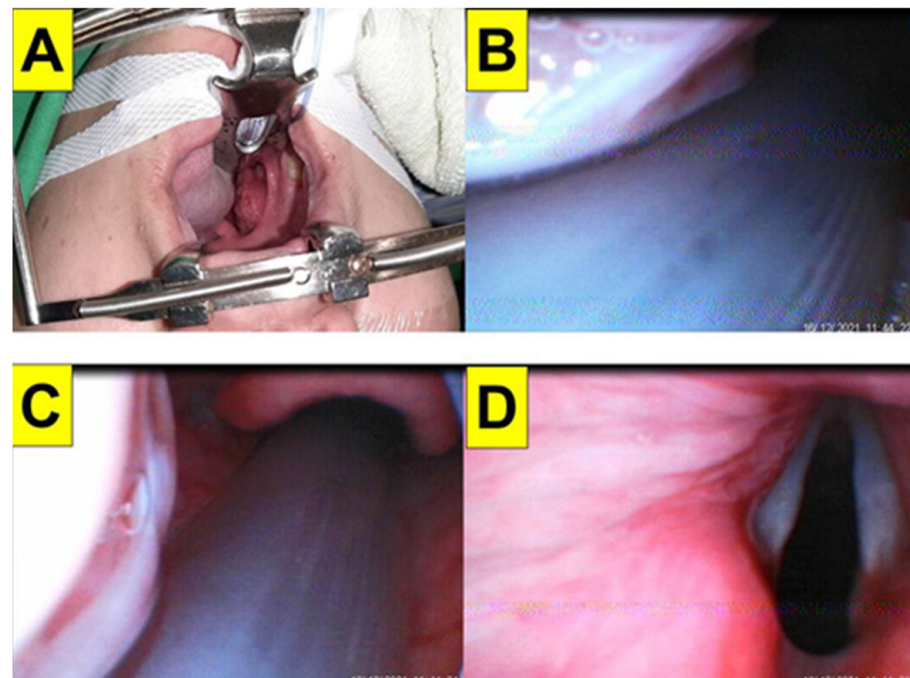


Figure 4. Case 2 (enlarged palatine tonsils). (A) View of enlarged right tonsil through a Dingman mouth gag; (B) intubating stylet passing by the left tonsil; (C) view of tonsil and epiglottis; (D) complete glottic view from intubating stylet camera. A suction tube device is seen in (B,C). (See also the video clip, Supplementary Material Video S3).

2.3. Case 3: Lower Gum Carcinoma with Neck Radiation Fibrosis

A 68-year-old man (164 cm, 40 kg, BMI 14.8 kg/m²) with right lower gum squamous cell carcinoma (pT4aN0) was scheduled to undergo a wide tumor excision (Commando operation), mandibulectomy, suprahyoid neck dissection, and tracheostomy in 2021. He was previously diagnosed with buccal and soft palate cancer 20 years ago and had undergone surgical resection and radiotherapy. Although post-radiotherapy neck muscle atrophy and soft-tissue fibrosis were noticed, the patient did not demonstrate any stridor or difficult breathing before induction of anesthesia. The mouth opening was restricted and only two-finger wide (Figure 5A,B). Although awake tracheostomy was not impossible, the surgical team preferred tracheal intubation to secure the airway first. We felt that a flexible fiberoptic intubation technique via the nasal path would be an option, however, we anticipated difficulty with increased secretions and bleeding along with the distorted anatomy with potential difficulty in advancing the tracheal tube. Oral tracheal intubation with the Shikani video-assisted intubating stylet technique was chosen (with the Video Intubation Light Stylet). Anesthesia was induced with fentanyl, lidocaine, propofol, and rocuronium. Sugammadex was ready for rescue if any difficult airway was encountered. The intubating procedure ended up being smooth and swift (Figure 5C,D also shown in Supplementary Material Video S4).

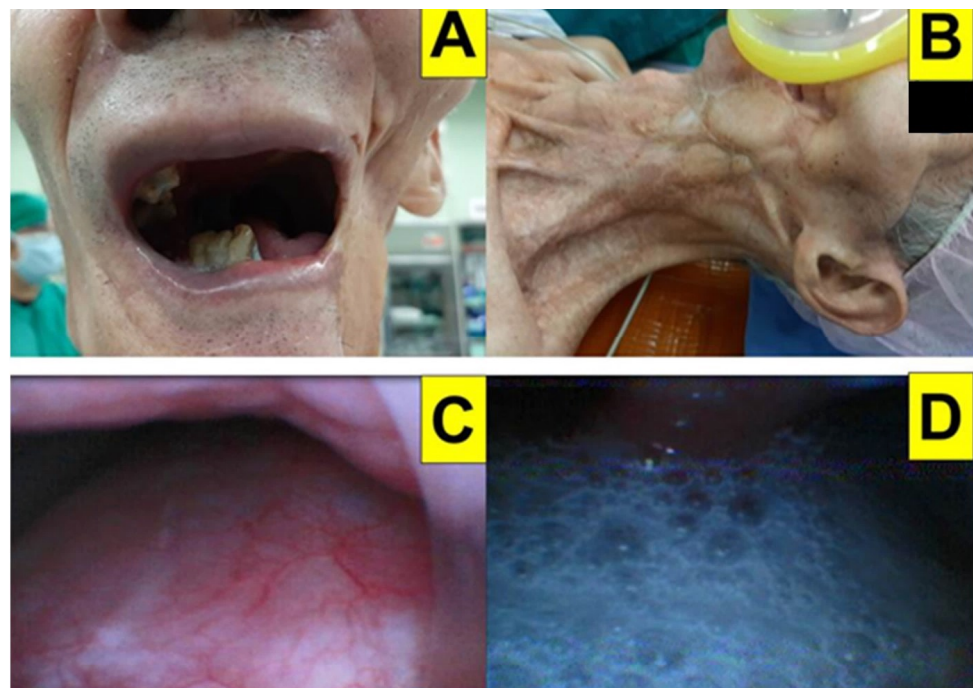


Figure 5. Case 3 (lower gum carcinoma with neck radiation fibrosis and surgical scar contracture). Limited mouth opening and poor dentition (A); stiff neck with restricted motility due to radiation fibrosis and scar contracture (B); intubating stylet view on pharyngeal space (C) and larynx (D). Copious mucus and saliva were noticed in front of the glottis. (See also the video clip in the Supplementary Material Video S4).

2.4. Case 4: Hypopharyngeal Cancer

A 63-year-old man (169 cm, 62 kg, BMI 21.7 kg/m²) was in his usual health status until 2 months prior to surgery when hoarseness was noted. A further examination and biopsy showed stage IV hypopharyngeal squamous cell carcinoma involving the left pyriform sinus cancer (T4aN2b) with extranodal extension (Figure 6A–C). The patient was scheduled to undergo a total laryngectomy with type II modified radical neck dissection, right selective neck dissection (II, III, IV), and free flap reconstruction in 2021. The standard monitoring was implemented and preoxygenation was applied. Oro-tracheal intubation was planned

using the Shikani video-assisted intubating stylet technique (with the Video Intubation Light Stylet) and was done with a 7.5 mm diameter endotracheal tube (Figure 6D,E). The surgeons were on standby for a possible surgical tracheotomy, however, this was not needed. Anesthesia was induced with glycopyrrolate, fentanyl, lidocaine, propofol, and succinylcholine. A suction tube through a nasal airway was inserted to clear the secretion inside the oropharyngeal space. The intubating process was done via the Shikani video-assisted stylet intubating technique in a smooth, swift, and uneventful fashion (shown in Supplementary Material Video S5).

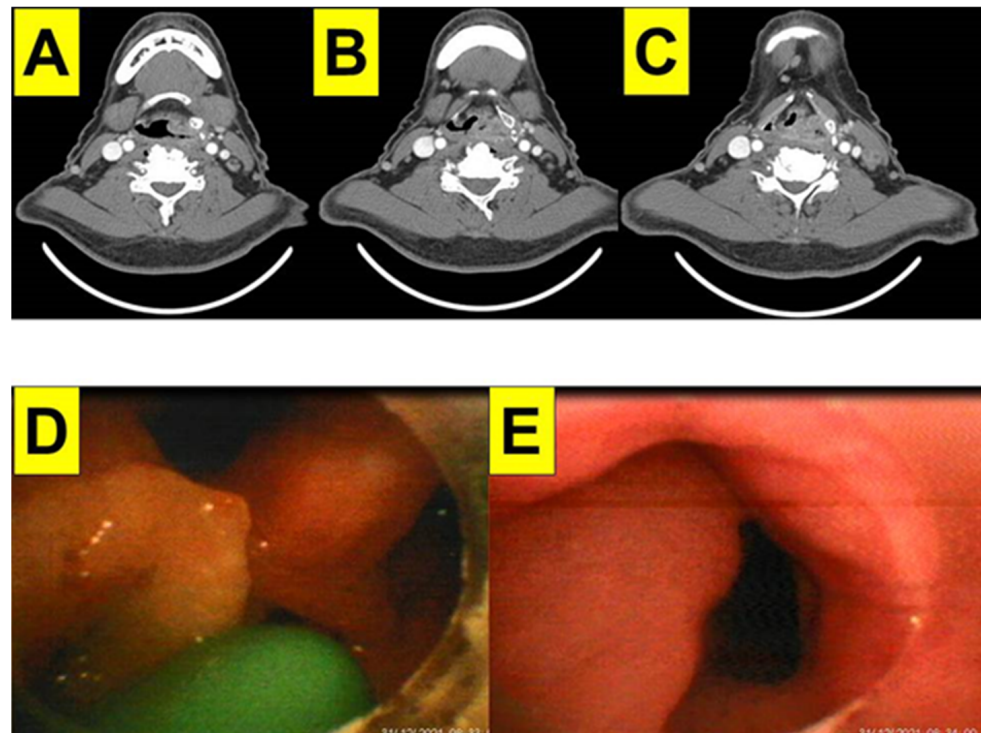


Figure 6. Case 4 (hypopharyngeal cancer). Computerized tomography scan views on hypopharyngeal tumor lesion (A–C). Such lesions can be seen from the intubating stylet camera (D,E). (See also the video clip in Supplementary Material Video S5).

2.5. Case 5: Vocal Cord Granuloma

A 46-year-old woman (160 cm and 72 kg, BMI 28.1 kg/m²) received a craniectomy due to intracerebral hemorrhage under general anesthesia with tracheal intubation with mechanical ventilation during the course of treatment. One year later, she suffered from hoarseness and was diagnosed with a very large vocal cord granuloma, obstructing a good portion of the glottis. After making her own decision with some delay, she eventually was willing to receive laryngo-microsurgery (LMS) to remove the granuloma in 2019. After implementing standard monitoring and adequate preoxygenation, anesthesia was induced with routine medications, including glycopyrrolate, lidocaine, fentanyl, propofol, and succinylcholine. The ENT team was on standby for possible surgical airway management, however, this was not needed. Oral tracheal intubation was then performed with the Shikani video-assisted intubating technique (with the Video Intubation Light Stylet) and a 6.5 mm endotracheal tube. The tracheal intubation was swift and successful on the first attempt (Figure 7A,B, also shown in Supplementary Material Video S6). Resection of the granuloma by LMS was smooth and uneventful (Figure 7C,D).

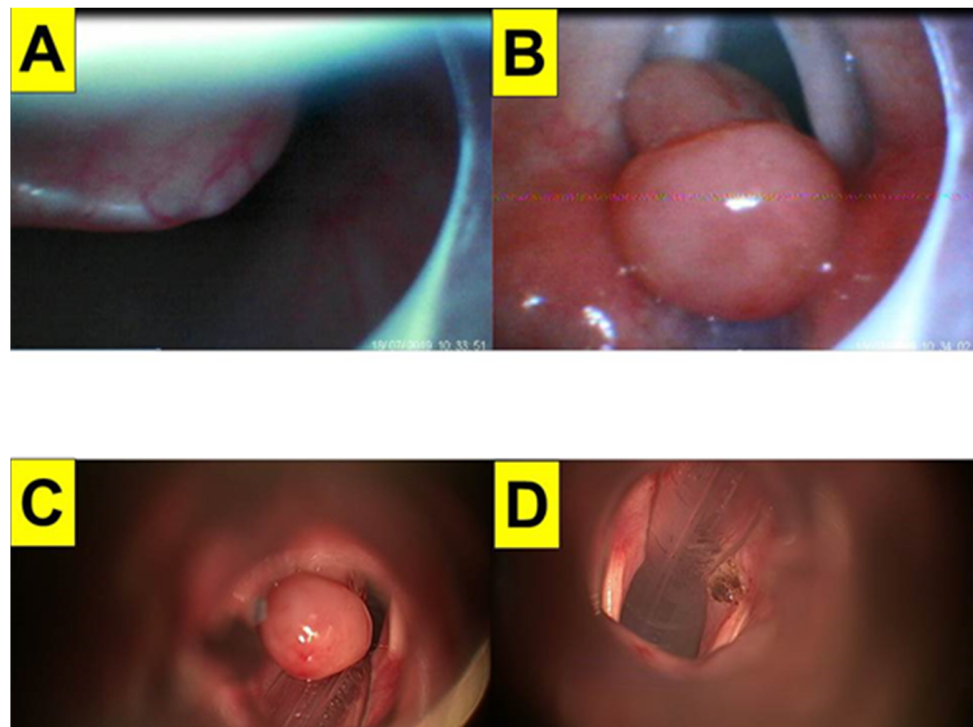


Figure 7. Case 5 (vocal cord granuloma). Intubating stylet view on epiglottis (A) and glottis (B). A granuloma was seen; laryngeal microscopic view on the granuloma before (C) and after (D) resection. (The video clip for the intubation process is shown in Supplementary Material Video S6).

3. Discussion

We reported five cases of anticipated difficult airways with various presentations, from facial-oral lesions to glottis abnormalities. Among the recommendations and the update in difficult airway guidelines made by the American Society of Anesthesiologists, some strategies have been proposed for the anticipated difficult intubation, depending on the patient's factors and condition, and the anesthesiologist's experience, skills, and preferences regarding airway management [12,13]. For example, in a situation where a difficult airway is anticipated but the patient can be adequately ventilated and oxygenated, awake intubation may not always be the first option. Instead, intubation under general anesthesia may be safer. In this case, the video laryngoscopy has been reported to be successful in various difficult airway scenarios (including morbid obesity, ankylosing spondylitis, congenital facial maxillary anomalies, giant thyroid goiter, oropharyngeal or laryngeal mass or tumor) [14,15].

In this report, we demonstrated the role of the Shikani video-assisted intubating stylet technique (Figures 1 and 2) in five patients with different airway challenges (from a facial-oral tumor to a glottis lesion, Figures 3–7). Although this case series report was not designed as a comparative clinical study between video laryngoscopy and the video-assisted intubating stylet technique, it is important to mention that we were successful on the first attempt using the aforementioned video-assisted intubating stylet in all these patients while we had real concerns about potentially facing difficulty with the other technique. In addition to the high success rate of the first attempt, the advantages of the intubating stylet technique include the short time to complete intubation, a low incidence of soft-tissue injuries and sympathetic reflexion (Table 1). Above all, the satisfaction level was high among the operators using the video-assisted intubating stylet technique.

Table 1. Advantageous features of video-assisted intubating stylet technique in the presenting five different clinical cases.

	Case 1	Case 2	Case 3	Case 4	Case 5
First-attempt success	Yes	Yes	Yes	Yes	Yes
Overall success rate			100%		
Laryngeal & glottic view	Full	Full	Full	Full	Full
Time to intubate (from lip to trachea)	24 s	12 s	25 s	26 s	50 s
Degree of difficulty for intubation	Easy	Easy	Easy	Easy	Easy
Required additional external maneuvers	No	No	No	No	No
Complications (tissue injuries, autonomic overstimulation, hypoxia)	No	No	No	No	No

The glottic view quality was judged by either the Cormack–Lehane grades or POGO scores.

The degree of difficulty for intubation was evaluated subjectively and confirmed by reviewing the video-recording images (Supplementary Materials Videos S1–S6).

Post-operative sore throat (POST) and hoarseness were not evaluated in these five head-neck surgical cases.

The potential airway risks for patients undergoing oral and throat surgery (e.g., tonsillectomy, laryngeal surgery, thyroidectomy, laryngectomy, etc.) cannot be overemphasized [16,17]. Unanticipated airway problems have been reported in patients with enlarged tonsils [18], thyroid tumor [19], neck radiation fibrosis [20], hypopharyngeal cancer and laryngectomy [21], and glottic lesions [22,23]. When dealing with a potentially difficult airway, airway operators should be prepared for any emergency. They should be familiar and comfortable with various airway management techniques that can be considered, including conventional blade laryngoscopy using a blade [24], fiberoptic nasotracheal intubation [25,26], flexible fiberoptic bronchoscope [27,28] and video laryngoscopy [29,30].

If the operator is not sure about the airway, it is generally recommended to keep the patient awake and maintain spontaneous respiration. In those cases, blade laryngoscopy intubation, which requires general anesthesia, is best avoided. Fiberoptic nasotracheal intubation and intubating stylet video laryngoscopy may be safer options in difficult airways. If the airway is potentially unstable, a planned surgical airway (tracheotomy) with the surgeon on standby could be considered. It has been our experience though, that intubation using the Shikani video-assisted intubating stylet technique has allowed us to avoid emergency tracheotomies in the great majority of difficult airway cases that we have encountered, even critical ones. This technique has shown to be superior to the Macintosh blade intubation in the literature [31–38].

In this case series, we report that the Shikani video-assisted intubating stylet technique is an easy and safe way to secure a variety of airway pathologies, including enlarged tonsils, radiation fibrosis of the upper airway and neck, hypopharyngeal cancer, vocal polyps, and granulomas. This is the first time that the use of the video-assisted intubating stylet technique has been reported in maxillofacial surgery. Difficult airways using conventional laryngoscopy were reported in maxillofacial surgery with a prevalence rate of 15.4% (against 1% to 4% in overall incidence) [13,14,39]. We have found that the video-intubating stylet technique is smooth and successful for patients undergoing large maxillofacial surgery (Figure 3, Table 1). It is also relevant to mention that the Shikani intubating stylet technique has also been described as advantageous in restricted neck movement and limited mouth opening [31–40]. It is less traumatic, being able to be used in patients with small mouth openings, thus requiring fewer neck or laryngeal manipulations [41–44].

Furthermore, it is worth mentioning that the airway operator might encounter some troubles while using the intubating stylet technique, such as an obstructed view by the soft tissues, difficulty finding the correct path to insert, blockade by the epiglottis, fogging of the lens, obstruction of the optics by saliva, mucous plugs, or blood, difficulty railroading the endotracheal tube into the trachea, etc. Fortunately, according to our own experiences, the time course for developing competency/proficiency in intubating using the stylet technique

is comparable to video laryngoscopy. Moreover, it should be emphasized that the outcomes of using the intubating stylet technique in anticipated difficult airway scenarios depend on various factors and conditions. While some airway operators with vast use experience and skills found the intubating stylet technique to be easy, others might not feel so at ease with dealing with such a technique. Therefore, a Plan B for airway management in such patient populations with potentially difficult airways should always be prepared in advance.

We found the Shikani video-assisted intubating stylet technique to be safe and reliable in a variety of airway management cases. We recommend that the airway operator add this technique to their armamentarium for managing the difficult airway. Initial training with simple cases is recommended before handling difficult ones.

Supplementary Materials: The following supporting information can be downloaded at: <https://www.mdpi.com/article/10.3390/healthcare10040741/s1>, Video S1: An example of routine tracheal intubation using the Shikani technique; Video S2: Shikani technique on Case 1 (cemento-ossifying fibroma); Video S3: Shikani technique on Case 2 (enlarged palatine tonsils); Video S4: Shikani technique on Case 3 (lower gum carcinoma with neck radiation fibrosis); Video S5: Shikani technique on Case 4 (hypopharyngeal cancer); Video S6: Shikani technique on Case 5 (vocal cord granuloma).

Author Contributions: Conceptualization, P.-J.T., C.-P.Y., H.-N.L., J.Z.Q. and A.S.; methodology, P.-J.T. and C.-P.Y.; validation, H.-N.L.; formal analysis, P.-J.T., C.-P.Y. and H.-N.L.; investigation, H.-N.L.; resources, H.-N.L.; data curation, H.-N.L.; writing—original draft preparation, P.-J.T., C.-P.Y. and H.-N.L.; writing—review and editing, J.Z.Q. and A.S.; visualization, H.-N.L.; supervision, H.-N.L.; project administration, H.-N.L.; funding acquisition, H.-N.L. All authors have read and agreed to the published version of the manuscript.

Funding: This research received no external funding.

Institutional Review Board Statement: The study was conducted according to the guidelines of the Declaration of Helsinki, and approved by REC, Hualien Tzuchi Hospital (Approved letter number: CR111-02).

Informed Consent Statement: Written informed consents were obtained from the patients or their legally authorized representatives (unless waived by the IRB).

Data Availability Statement: Not applicable.

Acknowledgments: Supported by Hualien Tzuchi Hospital.

Conflicts of Interest: The authors declare no conflict of interest.

References

1. Benumof, J.L. Management of the difficult adult airway. With special emphasis on awake tracheal intubation. *Anesthesiology* **1991**, *75*, 1087–1110. [[PubMed](#)]
2. Mort, T.C. Emergency tracheal intubation: Complications associated with repeated laryngoscopic attempts. *Anesth. Analg.* **2004**, *99*, 607–613. [[CrossRef](#)] [[PubMed](#)]
3. Apfelbaum, J.L.; Hagberg, C.A.; Connis, R.T.; Abdelmalak, B.B.; Agarkar, M.; Dutton, R.P.; Fiadjoe, J.E.; Greif, R.; Klock, P.A.; Mercier, D.; et al. American Society of Anesthesiologists practice guidelines for management of the difficult airway. *Anesthesiology* **2022**, *136*, 31–81.
4. Law, J.A.; Duggan, L.V.; Asselin, M.; Baker, P.; Crosby, E.; Downey, A.; Hung, O.R.; Jones, P.M.; Lemay, F.; Noppens, R.; et al. Canadian Airway Focus Group updated consensus-based recommendations for management of the difficult airway: Part 1. Difficult airway management encountered in an unconscious patient. *Can. J. Anaesth.* **2021**, *68*, 1373–1404. [[PubMed](#)]
5. Law, J.A.; Duggan, L.V.; Asselin, M.; Baker, P.; Crosby, E.; Downey, A.; Hung, O.R.; Kovacs, G.; Lemay, F.; Noppens, R.; et al. Canadian Airway Focus Group updated consensus-based recommendations for management of the difficult airway: Part 2. Planning and implementing safe management of the patient with an anticipated difficult airway. *Can. J. Anaesth.* **2021**, *68*, 1405–1436. [[PubMed](#)]
6. Healy, D.W.; Maties, O.; Hovord, D.; Kheterpal, S. A systematic review of the role of videolaryngoscopy in successful orotracheal intubation. *BMC Anesthesiol.* **2012**, *12*, 32. [[CrossRef](#)]
7. Matek, J.; Kolek, F.; Klementova, O.; Michalek, P.; Vymazal, T. Optical devices in tracheal intubation-State of the art in 2020. *Diagnostics* **2021**, *11*, 575. [[CrossRef](#)]
8. Shikani, A.H. New “seeing” stylet-scope and method for the management of the difficult airway. *Otolaryngol. Head Neck Surg.* **1999**, *120*, 113–116. [[CrossRef](#)]

9. Levitan, R.M. Design rationale and intended use of a short optical stylet for routine fiberoptic augmentation of emergency laryngoscopy. *Am. J. Emerg. Med.* **2006**, *24*, 490–495. [[CrossRef](#)]
10. Cheng, T.; Wang, L.K.; Wu, H.Y.; Yang, X.D.; Zhang, X.; Jiao, L. Shikani optical stylet for awake nasal intubation in patients undergoing head and neck surgery. *Laryngoscope* **2021**, *131*, 319–325. [[CrossRef](#)]
11. Fan, H.; Cao, H.; Sun, Y.; Chen, K.; Diao, Y.; Zhou, N.; Yao, G.; Zhou, J.; Zhang, T. Endotracheal intubation in elective cervical surgery: A randomized, controlled, assessor-blinded study. *Medicine* **2017**, *96*, e7817. [[CrossRef](#)] [[PubMed](#)]
12. Lovich-Sapola, J.; Johnson, F.; Smith, C.E. Anesthetic considerations for oral, maxillofacial, and neck trauma. *Otolaryngol. Clin. N. Am.* **2019**, *52*, 1019–1035. [[CrossRef](#)] [[PubMed](#)]
13. Zheng, G.; Feng, L.; Lewis, C.M. A data review of airway management in patients with oral cavity or oropharyngeal cancer: A single-institution experience. *BMC Anesthesiol.* **2019**, *19*, 92. [[CrossRef](#)] [[PubMed](#)]
14. Gupta, N.; Gupta, A.; Sarma, R.; Batra, A.; Madan, K. Video laryngoscopy vs. direct laryngoscopy for nasotracheal intubation in oromaxillofacial surgery: A systematic review and meta-analysis of randomized controlled trials. *Korean J. Anesthesiol.* **2021**, *74*, 439–448. [[CrossRef](#)] [[PubMed](#)]
15. Paolini, J.B.; Donati, F.; Drolet, P. Review article: Video-laryngoscopy: Another tool for difficult intubation or a new paradigm in airway management? *Can. J. Anaesth.* **2013**, *60*, 184–191. [[CrossRef](#)]
16. Eskander, A.; de Almeida, J.R.; Irish, J.C. Acute upper airway obstruction. *N. Engl. J. Med.* **2019**, *381*, 1940–1949. [[CrossRef](#)]
17. Waberski, A.T.; Espinel, A.G.; Reddy, S.K. Anesthesia safety in otolaryngology. *Otolaryngol. Clin. N. Am.* **2019**, *52*, 63–73. [[CrossRef](#)]
18. Ravindran, B.; Korandiarkunnel Paul, F.; Vyakarnam, P. Acute upper airway obstruction due to tonsillitis necessitating emergency cricothyroidotomy. *BMJ Case Rep.* **2021**, *14*, e242500. [[CrossRef](#)]
19. Kim, S.M.; Kim, H.J. Successful advancement of endotracheal tube with combined fiberoptic bronchoscopy and videolaryngoscopy in a patient with a huge goiter. *SAGE Open Med. Case Rep.* **2020**, *8*, 2050313X20923232. [[CrossRef](#)]
20. Huitink, J.M.; Zijp, L. Laryngeal radiation fibrosis: A case of failed awake flexible fiberoptic intubation. *Case Rep. Anesthesiol.* **2011**, *2011*, 878910. [[CrossRef](#)]
21. Moorthy, S.S.; Gupta, S.; Laurent, B.; Weisberger, E.C. Management of airway in patients with laryngeal tumors. *J. Clin. Anesth.* **2005**, *17*, 604–609. [[CrossRef](#)] [[PubMed](#)]
22. Nakahira, J.; Sawai, T.; Matsunami, S.; Minami, T. Worst-case scenario intubation of laryngeal granuloma: A case report. *BMC Res. Notes* **2014**, *7*, 74. [[CrossRef](#)] [[PubMed](#)]
23. Hofmeyr, R.; Llewellyn, R.; Fagan, J.J. Multidisciplinary difficult airway challenges: Perioperative management of glottic and supraglottic tumors. *Oper. Tech. Otolaryngol. Head Neck Surg.* **2020**, *31*, 120–127. [[CrossRef](#)]
24. Clarke, M.B.; Forster, P.; Cook, T.M. Airway management for tonsillectomy: A national survey of UK practice. *Br. J. Anaesth.* **2007**, *99*, 425–428. [[CrossRef](#)] [[PubMed](#)]
25. Evans, S.W.; McCahon, R.A. Management of the airway in maxillofacial surgery: Part 1. *Br. J. Oral Maxillofac. Surg.* **2018**, *56*, 463–468. [[CrossRef](#)]
26. Shindo, Y.; Toda, S.; Kido, K.; Masaki, E. Massive ameloblastoma: A case report of difficult fiberoptic intubation. *Ann. Med. Surg.* **2018**, *32*, 6–9. [[CrossRef](#)]
27. Asbjørnsen, H.; Kuwelker, M.; Søfteland, E. A case of unexpected difficult airway due to lingual tonsil hypertrophy. *Acta Anaesthesiol. Scand.* **2008**, *52*, 310–312. [[CrossRef](#)]
28. Zhang, X.; Cavus, O.; Zhou, Y.; Dusitkasem, S. Airway management during anesthetic induction of secondary laryngectomy for recurrent laryngeal cancer: Three cases of report and analysis. *Case Rep. Front. Med.* **2018**, *5*, 264. [[CrossRef](#)]
29. Pieters, B.M.A.; Maas, E.H.A.; Knape, J.T.A.; van Zundert, A.A.J. Videolaryngoscopy vs. direct laryngoscopy use by experienced anaesthetists in patients with known difficult airways: A systematic review and meta-analysis. *Anaesthesia* **2017**, *72*, 1532–1541. [[CrossRef](#)]
30. Aziz, M.F.; Dillman, D.; Fu, R.; Brambrink, A.M. Comparative effectiveness of the C-MAC video laryngoscope versus direct laryngoscopy in the setting of the predicted difficult airway. *Anesthesiology* **2012**, *116*, 629–636. [[CrossRef](#)]
31. Turkstra, T.P.; Pelz, D.M.; Shaikh, A.A.; Craen, R.A. Cervical spine motion: A fluoroscopic comparison of Shikani Optical Stylet vs Macintosh laryngoscope. *Can. J. Anaesth.* **2007**, *54*, 441–447. [[CrossRef](#)] [[PubMed](#)]
32. Yang, D.; Tong, S.Y.; Jin, J.H.; Tang, G.Z.; Sui, J.H.; Wei, L.X.; Deng, X.M. Shikani Optical Stylet-guided intubation via the intubating laryngeal airway in patients with scar contracture of the face and neck. *Chin. Med. Sci. J.* **2013**, *28*, 195–200. [[CrossRef](#)]
33. Yang, M.; Kim, J.A.; Ahn, H.J.; Choi, J.W.; Kim, D.K.; Cho, E.A. Double-lumen tube tracheal intubation using a rigid video-stylet: A randomized controlled comparison with the Macintosh laryngoscope. *Br. J. Anaesth.* **2013**, *111*, 990–995. [[CrossRef](#)] [[PubMed](#)]
34. Xu, M.; Li, X.X.; Guo, X.Y.; Jun Wang, J. Shikani Optical Stylet versus Macintosh laryngoscope for intubation in patients undergoing surgery for cervical spondylosis: A randomized controlled trial. *Chin. Med. J.* **2017**, *130*, 297–302. [[CrossRef](#)]
35. Wang, Y.H.; Xue, F.S.; Li, H.X.; Liu, Y.Y. Comparing Shikani Optical Stylet and Macintosh laryngoscope for orotracheal intubation. *Chin. Med. J.* **2017**, *130*, 1629–1630. [[CrossRef](#)]
36. Kucaba, G.; Muster, M.; Filip, D.; Horeczy, B.; Szarpak, L.; Woloszczuk-Gebicka, B. Pressure on the incisors during direct laryngoscopy and intubation using the Shikani Optical Stylet™. *Am. J. Emerg. Med.* **2017**, *35*, 1370–1372. [[CrossRef](#)] [[PubMed](#)]
37. Li, Z.; Wang, M.; Wang, Q.; Liu, C. Comparison of the Shikani Optical Stylet and Macintosh laryngoscope for orotracheal intubation with topical anesthesia in critically ill patients. *Clin. Med. Res.* **2018**, *7*, 84–91. [[CrossRef](#)]

38. Liu, X.; Zhang, Y.; Liu, Z.; Zhang, Q.; Wu, W.; Zheng, Z.; Zhang, Z. Application of second-generation Shikani optical stylet in critically ill patients undergoing cerebral aneurysm embolization. *J. Int. Med. Res.* **2019**, *47*, 1565–1572. [[CrossRef](#)]
39. Tuzuner-Oncul, A.M.; Kucukyavuz, Z. Prevalence and prediction of difficult intubation in maxillofacial surgery patients. *J. Oral Maxillofac. Surg.* **2008**, *66*, 1652–1658. [[CrossRef](#)]
40. Mahrous, R.S.S.; Ahmed, A.M.M. The Shikani Optical Stylet as an alternative to awake fiberoptic intubation in patients at risk of secondary cervical spine injury: A randomized controlled trial. *J. Neurosurg. Anesthesiol.* **2018**, *30*, 354–358. [[CrossRef](#)]
41. Ma, Y.; Wang, Y.; Shi, P.; Cao, X.; Ge, S. Ultrasound-guided versus Shikani optical stylet-aided tracheal intubation: A prospective randomized study. *BMC Anesthesiol.* **2020**, *20*, 221. [[CrossRef](#)] [[PubMed](#)]
42. Liu, L.; Yue, H.; Li, J. Comparison of three tracheal intubation techniques in thyroid tumor patients with a difficult airway: A randomized controlled trial. *Med. Princ. Pract.* **2014**, *23*, 448–452. [[CrossRef](#)] [[PubMed](#)]
43. Lin, N.; Li, M.; Shi, S.; Li, T.Z.; Zhang, B.X. Shikani™ Seeing Optical Stylet-aided tracheal intubation in patients with a large epiglottic cyst. *Chin. Med. J.* **2011**, *124*, 2795–2798. [[PubMed](#)]
44. Seo, H.; Lee, G.; Ha, S.I.; Song, J.G. An awake double lumen endotracheal tube intubation using the Clarus Video System in a patient with an epiglottic cyst: A case report. *Korean J. Anesthesiol.* **2014**, *66*, 157. [[CrossRef](#)]