



# Nasotracheal intubation in pediatrics: a narrative review

Jieun Kim, Sooyoung Jeon

National Dental Care Center for Persons with Special Needs, Seoul National University Dental Hospital, Seoul, Republic of Korea

Nasotracheal intubation (NTI) plays an important role in pediatric airway management, offering advantages in specific situations, such as oral and maxillofacial surgery and situations requiring stable tube positioning. However, compared to adults, NTI in children presents unique challenges owing to anatomical differences and limited space. This limited space, in combination with a large tongue and short mandible, along with large tonsils and adenoids, can complicate intubation. Owing to the short tracheal length in pediatric patients, it is crucial to place the tube at the correct depth to prevent it from being displaced due to neck movements, and causing injury to the glottis.

The equipment used for NTI includes different tube types, direct laryngoscopy vs. video laryngoscopy, and fiberoptic bronchoscopy. Considering pediatric anatomy, the advantages of video laryngoscopy have been questioned. Studies comparing different techniques have provided insights into their efficacy.

Determining the appropriate size and depth of nasotracheal tubes for pediatric patients remains a challenge. Various formulas based on age, weight, and height have been explored, including the recommendation of depth-mark-based NTI. This review provides a comprehensive overview of NTI in pediatric patients, including the relevant anatomy, equipment, clinical judgment, and possible complications.

**Keywords:** Complications; Intubation; Laryngoscopes; Nasotracheal; Oral and Maxillofacial Surgery; Pediatrics.



This is an Open Access article distributed under the terms of the Creative Commons Attribution Non-Commercial License (<http://creativecommons.org/licenses/by-nc/4.0/>) which permits unrestricted non-commercial use, distribution, and reproduction in any medium, provided the original work is properly cited.



## INTRODUCTION

Nasotracheal intubation (NTI) is a common airway management approach in oral, facial, and dental surgery since its introduction by Kuhn in 1902 [1]. NTI allows better surgical visibility and easier access to the surgical field during oral or maxillofacial surgery than oral intubation [2,3]. Additionally, NTI significantly reduces the frequency of unplanned extubations in pediatric intensive care units (PICUs) [4]. NTI is also more comfortable for patients and causes less damage to the lips, tongue, and larynx than oral intubation [5]. However,

NTI is technically more difficult and time-consuming than oral intubation, and there is a risk of injury to the nose and nasopharynx, bleeding, and sinusitis [5-7]. NTI is further complicated by a lack of specific guidelines for determining the appropriate tube size and insertion depth in pediatric patients. Most available literature reviews on NTI have been limited to adults. NTI reviews focusing on pediatric patients are not available. This review aimed to provide an overview of NTI in pediatric patients and discuss the recent studies on the appropriate tube size and insertion depth.

**Received:** February 19, 2024 • **Revised:** March 3, 2024 • **Accepted:** March 10, 2024

**Corresponding Author:** Sooyoung Jeon, National Dental Care Center for Persons with Special Needs, Seoul National University Dental Hospital, 101, Daehak-ro, Jongno-gu, Seoul, Republic of Korea

Tel: +82-2-6256-3728 Fax: +82-2-6256-3713 E-mail: [drjeonsy@gmail.com](mailto:drjeonsy@gmail.com)

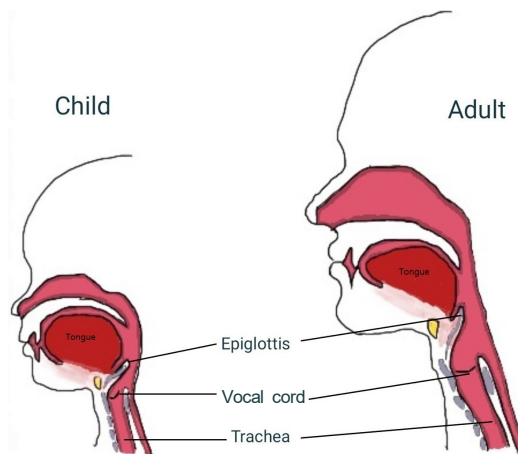
Copyright© 2024 Journal of Dental Anesthesia and Pain Medicine

## ANATOMY

Several crucial anatomical differences exist between the nasal structures of children and adults that can affect both normal function and medical procedures, such as nasotracheal intubation. Children have nasal structures characterized by reduced dimensions, narrower air channels, and less advanced bone growth than those in adults [8,9]. The lack of nasal space poses challenges for intubation and ventilation devices. Girls attain 84% of their complete nasal growth by 12 years of age, while boys attain 87% by 15 years of age [10]. Nasal development is nearly completed by 16 years of age in both boys and girls [8]. The nose is highly vascularized, particularly in the anterior cartilaginous septum where the venous vascular plexus, known as Little's area or Kisselbach's plexus, is located [9]. Most nosebleeds occur in this area (90% of all nosebleeds). Nosebleeds can occur even after minor trauma [11]. Epistaxis shows a bimodal age distribution, with the majority of cases occurring before the age of 10 years, or between 45 and 65 years [12].

Pediatric patients have relatively large tongues and short mandibles. They often have enlarged adenoids and tonsils, which may require surgery. These factors can make it challenging to maintain upper airway space, making mask ventilation difficult [13]. Unlike adults, young children have a cephalad larynx with an anterior-inferior to posterior-superior angle rather than a 90-degree angle with the trachea [14]. While this usually does not affect the laryngoscopic view, it may complicate endotracheal tube insertion and increase the risk of trauma [13].

Traditionally, children's airways were thought to change from funnel-shaped to cylindrical with growth [15]. However, studies using MRI, CT, and bronchoscopy have shown that the narrowest part of the airway in children is the glottis, which is the same as that in adults [16-18]. This has led to a paradigm shift in relation to the choice of endotracheal tubes. An uncuffed tube was



**Fig. 1.** The differences between the pediatric and adult airway. Epiglottis: floppier, U-shaped in children and shorter in adults. Vocal cords: inclined upward in children and horizontal in adults.

used when the cricoid cartilage was thought to be the narrowest part of the airway in children up to 8 years of age. However, with an updated understanding of the anatomy and the benefits of intubation with a cuffed tube, cuffed tubes have become the standard in pediatric anesthesia [19]. Importantly, NTI must be applied carefully because the short pediatric trachea makes it easier for the tube to change position when the neck is extended or flexed [14]. Moreover, a cuffed tube can cause trauma to the glottis [14]. Figure 1 illustrates the differences between the pediatric and adult airways.

## NASOTRACHEAL INTUBATION CONSIDERATIONS

NTI is valuable for oral, maxillofacial, and dental surgery. It is also suitable for patients with restricted mouth opening or oral infections. Furthermore, NTI is preferable for neonates and infants undergoing cardiac surgery because of the stable positioning of the tube during transesophageal echocardiography [20]. In contrast, NTI is contraindicated for cases of skull base fractures or CSF leakage. Additionally, in patients with coagulopathy, trauma to the nasal passage during NTI may cause significant bleeding. Deciding which nostril to use for NTI is crucial for minimizing epistaxis and facilitating intubation. Relative patency information can

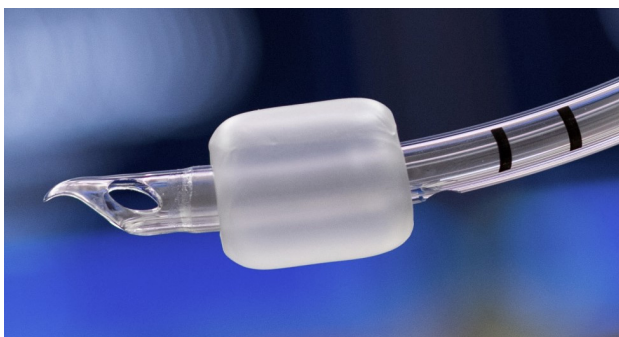


Fig. 2. The Parker Flex-Tip™ tube tip with a unique, patented design that helps avoid damaging the airway.

be gathered during preanesthetic evaluation by obtaining history or by occluding one nostril and breathing through the other [21]. Furthermore, rhinoscopy, flexible endoscopy, radiography, and CT scans may be beneficial. However, in pediatric patients, the impact of radiation exposure and cooperation issues must be considered.

## NASOTRACHEAL INTUBATION EQUIPMENT

### 1. The types of tubes

There are several types of tubes used for NTI. They vary in shape of the tube tip and/or material. The Murphy tip is a tube with a Murphy eye, which increases the risk of mucosal injury of the nasal cavity [22]. In contrast, the Parker Flex-Tip™ (Fig. 2) has a flexible distal tip that decreases the risk of nasal mucosa injury by avoiding direct contact with the turbinate and septum [23,24]. The Portex® North Polar tube (Fig. 3), made of velvet-soft polyvinyl chloride material, has been associated with fewer nosebleeds in clinical trials [25]. However, the smallest size of the Portex® has an internal diameter of 6.0 mm, which is not suitable for most pediatric use.

### 2. Direct laryngoscope versus video laryngoscope

NTI can be divided into three distinct phases: 1) entry through the nose into the pharynx; 2) guided insertion into the glottic inlet using a laryngoscope; and 3) guided insertion into the trachea using a laryngoscope [21].

During NTI via direct laryngoscopy, the Magill forceps

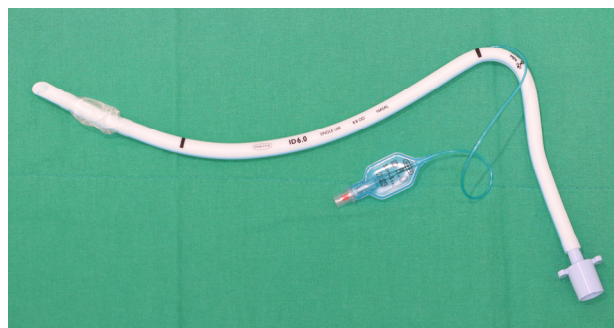


Fig. 3. The Portex® North Polar tube

is often used to properly position the nasotracheal tube within the trachea [26,27]. This maneuver can result in trauma to nearby tissues and potentially damage the tube cuff [26,28].

Video laryngoscopy during NTI offers a clear visualization of the glottis, leading to increased intubation success rates and shorter intubation times, and reduces the need for the Magill forceps [29-31]. These findings are based on adult studies, and thus, may not be generalizable to the pediatric population due to the cephalad larynx and posteriorly angled nature of the trachea in children. In a network meta-analysis of the effectiveness of indirect laryngoscopy versus direct laryngoscopy in pediatric patients, Hoshijima et al. reported that direct laryngoscopy (Macintosh blade) and video laryngoscopy had similar intubation failure rates and glottic visualization. The intubation time was only shorter for the C-MAC®. In contrast, longer intubation times were required for the GlideScope®, Storz DCI®, and Truview PCD®, when compared to the Macintosh blade [32]. Recent pediatric research comparing the use of the Macintosh laryngoscope, McGrath® video laryngoscope, and Pentax Airway Scope® for NTI showed that intubation difficulties were comparable among the groups [33]. However, the Macintosh laryngoscope required a shorter intubation time compared to that of the video laryngoscope [33]. Another NTI study comparing the C-MAC® and Macintosh laryngoscopes in pediatric patients found the C-MAC® to be superior for glottic visualization, intubation time, and for additional manipulation [34]. The large blade and curvature of the

video laryngoscope sometimes make it difficult to align the tube from the oropharynx to the glottis using the Magill forceps [31]. To achieve this alignment without using the Magill forceps, Goodine et al. suggested minimizing the lifting of the glottis during laryngoscopy and/or inflating the cuff of the nasotracheal tube [35].

### 3. Fiberoptic bronchoscopy

In pediatric patients, fiberoptic intubation is indicated for difficult airways, particularly in managing cases involving restricted mouth opening, intraoral masses, and craniofacial dysmorphism [36-38]. It is also indicated for pediatric patients who require awake intubation [39,40], and has been reported to produce a more stable hemodynamic response during intubation [41]. However, it requires specialized equipment and a longer intubation time, and can only be performed by a trained anesthesiologist [36,42]. Prolonging the intubation time in pediatric patients increases mortality risks as the window of time for ensuring a safe oxygen level during apnea is limited [13,43]. Consequently, maintaining continuous oxygenation through the opposite nostril during awake fiberoptic intubation is recommended for children with difficult airways. Unlike adult patients, the procedure is challenging in children due to their lack of cooperation. Moreover, visual access is limited due to the smaller size of the pediatric airway, and even minor movements of the scope tip may obstruct the view [36].

## NASOTRACHEAL TUBE SIZE AND DEPTH OF INSERTION

Determining the size and depth of nasotracheal tube insertion in pediatric patients can be challenging. Smaller sizes may lead to air leakage, resulting in inadequate mechanical ventilation, and an increased risk of pulmonary aspiration, while larger sizes can result in pressure-related ischemic injury [44]. Age ( $ID = 4 + 4/\text{age}[\text{years}]$ ), height ( $2 + \text{height}[\text{cm}]/30$ ), and weight ( $\text{weight}[\text{kg}]/10 + 3.5$ ) are considered when determining

the appropriate oral intubation tube size for a child [45-47]. Importantly, studies on the tube size used for NTI in pediatric patients are lacking. In a retrospective study of 442 children, Tsukamoto et al. recommended using height as a guide. Specifically, the study focused on the size of uncuffed endotracheal tubes, and the authors suggested choosing a 0.5 mm smaller tube if the expected tube size is 5.5-6.0 mm and a 0.5 mm larger tube if the expected tube size is 4.0 mm [48]. Chou et al. in their 2023 retrospective study of 684 patients evaluated the cuffed nasotracheal tube and found that tubes 0.5 mm smaller fit better than the age-based formula ( $4 + \text{age}/4$ ). The authors also proposed a new formula [49]:

$$ID (\text{mm}) = 3.98 + 0.052 \times \text{age} + 0.048 \times \text{gender} (\text{male} = 1, \text{female} = 0) + 0.023 \times \text{body weight} (\text{kg})$$

Correct insertion depth is critical because of the short length of the trachea in children. An inappropriate depth may result in bronchial intubation and unplanned extubation [50,51]. Table 1 provides the details from several studies examining the depth of nasotracheal tubes in pediatric patients [49,52-59], including the appropriate nasotracheal intubation depths. The authors suggested formulas based on age, weight, and height. Some relied on a single variable, while others recommended multiple variables, such as age and sex. Kemper et al. demonstrated that depth-mark-based NTI outperforms these formulas [58]. However, errors may also be associated with this method. Therefore, verifying the depth by auscultation or cuff palpation is crucial. Furthermore, ultrasonography can be used to verify the precise location of the endotracheal tube cuff [60].

## NASOTRACHEAL INTUBATION COMPLICATIONS

### 1. Epistaxis

Nosebleeds, especially at the Kisselbach's plexus and the anterior nasal septum region, are the most common complications of NTI [9,61]. To prevent nosebleeds, a smaller tube, vasoconstrictors (oxymetazoline nasal

**Table 1.** Formula or recommendation of pediatric nasotracheal tube insertion depth

No	Source, author, year	Age (years), n, site	Nasal tube length (cm)/Formula or recommendation
1	Paediatric Anaesthesia, Davenport, 3 <sup>rd</sup> Edn (1980) [52]	-	14 + (age/2)
2	Yates AP et al (1987) [53]	0-18, 634, ICU	L = (3 × S) + 2; > 3 kg, S = internal diameter (ID) in mm
		Newborn	14
		1	15
		2	16
3	Manual of Pediatric Anesthesia, Steward, 5 <sup>th</sup> Edn (2001) [54]	4	17
		6	19
		8	21
		10	22
4	Antona M, et al (2002) [55]	0-4, 99, ICU	10.5 + (weight/2)
5	Kim KO, et al (2003) [56]	0-7, 85, OR	Tube tip 2 cm above carina
6	Lau N, et al (2006) [57]	0-15, 89, ICU	Age < 1      9 + (weight/2) Age > 1      15 + (age/2)
7	Kemper M, et al (2014) [58]	0-10, 76, OR	Depth mark-based NTI is superior to formula and recommendation.
8	Imani AT, et al (2023) [59]	0-4, 110, OR	L = 0.1 × height + 7
9	Chou C, et al (2023) [49]	0-17, 684, OR	L = 15.1 + 0.43age + 0.300 × gender (male = 1, female = 0)

Age (years), weight (kg), height (cm), ICU, intensive care unit; No, number; OR, operating room.

Study No.7: comparison of study No.1 to 6

Study No.8: comparison of study No. 1, 2, 4, 6

spray), and tube lubrication can be considered. Other methods include thermosoftening of the tube or intubation with a red-rubber catheter placed at the end of the tube. Of these, the effectiveness of oxymetazoline nasal spray has not been clearly demonstrated, and it is not used by many anesthesiologists because of rare complications, such as cardiac arrest [62]. Tube warming is effective in adults [63,64], but studies in children did not demonstrate a reduction in the frequency of clinically relevant bleeding [65]. A meta-analysis by Tan et al. considered NTI-induced nosebleeds and the right versus the left nostril. The authors found that when both nostrils were patent, intubating the right nostril was associated with fewer nosebleeds and shorter intubation times [66]. The meta-analysis analyzed ten randomized controlled trials limited to adult patients, and did not include pediatric patients. Several studies have examined the association between epistaxis and tube tips, but these have also been limited to adults. Lee et al. found that nosebleeds were more common with Murphy tip tubes than with Magill tip tubes [22]. Sanuki T et al. and Sugiyama K et al. reported reduced epistaxis with the Parker Flex-Tip™ nasal tube compared to a standard tube

[23,24]. In contrast, Earle R. et al. observed no significant difference [67].

## 2. Sinusitis

Prolonged NTI may obstruct nasal drainage, leading to sinusitis [68,69]. Sinus opening occlusions can impede sinus drainage, resulting in edema and facilitating local infection of the nasal mucosa, thus, ultimately leading to higher occurrences of sinusitis. A higher incidence of sinusitis has been associated with NTI in adult patients compared to the use of oral tubes [70,71]. On the contrary, a retrospective study of PICUs in the United States reported no difference in the frequency of sinusitis between oral and nasotracheal intubations [4]. Most patients in the PICU study were very young and the sinus had not completely developed at the time of intubation, which may explain the low frequency of sinusitis.

## 3. Necrosis of the nasal ala

Superficial necrosis of the nasal ala is a common complication related to NTI, with an incidence of 2.2-24.48% [2,72]. To prevent pressure on the nasal ala, shortening the duration of surgery and using hydrocolloid

dressings to prevent pressure sores have been suggested [73,74]. However, these methods may not always be feasible in pediatric patients due to limited space in the nares [74].

#### 4. Retropharyngeal perforation

Although rare, retropharyngeal perforation can have serious consequences [75,76]. If the tube encounters resistance and no breath sounds are heard, the possibility that the tube is already positioned against the pharyngeal wall should be recognized.

#### 5. Bacteremia

In patients undergoing dental treatment under general anesthesia, the risk of bacteremia is particularly high. Bacteremia can be caused by the spread of alpha-hemolytic *Streptococcus* and *Corynebacterium spp.*, the most common bacteria in the nasal cavity, that enter the blood via damaged nasal mucosa [2,77]. To prevent this, the use of mupirocin ointment, prophylactic antibiotics, and minimizing nasal damage should be considered, especially among high-risk patients [78-80].

### CONCLUSIONS

NTI in pediatric patients is a valuable airway management technique and offers advantages in specific situations. Healthcare providers must have a thorough understanding of the indications, complications, and recent advancements in airway management to ensure safe and effective airway management in pediatric patients. NTI with a video laryngoscope or fiberoptic scope is particularly helpful when handling difficult airways. Finally, given the disparity in outcomes between adults and children and the limited number of studies available, further studies in the pediatric population are warranted.

#### AUTHOR ORCIDs

**Jieun Kim:** <https://orcid.org/0000-0002-8265-1952>

**Sooyoung Jeon:** <https://orcid.org/0000-0003-2119-0360>

#### AUTHOR CONTRIBUTIONS

**Jieun Kim:** Conceptualization, Investigation, Writing - original draft, Writing - review & editing

**Sooyoung Jeon:** Conceptualization, Supervision, Writing - original draft, Writing - review & editing

**DECLARATIONS OF INTEREST:** The authors declare no conflicts of interest.

### REFERENCES

1. Dhakate VR, Singam AP, Bharadwaj HS. Evaluation of nasopharyngeal airway to facilitate nasotracheal intubation. *Ann Maxillofac Surg* 2020; 10: 57-60.
2. Prasanna D, Bhat S. Nasotracheal intubation: an overview. *J Maxillofac Oral Surg* 2014; 13: 366-72.
3. Hall CE, Shutt LE. Nasotracheal intubation for head and neck surgery. *Anaesthesia* 2003; 58: 249-56.
4. Christian CE, Thompson NE, Wakeham MK. Use and outcomes of nasotracheal intubation among patients requiring mechanical ventilation across U.S. PICUs. *Pediatr Crit Care Med* 2020; 21: 620-4.
5. Holzapfel L. Nasal vs oral intubation. *Minerva Anestesiol* 2003; 69: 348-52.
6. Jagannathan N, Sequera-Ramos L, Sohn L, Huang A, Sawardekar A, Wasson N, et al. Randomized comparison of experts and trainees with nasal and oral fiberoptic intubation in children less than 2 yr of age. *Br J Anaesth* 2015; 114: 290-6.
7. Black AE, Hatch DJ, Nauth-Misir N. Complications of nasotracheal intubation in neonates, infants and children: a review of 4 years' experience in a children's hospital. *Br J Anaesth* 1990; 65: 461-7.
8. Samoliński BK, Grzanka A, Gotlib T. Changes in nasal cavity dimensions in children and adults by gender and

- age. *Laryngoscope* 2007; 117: 1429-33.
9. Zalzal HG, O'Brien DC, Zalzal GH. Pediatric anatomy: nose and sinus. *Oper Tech Otolaryngol Head Neck Surg* 2018; 29: 44-50.
  10. Buck DL, Brown CM. A longitudinal study of nose growth from ages 6 to 18. *Ann Plast Surg* 1987; 18: 310-3.
  11. Bernius M, Perlin D. Pediatric ear, nose, and throat emergencies. *Pediatr Clin North Am* 2006; 53: 195-214.
  12. Pallin DJ, Chng YM, McKay MP, Emond JA, Pelletier AJ, Camargo CA Jr. Epidemiology of epistaxis in us emergency departments, 1992 to 2001. *Ann Emerg Med* 2005; 46: 77-81.
  13. Harless J, Ramaiah R, Bhananker SM. Pediatric airway management. *Int J Crit Illn Inj Sci* 2014; 4: 65-70.
  14. Santillanes G, Gausche-Hill M. Pediatric airway management. *Emerg Med Clin North Am* 2008; 26: 961-75, ix.
  15. Eckenhoff JE. Some anatomic considerations of the infant larynx influencing endotracheal anesthesia. *Anesthesiology* 1951; 12: 401-10.
  16. Litman RS, Weissend EE, Shibata D, Westesson PL. Developmental changes of laryngeal dimensions in unparalyzed, sedated children. *Anesthesiology* 2003; 98: 41-5.
  17. Dalal PG, Murray D, Messner AH, Feng A, McAllister J, Molter D. Pediatric laryngeal dimensions: an age-based analysis. *Anesth Analg* 2009; 108: 1475-9.
  18. Wani TM, Bissonnette B, Rafiq Malik M, Hayes D Jr, Ramesh AS, Al Sohaibani M, et al. Age-based analysis of pediatric upper airway dimensions using computed tomography imaging. *Pediatr Pulmonol* 2016; 51: 267-71.
  19. Litman RS, Maxwell LG. Cuffed versus uncuffed endotracheal tubes in pediatric anesthesia: the debate should finally end. *Anesthesiology* 2013; 118: 500-1.
  20. Greene NH, Jooste EH, Thibault DP, Wallace AS, Wang A, Vener DF, et al. A study of practice behavior for endotracheal intubation site for children with congenital heart disease undergoing surgery: impact of endotracheal intubation site on perioperative outcomes—an analysis of the society of thoracic surgeons congenital cardiac anesthesia society database. *Anesth Analg* 2019; 129: 1061-8.
  21. Park DH, Lee CA, Jeong CY, Yang HS. Nasotracheal intubation for airway management during anesthesia. *Anesth Pain Med (Seoul)* 2021; 16: 232-47.
  22. Lee JH, Kim CH, Bahk JH, Park KS. The influence of endotracheal tube tip design on nasal trauma during nasotracheal intubation: magill-tip versus murphy-tip. *Anesth Analg* 2005; 101: 1226-9.
  23. Sanuki T, Hirokane M, Matsuda Y, Sugioka S, Kotani J. The parker flex-tip tube for nasotracheal intubation: the influence on nasal mucosal trauma. *Anaesthesia* 2010; 65: 8-11.
  24. Sugiyama K, Manabe Y, Kohjitan A. A styletted tracheal tube with a posterior-facing bevel reduces epistaxis during nasal intubation: a randomized trial. *Can J Anaesth* 2014; 61: 417-22.
  25. Özkan ASM, Akbas S, Toy E, Durmus M. North polar tube reduces the risk of epistaxis during nasotracheal intubation: a prospective, randomized clinical trial. *Curr Ther Res Clin Exp* 2019; 90: 21-6.
  26. Mahajan R, Batra YK, Kumar S. Another use of magill forceps to assist nasotracheal intubation. *Can J Anaesth* 2007; 54: 957-8.
  27. Munshey FN, Gamble JJ, McKay WP. Modified pediatric magill forceps effect on nasal intubation time. *Paediatr Anaesth* 2016; 26: 221-2.
  28. Nakamura S, Watanabe T, Hiroi E, Sasaki T, Matsumoto N, Hori T. Cuff damage during naso-tracheal intubation for general anesthesia in oral surgery. *Masui* 1997; 46: 1508-14.
  29. Asai T. Are videolaryngoscopes useful for nasotracheal intubation? *J Anesth* 2014; 28: 647-9.
  30. Puchner W, Drabauer L, Kern K, Mayer C, Bierbaumer J, Rehak PH, et al. Indirect versus direct laryngoscopy for routine nasotracheal intubation. *J Clin Anesth* 2011; 23: 280-5.
  31. Ryoo SH, Park KN, Karm MH. The utilization of video laryngoscopy in nasotracheal intubation for oral and maxillofacial surgical procedures: a narrative review. *J Dent Anesth Pain Med* 2024; 24: 1-17.
  32. Hoshijima H, Mihara T, Kokubu S, Takeda S, Shiga T,

- Mizuta K. Effectiveness of indirect and direct laryngoscopes in pediatric patients: a systematic review and network meta-analysis. *Children (Basel)* 2022; 9: 1280.
33. Yoo JY, Chae YJ, Lee YB, Kim S, Lee J, Kim DH. A comparison of the macintosh laryngoscope, mcgrath video laryngoscope, and pentax airway scope in paediatric nasotracheal intubation. *Sci Rep* 2018; 8: 17365.
34. Patil VV, Subramanya BH, Kiranchand N, Bhaskar SB, Dammur S. Does c-mac<sup>®</sup> video laryngoscope improve the nasotracheal intubating conditions compared to macintosh direct laryngoscope in paediatric patients posted for tonsillectomy surgeries? *Indian J Anaesth* 2016; 60: 732-6.
35. Goodine C, Sparrow K, Asselin M, Hung D, Hung O. The alignment approach to nasotracheal intubation. *Can J Anesth* 2016; 63: 991-2.
36. Kaddoum RN, Ahmed Z, D'Augsutine AA, Zestos MM. Guidelines for elective pediatric fiberoptic intubation. *J Vis Exp* 2011; 47: 2364.
37. Kinouchi K. Management of difficult pediatric airway. *Masui* 2006; 55: 24-32.
38. Kumar N, Mishra N, Ahmad S. Fiberoptic nasotracheal intubation using flexible neonatal bronchoscope in a pediatric patient with post-burn hypertrophic scar over the face. *Trends Anaesth Crit Care* 2022; 45: 52-4.
39. Oei J, Hari R, Butha T, Lui K. Facilitation of neonatal nasotracheal intubation with premedication: a randomized controlled trial. *J Paediatr Child Health* 2002; 38: 146-50.
40. Kim JS, Park SY, Min SK, Kim JH, Lee SY, Moon BK. Awake nasotracheal intubation using fiberoptic bronchoscope in a pediatric patient with freeman-sheldon syndrome. *Paediatr Anaesth* 2005; 15: 790-2.
41. Ozkan AS, Akbas S. Nasotracheal intubation in children for outpatient dental surgery: Is fiberoptic bronchoscopy useful? *Niger J Clin Pract* 2018; 21: 183-8.
42. Kwon MA, Song J, Kim S, Ji SM, Bae J. Inspection of the nasopharynx prior to fiberoptic-guided nasotracheal intubation reduces the risk epistaxis. *J Clin Anesth* 2016; 32: 7-11.
43. Lee JR. Updated review in pediatric airway management. *Anesth Pain Med* 2017; 12: 195-200.
44. Eck JB, De Lisle Dear G, Phillips-Bute BG, Ginsberg B. Prediction of tracheal tube size in children using multiple variables. *Paediatr Anaesth* 2002; 12: 495-8.
45. Shott SR. Down syndrome: analysis of airway size and a guide for appropriate intubation. *Laryngoscope* 2000; 110: 585-92.
46. Takita K, Morimoto Y, Okamura A, Kemmotsu O. Do age-based formulae predict the appropriate endotracheal tube sizes in japanese children? *J Anesth* 2001; 15: 145-8.
47. van den Berg AA, Mphanza T. Choice of tracheal tube size for children: finger size or age-related formula? *Anaesthesia* 1997; 52: 701-3.
48. Tsukamoto M, Yamanaka H, Yokoyama T. Predicting the appropriate size of the uncuffed nasotracheal tube for pediatric patients: a retrospective study. *Clin Oral Investig* 2019; 23: 493-5.
49. Chou CH, Tsai CL, Lin KL, Wu SC, Chiang MH, Huang HW, et al. A new formula to predict the size and insertion depth of cuffed nasotracheal tube in children receiving dental surgery: a retrospective study. *Sci Rep* 2023; 13: 12585.
50. Sugiyama K, Yokoyama K. Displacement of the endotracheal tube caused by change of head position in pediatric anesthesia: evaluation by fiberoptic bronchoscopy. *Anesth Analg* 1996; 82: 251-3.
51. Yamanaka H, Tsukamoto M, Hitosugi T, Yokoyama T. Changes in nasotracheal tube depth in response to head and neck movement in children. *Acta Anaesthesiol Scand* 2018; 62: 1383-8.
52. Davenport HT. *Paediatric anaesthesia*. 3rd ed. London, Heinemann Medical Books. 1980.
53. Yates AP, Harries AJ, Hatch DJ. Estimation of nasotracheal tube length in infants and children. *Br J Anaesth* 1987; 59: 524-6.
54. Steward DJ, Lerman J. *Manual of pediatric anesthesia*. 5th ed. London, Churchill Livingstone. 2001.
55. de la Sierra Antona M, López-Herce J, Rupérez M, García C, Garrido G. Estimation of the length of nasotracheal tube to be introduced in children. *J Pediatr* 2002; 140: 772-4.
56. Kim KO, Um WS, Kim CS. Comparative evaluation of methods for ensuring the correct position of the tracheal



- tube in children undergoing open heart surgery. *Anaesthesia* 2003; 58: 889-93.
57. Lau N, Playfor SD, Rashid A, Dhanarass M. New formulae for predicting tracheal tube length. *Paediatr Anaesth* 2006; 16: 1238-43.
  58. Kemper M, Dullenkopf A, Schmidt AR, Gerber A, Weiss M. Nasotracheal intubation depth in paediatric patients. *Br J Anaesth* 2014; 113: 840-6.
  59. Taghizadeh Imani A, Goudarzi M, Shababi N, Nooralishahi B, Mohseni A. Comparison of four formulas for nasotracheal tube length estimation in pediatric patients: an observational study. *Braz J Anesthesiol* 2023; 73: 584-8.
  60. Weiss M, Dullenkopf A, Fischer JE, Keller C, Gerber AC. Prospective randomized controlled multi-centre trial of cuffed or uncuffed endotracheal tubes in small children. *Br J Anaesth* 2009; 103: 867-73.
  61. O'Hanlon J, Harper KW. Epistaxis and nasotracheal intubation—prevention with vasoconstrictor spray. *Ir J Med Sci* 1994; 163: 58-60.
  62. Thrush DN. Cardiac arrest after oxymetazoline nasal spray. *J Clin Anesth* 1995; 7: 512-4.
  63. Kim EM, Chung MH, Lee MH, Choi EM, Jun IJ, Yun TH, et al. Is tube thermosoftening helpful for videolaryngoscope-guided nasotracheal intubation?: a randomized controlled trial. *Anesth Analg* 2019; 129: 812-8.
  64. Kim YC, Lee SH, Noh GJ, Cho SY, Yeom JH, Shin WJ, et al. Thermosoftening treatment of the nasotracheal tube before intubation can reduce epistaxis and nasal damage. *Anesth Analg* 2000; 91: 698-701.
  65. Watt S, Pickhardt D, Lerman J, Armstrong J, Creighton PR, Feldman L. Telescoping tracheal tubes into catheters minimizes epistaxis during nasotracheal intubation in children. *Anesthesiology* 2007; 106: 238-42.
  66. Tan YL, Wu ZH, Zhao BJ, Ni YH, Dong YC. For nasotracheal intubation, which nostril results in less epistaxis: right or left?: a systematic review and meta-analysis. *Eur J Anaesthesiol* 2021; 38: 1180-6.
  67. Earle R, Shanahan E, Vaghadia H, Sawka A, Tang R. Epistaxis during nasotracheal intubation: a randomized trial of the parker flex-tip™ nasal endotracheal tube with a posterior facing bevel versus a standard nasal rae endotracheal tube. *Can J Anaesth* 2017; 64: 370-5.
  68. Moore BM, Blumberg K, Laguna TA, Liu M, Zielinski EE, Kurachek SC. Incidental sinusitis in a pediatric intensive care unit. *Pediatr Crit Care Med* 2012; 13: e64-8.
  69. Willatts SM, Cochrane DF. Paranasal sinusitis: a complication of nasotracheal intubation: two case reports. *Br J Anaesth* 1985; 57: 1026-8.
  70. Michelson A, Kamp HD, Schuster B. Sinusitis in long-term intubated, intensive care patients: nasal versus oral intubation. *Anaesthesist* 1991; 40: 100-4.
  71. Bach A, Boehrer H, Schmidt H, Geiss HK. Nosocomial sinusitis in ventilated patients. Nasotracheal versus orotracheal intubation. *Anaesthesia* 1992; 47: 335-9.
  72. Zwillich C, Pierson DJ. Nasal necrosis: a common complication of nasotracheal intubation. *Chest* 1973; 64: 376-7.
  73. Huang TT, Tseng CE, Lee TM, Yeh JY, Lai YY. Preventing pressure sores of the nasal ala after nasotracheal tube intubation: from animal model to clinical application. *J Oral Maxillofac Surg* 2009; 67: 543-51.
  74. Yamamoto T, Flenner M, Schindler E. Complications associated with nasotracheal intubation and proposal of simple countermeasure. *Anesthesiol Intensive Ther* 2019; 51: 72-3.
  75. Chait DH, Poulton TJ. Case report: retropharyngeal perforation, a complication of nasotracheal intubation. *Nebr Med J* 1984; 69: 68-9.
  76. Landess WW. Retropharyngeal dissection: a rare complication of nasotracheal intubation revisited—a case report. *AANA J* 1994; 62: 273-7.
  77. Onçağ O, Cökmez B, Aydemir S, Balcioglu T. Investigation of bacteremia following nasotracheal intubation. *Paediatr Anaesth* 2005; 15: 194-8.
  78. Takahashi S, Minami K, Ogawa M, Miyamoto H, Ikemura K, Shigematsu A, et al. The preventive effects of mupirocin against nasotracheal intubation-related bacterial carriage. *Anesth Analg* 2003; 97: 222-5, table of contents.
  79. Talesh KT, Gargary RM, Arta SA, Yazdani J, Roshandel M, Ghanizadeh M, et al. Effect of 2% nasal mupirocin ointment on decreasing complications of nasotracheal intubation: a randomized controlled trial. *J Clin Diagn Res*

- 2017; 11: PC08-12.
80. Lockhart PB, Brennan MT, Kent ML, Norton HJ, Weinrib DA. Impact of amoxicillin prophylaxis on the incidence, nature, and duration of bacteremia in children after intubation and dental procedures. *Circulation* 2004; 109: 2878-84.