

Neurorehabilitation of saccadic ocular movement in a patient with a homonymous hemianopia postgeniculate caused by an arteriovenous malformation

A Case Report

Mirna Pineda-Ortíz, MSc^a, Gustavo Pacheco-López, PhD^a, Moisés Rubio-Osornio, PhD^b, Carmen Rubio, PhD^b, Juan Valadez-Rodríguez, MD^{b,*}

Abstract

Rationale: Visual therapy, which includes a restorative and compensatory approach, seems to be a viable treatment option for homonymous defects of the visual field in patients with postgeniculate injury of the visual pathway, due to occipital arteriovenous malformation (AVM). Until now, the Mexican population suffering from homonymous hemianopia did not have health services that provided any type of visual therapy for their condition.

Patient concerns: A 31-year-old patient, who underwent a surgical procedure for resection of the AVM, was referred with posterior low vision on the left side.

Diagnoses: The patient was diagnosed with left homonymous hemianopia.

Interventions: Visual neurorehabilitation therapy (NRT), which integrated restorative and compensatory approaches, was administered for 3 hours each week. NRT included fixation, follow-up, search, peripheral vision, and reading.

Outcomes: The NRT did not change visual field defects and, retinotopically, the same campimetric defects remained. However, after training the tracking ocular movements improved to standard values on the ENG, further, the visual search became more organized. The reading reached a level without mistakes, with rhythm and goog intonation. The Beck test demonstrated an improvement in depression symptoms. Regarding the daily life activities, the patient reported significant improvements.

Lessons: Visual NRT can significantly improve eye movements, as well as the quality of life and independence of the patient. This integral approach could be an effective therapeutic option for homonymous defects of the visual field.

Abbreviations: AVM = arteriovenous malformation, EEG = electroencephalogram, ENG = electronystagmography, HH = homonymous hemianopia, MRI = magnetic resonance imaging, NRT = neurorehabilitation therapy.

Keywords: arteriovenous malformation, homonymous hemianopia, visual field defect, visual rehabilitation

1. Introduction

Several etiologies, mainly of vascular origin, have been reported to cause visual field homonymous defects.^[1] In this regard, arteriovenous malformation (AVM), despite being a rare

vascular disease, has significant visual morbidity.^[2,3] Homonymous hemianopia (HH) is a campimetric defect that involves the loss of vision in the left or right contralateral hemi-field with injury to both eyes.^[4] This defect indicates retrochiasmatic visual pathway damage and produces complete or incomplete HH, depending on the site of injury.^[5] It is known that 40% of HH is produced by injury to the occipital lobe, 30% to the parietal lobe, 25% to the temporal lobe, and the rest due to injury to the lateral geniculate nucleus and optic tract.^[6] HH provokes several visual alterations, for example, reading deficit, altered visual examination, visual-spatial disorders, middle line deviation, and disorganized visual search.^[7-9] This condition also imposes a higher risk of falls and collisions, with a concomitant loss of independence, social isolation, and depression.^[10]

Currently, there are 2 rehabilitation approaches for the HH management as follows: compensatory therapy and vision restoration therapy. The first optimizes training of the performance through ocular saccadic movements improving the consciousness of the blind side, using visual search strategies. The second approach is based on the training and stimulation of the blind field, with practice detecting visual stimuli on the middle line of the damaged visual field, while waiting for changes in the cortical function.^[11] Since previous studies of visual rehabilitation therapy

Editor: Glays Ko.

The authors have no conflicts of interest to declare.

^a Health Sciences Department, Campus Lerma, Metropolitan Autonomous University (UAM), Lerma, Edo. Mex., ^b National Institute of Neurology and Neurosurgery "Manuel Velasco Suárez." Tlalpan, Mexico City, Mexico.

* Correspondence: Juan Valadez-Rodríguez, Instituto Nacional de Neurología y Neurocirugía "Manuel Velasco Suárez". Av. Insurgentes Sur No. 3877, Col. La Fama, Tlalpan, Mexico City, Mexico (e-mail: valadezjr25@gmail.com).

Copyright © 2018 the Author(s). Published by Wolters Kluwer Health, Inc. This is an open access article distributed under the terms of the Creative Commons Attribution-Non Commercial-No Derivatives License 4.0 (CCBY-NC-ND), where it is permissible to download and share the work provided it is properly cited. The work cannot be changed in any way or used commercially without permission from the journal.

Medicine (2018) 97:11(e9890)

Received: 3 September 2017 / Received in final form: 7 December 2017 /

Accepted: 24 January 2018

<http://dx.doi.org/10.1097/MD.0000000000009890>

for HH have focused on the effects of 1 of these 2 types of therapies (restorative or compensatory), the present innovative study provided an integrative therapy, which included both therapeutic approaches. In addition, neuropsychological therapy was also implemented. Overall, cortical neuroplasticity and compensatory changes were expected following this integrative therapy.

2. Case description

A 31-year-old female undergraduate student, of Mexican nationality, with previous seizures in the visual area (since she was 15 years old), arrived at National Institute of Neurology and Neurosurgery (INNN)-emergency, Mexico City, 9 days after a minor automobile accident. She presented headache, left hemianopia, and paresthesia. An magnetic resonance imaging (MRI) head scan detected a vascular anomaly (Fig. 1A) and panangiography confirmed a right occipital AVM (Fig. 1B). Successful

neurosurgery for uncomplicated AVM resection was performed. However, 5 days after surgery the patient was referred for blurred vision. A Goldmann perimetry test revealed a macular consequence of an injury in the right occipital calcarine area. Electroencephalogram (EEG) showed poor expression in the right back side of the temporal epileptiform activity. There was also asymmetry and regional asynchrony due to intermittent delay, and a bigger voltage on the right occipital region. EEG results indicated a decrease of the regional epileptic threshold and a pattern of structural injury on the occipital side. Neuropsychiatry assessment using the Beck Depression Inventory determined a moderate depression. Electronystagmography (ENG) revealed altered ocular movements at 30°, in persecution with 0.1 and 0.2 Hz. The alteration of those movements was evident at 0.4 Hz, when the patient looked to the left side. Some of the visual impairments that the patient presented with prior (t1) to neurorehabilitation therapy (NRT) were as follows: reading

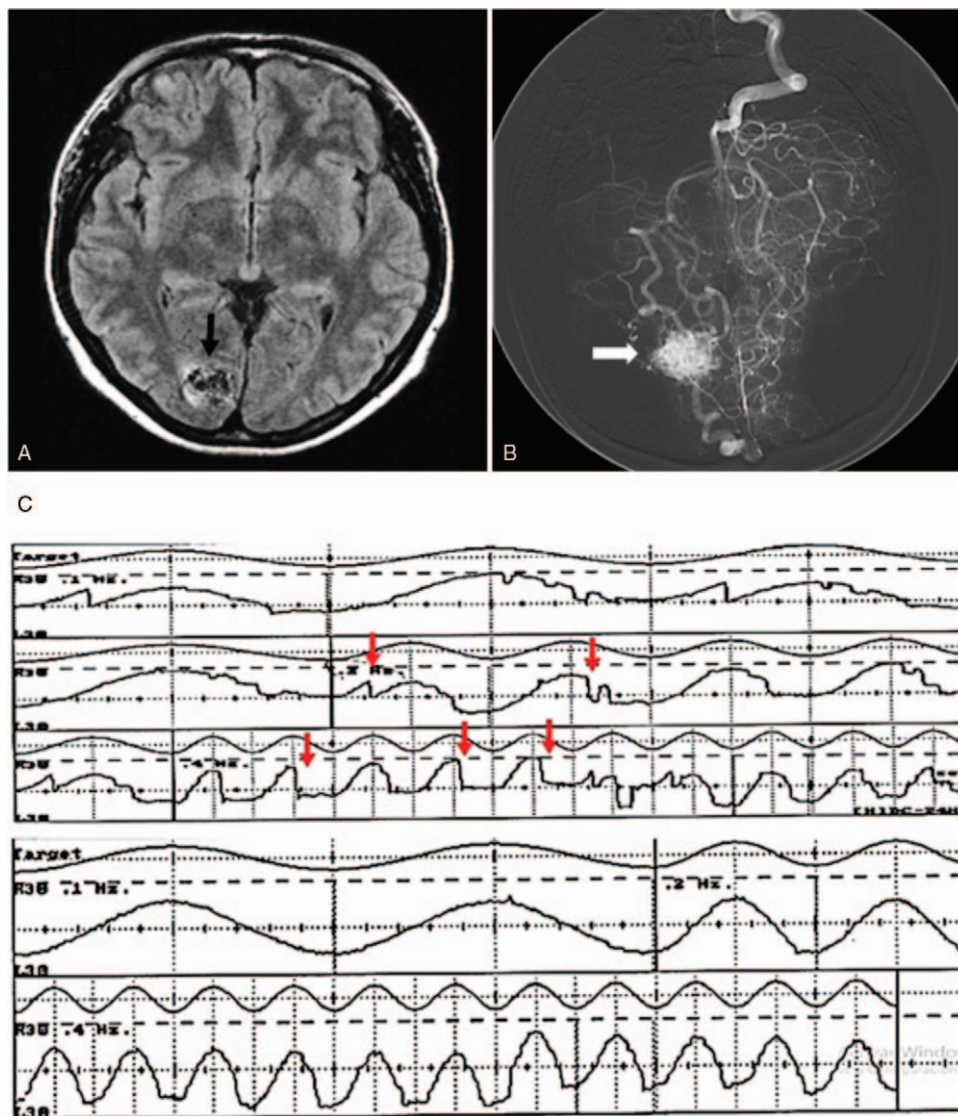


Figure 1. A. Axial cranial magnetic resonance imaging (MRI) detected abnormal arteriovenous malformation (AVM) in the right hemisphere-occipital lobe (black arrow). B. Cerebral panangiography confirmed occipital AVM, (white arrow). C. Electronystagmography (ENG) prior to neurorehabilitation therapy (NRT) (t1), upper panel, shows series of altered saccadic eye movements with loss of leftward tracking (red arrow). ENG post-NRT (t3), lower panel, depicts standardized ocular movement very similar to the target stimuli.

Table 1

Integrative neurorehabilitation therapy (NRT), tasks, and procedures. All therapies were performed at the following time-points: t1, t2, and t3 (see text).

Therapy	Task	Details
Search therapy (ST)	Task 1 (search 3s)	Objective: To locate a different stimulus between 5 equals, the time of occurrence between stimuli was 3 s, the appearance of the stimulus was more frequently towards the injured hemispace. Therapy duration was 10 min divided in 2 times.
	Task 2 (advanced search)	Objective: To locate a different stimulus among 40 distractors, the appearance of the stimulus was more frequently towards the side of the injured hemispace. Duration of therapy, 10 min divided in 2 times.
	Task 3 (inverted triangle)	Objective: To locate an inverted stimulus between the distractors, the time of occurrence between stimuli was 3 s. Duration of therapy 5 min.
Peripheral vision therapy (PVT)	Task 4 (peripheral vision therapy)	Objective: To observe a red dot in the center of the screen, without stopping to see the maximum of stimuli around this, making use of the peripheral vision. Duration 5 min.
Reading therapy (RT)	Task 5 (reading test I)	Objective: To carry out a reading exercise in reading cards with separate lines at 3 points. This therapy simulates the ocular movement that is performed during the reading as well as the line change. Duration: the time the patient takes.
	Task 6 (reading test II)	Objective: To carry out a reading exercise in reading cards with separate lines at 2.5 points. This therapy simulates the ocular movement that is performed during the reading as well as the line change. Duration: the time the patient takes.
	Task 7 (reading test III)	Objective: To carry out a reading exercise in reading cards with separate lines at 2 points. This therapy simulates the ocular movement that is performed during the reading as well as the line change. Duration: the time the patient takes.
	Task 8 (reading test IV)	Objective: To carry out a reading exercise in reading cards with separate lines at 1.5 points. This therapy simulates the ocular movement that is performed during the reading as well as the line change. Duration: the time the patient takes.
	Task 9 (appearance of low level word)	Objective: Read the letters that appear on the screen every 3 s. Duration: 5 min.
	Task 10 (appearance of medium level word)	Objective: Read the letters that appear on the screen every 1 s. Duration: 5 min.

alterations, confusion of similar numbers, longer search time, disorganized exploration, and continuous loss of moving objects. In addition, she reported collision and frequent falls, which sometimes increased anxiety when observing various stimuli at the same time, whether on television, a computer, or during daily domestic activities. After the AVM neurosurgery, the patient self-restricted to her home, and was dependent on relatives or caretakers.

2.1. Assessment

2.1.1. Neurorehabilitation therapy. A total of 3 hours of visual NRT were administered each week, which included fastening, tracking, searching, periphery vision, and a reading task. The therapy focused on showing stimuli on a wall-screen with the help of a personal computer and video-projector. Table 1 outlines the NRT details. The first part of NRT was performed in 3 months (t1), immediately followed by the second part that lasted another 3 months (t2). The third and last part was administered 12 months after t1 starting point, for an additional 3 months (t3). The INNN-Ethics Committee approved the current study (Protocol No. 96/14) and the patient provided written informed consent.

3. Results

The NRT did not change visual field defects (t1 vs t3) and, retinotopically, the same campimetric defect remained. However, after t3 the tracking ocular movements improved to standard values on the ENG (Fig. 1C). Further, the visual search became more organized since a higher number of visual stimuli were accepted. The average number of mistakes for NRT-task 1 for t1 and t3 were comparable. In NRT-task 2, the average number of mistakes for t1 was 16 mistakes, while it was 3.6 mistakes for t3, with a greater number of stimuli. For the NRT-task 3 the patient

obtained an average score of 40.5 and 19.7 mistakes at t1 and t3, respectively. The results obtained for NRT-task 2 and task 3 demonstrated the significant improvement in the location of the stimuli between t1 versus t3. The differences in the average number of mistakes for NRT-task 2 and task 3 were found for 75 and 100 stimuli, respectively, which demonstrated the decreasing error rate in both tasks. In terms of peripheral vision training, the patient correctly placed a greater number of visual stimuli towards the midline of the blind side after NRT, obtaining an average score of 10 mistakes in t1, and 5.8 mistakes at t3, with a total of 14 stimuli. These results indicated greater location of stimuli with the use of peripheral vision. Reading reached a level without mistakes, with rhythm and good intonation. Additionally, the Beck Depression Inventory demonstrated a score of 28 points pre-NRT (t1), and 12 points at post-NRT (t3), indicating an improvement in depression symptoms. Regarding the daily life activities, the patient reported significant independence improvements, and was able to cook, go on strolls, enroll in a course, and start a hobby/business.

4. Discussion

Due to its location, occipital AVM can cause visual deficiencies.^[12] In addition, the majority of patients with AVM initially have intracranial hemorrhage, seizure symptoms, headaches, short falls, or even progressive neurological deficits.^[13] It is imperative to recognize symptoms that distinguish the presence of an AVM from other disorders, since this will ease its diagnosis and treatment. Thus, transcendental neuroimaging, neurophysiology, neuro-ophthalmology, neuropsychology, and neuropsychiatry assessments prior to treatment aim to achieve a correct diagnosis and design an effective treatment for each patient. Personalized therapy may promote a better response and treatment adherence.

In Mexico, visual NRT for campimetric defects is uncommon because there are no health institutions with experience that are dedicated to it. Studies in developed countries have focused on administering therapies to patients with HH due to different etiologies, most of which report that restorative therapy is less reliable than compensatory therapy.^[14] A few studies, however, focused on restorative therapy increasing the visual field of patients.^[15–17] Previous studies demonstrated that the treatment choice affects the outcome in terms of visual recovery, as well as the patient's improvement. To date, there have been no studies in Mexico on the treatment of visual field defects. Further, there is no evidence that integrative NRT offers both therapeutic approaches in parallel with neuropsychological treatment. The purpose of this research was to test an integrative visual NRT in a patient with a campimetric defect, using residual vision and the implementation of compensatory strategies, with an aim to improve the patient's quality of life. The result of this case study was positive and promising. The patient achieved better visual frontal scanning, had decreased searching time, accurate identified objects, and obtained better and more organized reading and visual exploration. Overall, this improved the patient's quality of life and independence.

Nevertheless, it must be noted that this single case cannot be used as sole evidence for the effect of NRT because several other factors, such as age, genetics, duration of injury, mood, or socioeconomic level, could have also interacted. Thus, a randomized clinical trial is warranted as a follow-up. Moreover, there are few studies on the treatment of campimetric defects performed in homogeneous populations, in terms of etiology.^[18–20] This highlights the need for more visual rehabilitation studies in different etiologies to analyze the response to particular therapeutic strategies, with an aim of developing effective and personalized NRT in the near future.

5. Conclusion

This case study is the first to report the use of integrative NRT treatment in Mexico, designed with 2 approaches of visual rehabilitation (restorative and compensatory therapy), in which positive and encouraging functional results were obtained. This suggested that this treatment approach could be a viable option for the treatment of HH generated by occipital AVM.

Acknowledgments

M. Pineda-Ortíz performs graduate studies at UAM, Biological and Health Sciences Doctorate Program (2143806993).

CONACYT supported M. Pineda-Ortíz with a scholarship (CVU-330694). Y. Sánchez-Jiménez, I. González-Olhovich, J. Morales-Camacho, J.J. Reyes-Lagos, D.L. Sifuentes-Becerril, and M. Pérez-Rosas contributed to this research.

References

- [1] Gold DR, Grover LL. Treatment of homonymous visual field defects. *Curr Treat Options Neurol* 2012;14:73–83.
- [2] Ajiroye N, Chalouhi N, Starke RM, et al. Cerebral arteriovenous malformations: evaluation and management. *Scientific World J* 2014; 2014:649036.
- [3] Gutteridge IF, McDonald RA. Hemianopic visual field loss as the first clinical evidence of occipital arteriovenous malformation. *Clin Exp Optom* 2004;87:394–9.
- [4] Goodwin D. Homonymous hemianopia: challenges and solutions. *Clin Ophthalmol* 2014;8:1919–27.
- [5] Kedar S, Zhang X, Lynn MJ, et al. Congruency in homonymous hemianopia. *Am J Ophthalmol* 2007;143:772–80.
- [6] Pambakian AL, Kennard C. Can visual function be restored in patients with homonymous hemianopia? *Br J Ophthalmol* 1997;81:324–8.
- [7] Kerkhoff G. Restorative and compensatory therapy approaches in cerebral blindness a review. *Restor Neurol Neurosci* 1999;15:255–71.
- [8] Kerkhoff G. Neurovisual rehabilitation: recent developments and future directions. *J Neurol Neurosurg Psychiatry* 2000;68:691–706.
- [9] Mueller I, Poggel DA, Kenkel S, et al. Vision restoration therapy after brain damage: subjective improvements of activities of daily life and their relationship to visual field enlargements. *Vis Impair Res* 2003;5:157–78.
- [10] Rowe FJ, Wright D, Brand D, et al. A prospective profile of visual field loss following stroke: prevalence, type, rehabilitation, and outcome. *Bio Med Res Int* 2013;2013:719096.
- [11] Luu S, Lee AW, Daly A, et al. Visual field defects after stroke—a practical guide for GPs. *Aust Fam Physician* 2010;39:499–503.
- [12] Kupersmith MJ, Vargas ME, Yashar A, et al. Occipital arteriovenous malformations: visual disturbances and presentation. *Neurology* 1996; 46:953–7.
- [13] Chen JS, Ilsen PF. Parieto-occipital arteriovenous malformation. *Optometry* 2002;73:477–91.
- [14] Raz N, Levin N. Neuro-visual rehabilitation. *J Neurol* 2017;264: 1051–8.
- [15] Bouwmeester L, Heutink J, Lucas C. The effect of visual training for patients with visual field defects due to brain damage: a systematic review. *J Neurol Neurosurg Psychiatry* 2007;78:555–64.
- [16] Plow EB, Maguire S, Obretenova S, et al. Approaches to rehabilitation for visual field defects following brain lesions. *Expert Rev Med Devices* 2009;6:291–305.
- [17] Romano JG, Schulz P, Kenkel S, et al. Visual field changes after a rehabilitation intervention: vision restoration therapy. *J Neurol Sci* 2008;273:70–4.
- [18] Julkunen L, Tenovuo O, Jaaskelainen S, et al. Computer-assisted training: a clinical and neurophysiological study. *Restor Neurol Neurosci* 2000;21:19–28.
- [19] Balliet R, Blood KM, Bach-y-Rita P. Visual field rehabilitation in the cortically blind? *J Neurol Neurosurg Psychiatry* 1985;48:1113–24.
- [20] Zihl J. Eye movement patterns in hemianopic dislexia. *Brain* 1995; 118:891–912.