

## Robotic mitral replacement for a degenerated valve-in-valve transcatheter mitral prosthesis



Makoto Hibino, MD, Amalia A. Jonsson, MD, Michael E. Halkos, MD, and Douglas A. Murphy, MD, Atlanta, Ga

From the Division of Cardiothoracic Surgery, Department of Surgery, Emory Saint Joseph's Hospital, Emory University School of Medicine, Atlanta, Ga.

Disclosures: Dr Murphy is a speaker for Intuitive Surgical. All other authors reported no conflicts of interest. The *Journal* policy requires editors and reviewers to disclose conflicts of interest and to decline handling or reviewing manuscripts for which they have a conflict of interest. The editors and reviewers of this article have no conflicts of interest.

Read at *The American Association for Thoracic Surgery Mitral Conclave Workshop, New York, New York, May 4-5, 2023.*

Received for publication Feb 15, 2023; revisions received April 26, 2023; accepted for publication May 1, 2023; available ahead of print May 25, 2023.

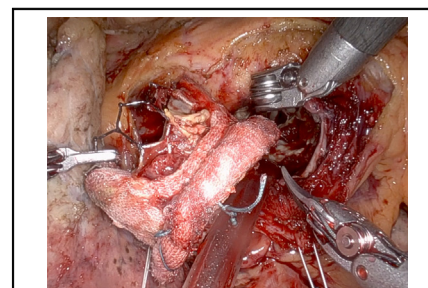
Address for reprints: Douglas A. Murphy, MD, Division of Cardiothoracic Surgery, Department of Surgery, Emory Saint Joseph's Hospital, Emory University School of Medicine, 5665 Peachtree Dunwoody Rd, Suite 200, Atlanta, GA 30342 (E-mail: [douglas.murphy@emory.edu](mailto:douglas.murphy@emory.edu)).

JTCVS Techniques 2023;21:83-5

2666-2507

Copyright © 2023 The Authors. Published by Elsevier Inc. on behalf of The American Association for Thoracic Surgery. This is an open access article under the CC BY-NC-ND license (<http://creativecommons.org/licenses/by-nc-nd/4.0/>).

<https://doi.org/10.1016/j.jtc.2023.05.001>



Valve-in-valve TMVR prosthesis was removed en bloc.

### CENTRAL MESSAGE

Robotic approach allowed for optimal visualization with effective manipulation while minimizing invasiveness by avoiding fourth re-sternotomy for replacement of valve-in-valve TMVR prosthesis.

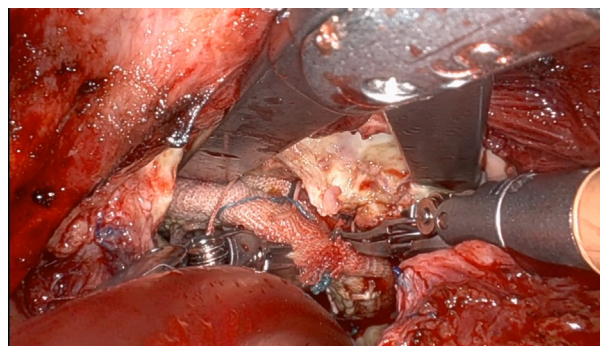
▶ Video clip is available online.

We have utilized a lateral endoscopic approach with robotics (LEAR) to perform mitral valve surgery in patients with previous sternotomy and demonstrated the safe and effective use of LEAR technique in this high-risk population.<sup>1</sup> For patients undergoing redo operation with isolated mitral and/or tricuspid valve disease, contraindications to this LEAR approach are very few; these include dense right pleural adhesions and severe peripheral atherosclerosis that prohibits peripheral cannulation for cardiopulmonary bypass. Transcatheter mitral valve replacement (TMVR) has been primarily used for valve-in-valve implantation, with 2 additional uses: valve-in-ring and valve-in-mitral annular calcification.<sup>2</sup> Although the number of TMVR procedures has steadily increased over the past decade, there is a paucity of reports on the explantation of TMVR prostheses. In this report, we describe our clinical experience and technical details of a fourth-time redo mitral valve replacement with LEAR technique, including the explantation of a degenerated valve-in-valve TMVR prosthesis.

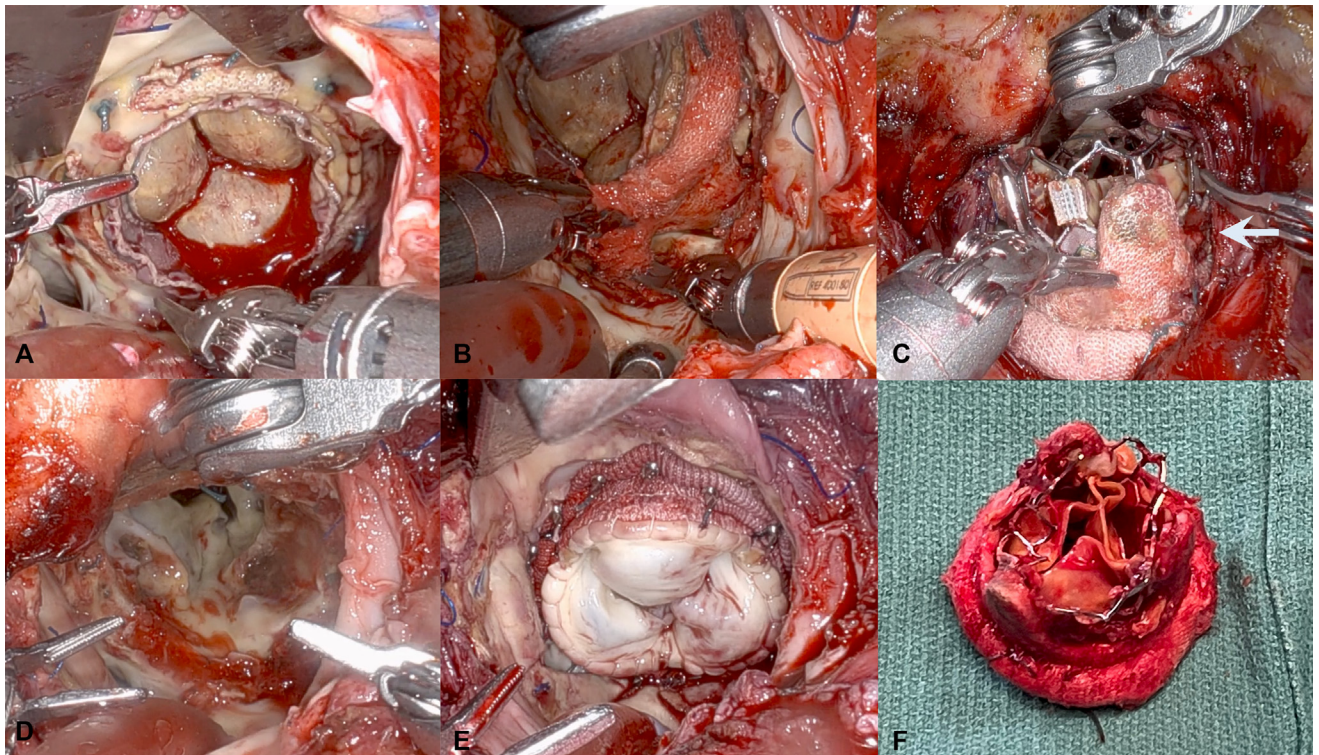
### CASE PRESENTATION

A 69-year-old man with history of 3-time mitral valve replacement developed severe regurgitation 12 years after the third replacement with a 31 mm Mosaic (Medtronic)

valve and underwent TMVR with a 29-mm Sapien 3 (Edwards Lifesciences) valve at an outside hospital 5 years ago. This time, he developed symptomatic severe prosthetic mitral stenosis (mean pressure gradient, 16 mm Hg) with left ventricular outflow tract obstruction (mean pressure gradient, 16 mm Hg and peak pressure gradient, 31 mm Hg) related to the projection of the prosthetic mitral valve



**VIDEO 1.** Robotic approach for fourth redo mitral replacement following valve-in-valve transcatheter mitral valve replacement. Video available at: [https://www.jtcvs.org/article/S2666-2507\(23\)00144-X/fulltext](https://www.jtcvs.org/article/S2666-2507(23)00144-X/fulltext).




**FIGURE 1.** A, Intraoperative view showing the transcatheter mitral valve replacement (TMVR) prosthesis inside the previous tissue valve. B, The previous tissue valve was dissected from the mitral annulus using robotic scissors. C, The TMVR prosthesis within the previous tissue valve was removed en bloc. An arrow points to thrombi present under the original Mosaic valve (Medtronic), adjacent to the TMVR prosthesis. D, The mitral annulus tissue was preserved after the residual pannus tissue was debrided. E, A new tissue valve was implanted. F, The explanted valves. The metal frame of Sapien 3 (Edwards Lifesciences) was deformed when it went through the service port.

struts (Video 1) as well as pulmonary hypertension (mean pulmonary pressure, 39 mm Hg and pulmonary artery wedge pressure, 33 mm Hg). Although there was no perivalvular leakage detected between the 2 prosthetic valves, there was evidence of paravalvular leakage between the tissue valve and the native annulus, specifically from the 3 o'clock to 7 o'clock position. The patient had an ejection fraction of 65% and mild to moderate tricuspid regurgitation. Therefore, the patient was referred for elective surgical mitral valve treatment. This study was approved by the institutional review board (IRB No. 00073906; April 21, 2014). Written informed consent for publication of study data was obtained from the patient.

### SURGICAL TECHNIQUE

We decided to employ a robotic approach (DaVinci Robot Xi; Intuitive Surgical Inc). The patient was positioned in the right hemi-ecubitus position, and before obtaining vascular access, we confirmed that there was no dense adhesion in the right chest wall. We established cardiopulmonary bypass by cannulating the left femoral vein and anastomosing an 8-mm polyethylene terephthalate graft to the right axillary artery. We exposed the left atrium by dissecting adhesions from previous operations with an

electrocautery spatula (Video 1). Under aortic occlusion using an IntraClude intra-aortic occlusion device (Edwards Lifesciences), we opened the left atrium. The previous tissue valve, along with the TMVR prosthesis, was separated from the native mitral annulus using curved scissors and removed en bloc through a right lateral minithoracotomy incision in the fourth intercostal space (Video 1 and Figure 1, A-C). The TMVR prosthesis was located within the tissue valve and had limited adhesion with the native mitral annular structure. There were thrombi present under the original Mosaic valve, adjacent to the TMVR prosthesis (Figure 1, C). After meticulously removing old suture material and debris from the intracardiac space using customized suction device,<sup>1</sup> we successfully implanted a 31-mm Epic tissue valve (St Jude Medical) without the need for annular repair (Figure 1, D and E). The valve was secured in place using pledged-enforced vertical mattress stitches, which were organized with 2 units of suture guides attached to the right-side drape (Figure 2). The porcine prosthesis was prepared with a custom cinch suture after removing its holder, and passed through the minithoracotomy incision without spreading the ribs. The stitches were tied with Cor-knot surgical tying device (LSI Solutions). Echocardiography showed no paravalvular leakage, no left ventricular



**FIGURE 2.** Our standard port placements in a lateral endoscopic approach with robotics technique. Valve replacement stitches were organized with 2 units of suture guides attached to the right-side drape.

outflow tract obstruction, and mean mitral pressure gradient of 4 mm Hg. The patient recovered well, and he was discharged home on the eighth day after surgery.

## CONCLUSIONS

The endoscopic robotic approach allowed for optimal visualization and effective operative manipulation while also minimizing invasiveness by avoiding a fourth re sternotomy.

Thrombus formation between 2 prostheses may warrant further investigation into its clinical significance.

## References

1. Murphy DA, Jonsson AA, Halkos ME. Endoscopic robotic mitral valve surgery in patients with previous sternotomy cardiac surgery. *Innovations*. 2022;17:297-303.
2. Mack M, Carroll JD, Thourani V, Vemulapalli S, Squiers J, Manandhar P, et al. Transcatheter mitral valve therapy in the United States: a report from the STS-ACC TVT Registry. *J Am Coll Cardiol*. 2021;78:2326-53.