

## Case Report

# Stereotactic Mesencephalotomy for Cancer - Related Facial Pain

Deok-ryeong Kim, M.D.,<sup>1</sup> Sang-won Lee, M.D., Ph.D.,<sup>2</sup> Byung-chul Son, M.D., Ph.D.<sup>3,4</sup>

*Department of Neurosurgery,<sup>1</sup> Eulji General Hospital, College of Medicine, Eulji University, Seoul, Korea*

*Department of Neurosurgery,<sup>2</sup> St. Vincent's Hospital, College of Medicine, The Catholic University of Korea, Seoul, Korea*

*Department of Neurosurgery,<sup>3</sup> Seoul St. Mary's Hospital, College of Medicine, The Catholic University of Korea, Seoul, Korea*

*Catholic Neuroscience Institute,<sup>4</sup> College of Medicine, The Catholic University of Korea, Seoul, Korea*

Cancer-related facial pain refractory to pharmacologic management or nondestructive means is a major indication for destructive pain surgery. Stereotactic mesencephalotomy can be a valuable procedure in the management of cancer pain involving the upper extremities or the face, with the assistance of magnetic resonance imaging (MRI) and electrophysiologic mapping. A 72-year-old man presented with a 3-year history of intractable left-sided facial pain. When pharmacologic and nondestructive measures failed to provide pain alleviation, he was reexamined and diagnosed with inoperable hard palate cancer with intracranial extension. During the concurrent chemoradiation treatment, his cancer-related facial pain was aggravated and became medically intractable. After careful consideration, MRI-based stereotactic mesencephalotomy was performed at a point 5 mm behind the posterior commissure, 6 mm lateral to and 5 mm below the intercommissural plane using a 2-mm electrode, with the temperature of the electrode raised to 80°C for 60 seconds. Up until now, the pain has been relatively well-controlled by intermittent intraventricular morphine injection and oral opioids, with the pain level remaining at visual analogue scale 4 or 5. Stereotactic mesencephalotomy with the use of high-resolution MRI and electrophysiologic localization is a valuable procedure in patients with cancer-related facial pain.

**Key Words :** Mesencephalotomy · Facial pain · Magnetic resonance imaging.

## INTRODUCTION

Cancer-related facial pain accounts for approximately 1–13% of patients with clinical trigeminal neuralgia symptoms<sup>4,16</sup>. Direct tumorous invasion of the trigeminal nerve or tumors in close proximity to the trigeminal nerve can cause facial pain similar to the pain experienced by patients with trigeminal neuralgia<sup>4</sup>. It can be associated with shock-like pains which are abrupt in onset and termination, and limited to certain distributions of the trigeminal nerve<sup>11</sup>. The frequency and intensity of the pain increase with the progressive growth of the intracranial lesions and with more severe nerve compression. What is worse, most cases of this type of cancer pain are refractory to medication and respond only to surgical measures. Surgical resection has been reported as a modality for pain relief<sup>13</sup>; however, some patients are not candidates for surgery due to medi-

cal comorbidities or prohibitive tumor characteristics<sup>4,13,16</sup>. In such cases, pain surgery becomes necessary for symptomatic relief as an alternative mode of management.

Since the primary pain pathway has been ascertained to be the spinothalamic tract in the spinal level<sup>28</sup> for the body and the trigeminothalamic tract above the spinal cord level for the face, head and neck, various surgical procedures have been performed and ablative procedures still have a role to play in the treatment of cancer pain<sup>20</sup>. Anterolateral cordotomy has been used more often than any other procedure for pain management. However, if the pain occurs in the upper extremities, upper body, or even in the face, it becomes necessary to interrupt the primary pain pathway at a level above the spinal cord. Stereotactic ablation of the thalamic sensory nucleus is widely practiced but this does not provide consistent results and neurosurgeons still require definite solutions to overcome unknown aspects<sup>17,20</sup>. Interruption of the

• Received : November 26, 2013 • Revised : March 29, 2014 • Accepted : July 15, 2014

• Address for reprints : Byung-chul Son, M.D., Ph.D.

Department of Neurosurgery, Seoul St. Mary's Hospital, Catholic Neuroscience Institute, College of Medicine, The Catholic University of Korea, 222 Banpo-daero, Seocho-gu, Seoul 137-701, Korea

Tel : +82-2-2258-6122, Fax : +82-2-594-4248, E-mail : sbc@catholic.ac.kr

• This is an Open Access article distributed under the terms of the Creative Commons Attribution Non-Commercial License (<http://creativecommons.org/licenses/by-nc/3.0>) which permits unrestricted non-commercial use, distribution, and reproduction in any medium, provided the original work is properly cited.

limbic pathways, particularly the cingulate gyrus, reduces the associated suffering but does not abolish pain perception<sup>18,30</sup>. Stereotactic mesencephalotomy and pontine tractotomy target the primary pain pathway in the brainstem. There are clearly advantages and disadvantages between the two surgical approaches for obtaining high analgesic levels. The former has a little shorter trajectory toward the target and the outcome is good in terms of pain control<sup>20</sup>. Moreover, recent magnetic resonance image (MRI)-based electrophysiologic localization techniques can minimize the occurrence of any associated complications such as oculomotor disorders or injury to the reticular formation. That is why the mesencephalotomy procedure targeting the spinothalamic and trigeminothalamic pathways in the mid-brain level is frequently performed.

The author reports a case of successful management using stereotactic mesencephalotomy for a patient with facial cancer-related trigeminal pain, without any complications and, as far as we know, this is the first case documented domestically.

### CASE REPORT

A 72-year-old man presented with a 3-year history of intractable left-sided facial pain. His pain was characterized by stabbing, burning, and dysesthesia, and involved the V1, V2, and V3 distributions of the trigeminal nerve. In the early stage, he was misdiagnosed with trigeminal neuralgia and underwent Gamma knife radiosurgery at an outside hospital. When the procedure and pharmacologic measures failed to provide pain alleviation, He was reexamined with paranasal sinus MRI and his diagnosis was confirmed with a biopsy of the nose and neck. At that time, his final diagnosis was inoperable hard palate cancer with intracranial extension, stage IVB (T4bN1M0). Since then, he has received concurrent chemoradiation therapy as another treatment option. During the treatment, his cancer-related facial pain became aggravated and refractory to the maximum dose of opioids including oxycotin, durosic patches, and so forth. He was then referred to the neurosurgery department for surgical treatment of the intractable pain.

When we checked his neurologic status, left hemifacial pain corresponding to a visual analogue scale (VAS) score of 9 combined with mild hypoesthesia (decreased to 80 percent compared with the right side) and left masseter muscle atrophy with

decreased mastication were identified. After careful consideration of the factors, including the factors involved in multiple clinical disciplines, the surgical option of a mesencephalotomy was discussed with the patient and his caregivers and they decided to proceed with it as a last resort due to the severity of his symptoms and the refractoriness to medical treatment.

On the morning of the operation, the patient's head was fixed parallel to the line between the infraorbital margin and the upper margin of the external auditory meatus in a Leksell stereotactic frame (Elekta Instruments, Atlanta, GA, USA), and coronal and axial T2-weighted MRI images were then obtained. The surgical target based on the MR image was chosen 5 mm behind the posterior commissure, 6 mm lateral to, and 5 mm below the intercommissural plane (Fig. 1). An MR navigation system (Stryker Instrument, Freiburg, DEU) was used to define the appropriate trajectory. The surgery was carried out under local anesthesia. When the underlying dura and pia were opened with bipolar cautery, three straight microelectrodes (FHC Inc., Bowdoin, ME, USA) were inserted into the center, 2 mm medial, and 2 mm lateral to the target, for electrophysiologic mapping. After stimulation with the electrode, typical tingling and a warm sensation in the left upper arm and face were noted in the center tract (6 mm lateral to the right of the midline). After confirming the final target based on the electrophysiologic mapping findings, a lesion was made using a 2 mm diameter tip monopolar straight electrode with a 4 mm uninsulated length (Leibinger GmbH, Freiburg, Germany) and raising the temperature of the electrode to 80°C for 60 seconds. And the lesion was increased in length by 2 mm by moving the electrode along the dorsolateral direction and by repeating the heating (Fig. 2). At the end of the operation, a navigation-guided Ommaya reservoir was inserted for intraventricular injection of morphine to aid in the control of the remaining cancer pain. The patient remained stable throughout the procedure.

On the first day after the operation, the left hemifacial pain had dramatically improved according to the VAS score, which dropped from 9 to 1, and the hypoesthesia on the left face showed a noticeable decrease of 50 percent compared with the right side. Besides, there was no evidence of any new gaze paresis or left-sided extremity dysesthesia. However, the pain slightly recurred with a VAS score of 3 a week after the surgery and the pain progressively increased, with the VAS increasing to 5 at postopera-

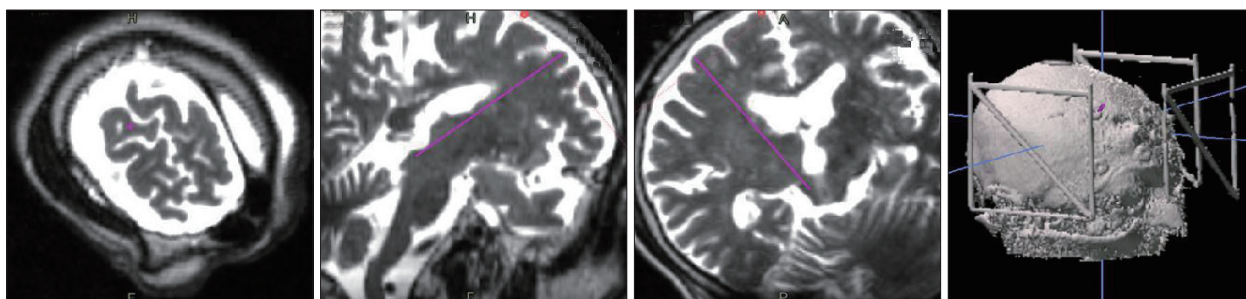


Fig. 1. Preoperative planning images showing the anatomical target and the appropriate trajectory.

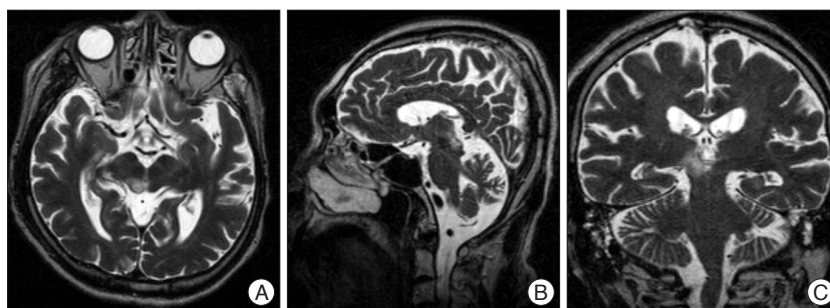
tive two months. Until a recent date, the pain has been relatively well controlled, staying at VAS 4 or 5, by intermittent intraventricular morphine injections and oral opioids; also, there have been no neurologic deficits detected.

## DISCUSSION

Stereotactic mesencephalotomy was initially introduced by Spiegel and Wy-cis in 1947<sup>6</sup>. They reported pain relief that lasted for at least 18 years for facial dysesthesia<sup>27</sup>. Since then, various authors have developed this technique, making some minor revisions involving changes in the approaches or anatomical targets, for relieving medically refractory pain<sup>1,7,12,14</sup>. Different and more accurate approaches through the posterior parietal lobe or an anterior frontal approach and a more medially placed target or a more laterally positioned lesion have been attempted and they have shown good results, with significantly reduced morbidities. The integrated data show that the anatomical target points of several authors were 5 mm behind the posterior commissure, 5–10 mm lateral to, and 5 mm below the intercommissural plane<sup>15,21,22,24,28</sup>.

The original stereotactic target was the lateral spinothalamic and trigeminothalamic tracts, avoiding the medial lemniscus. In some later procedures, several authors included a lesion in the dorsomedial nucleus of the thalamus in order to interrupt its connections to the pre-frontal area. Their rationale was that interrupting the spinothalamic lesion treated the pain transmission, but the dorsomedial lesion helped the “suffering” component of the intractable pain, which is projected via the spinoreticular system to limbic structures<sup>26</sup>. In 1954, Spiegel et al.<sup>24,25</sup> demonstrated that pain was transmitted via the spinoreticular pathways, which had been recognized as being involved with pain transmission. They advocated that the mesencephalotomy lesion extend medially to include spinoreticular areas, especially in patients with a strong emotional component to the chronic pain syndrome<sup>31</sup>. In accordance with the previous work, Shieff and Nashold<sup>22,23</sup> demonstrated that chronic pain is invariably associated with emotional distress and the interruption of the extralemniscal pathway alleviated the emotional aspect of the pain. Consequently, if psychological generation of the suffering accounts for a considerable portion of the pain syndrome, the patient may benefit from the interruption of the spinoreticulothalamic pathways as part of the management of the suffering of the patient<sup>14</sup>. However, in the case reported here, we did not consider spinoreticular lesion involvement because the suffering was not a significant part of his cancer pain and he was not indicated to receive psychotropic medication or counseling.

Various postoperative disturbances can happen despite the accuracy of modern MRI-guided stereotactic targeting, which has an accuracy within 1 mm, as recently described<sup>3</sup>. Several



**Fig. 2.** Post-operative axial (A), sagittal (B) and coronal (C) magnetic resonance imaging slices showing the location of the lesion of the stereotactic mesencephalotomy.

authors demonstrated that dysesthesia correlated with damage to the medial lemniscus<sup>5,8</sup>. In 1969, Nashold et al.<sup>15</sup> verified that high-frequency stimulation in the central grey area medial to the spinothalamic tract produced unpleasant sensations involving the midline structures, as well as a strong negative or fearful emotional outburst. Significantly disabling ocular mobility could be produced by defined encroachment on the emerging oculomotor fibers. Shieff and Nashold<sup>22,23</sup> as well as Amano<sup>2</sup> recommended a target at the level of the inferior colliculus, 5 mm below the intercommissural plane, to avoid that complication. Gybels and Sweet<sup>10</sup> reported that oculomotor dysfunction was seen in 13–20% of patients, even with intraoperative stimulation control and directing the lesion to the safer more caudal target. Besides, it has become evident that after interruption of the pain pathways for chronic pain of benign origin, the pain almost invariably returns, so mesencephalotomy is rarely indicated for pain other than cancer pain and thalamic syndrome<sup>9</sup>. Pain recurrence that appears within the first month of the intervention is due to insufficient coagulation while late pain recurrence depends on either factors of nervous system regeneration or on the polymodal function of the central nervous system<sup>22</sup>. In consideration of these limitations, it is necessary to select patients carefully, since the procedure is not without danger. Only for patients with cancer pain involving the head, neck, or upper extremities, it may be particularly helpful when all non-invasive modalities have failed and there is good correlation between the site of cancer involvement and the generation of pain.

Facial pain is a common presentation secondary to tumorous invasion of the trigeminal nerve. The pain can be elicited by everyday stimuli such as eating, shaving, talking and brushing teeth. It can be classified as either primary or idiopathic TN and secondary or symptomatic TN<sup>29</sup>. While primary or idiopathic TN has no clear cause, secondary TN has a presenting cause that can include etiologies such as tumor, multiple sclerosis or neurovascular compression. There have been few studies in the scientific literature dedicated to the treatment of tumor-related facial pain with chemoradiotherapy, radiosurgery or open surgery. Pollock et al.<sup>19</sup> reported a series of 8 patients with malignant tumor-related facial pain treated with gamma knife radiosurgery. All 8 patients with malignant tumors initially achieved pain relief, but 50% subsequently experienced a relapse of pain such as

our patients did. The other modalities resulted in considerable effects for local control. However, local control may not necessarily imply improvement in symptomatology. Our primary goal was to provide immediate pain relief and improve functional status and quality of life in patients near the end of life.

## CONCLUSION

Stereotactic mesencephalotomy with the use of high-resolution MRI and electrophysiologic localization is a valuable procedure, and as far as we know, this operation was attempted domestically for the first time. If performed meticulously and precisely, it may be beneficial in cancer pain as well as in central pain, with the avoidance of any related complications.

## References

- Amano K, Iseki H, Notani M, Kawabatake H, Tanikawa T, Kawamura H, et al. : Rostral mesencephalic reticulotomy for pain relief. Report of 15 cases. *Acta Neurochir Suppl (Wien)* 30 : 391-393, 1980
- Amano K : Destructive central lesions for persistent pain. Outcome in Gildenberg PL, Tasker RR, Franklin, Patricia O (eds) : *Textbook of Stereotactic and Functional Neurosurgery*. New York : McGraw-Hill, 1998, pp1425-1429
- Black PM, Moriarty T, Alexander E 3rd, Stieg P, Woodard EJ, Gleason PL, et al. : Development and implementation of intraoperative magnetic resonance imaging and its neurosurgical applications. *Neurosurgery* 41 : 831-842; discussion 842-845, 1997
- Bullitt E, Tew JM, Boyd J : Intracranial tumors in patients with facial pain. *J Neurosurg* 64 : 865-871, 1986
- Colombo F : Somatosensory-evoked potentials after mesencephalic tractotomy for pain syndromes. Neuroradiologic and clinical correlations. *Surg Neurol* 21 : 453-458, 1984
- Fountas KN, Lane FJ, Jenkins PD, Smith JR : MR-based stereotactic mesencephalic tractotomy. *Stereotact Funct Neurosurg* 82 : 230-234, 2004
- Frank F, Fabrizi AP, Gaist G : Stereotactic mesencephalic tractotomy in the treatment of chronic cancer pain. *Acta Neurochir (Wien)* 99 : 38-40, 1989
- Frank F, Tognetti F, Gaist G, Frank G, Galassi E, Sturiale C : Stereotaxic rostral mesencephalotomy in treatment of malignant faciothoracobrachial pain syndromes. A survey of 14 treated patients. *J Neurosurg* 56 : 807-811, 1982
- Gildenberg PL : Mesencephalotomy for cancer pain in Lozano AM, Gildenberg PL, Tasker RR (eds) : *Textbook of Stereotactic and Functional Neurosurgery*, ed 2. Berlin : Springer, 2009, pp2533-2540
- Gybel JM, Sweet WH : Neurosurgical treatment of persistent pain. Physiological and pathological mechanisms of human pain. *Pain Headache* 11 : 1-402, 1989
- International Headache Society Headache Classification Subcommittee : *The International Classification of Headache Disorders*, ed 2. Oxford : Blackwell Pub., 2004, pp1-160
- Mazars G, Merienne L, Cioloca C : [Present state of pain surgery]. *Neurochirurgie* 22 Suppl 1 : 5-164, 1976
- Miller JP, Acar F, Burchiel KJ : Trigeminal neuralgia and vascular compression in patients with trigeminal schwannomas : case report. *Neurosurgery* 62 : E974-E975; discussion E975, 2008
- Nashold BS Jr : Extensive cephalic and oral pain relieved by midbrain tractotomy. *Confin Neurol* 34 : 382-388, 1972
- Nashold BS Jr, Wilson WP, Slaughter DG : Stereotaxic midbrain lesions for central dysesthesia and phantom pain. Preliminary report. *J Neurosurg* 30 : 116-126, 1969
- Nomura T, Ikezaki K, Matsushima T, Fukui M : Trigeminal neuralgia. differentiation between intracranial mass lesions and ordinary vascular compression as causative lesions. *Neurosurg Rev* 17 : 51-57, 1994
- Ohye C : Stereotactic treatment of central pain. *Stereotact Funct Neurosurg* 70 : 71-76, 1998
- Pillay PK, Hassenbusch SJ : Bilateral MRI-guided stereotactic cingulotomy for intractable pain. *Stereotact Funct Neurosurg* 59 : 33-38, 1992
- Pollock BE, Iuliano BA, Foote RL, Gorman DA : Stereotactic radiosurgery for tumor-related trigeminal pain. *Neurosurgery* 46 : 576-582; discussion 582-583, 2000
- Raslan AM, Cetas JS, McCartney S, Burchiel KJ : Destructive procedures for control of cancer pain : the case for cordotomy. *J Neurosurg* 114 : 155-170, 2011
- Roeder F, Orthner H. [Experiences with stereotactic surgery. III. On cerebral surgery of pain with special reference to medical mesencephalotomy in thalamic hyperpathia and anesthesia dolorosa]. *Confin Neurol* 21 : 51-97, 1961
- Shieff C, Nashold BS Jr : Stereotactic mesencephalic tractotomy for the relief of thalamic pain. *Br J Neurosurg* 1 : 305-310, 1987
- Shieff C, Nashold BS Jr : Stereotactic mesencephalotomy. *Neurosurg Clin N Am* 1 : 825-839, 1990
- Spiegel EA, Kletzklin M, Szekeley EG : Pain reactions upon stimulation of the tectum mesencephali. *J Neuropathol Exp Neurol* 13 : 212-220, 1954
- Spiegel EA, Kletzklin M, Szekeley EG, Wycis HT : Role of hypothalamic mechanisms in thalamic pain. *Neurology* 4 : 739-751, 1954
- Spiegel EA, Wycis HT : Mesencephalotomy in treatment of intractable facial pain. *AMA Arch Neurol Psychiatry* 69 : 1-13, 1953
- Spiegel EA, Wycis HT : Present status of stereoencephalotomies for pain relief. *Confin Neurol* 27 : 7-17, 1966
- Spiller WG : The location within the spinal cord of the fibers for temperature and pain sensations. *J Nerv Ment Dis* 32 : 318-320, 1905
- Toda K : Etiology of trigeminal neuralgia. *Oral Sci Int* 4 : 10-18, 2007
- Wong ET, Gunes S, Gaughan E, Patt RB, Ginsberg LE, Hassenbusch SJ, et al. : Palliation of intractable cancer pain by MRI-guided cingulotomy. *Clin J Pain* 13 : 260-263, 1997
- Wycis HT, Spiegel EA : Long-range results in the treatment of intractable pain by stereotaxic midbrain surgery. *J Neurosurg* 19 : 101-107, 1962