

Utilization of low-temperature helium plasma (J-Plasma) for dissection and hemostasis during carotid endarterectomy

Konstantinos Filis, PhD, George Galyfos, PhD, Fragiska Sigala, PhD, and Georgios Zografos, PhD,
Athens, Greece

ABSTRACT

Herein we report nine cases of carotid endarterectomy in which we used a cold atmospheric helium plasma device (J-Plasma; Apyx Medical Corporation, Clearwater, Fla). Although clinical reports are limited, experimental data indicate that this technology could be used for dissection and coagulation during surgery, yielding limited adjacent tissue damage. As a result, it could be extremely useful in procedures like carotid endarterectomy that necessitate careful dissection and coagulation with limited damage of adjacent neurovascular structures. (*J Vasc Surg Cases and Innovative Techniques* 2020;6:152-5.)

Keywords: Carotid endarterectomy; Neon plasma; Dissection; Hemostasis; Low temperature

Surgical dissection and coagulation by radiofrequency devices or argon plasma are electrosurgical techniques that have been widely used during open or laparoscopic surgery for the last three decades.¹ Their use has been broadly reported for secondary hemostasis or cutdown dissection in different specialties, such as general surgery, dermatology, and gynecology.²⁻⁴ However, such modalities have been associated with extensive thermal injury of adjacent tissue that prohibits their use in dissection near sensitive neurovascular anatomic structures, especially during specific vascular surgery procedures.^{1,5}

Carotid endarterectomy (CEA) remains a vascular surgery procedure that demands precision and surgical skills. Recent pooled data reveal that the rate of cranial nerve injury has been decreased during this procedure, although it still remains a significant complication.⁶ Therefore, avoidance of unnecessary thermal damage using traditional electrocautery is of importance, and the application of new technologies could be of benefit during such procedures. A new technology has recently been introduced whereby electrical energy is delivered to tissue through a beam of helium instead of argon gas, providing a lower plasma temperature.⁵ This technology is called cold atmospheric helium plasma (CAHP).

J-Plasma (Apyx Medical Corporation, Clearwater, Fla) is such a CAHP device. It uses a gas ionization process to produce a stable, focused beam of ionized helium gas, providing surgeons with greater precision, minimal invasiveness, and absence of conductive currents during

surgery.⁵ It also has a retractable blade, which allows it to function as a cutting tool that leaves behind almost no tissue damage. When the blade is extended, it cuts down tissue with precision through low-temperature thermal energy produced by the combination of monopolar waveform and flow of helium gas. When the blade is retracted, a noncontact helium “spray” beam is used for ablation or coagulation.

This report describes the promising results with use of the device during CEA, given that there is lack of such evidence in the literature. All patients provided written informed consent for the publication of this case series as well as for all aspects of the procedure.

CASE REPORT

From January 2019 to June 2019, a total of nine patients underwent CEA for significant carotid artery stenosis. Basic characteristics of all patients are summarized in the [Table](#). Overall, four patients (44.4%) were treated for a symptomatic carotid stenosis; the rest of the patients (55.6%) were treated for asymptomatic stenosis. Among the symptomatic patients, two patients presented with minor stroke, one patient with transient ischemic attack, and one patient with amaurosis fugax.

Dissection was conducted intraoperatively with a DeBakey forceps and the J-Plasma device, although traditional electrocautery had been used for all previous cases until now. A 90-degree angled dissector was used only for surrounding vessels with loops or when the dissection plane was not clear. Dissection and coagulation were conducted with the J-Plasma

From the First Department of Propaedeutic Surgery, National and Kapodistrian University of Athens, Hippocraton Hospital.

K.F. and G.G. contributed equally to this article.

Apyx Medical Corporation or its representative in Greece may cover any submission fee partly or in full.

Author conflict of interest: none.

Correspondence: George Galyfos, PhD, First Department of Propaedeutic Surgery, National and Kapodistrian University of Athens, Hippocraton Hospital, 114 Vasilissis Sofias Ave, 11527 Athens, Greece (e-mail: georgegalyfos@hotmail.com).

The editors and reviewers of this article have no relevant financial relationships to disclose per the Journal policy that requires reviewers to decline review of any manuscript for which they may have a conflict of interest.

2468-4287

© 2020 The Author(s). Published by Elsevier Inc. on behalf of Society for Vascular Surgery. This is an open access article under the CC BY-NC-ND license (<http://creativecommons.org/licenses/by-nc-nd/4.0/>).

<https://doi.org/10.1016/j.jvscit.2020.01.008>

Table. Basic characteristics of patients

Case	1	2	3	4	5	6	7	8	9
Age, years	65	67	72	60	67	78	74	74	68
Sex	Male	Male	Female	Male	Male	Male	Female	Male	Male
Carotid stenosis, %	90	95	80	85	99	99	95	75	80
Asymptomatic	+	+	–	–	+	+	+	–	–
Stroke	–	–	+	–	–	–	–	+	–
Transient ischemic attack	–	–	–	+	–	–	–	–	–
Amaurosis	–	–	–	–	–	–	–	–	+
Coronary disease	+	–	–	–	+	+	+	–	–
Diabetes mellitus	+	–	+	–	+	+	–	–	–
Smoking history	+	+	+	+	–	+	+	+	+
Hypertension	+	–	+	+	+	+	+	+	+
Dyslipidemia	+	+	+	+	–	+	+	+	+

device at all stages of the procedure: cutting through subcutaneous tissue and platysma; dissection along the edge of the sternocleidomastoid muscle; dissection of all neurovascular structures, such as the vagus or hypoglossal nerve, the common carotid artery, and the bifurcation; and coagulation at all levels. Both options of the device were used: expanded blade for accuracy during cutting or dissecting, and helium beam for coagulation with the blade retracted. No special protective device was needed for the operating team during the procedure. The recommended settings for this procedure were the following according to the company: cutting, 20W; and coagulation, 30W. These settings may be re-evaluated in the future with growing experience. Figs 1 to 3 show use of the device throughout the procedure.

Early outcomes were optimal. There were no deaths, no cerebrovascular events, and no cardiac complications. No cranial nerve injury was observed. All patients were able to speak freely and to move the facial muscles and tongue without any paresis, and they could swallow easily. There were no major bleedings and no surgical site complications. All patients were discharged up to the third postoperative day. No 30-day adverse events have been reported.

DISCUSSION

High-frequency electrosurgical devices that cauterize tissues by use of electrical current have been associated with generation of high temperatures, extended adjacent tissue damage, and postoperative complications.⁷⁻⁹ Factors influencing the tissue effect are the duration of the application, the power setting of the device, and the distance from the probe to the tissue.¹⁰ Therefore, CAHP technology has been introduced in recent years to ameliorate these disadvantages. The cold plasma effect is highly localized, minimizing temperature levels and collateral damage to surrounding healthy tissue.^{11,12} Moreover, there is no need for a grounding pad, in contrast to standardized electrosurgical devices.

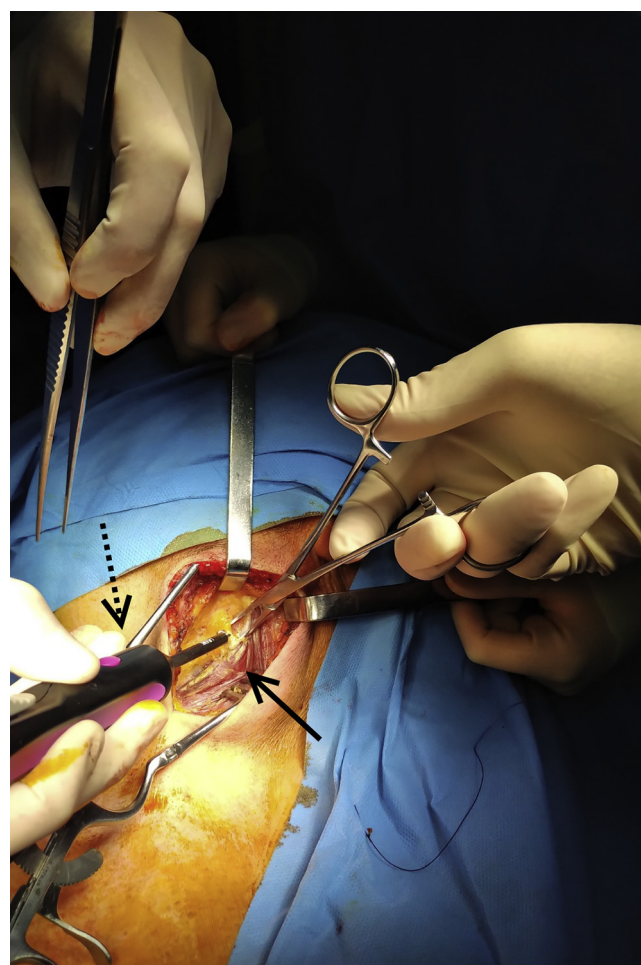


Fig 1. Dissection along the anterior border of the sternocleidomastoid muscle (solid arrow) using the J-Plasma device (dotted arrow).

Only a few reports in the literature describe the clinical use of J-Plasma during certain types of procedures, such as oncologic or dermatologic surgery.^{13,14} Furthermore, this device seems to reduce

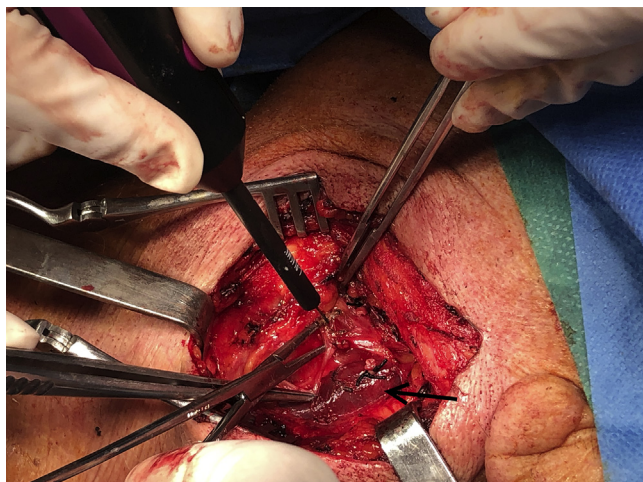


Fig 2. Dissection along the anterior border of the internal jugular vein (arrow).

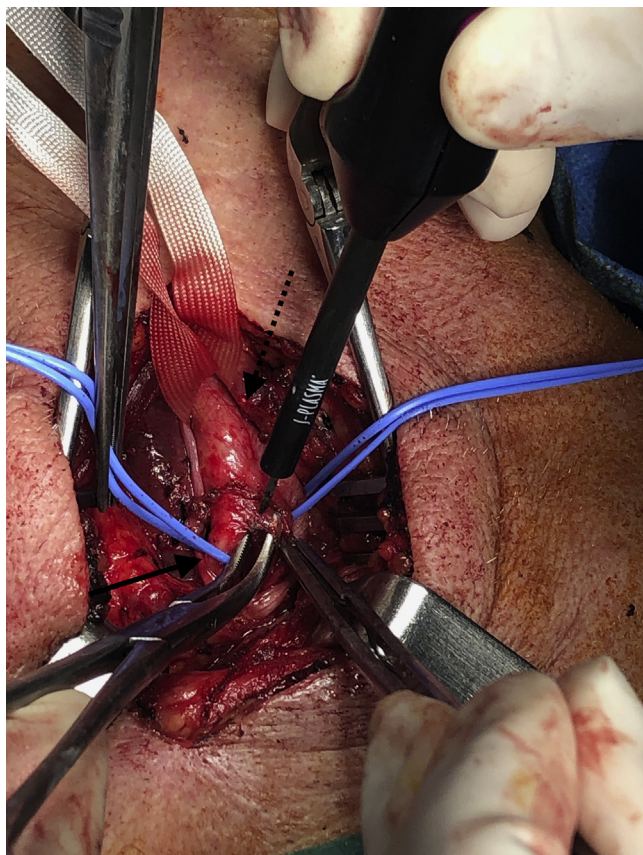


Fig 3. Dissection along the carotid bifurcation; dotted arrow, common carotid artery; solid arrow, internal carotid artery.

perioperative morbidity, including blood loss, postoperative pain, and overall procedural time in patients undergoing otolaryngologic surgery.^{15,16} J-Plasma also allows safe and effective tissue coagulation, ablation, and incision with controlled precision.⁵ In addition, its

retractable blade enables greater versatility and control of the energy as well as enhanced visibility at the application site. Thus, this device becomes extremely attractive for procedures necessitating careful dissection and coagulation, such as CEA. These data have motivated us to start using this device, given that its potential risks are similar to those of traditional electrocautery devices.^{1,4} Compared with our previous experience,¹⁷ this technique does not seem to have a negative effect on major outcomes, although a larger number of patients are needed to evaluate the effect on hemostasis time and overall duration of the procedure.

Experimental studies on animal models have shown that J-Plasma seems to control oozing bleeding by increasing blood coagulation activity, although it decreases adjacent tissue coagulation.¹⁸ This mechanism is similar to the mechanism of surgical hemostats that stimulate aggregation of platelets and coagulation factors.¹⁹ In a study by Pedroso et al,²⁰ this specific device was applied on porcine liver, kidney, and muscle tissue at different power levels and gas flows. It was shown that J-Plasma has minimal lateral and depth spread when it is applied to various tissue types, even at higher power settings or gas flow rates.¹⁷ Finally, when J-Plasma is applied to various tissue types, it performs better than or similar to other types of technology, such as monopolar, bipolar, or argon beam.²¹

Finally, regarding cost, this device is more expensive than the average electrocautery device. The cost for a J-Plasma probe reaches 500 Euros (taxes included) in Greece per procedure, although the plasma generator is provided for free by the selling company. Although comparative studies in the literature have shown a significantly lower overall cost with low-temperature plasma devices compared with traditional electrocautery, they do not refer to helium gas devices.^{22,23} In addition, the fact that J-Plasma may reduce the overall time of CEA based on our experience shows that overall costs may be reduced. These data are indicative of the cost-effectiveness, although comparative studies specifically of J-Plasma are still needed to support this strategy. Regarding the helium gas, the gas flow during the procedure is small, not exceeding 0.6 L/min. Furthermore, the cost for the gas is included in the price of the probe without additional charges.

CONCLUSIONS

Our results using J-Plasma during CEA procedures are promising. However, clinical studies are necessary to compare the efficacy and safety of this device with other traditional technologies. To achieve this, objective measures of comparison need to be defined for safer conclusions.

REFERENCES

1. Sankaranarayanan G, Resapu RR, Jones DB, Schwaitzberg S, De S. Common uses and cited complications of energy in surgery. *Surg Endosc* 2013;27:3056-72.
2. Lee DH, Bae WK, Kim JW, Paik WH, Kim NH, Kim KA, et al. The usefulness of argon plasma coagulation compared with endoscopic submucosal dissection to treat gastric adenoma. *Korean J Gastroenterol* 2017;69:283-90.
3. Steinemann DC, Lamm SH, Zerz A. Efficacy and safety of combined ultrasonic and bipolar energy source in laparoscopic surgery. *J Gastrointest Surg* 2016;20:1760-8.
4. Tammam AE, Ahmed HH, Abdella AH, Taha SA. Comparative study between monopolar electrodes and bipolar electrodes in hysteroscopic surgery. *J Clin Diagn Res* 2015;9:11-3.
5. Gentile RD. Cool atmospheric plasma (J-Plasma) and new options for facial contouring and skin rejuvenation of the heavy face and neck. *Facial Plast Surg* 2018;34:66-74.
6. Kakisis JD, Antonopoulos CN, Mantas G, Moulakakis KG, Sfyroeras G, Geroulakos G. Cranial nerve injury after carotid endarterectomy: incidence, risk factors, and time trends. *Eur J Vasc Endovasc Surg* 2017;53:320-35.
7. Pogorelić Z, Perko Z, Družijanić N, Tomić S, Mrklič I. How to prevent lateral thermal damage to tissue using the harmonic scalpel: experimental study on pig small intestine and abdominal wall. *Eur Surg Res* 2009;43:235-40.
8. Humes DJ, Ahmed I, Lobo DN. The pedicle effect and direct coupling: delayed thermal injuries to the bile duct after laparoscopic cholecystectomy. *Arch Surg* 2010;145:96-8.
9. Družijanić N, Pogorelić Z, Perko Z, Mrklič I, Tomić S. Comparison of lateral thermal damage of the human peritoneum using monopolar diathermy, Harmonic scalpel and LigaSure. *Can J Surg* 2012;55:317-21.
10. Applewhite MK, White MG, James BC, Abdulrasool L, Kaplan EL, Angelos P, et al. Ultrasonic, bipolar, and integrated energy devices: comparing heat spread in collateral tissues. *J Surg Res* 2017;207:249-54.
11. Yan D, Sherman JH, Keidar M. Cold atmospheric plasma, a novel promising anti-cancer treatment modality. *Oncotarget* 2017;8:15977-95.
12. Glowka TR, Standop J, Paschenda P, Czaplík M, Kalff JC, Tolba RH. Argon and helium plasma coagulation of porcine liver tissue. *J Int Med Res* 2017;45:1505-17.
13. Parsa M. Retroperitoneal dissection of ovarian endometrioma using J-Plasma technology. *J Minim Invasive Gynecol* 2015;22:140.
14. Binenbaum Y, Ben-David G, Gil Z, Slutsker YA, Ryzhkov MA, Felsteine J, et al. Cold atmospheric plasma, created at the tip of an elongated flexible capillary using low electric current, can slow the progression of melanoma. *PLoS One* 2017;12:0169457.
15. Zhang QF, She CP, Song W, Zhang X. [Endoscopic surgery using the low-temperature plasma radiofrequency for nasal inverted papilloma]. *Zhonghua Er Bi Yan Hou Tou Jing Wai Ke Za Zhi* 2009;44:543-5.
16. Chan KH, Friedman NR, Allen GC, Yaremchuk K, Wirtschafter A, Bikhazi N, et al. Randomized, controlled, multisite study of intracapsular tonsillectomy using low-temperature plasma excision. *Arch Otolaryngol Head Neck Surg* 2004;130:1303-7.
17. Galyfos G, Tsioufis C, Theodorou D, Katsaragakis S, Zografos G, Filis K. Cardiac troponin I after carotid endarterectomy in different cardiac risk patients. *J Stroke Cerebrovasc Dis* 2015;24:711-7.
18. Miyamoto K, Ikehara S, Takei H, Akimoto Y, Sakakita H, Ishikawa K, et al. Red blood cell coagulation induced by low-temperature plasma treatment. *Arch Biochem Biophys* 2016;605:95-101.
19. Miyamoto K, Ikehara S, Sakakita H, Ikehara Y. Low temperature plasma equipment applied on surgical hemostasis and wound healings. *J Clin Biochem Nutr* 2017;60:25-8.
20. Pedroso JD, Gutierrez MM, Volker KW, Howard DL. Thermal effect of J-Plasma energy in a porcine tissue model: implications for minimally invasive surgery. *Surg Technol Int* 2017;30:19-24.
21. Masghati S, Pedroso J, Gutierrez M, Stockwell E, Volker KW, Howard DL. Comparative thermal effects of J-Plasma, monopolar, argon, and laser electrosurgery in a porcine tissue model. *Surg Technol Int* 2019;34:35-9.
22. Kypta A, Blessberger H, Saleh K, Hönig S, Kammler J, Neeser K, et al. An electrical plasma surgery tool for device replacement—retrospective evaluation of complications and economic evaluation of costs and resource use. *Pacing Clin Electrophysiol* 2015;38:28-34.
23. Kim B, Kim BJ, Seo IK, Kim JC. Cost-effectiveness and short-term clinical outcomes of argon plasma coagulation compared with endoscopic submucosal dissection in the treatment of gastric low-grade dysplasia. *Medicine (Baltimore)* 2018;97:e0330.

Submitted Oct 2, 2019; accepted Jan 20, 2020.