

# Severe acitretin-induced diffuse idiopathic skeletal hyperostosis: a case report

Journal of International Medical Research

48(10) 1–6

© The Author(s) 2020

Article reuse guidelines:

[sagepub.com/journals-permissions](https://sagepub.com/journals-permissions)

DOI: 10.1177/0300060520966896

[journals.sagepub.com/home/imr](https://journals.sagepub.com/home/imr)

**Gabrielle Gour-Provençal<sup>1</sup>,**  
**Nicholas M. Newman<sup>2</sup>,**  
**Mathieu Boudier-Révérét<sup>1</sup> and**  
**Min Cheol Chang<sup>3</sup>** 

## Abstract

Diffuse idiopathic skeletal hyperostosis (DISH), also known as Forestier–Rotes–Querol disease, is a systemic noninflammatory disease characterized by ossification of the entheses. DISH predominantly affects the spine. Although peripheral involvement is also often reported, it rarely affects patients' function. A 77-year-old man presented to our emergency department because of incapacitating pain and stiffness in the spine and hips. The patient had been diagnosed with biopsy-proven mycosis fungoides 3 years earlier and had been treated with oral acitretin at 25 to 50 mg daily since diagnosis. However, the patient gradually developed a severely limited range of motion in his spine and hips (left > right), significantly impairing his mobility and activities of daily living. Cervical and dorsolumbar radiographs showed extensive ossification along the anterior longitudinal ligament; this finding was compatible with DISH and had not been present in radiographs taken 3 years earlier. Pelvic radiographs showed multiple enthesophytes predominantly around the coxofemoral joints. DISH has been reported as a possible long-term adverse effect of acitretin. Despite optimal conservative treatment, the patient remained severely impaired and thus finally underwent extensive osteophyte excision and total hip replacement on the left side. His acitretin therapy was also stopped to prevent further progression of his DISH.

<sup>3</sup>Department of Physical Medicine and Rehabilitation, College of Medicine, Yeungnam University, Namku, Taegu, Republic of Korea

### Corresponding author:

Min Cheol Chang, Department of Physical Medicine and Rehabilitation, College of Medicine, Yeungnam University, 317-1 Daemyungdong, Namku, Taegu 705-717, Republic of Korea.

Email: [wheel633@gmail.com](mailto:wheel633@gmail.com)

<sup>1</sup>Department of Physical Medicine and Rehabilitation, Centre Hospitalier de l'Université de Montréal, Montreal, Canada

<sup>2</sup>Orthopedic Service, Centre Hospitalier de l'Université de Montréal, Montreal, Canada



## Keywords

Diffuse idiopathic skeletal hyperostosis, hip joint, range of motion, arthroplasty, acitretin, mycosis fungoides

Date received: 4 May 2020; accepted: 25 September 2020

## Introduction

Diffuse idiopathic skeletal hyperostosis (DISH), also known as Forestier–Rotes–Querol disease, is a systemic noninflammatory disease characterized by ossification of the entheses.<sup>1</sup> Although DISH predominantly affects the spine, peripheral involvement is also often reported.<sup>1</sup> Various signs and symptoms such as polyarticular pain; neck, thoracic, lumbar, or extremity pain; limited spinal range of motion (ROM); dysphagia; and increased susceptibility to unstable spinal fractures have been described.<sup>1</sup>

The cause of DISH remains unclear. However, various factors, such as exposure to drugs in the retinoid family (e.g., acitretin), have been hypothesized to be associated with the development of the disease.<sup>1</sup> Acitretin, a synthetic retinoid, is the pharmacologically active metabolite of etretinate.<sup>2</sup> It is an established systemic second-line therapy for severe psoriasis resistant to topical therapy and is a well-tolerated therapy for early-stage mycosis fungoides.<sup>2</sup>

This report describes a patient with acitretin-induced DISH with severe ROM limitation in both hip joints requiring osteophyte excision and total hip arthroplasty.

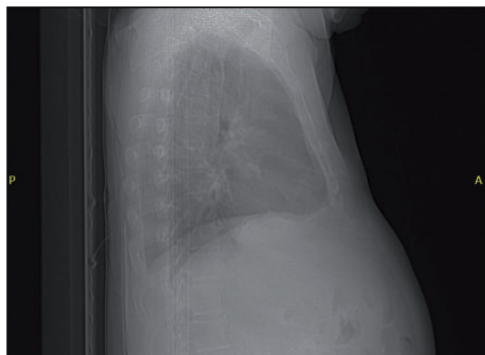
## Case report

A 77-year-old man presented to the emergency department for gradual difficulty in ambulation due to progressive pain and stiffness in the spine and hips. He had been diagnosed with biopsy-proven mycosis

fungoides 3 years earlier and had been treated with oral acitretin at 25 to 50 mg daily since diagnosis. However, the patient gradually developed severely limited ROM in the spine and hips (left > right), significantly impairing his ability to perform activities of daily living. The patient also complained of bilateral hip and low back pain.

While standing, the patient exhibited an attitude of forward trunk flexion; while walking, he exhibited decreased hip and knee ROM. Neurological and vascular examination findings were normal with the exception of diffuse hyperreflexia (3+/4) with no other upper motor neuron signs. The passive and active ROM of the hips was limited to a few degrees and elicited significant anterior thigh pain. The spine ROM was also very limited in all directions and elicited pain predominantly in flexion.

A lateral chest radiograph performed 3 years prior to the patient presenting showed no osteophytic bridging of more than three contiguous levels (Figure 1). However, cervical and dorsolumbar radiographs and a computed tomography (CT) scan performed at the present visit showed extensive ossification along the anterior longitudinal ligament (Figure 2(a)–(c)), which was compatible with DISH according to the criteria published by Resnick and Niwayama<sup>3</sup> (i.e., flowing ossification along the anterolateral aspect of at least four contiguous vertebral bodies, relative preservation of the intervertebral disc height in the involved segment, and absence of apophyseal joint bony



**Figure 1.** Lateral chest radiograph of the 77-year-old patient obtained 3 years prior to the patient presenting. No findings of diffuse idiopathic skeletal hyperostosis were observed.

ankylosis and sacroiliac joint erosion). A pelvic radiograph showed multiple enthesophytes predominantly around the coxofemoral joints (Figure 2(d)–(f)) without significant osteoarthritis. A pelvic CT scan (Figure 2(g)) showed enthesophytes over the bilateral hip joints. A positron emission tomography scan performed to evaluate the extent of the patient's mycosis fungoides showed no suspicious lesions and revealed osteodegenerative phenomena accompanied by inflammation, especially at the level of both hips, in the spine as well as enthesopathy of both greater trochanters. In light of these results, the patient's acitretin was discontinued.

During the next few months, the patient underwent multiple physiotherapy sessions without significant improvement in either pain or ROM. Fluoroscopy-guided bilateral coxofemoral injections were then performed. Despite optimal conservative treatment, the patient remained severely impaired, and an orthopedic consultation was therefore requested. Once under anesthesia, the patient's ROM was reassessed. Left hip flexion was limited to 30 degrees, thus reinforcing the fact that pain was not the only limiting factor. The orthopedic surgeon first considered excision of the

enthesophytes; however, given their significant number and size, he decided after discussing the case with his colleagues to perform total hip arthroplasty combined with excision of the most significant enthesophytes (Figure 1(h), (i)). One day postoperatively, the patient's passive left hip flexion (almost pain-free) was approximately 80 degrees, internal rotation was 20 degrees, and external rotation was 30 degrees.

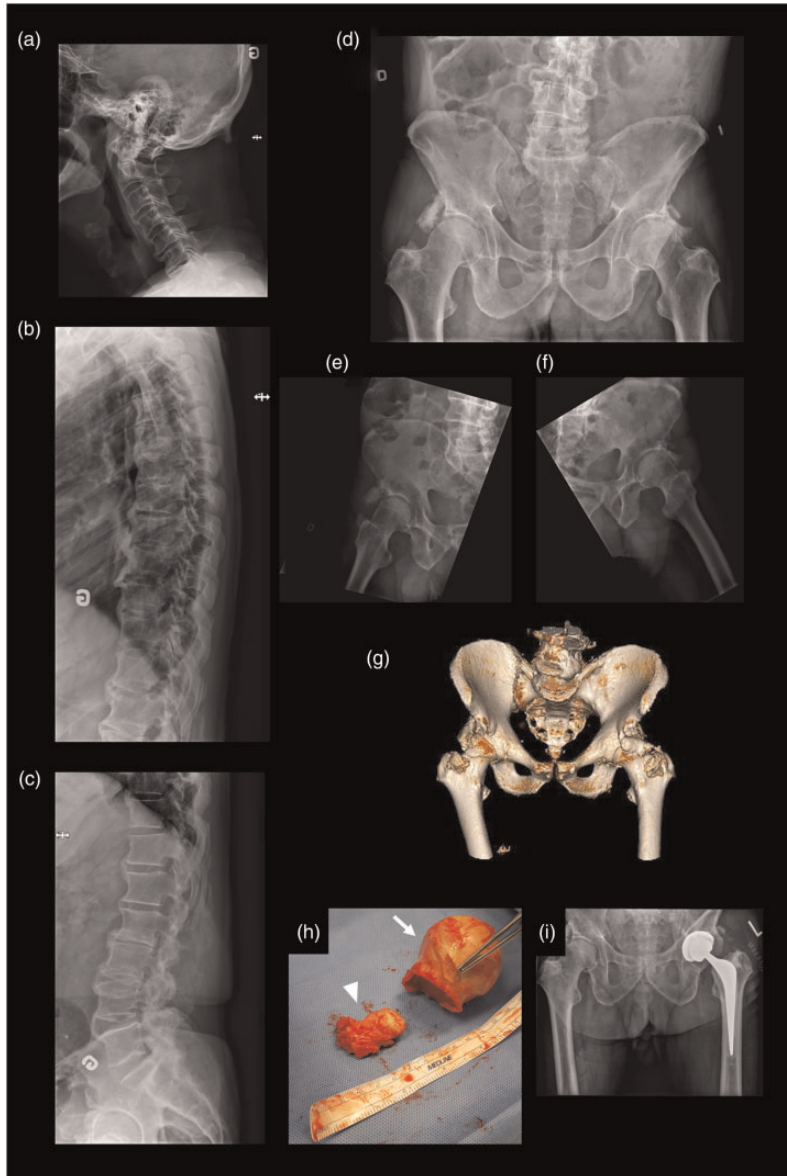
At the 6-week follow-up appointment with the orthopedic surgeon, the patient reported a significant decrease in pain, was able to flex his left hip to 40 degrees, and was able to ambulate with a walker. Given the improvement on the left side, a similar surgery will be considered for the right hip if the patient becomes more symptomatic.

## Discussion

This report describes a patient with acitretin-induced DISH with severe ROM limitation in both hip joints requiring enthesophyte excision and total hip arthroplasty. This case report aims to highlight the importance of early diagnosis of acitretin-induced DISH to prevent occurrence of severely limited spine and hip ROM. A surgical treatment option is presented in case of conservative treatment failure.

DISH is a systemic noninflammatory disease characterized by ossification of the tendons, ligaments, and joint capsules.<sup>1</sup> Although DISH predominantly affects the anterior longitudinal ligament of the spine, peripheral involvement, such as periarticular hyperostosis of the pelvis, is also often reported.<sup>1,4,5</sup>

Fahrer et al.<sup>6</sup> stated that although radiologically very impressive, periarticular hyperostosis of the pelvic area was of little clinical relevance in a group of 23 patients with DISH because it typically did not significantly affect passive ROM of the hips compared with control patients.



**Figure 2.** All images in this figure are of the 77-year-old man who developed severe acitretin-induced diffuse idiopathic skeletal hyperostosis in the present study. Lateral radiographs of the (a) cervical, (b) thoracic, and (c) lumbar spine show flowing ossifications along the anterolateral aspect of at least four contiguous vertebral bodies at each spinal level. (d) An anteroposterior pelvic radiograph shows extensive enthesophytes around both hip joints, which are better seen on the lateral views of the (e) right and (f) left hips. (g) Three-dimensional reconstruction from the pelvic computed tomography scan shows how the ossification over the superolateral left hip joint involves the articular capsule and contributes to range of motion limitation. Surgery consisted of left osteophyte resection combined with total hip arthroplasty. (h) The largest enthesophyte (arrowhead) measured around 4 cm, and the femoral head (arrow), did not show significant osteoarthritic changes. (i) An anteroposterior pelvic radiograph taken immediately postoperatively showed that the total hip prosthesis was well positioned, the major osteophytes had been resected, and a periprosthetic fracture was absent.

However, one previously published article described a patient with severe bilateral hip ROM limitations developing over a 10-year period because of severe hyperostosis induced by DISH.<sup>7</sup> Accordingly, previous studies have shown that patients with DISH often develop stiffness of both the spine and peripheral joints.<sup>8,9</sup> In our case, the patient complained of severe painful ROM restrictions in both hip joints, limiting his mobility and ability to perform activities of daily living. To the best of our knowledge, this is the first report to describe severe spinal and pelvic DISH refractory to conservative treatment that was most likely acitretin-induced.

Although current knowledge on the pathogenesis of DISH is very limited, genetic, mechanical, and environmental factors have been hypothesized to be associated with its development.<sup>1,8,10</sup> DISH is reportedly a possible long-term adverse effect of acitretin, a synthetic retinoid used for severe psoriasis and early-stage mycosis fungoides.<sup>1,2,10,11</sup> Although the exact mechanism by which acitretin induces DISH remains unknown, high levels of vitamin A and increased levels of growth hormones might be involved in the pathophysiology.<sup>12</sup>

The treatment approach for the pain and stiffness associated with DISH is currently based on the treatment guidelines for other noninflammatory conditions, such as osteoarthritis. It mainly consists of physical therapy, lifestyle changes, and the use of analgesics and local or systemic nonsteroidal anti-inflammatory drugs.<sup>8</sup> Although the literature supporting surgery is sparse, it is generally accepted that a surgical approach may be indicated after failed conservative treatment in patients with severe pain and limitation.<sup>1,8</sup> Because of the tendency for development of heterotopic ossification following arthroplasty in patients with DISH, it has been suggested that nonsteroidal anti-inflammatory drugs and/or radiotherapy may be used as preventive measures in the

postoperative period. Despite optimal conservative treatment, our patient remained severely impaired and thus finally underwent extensive osteophyte excision and total hip replacement on the left side. After surgery, his pain was significantly less severe, he gained some active/passive hip ROM, and he was able to ambulate with a walker.

In light of the findings in the present case, we suggest periodic performance of ROM examinations in patients who are being treated with retinoids and have symptoms or ROM limitations; additionally, radiographs should be ordered to screen for possible ossification abnormalities. If DISH arises, the continuation of therapy should be discussed with the patient by carefully evaluating the risks and benefits of such treatment. For patients with severely painful ROM limitations in whom conservative treatment has failed, surgery may be indicated.

### **Ethics**

This study was approved by the institutional review board of the Centre Hospitalier de Université de Montréal (number: 00003050). The requirement for written informed consent was waived because of the retrospective study design.


### **Declaration of conflicting interest**

The authors declare that there is no conflict of interest.

### **Funding**

The present study was supported by a National Research Foundation of Korea grant funded by the Korean government (grant no. NRF-2019M3E5D1A02069399).

### **ORCID iD**

Min Cheol Chang  <https://orcid.org/0000-0002-7629-7213>

## References

1. Nascimento FA, Gatto LAM, Lages RO, et al. Diffuse idiopathic skeletal hyperostosis: a review. *Surg Neurol Int* 2014; 5: S122–S125.
2. Ormerod A, Campalani E and Goodfield M. British Association of Dermatologists guidelines on the efficacy and use of acitretin in dermatology. *Br J Dermatol* 2010; 162: 952–963.
3. Resnick D and Niwayama G. Radiographic and pathologic features of spinal involvement in diffuse idiopathic skeletal hyperostosis (DISH). *Radiology* 1976; 119: 559–568.
4. Mazieres B. Diffuse idiopathic skeletal hyperostosis (Forestier-Rotes-Querol disease): what's new? *Joint Bone Spine* 2013; 80: 466–470.
5. Belanger TA and Rowe DE. Diffuse idiopathic skeletal hyperostosis: musculoskeletal manifestations. *J Am Acad Orthop Surg* 2001; 9: 258–267.
6. Fahrer H, Barandun R, Gerber N, et al. Pelvic manifestations of diffuse idiopathic skeletal hyperostosis (DISH): are they clinically relevant? *Rheumatol Int* 1989; 8: 257–261.
7. Lee W, Kim WR and Chang MC. Severe hip joint motion restriction in a patient with diffuse idiopathic skeletal hyperostosis: a case report. *Medicine (Baltimore)* 2018; 97: e0652.
8. Mader R, Verlaan JJ, Eshed I, et al. Diffuse idiopathic skeletal hyperostosis (DISH): where we are now and where to go next. *RMD Open* 2017; 3: e000472.
9. Mata S, Fortin PR, Fitzcharles MA, et al. A controlled study of diffuse idiopathic skeletal hyperostosis. Clinical features and functional status. *Medicine (Baltimore)* 1997; 76: 104–117.
10. Lee E and Koo J. Single-center retrospective study of long-term use of low-dose acitretin (Soriatane®) for psoriasis. *J Dermatolog Treat* 2004; 15: 8–13.
11. Cheeley J, Sahn RE, DeLong LK, et al. Acitretin for the treatment of cutaneous T-cell lymphoma. *J Am Acad Dermatol* 2013; 68: 247–254.
12. Vincent V, Zabraniecki L, Loustau O, et al. Acitretin-induced enthesitis in a patient with psoriatic arthritis. *Joint Bone Spine* 2005; 72: 326–329.