

A Case of Dural Arteriovenous Fistula in the Falx Cerebri: Case Report and Review of the Literature

Takashi Yamaguchi, Ayuho Higaki, Hidenori Yokota, Toshihiro Mashiko, and Keiji Oguro

A 67-year-old man presented with consciousness disturbance and right hemiparesis. Computed tomography (CT) scan showed an intracerebral hematoma with two enhanced vascular lesions. Digital subtraction angiography revealed the dural arteriovenous fistula (dAVF) in the falx cerebri which was supplied by both bilateral middle meningeal arteries and left pericallosal artery and drained into both the superior sagittal sinus and the vein of Galen via the posterior callosal vein accompanied by two venous pouches. The dAVF was obliterated by a combination of the endovascular and the direct surgeries. A dAVF in a falx cerebri is very rare and only five cases were reported. Clinical characteristics of the dAVFs are uncertain. Before deciding the strategy of treatment, it is important to consider the pathological condition including embryology of the falx, the falcine sinus, and the falcine venous plexus.

Keywords: dural arteriovenous fistula, falx cerebri, falcine sinus

Introduction

Dural arteriovenous fistulas (dAVFs) comprise approximately 10–15% of all intracranial arteriovenous malformations.^{1,2)} Most of them are located in the posterior fossa or in the region of the cavernous sinus.^{3–5)} It is well known that dAVFs are sometimes recognized at other lesions, for example, the superior sagittal sinus, the anterior cranial fossa, and the cranio-cervical junction. However, the dAVF of the falx cerebri is extremely rare and only five cases have been reported. We present a case of the dAVF of the falx cerebri with a huge intracerebral hemorrhage and review the literature focused on its embryology.

Case Presentation

A 67-year-old male was transferred to our institute due to moderate consciousness disturbance. He had no obvious history of severe head trauma or suggestion of cerebral venous thrombosis anytime in his life. Neurological examination revealed impairment of consciousness, Glasgow Coma Scale of 8 (E2, V1, M5), right hemiparesis (MMT 3), and suspicion of aphasia. Pre-contrast computed tomography

(CT) scan showed a left frontal intracerebral hematoma of 5 cm in diameter and a right frontal round isodensity mass of 2 cm in diameter. Post-contrast CT scan demonstrated that the latter was homogeneously enhanced and a smaller enhanced lesion was also evident close to the left frontal hematoma and was supposed to be responsible for bleeding (Fig. 1). Instantly, digital subtraction angiography (DSA) was undertaken and revealed the existence of dAVF with a huge venous pouch. But before we could get further information, the patient fell into a coma and showed bilateral dilated pupils and respiratory depression. DSA was discontinued and hematoma removal was performed through small craniotomy at once. Re-examination of the DSA was performed as he recovered his neurological condition. The DSA disclosed the dAVF in the falx cerebri fed by the bilateral middle meningeal arteries (MMAs), the falcine artery raised the right ophthalmic artery and the left pericallosal artery. Furthermore, the dAVF drained into the falcine sinus coursed to both the superior sagittal sinus (SSS) and the posterior callosal vein coursed to the vein of Galen and was accompanied by two large venous pouches (Fig. 2). The exact fistulous point was thought to be located in the lower edge of the falx cerebri close to the feeders from the left pericallosal artery. Our final diagnosis was dAVF in the falx cerebri which was classified as Cognard type IV. Bilateral MMAs were occluded by the GDC (Guglielmi Detachable Coils)TM Detachable Coils at bilateral distal points approximately 4–5 cm from both foramen spinosum to avoid any unexpected massive bleeding. Radical surgery was performed 22 days after onset of the disease. After bifrontal craniotomy and bilateral dural incision parallel to the SSS with an interhemispheric approach, multiple draining veins that flowed out through the falx cerebri were identified (Fig. 3). The fistulous points were obliterated by multiple Sugita's titanium clips. Moreover, the falx was extensively coagulated on both sides to achieve complete occlusion of the falcine sinus and other small fistulas. Post operative DSA demonstrated complete disappearance of the dAVF (Fig. 4). The patient whose moderate dementia and right hemiparesis remained was transferred to another hospital for further rehabilitation. His final modified Rankin Scale was 4 at 6 months after the surgery.

Discussion

The dAVF in the falx cerebri has been considered enormously rare and only five cases have been reported. Among them, Yoshioka et al. first reported a case of the falcine sinus dAVF in 2013.⁶⁾ The falcine sinus, located in the falx cerebri, is an embryonic vessel which connects between the

Department of Neurosurgery, Jichi Medical University, Shimotsuke, Tochigi

Received: November 14, 2015; Accepted: January 14, 2016

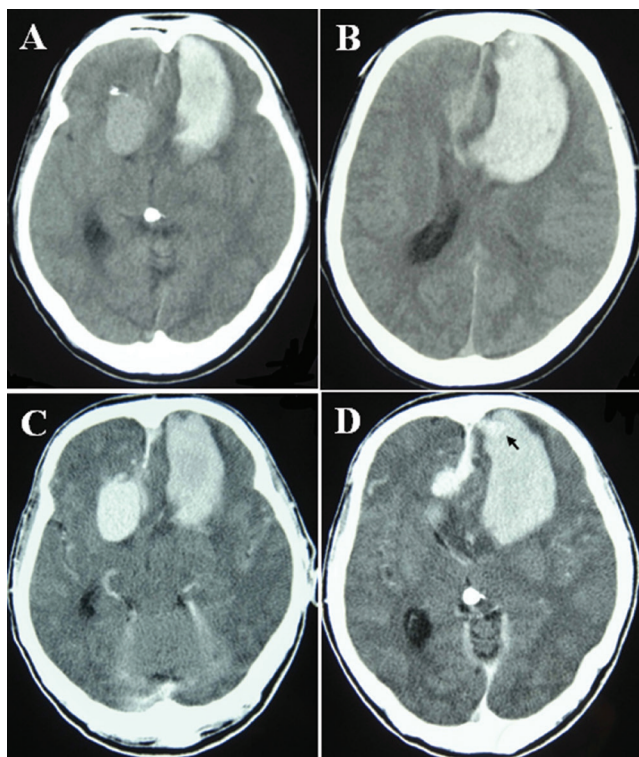


Fig. 1 A, B: Pre-contrast computed tomography (CT) scan showed the intracerebral hematoma in the left frontal lobe and the isodensity round mass in the right frontal lobe. C, D: Post-contrast CT scan revealed the left midline small enhanced lesion adjacent to the hematoma (arrow) and the right isodensity round mass was homogeneously enhanced.

SSS and the inferior sagittal sinus (ISS) and mostly closes after birth.⁷⁾ Persistent falcine sinus has widely been described in the literature in the pediatric population. It is extremely rare to identify a persistent falcine sinus without associated anomalies. Associate anomalies include bifid cranium, vein of Galen aneurysmal malformation, agenesis of the corpus callosum, Apert syndrome, osteogenesis imperfecta, and Chiari malformation Type II.⁷⁾ Furthermore, if the straight sinus is absent or rudimentary, the falcine sinus may be recanalized.^{8,9)} Falcine sinuses are known to be highly rare in the adult population.⁹⁻¹¹⁾ On the other hand, Ryu mentioned falcine sinuses were present in 2.1% in adults.¹²⁾ Tatarli et al. concluded that the falcine venous plexus exhibited different anatomical patterns in the anterior, middle, and posterior portions of the falx cerebri and that falcine sinuses were different patterns according to their location.¹³⁾ But an important distinction should be made between the rare persistent fetal falcine sinus and the falcine venous plexus.¹⁴⁾

Six cases of the dAVFs in the falx cerebri including our case have been reported (Table 1).^{6,15-18)} There are no outstanding characteristics about age, gender, or symptoms at onset. Of note, dAVFs in the falx cerebri frequently have feeders branching from anterior cerebral arteries. As for the drainers of these dAVFs, Yoshioka et al. reported the only case whose drainer was identical to the falcine sinus but some cases could be also judged that part of their drainers were the falcine sinuses by our detailed analysis. Because the fistula is located in the falx cerebri, the opened falcine venous plexus channel could form the falcine sinus as the draining vein. This means that this type of dAVF is thought

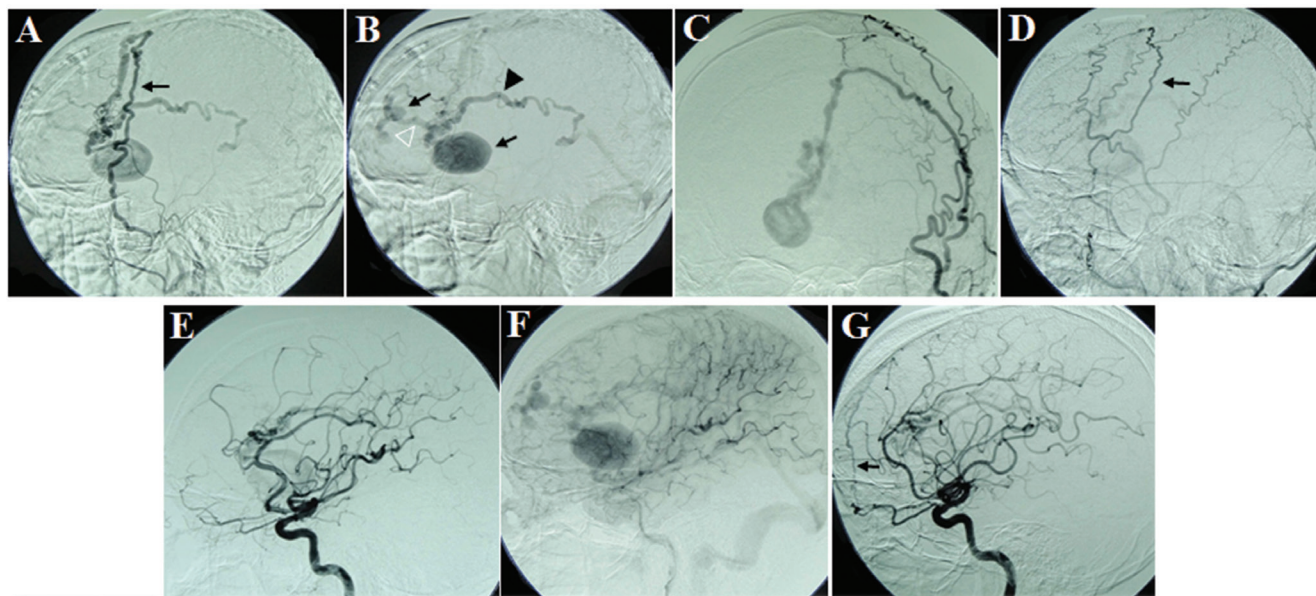


Fig. 2 A, C: Left external carotid angiography (ECAG) in early phase showed the dural arteriovenous fistula (dAVF) in the falx cerebri with a huge venous pouch fed by the middle meningeal artery (MMA) (arrow). B: Left ECAG in late phase demonstrated two draining veins coursed to the superior sagittal sinus (white triangle) and the posterior callosal artery (black triangle). The two venous pouches are visible (arrow). D: Right ECAG also showed the right MMA supplied the dAVF (arrow). E, F: Left internal carotid angiography (ICAG) in early (E) and late phase (F) demonstrated the dAVF fed by the anterior cerebral artery with two venous pouches. G: Right ICAG showed the developed anterior falcine artery connected to the dAVF (arrow).

to be formed due to either the recanalization of the falcine sinus/venous plexus after obstruction of one or more of the SSS, ISS, Galenic vein, and/or straight sinus, or the acquired obstruction of a congenital falcine sinus/venous plexus. Therefore, dAVFs in the falx cerebri may occur at a younger age. These dAVFs are often accompanied with venous pouches. High possibility of blood supply from the anterior cerebral artery and existence of the venous pouch is supposed to be valid if they belong to a lateral group of Geibprasert's classification similar to an anterior cranial fossa dAVF.¹⁹

Extensive removal of the falx cerebri including the falcine sinus, the abnormal falcine venous plexus, and other draining

veins or complete endovascular obliteration of the entire draining system represents an adequate strategy in the surgical treatment of the dAVF in the falx cerebri. However, we achieved complete obliteration of the dAVF with enough coagulation on both sides of the falx. Prognosis of this disease depends on the onset form, especially the severity of the bleeding.

In summary, embryological consideration including the possibility of a falcine sinus and a falcine venous plexus is definitely needed to understand the pathogenesis of the dAVF in the falx cerebri. Yet, the clinical characteristics have not been fully clarified due to the very rare occurrence of the dAVF in the falx. Further review of this disease will be desired.

Conclusion

We experienced a rare case of the dAVF in the falx cerebri with a huge venous pouch and an intracerebral hematoma.

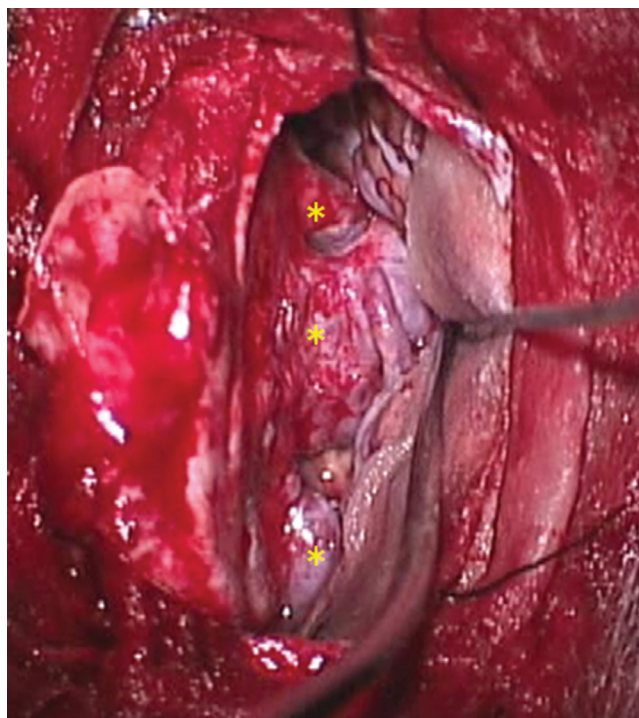


Fig. 3 Intraoperative microscopic image. It is revealed that three major draining veins flowed out from the falx cerebri (*: fistulous points) by retracting right frontal lobe.

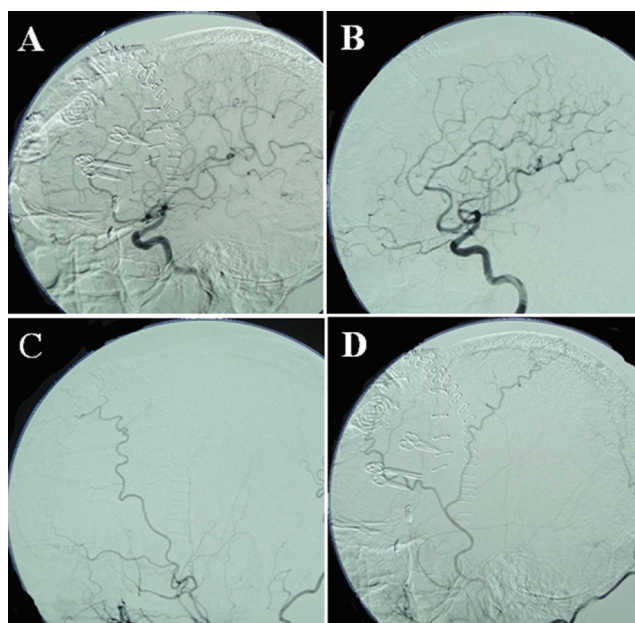


Fig. 4 Post operative digital subtraction angiography (A: right ICAG, B: left ICAG, C: right ECAG, D: left ECAG) showed complete obliteration of the dural arteriovenous fistula. ECAG: external carotid angiography, ICAG: internal carotid angiography.

Table 1 Summary of the cases of dural arteriovenous fistulas in the falx cerebri

No.	Authors, year	Age/Sex	Onset	Feeder	Drainer	VP	RVD	Treatment	Outcome
1	Kosnik et al., 1974 ¹⁵⁾	34/F	headache	ACA, AFA	ISS	(-)	(-)	DS	Excellent
2	Agawa et al., 1991 ¹⁶⁾	62/M	SAH	MMA, AFA	FS→SSS	(+)	(+)	DS	Excellent
3	Kothbauer et al., 1994 ¹⁷⁾	73/F	SAH	MMA, OA	PPV→GV	(+)	(+)	unknown	unknown
4	Ratliff et al., 1999 ¹⁸⁾	24/M	headache	ACA, VA*	SSS, PPV→GV	(+)	(+)	DS+RS	Excellent
5	Yoshioka et al., 2013 ⁶⁾	60/M	incidental	ACA, MMA, AEA	FS→SSS/ISS	(-)	(+)	DS	Excellent
6	Present case, 2015	67/M	ICH	ACA, MMA	FS→SSS, PPV→GV	(+)	(+)	TAE+DS	Fair

VP: venous pouch, RVD: retrograde venous drainage, SAH: subarachnoid hemorrhage, ICH: intracranial hemorrhage, ACA: anterior cerebral artery, AFA: anterior falcine artery, MMA: middle meningeal artery, OA: occipital artery, VA*: meningeal branch of vertebral artery, AEA: anterior ethmoidal artery, ISS: inferior sagittal sinus, SSS: superior sagittal sinus, FS: falcine sinus, PPV: posterior pericallosal vein, GV: Galenic vein, DS: direct surgery, RS: radiosurgery, TAE: transarterial embolization, F: female, M: male.

By reviewing the literature, it is speculated that the falcine sinus dAVF and the dAVF in the falx cerebri could be synonymous. To consider surgical strategy, its etiology and pathology must be declared.

Conflicts of Interest Disclosure

The authors have no personal, financial, or institutional interest in any of the drugs, materials, or devices described in this article.

References

- 1) Houser OW, Baker HL, Rhoton AL Jr, Okazaki H: Intracranial dural arteriovenous malformations. *Radiology* 105: 55–64, 1972
- 2) Ohta T, Kajikawa H: [Dural arteriovenous malformation (author's transl)]. *Neurol Med Chir (Tokyo)* 18: 439–472, 1978 (Japanese)
- 3) Newton TH, Weidner W, Greitz T: Dural arteriovenous malformation in the posterior fossa. *Radiology* 90: 27–35, 1969
- 4) Malik GM, Pearce JE, Ausman JI, Mehta B: Dural arteriovenous malformations and intracranial hemorrhage. *Neurosurgery* 15: 332–339, 1984
- 5) Lasjaunias P, Manelfe C, Chiu M: Angiographic architecture of intracranial vascular malformations and fistulas—pretherapeutic aspects. *Neurosurg Rev* 9: 253–263, 1986
- 6) Yoshioka S, Moroi J, Kobayashi S, Furuya N, Ishikawa T: A case of falcine sinus dural arteriovenous fistula. *Neurosurgery* 73: E554–E556, 2013
- 7) Sener RN: Association of persistent falcine sinus with different clinico-radiologic conditions: MR imaging and MR angiography. *Comput Med Imaging Graph* 24: 343–348, 2000
- 8) Kesava PP: Recanalization of the falcine sinus after venous sinus thrombosis. *AJNR Am J Neuroradiol* 17: 1646–1648, 1996
- 9) Strub WM, Leach JL, Tomsick TA: Persistent falcine sinus in an adult: demonstration by MR venography. *AJNR Am J Neuroradiol* 26: 750–751, 2005
- 10) Varma DR, Reddy BC, Rao RV: Recanalization and obliteration of falcine sinus in cerebral venous sinus thrombosis. *Neurology* 70: 79–80, 2008
- 11) Kashimura H, Arai H, Ogasawara K, Ogawa A: Persistent falcine sinus associated with obstruction of the superior sagittal sinus caused by meningioma—case report. *Neurol Med Chir (Tokyo)* 47: 83–84, 2007
- 12) Ryu CW: Persistent falcine sinus: is it really rare? *AJNR Am J Neuroradiol* 31: 367–369, 2010
- 13) Tatarli N, Ceylan D, Canaz H, Tokmak M, Bay HH, Şeker A, Keleş E, Kiliç T, Cavdar S: Falcine venous plexus within the falx cerebri: anatomical and scanning electron microscopic findings and clinical significance. *Acta Neurochir (Wien)* 155: 2183–2189; discussion 2189, 2013
- 14) Tubbs RS, Loukas M, Louis RG, Shoja MM, Acakpo-Satchivi L, Blount JP, Salter EG, Oakes WJ, Wellons JC: Anatomy of the falcine venous plexus. *J Neurosurg* 107: 155–157, 2007
- 15) Kosnik EJ, Hunt WE, Miller CA: Dural arteriovenous malformations. *J Neurosurg* 40: 322–329, 1974
- 16) Agawa M, Kohno T, Sogabe K: [Dural arteriovenous malformation in the falx with subarachnoid hemorrhage]. *No Shinkei Geka* 19: 841–845, 1991
- 17) Kothbauer K, Huber P: Dural arteriovenous fistula in the falx cerebri. *Neuroradiology* 36: 616–618, 1994
- 18) Ratliff J, Voorhies RM: Arteriovenous fistula with associated aneurysms coexisting with dural arteriovenous malformation of the anterior inferior falx. Case report and review of the literature. *J Neurosurg* 91: 303–307, 1999
- 19) Geibprasert S, Pereira V, Krings T, Jiarakongmun P, Toulgoat F, Pongpech S, Lasjaunias P: Dural arteriovenous shunts: a new classification of craniospinal epidural venous anatomical bases and clinical correlations. *Stroke* 39: 2783–2794, 2008

Corresponding author:

Takashi Yamaguchi, MD, PhD, Department of Neurosurgery, Jichi Medical University, 3311-1 Yakushiji, Shimotsuke, Tochigi 329-0498, Japan.

✉ takashiy@jichi.ac.jp