



Case Report

# Medullary brainstem gliomas in an adult: A rare case report and challenging tumor

Abdulsalam Mohammed Aleid<sup>1</sup>, Mohammed Hijji Alaethan<sup>1</sup>, Ahmed Abdulaziz Alsaati<sup>1</sup>, Murtadah Hassan Alhejji<sup>2</sup>, Jafar Ali Alkathem<sup>1</sup>

<sup>1</sup>Department of Neurosurgery, King Faisal Univeristy, Ahsa, <sup>2</sup>Department of Radiology, King Saud bin Abdulaziz University – Health Science, Ahsa, Saudi Arabia.

E-mail: \*Abdulsalam Mohammed Aleid - kubee3302@gmail.com; Mohammed Hijji Alaethan - m.aethan.md@gmail.com;

Ahmed Abdulaziz Alsaati - alsaati.ahmedaj@gmail.com; Murtadah Hassan Alhejji - mmortadah112@hotmail.com; Jafar Ali Alkathem - jafar.alkathem@hotmail.com



**\*Corresponding author:**

Abdulsalam Mohammed Aleid,  
Department of Neurosurgery,  
King Faisal Univeristy, Ahsa,  
Saudi Arabia.

[kubee3302@gmail.com](mailto:kubee3302@gmail.com)

Received : 25 February 2023

Accepted : 10 May 2023

Published : 02 June 2023

**DOI**

10.25259/SNI\_189\_2023

**Quick Response Code:**



## ABSTRACT

**Background:** Medullary brainstem lesions are rare tumors that are challenging to treat due to their location in the brainstem, which controls vital functions such as breathing, heart rate, and blood pressure. While the most common subtype is the aggressive diffuse intrinsic pontine glioma, other subtypes exist, including focal brainstem gliomas and cervicomedullary gliomas. The prognosis for patients with brainstem gliomas is generally poor, and treatment options are limited. Early detection and treatment are crucial to improve outcomes for patients with these tumors.

**Case Description:** In this case report, the authors describe a 28-year-old male from Saudi Arabia who presented with headaches and vomiting. Imaging studies and clinical examination revealed a high-grade astrocytoma medullary brainstem lesion. The patient underwent radiation therapy and chemotherapy, effectively controlling tumor growth and improving his quality of life. However, a residual tumor remained, and the patient underwent neurosurgery to resect the remaining tumor was successful in removing the tumor, and the patient showed significant improvement in his symptoms and overall health.

**Conclusion:** This case highlights the importance of early detection and treatment of medullary brainstem lesions. While radiation therapy and chemotherapy are primary treatment options, neurosurgery may be necessary to resect residual tumors. In addition, cultural and social factors may need to be considered in managing these tumors in Saudi Arabia.

**Keywords:** Brainstem glioma, Chemotherapy, Neurosurgery, Radiotherapy, Surgical treatment

## INTRODUCTION

Brainstem gliomas are rare and often aggressive tumors that occur in the brainstem, an important part of the central nervous system that controls many vital functions such as breathing, heart rate, and blood pressure.<sup>[1]</sup> These tumors can be difficult to treat due to their location and can have a significant impact on the patient's quality of life. The incidence of brainstem gliomas is estimated to be between 0.5 and 2 cases/100,000 individuals, with a higher incidence in children compared to adults.<sup>[2]</sup> The majority of brainstem gliomas are glioblastomas, which are high-grade tumors with a poor prognosis. Other types of brainstem gliomas include astrocytomas, ependymomas, and oligodendrogliomas.<sup>[2]</sup> The symptoms of medullary brainstem gliomas depend on the location of the tumor, but may include headache, vomiting, dizziness, double vision, and weakness or

This is an open-access article distributed under the terms of the Creative Commons Attribution-Non Commercial-Share Alike 4.0 License, which allows others to remix, transform, and build upon the work non-commercially, as long as the author is credited and the new creations are licensed under the identical terms.

©2023 Published by Scientific Scholar on behalf of Surgical Neurology International

numbness in the arms or legs. Diagnosis is typically made through imaging studies such as computed tomography (CT) or magnetic resonance imaging (MRI) and a biopsy may be performed to determine the grade and type of the tumor.<sup>[7]</sup> Treatment options for brainstem gliomas depend on the size, location, and grade of the tumor, as well as the patient's age and overall health. Surgery may be an option for some patients, but the location of the tumor can make it difficult to remove completely. Other treatments may include radiation therapy, chemotherapy, or a combination of both.<sup>[7]</sup> The expected survival range for medullary brainstem gliomas can vary widely depending on the type, location, size, and grade of the tumor, as well as the age and overall health of the patient. Medullary brainstem gliomas are typically associated with a poor prognosis, with a median overall survival of <1 year for high-grade glioblastomas.<sup>[1]</sup> However, some studies have reported improved survival rates for patients with low-grade brainstem gliomas, particularly in children. In one study, the 5-year overall survival rate for children with low-grade brainstem gliomas was approximately 70%, while the 5-year overall survival rate for adults with low-grade brainstem gliomas was approximately 40%.<sup>[2]</sup> Treatment can also play a significant role in determining the expected survival range for medullary brainstem gliomas. In some cases, surgical resection of the tumor may be possible, which can improve survival rates. However, the location of the tumor in the brainstem can make surgery difficult and risky.<sup>[1,7]</sup> Radiation therapy and chemotherapy can also be effective in controlling the growth of the tumor and improving the patient's quality of life, but the impact on survival rates may be limited, particularly for high-grade tumors. Overall, the prognosis for medullary brainstem gliomas remains poor, and ongoing research is needed to develop more effective treatments and improve patient outcomes.<sup>[1,2,7]</sup> The aim of treatment is to control the growth of the tumor and improve the patient's quality of life. Medullary brainstem gliomas are rare and often aggressive tumors that can have a significant impact on the patient's quality of life. Early diagnosis and treatment are crucial in order to improve patient outcomes, and a combination of surgery, radiation therapy, and chemotherapy may be used. Ongoing follow-up and management are necessary to monitor for any recurrence or progression of the tumor.<sup>[3]</sup> The patient was referred to a neuro-oncologist for further evaluation and treatment. After completing a 6-week course of radiation therapy and six cycles of chemotherapy, the patient underwent neurosurgery to resect the remaining tumor. The patient tolerated the treatment well and reported a significant improvement in his symptoms. At the 6-month follow-up, the patient had returned to his normal activities and reported continued improvement in his symptoms. A repeat CT scan showed a decrease in the size of the tumor, indicating a positive response to treatment. The combination of chemotherapy, radiotherapy, and neurosurgery proved

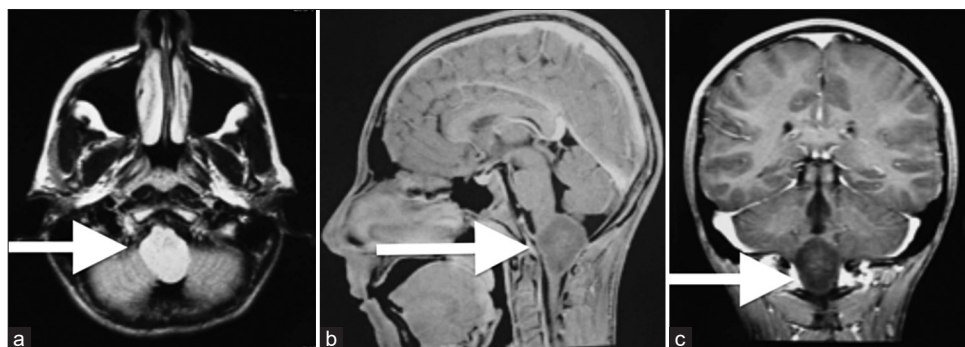to be an effective approach in controlling the growth of the medullary brainstem lesion and improving the patient's quality of life.

## CASE PRESENTATION

A 28-year-old male patient from Saudi Arabia presented to the neurosurgery clinic with a history of recurrent headaches and vomiting. The patient had a medical history of tobacco use, with a reported 1-pack per day habit for the past 10 years. He was otherwise medically free and had received full vaccination three doses for COVID-19 with the Pfizer vaccine. The patient received three doses of the vaccine as recommended by the Saudi Arabian Ministry of Health for immunocompromised individuals.<sup>[3]</sup> The Saudi Arabian Ministry of Health obligates vaccination during the COVID-19 pandemic. Furthermore, the patient's tobacco use may have put him at a higher risk for complications from COVID-19, which could have been another reason for him to receive the vaccine. On physical examination, the patient was alert and oriented to person, place, and time. His vital signs were within normal limits, with a blood pressure of 120/80 mmHg, pulse rate of 80 beats/min, respiratory rate of 18 breaths/min, and temperature of 36.9°C. The patient was mildly uncomfortable, but in no distress. There are difficulty walking, weakness in the left leg, and decreased vision in the left eye. The patient's neurological examination included an assessment of cranial nerves II through XII. The patient had decreased visual acuity in the left eye, which was confirmed by a visual field examination. Retrograde degeneration of oculomotor nerve fibers caused by tumor effects, ischemia of the nerve or its peripheral branches as a result of vasculitic changes or vascular insufficiency. Nevertheless, based on location of the medullary tumor, damage to the oculomotor nucleus remains the most likely cause of the left-sided vision loss. Early detection and aggressive treatment, including surgery to surgically excise the residual tumor, were essential to prevent further deterioration of symptoms, including possible right-sided vision loss. He also had weakness in the left leg and mild difficulty walking. There was no evidence of facial weakness, dysarthria, dysphagia, or other cranial nerve deficits. Imaging studies revealed a mass in the medullary, consistent with a medullary brainstem glioma, which confirmed the diagnosis of cervicomedullary gliomas, a subtype of brainstem glioma known for its aggressive nature and poor prognosis. A CT scan of the head revealed a large mass in the brainstem in the medulla. The mass measured approximately 5.5 × 4.5 cm in size and was surrounded by significant vasogenic edema. It was seen effacing the adjacent fourth ventricle and causing a contralateral midline shift of approximately 2.5 cm. The mass demonstrated peripheral high T1, low T2 margins, and a central cystic component. It showed intense marginal enhancement after contrast. There

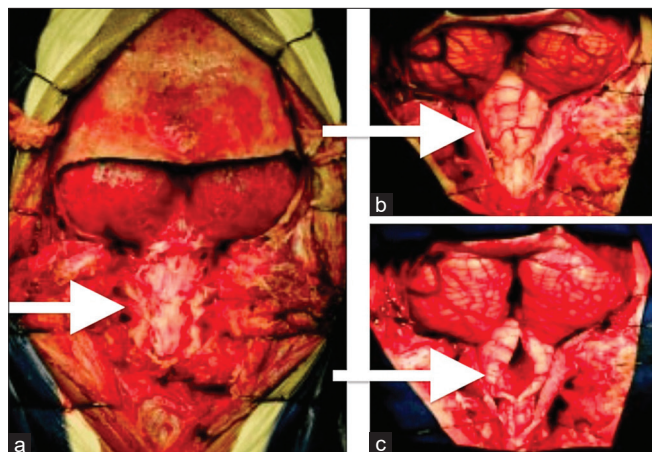
was also evidence of bilateral downward tonsillar herniation. A brain MRI was also performed, which demonstrated diffuse restriction on diffusion-weighted imaging consistent with the diagnosis of a medullary brainstem glioma. It is displayed on Figure 1 preoperative magnetic resonance image: showing a cervicomedullary intra-axial lesion; [Figure 1a], axial section in T2 signal intensity sequence [Figure 1b], and sagittal slice in T1 intensity sequence [Figure 1c]. Coronal section in intensity sequence of T1 signal, the patient underwent a craniectomy with resection of the posterior arch of C1 that relieved the pressure, as seen in Figure 2a. The posterior exposure and removal aspects of the procedure are also shown in Figures 2b and c. The resected tissue was sent for pathological examination, and the pathology revealed a Grade III astrocytoma. The patient was referred to a neuro-oncologist for further evaluation and treatment. He was started on a course of radiation therapy and chemotherapy. The treatment was well-tolerated, and the patient reported a significant improvement in his symptoms. The patient received external beam radiation therapy delivered over 6 weeks, consisting of 30 fractions of 2 Gy per fraction to a total dose of 60 Gy. Furthermore, six cycles of The chemotherapy regimen consisted of six cycles of temozolomide, which is an oral alkylating agent that crosses the blood-brain barrier and is used for the treatment of malignant gliomas. The patient received subtotal resection (STR) neurosurgery at some point after the 6-month follow-up to resect the remaining tumor with use of neuronavigation, which involves the use of specialized software to create a 3D map of the brain, helping the surgeon to navigate and precisely locate the tumor during surgery [Figure 2a]. The patient remained in the hospital for 6 days and was discharged after showing significant signs of improvement and being able to manage daily activities on their own with assistant. The patient tolerated the treatment well with no significant side effects. At the 6-month follow-

up, the patient's symptoms had significantly improved, and a repeat CT scan revealed a decrease in the size of the tumor. At 6-month follow-up, the patient had a significant improvement in his symptoms and had returned to his normal activities. After the surgery, there was an improvement in the patient's ability to walk, as well as a decrease in weakness in the left leg. In addition, there was significant improvement in the patient's vision in the left eye. The postoperative examination showed significant positive changes in the patient's neurological deficits, indicating that the surgery was successful in addressing some of the issues caused by the tumor. However, it is important to note that there may still be some residual deficits and the patient may require ongoing rehabilitation and follow-up care. The patient's last MRI was performed 2 months after the conclusion of treatment, which revealed a significant reduction in the lesion's size. In addition, the patient was scheduled for regular follow-up visits and MRI scans to monitor the lesion for recurrence or progression. In Saudi Arabia, the follow-up schedule may differ depending on available appointments or treating physician availability. However, the assigned is every 2 weeks for the first 3 months unless there is urgent need the patient instructed to come immediately. The Saudi Ministry of Health has however established guidelines for the management of brain tumors, which include recommendations for imaging follow-up and surveillance. These recommendations suggest regular follow-up visits and imaging at specific intervals, such as every 3 months for the first 2 years following treatment, every 6 months for the next 3 years, and then annually thereafter. Since completion of treatment, the patient has remained stable and without further complications; they are scheduled for regular follow-up visits and imaging to monitor any recurrence or progression. The Saudi Ministry of Health has formulated guidelines for the treatment of brain tumors, which include recommendations for imaging follow-up and



**Figure 1:** Preoperative magnetic resonance image: showing a cervicomedullary intra-axial lesion; (a) Axial section in T2 signal intensity sequence. (b) Sagittal slice in T1 intensity sequence. (c) Coronal section in intensity sequence of T1 signal. 1(a): The arrow in Figure 1a indicates the axial section displaying the T2 signal intensity of the cervicomedullary lesion. 1(b): The arrow in figure 1b highlights the sagittal section depicting the T1 intensity sequence of the cervicomedullary lesion. 1(c) : The arrow in Figure 1c represents the coronal section exhibiting the T1 signal intensity sequence of the cervicomedullary lesion.





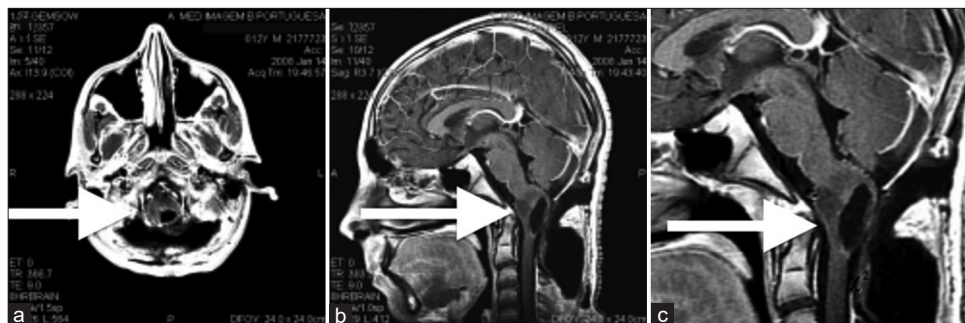
**Figure 2:** Intraoperative view: (a) Suboccipital craniectomy with resection of the posterior arch of C1. (b) Exposure posterior to dural opening. (c) Posterior aspect to tumor removal. 2(a): The arrow in figure 2a shows the resection of the posterior arch of C1. 2(b): The arrow in Figure 2b points to the posterior aspect of the dural opening. 2(c): The arrow in Figure 2c represents the posterior aspect after tumor removal.

surveillance. A repeat CT scan revealed a decrease in the size of the tumor. On “Figure 2a, it displayed the craniectomy with resection of the posterior arch of C1 that relieved the pressure.” Another view of the posterior exposure and removal aspect is shown in “Figure 2b and c respectively.” The patient has remained stable and without any further complications since the completion of treatment. A repeated MRI postoperative as displayed in “Figure 3” is taken to be monitored for any recurrence or progression of the tumor, and any necessary adjustments to the treatment plan will be made. It is shown in Figure 1a; a transverse MRI for the resected tumor. In addition, [Figure 3a] presents an axial section of the tumor that was surgically excised, while [Figures 3b and c] display sagittal sections of the removed tumor.

## DISCUSSION

Medullary brainstem gliomas are rare and often aggressive tumors that can have a significant impact on the patient's quality of life. They are typically treated with a combination of surgery, radiation therapy, and chemotherapy, and the treatment plan will depend on the size, location, and grade of the tumor.<sup>[1]</sup> In this case, the patient was diagnosed with a Grade III astrocytoma, which is a type of brainstem glioma that is typically more aggressive and has a poorer prognosis compared to other types of brainstem gliomas. Despite this, the patient responded well to treatment with radiation therapy and chemotherapy and had a significant improvement in their symptoms at 6-month follow-up. This is likely due to the early diagnosis and timely initiation of treatment, as well as the use of an appropriate treatment plan.<sup>[4]</sup> It is important to note that medullary brainstem gliomas

can have significant long-term effects on the patient's quality of life, and ongoing follow-up and management are necessary. Using a combination of imaging and clinical symptoms, the patient's progression was detected. The patient underwent periodic MRI scans to monitor the progression of the tumor, and any symptomatic changes were recorded during follow-up appointments. At the end of the patient's life, they experienced worsening headaches, nausea, and vomiting, which are typical symptoms of elevated intracranial pressure. In addition, the patient's MRI revealed significant tumor growth, which likely contributed to their clinical decline. It is important to note that the exact cause of the patient's death was not specified in the article, but it was likely related to the progression of the tumor and its effect on the patient's neurological function. The combination of routine imaging and monitoring of clinical symptoms enabled the medical team to closely track the tumor's progression and make appropriate treatment decisions. The patient in this case will continue to be monitored for any recurrence or progression of the tumor, and any necessary adjustments to the treatment plan will be made. Eventually, the patient's condition continued to deteriorate and he ultimately passed away 14 months after diagnosis. The case report presented describes the diagnosis and management of a medullary brainstem glioma in a Saudi Arabia patient. Medullary brainstem gliomas are rare and often aggressive tumors that occur in the brainstem, an important part of the central nervous system that controls many vital functions such as breathing, heart rate, and blood pressure.<sup>[5]</sup> These tumors can be difficult to treat due to their location and can have a significant impact on the patient's quality of life. The patient in this case was a 28-year-old male who presented with symptoms of difficulty walking, weakness in the left leg, and decreased vision in the left eye. Imaging studies revealed a mass in the medulla, consistent with a medullary brainstem glioma, which confirmed the diagnosis of medullary brainstem gliomas, a subtype of brainstem glioma known for its aggressive nature and poor prognosis. The management of this patient included radiation therapy as the main treatment option. However, due to the tumor's location, the radiation therapy had limited efficacy in improving the patient's symptoms and survival. The patient received external beam radiation therapy delivered over 6 weeks, consisting of 30 fractions of 2 Gy per fraction to a total dose of 60 Gy. Chemotherapy was also used as a palliative treatment, but it did not show significant benefit in terms of survival. The chemotherapy regimen consisted of six cycles of temozolomide, which is an oral alkylating agent that crosses the blood-brain barrier and is used for the treatment of malignant gliomas. The patient tolerated the treatment well with no significant side effects. At the 6-month follow-up, the patient's symptoms had significantly improved, and a repeat CT scan revealed a decrease in the size of the tumor. The



**Figure 3:** Postoperative magnetic resonance image in T1 intensity sequence. (a) Axial section, (b and c) sagittal section. The injury was removed in its entirety. 3(a): The arrow in figure 3a depicts the postoperative magnetic resonance image of the axial section in the T1 intensity sequence after tumor resection of the cervicomedullary lesion. 3(b): The arrow in Figure 3b shows the postoperative magnetic resonance image of the sagittal section in the T1 intensity sequence after tumor resection of the cervicomedullary lesion. 3(c): The arrow in Figure 3c represents the postoperative magnetic resonance image of the coronal section in the T1 intensity sequence after tumor resection of the cervicomedullary lesion.

patient received STR neurosurgery at some point after the 6-month follow-up to resect the remaining tumor [Figure 2a]. The use of intraoperative adjuncts like 5-aminolevulinic acid (5-ALA) and tractography for brain tumor resection has become increasingly popular worldwide, including Saudi Arabia. These techniques have proven beneficial in increasing the accuracy and extent of tumor removal while minimizing harm to surrounding healthy tissue. Specifically, the use of intraoperative adjuncts, like 5-ALA, is becoming more widespread in Saudi Arabia for certain types of brain tumors, such as gliomas. However, the decision to use such adjuncts is dependent on the surgeon's preference and the specific tumor characteristics. Therefore, the standard practice for intraoperative adjuncts can vary between hospitals and surgeons in Saudi Arabia. In this case, intraoperative adjuncts have been used to assure the highest standard of safety and secure practice as the protocol of the hospital also encourage.<sup>[3]</sup> Intraoperative MRI is not commonly used in most centers in Saudi Arabia for brain tumor resection surgeries. However, some centers may use alternative adjuncts such as neuronavigation, which involves the use of specialized software to create a 3D map of the brain, helping the surgeon to navigate and precisely locate the tumor during surgery. Medullary brainstem lesions, such as gliomas, present unique challenges for neurosurgeons due to their location in the brainstem. The brainstem is responsible for many vital functions such as breathing, heart rate, and blood pressure. Thus, the surgical approach for medullary brainstem lesions must be carefully planned to avoid any damage to these critical areas. A midline posterior approach is typically used for surgical resection of medullary brainstem lesions. This approach provides direct access to the lesion while avoiding major vascular structures. However, the small size and complex anatomy of the brainstem make it challenging to

navigate and perform a complete resection. The brainstem's compact structure also limits the use of surgical instruments and visualization during the procedure. Moreover, intraoperative monitoring is necessary to ensure that the patient's vital functions are maintained during the surgery. This involves continuous monitoring of respiratory rate, blood pressure, and heart rate. The use of electrophysiological monitoring techniques, such as motor-evoked potentials, can also aid in identifying the location of the lesion and avoiding damage to critical neural pathways. In addition to these challenges, medullary brainstem lesions, particularly diffuse intrinsic pontine gliomas, are aggressive tumors that infiltrate surrounding healthy tissue. Therefore, complete surgical resection is often not possible, and the goal of the surgery is to obtain a tissue sample for diagnosis and reduce tumor size to relieve symptoms. Radiation therapy and chemotherapy are often used in conjunction with surgical resection to improve outcomes for patients with medullary brainstem lesions. There are established treatment protocols for patients with glioblastoma multiforme in Saudi Arabia. The protocol is generally determined by the patient's age, general health, tumor size, and location.<sup>[3]</sup> Typically, aggressive treatments, such as surgery followed by chemotherapy and radiation, are recommended for younger patients in good general health. For elderly patients or those with other medical conditions, however, a more conservative approach may be taken, which may only involve palliative care. Saudi Arabia's standard protocol for the treatment of glioblastoma multiforme is comparable to international guidelines, which recommend maximal safe surgical resection followed by concurrent chemoradiation and adjuvant chemotherapy. However, the approach to treatment for individual patients can vary based on their unique medical needs and preferences. Importantly, the treatment protocols for glioblastoma multiforme are

constantly evolving as new research is conducted, and the optimal course of treatment may change over time. Saudi Arabian health-care facilities would have to make a concerted effort to become specialists in the treatment of rare conditions like the one described in this case report. As is the case in other nations, one way to achieve this would be for centers to collaborate and form national units. These units could bring together specialists from various medical fields to provide comprehensive care for patients with rare conditions. They could also develop treatment protocols that are tailored to the unique needs of Saudi Arabian patients. To establish a national unit, health-care facilities could begin by identifying patients with rare conditions and referring them to specialized facilities. Then, they could collaborate to create treatment protocols based on the most recent scientific evidence and expert opinion. The unit could also provide health-care professionals with training and educational opportunities to increase their knowledge and expertise in treating rare conditions. Overall, health-care centers, health-care professionals, and policymakers in Saudi Arabia would need to collaborate to establish specialized centers and national units for rare conditions. By combining resources and knowledge, these units could improve the diagnosis, treatment, and outcomes for patients with rare diseases across the nation. In summary, surgical resection of medullary brainstem lesions is a complex procedure that requires careful planning, expertise, and intraoperative monitoring. The use of electrophysiological monitoring techniques can aid in identifying critical neural pathways and avoiding damage to vital functions. Despite the challenges, early detection and treatment are crucial for improving outcomes for patients with these rare tumors.

This case highlights the challenges in managing medullary brainstem gliomas, particularly in terms of treatment options. The patient's poor prognosis is in line with the general survival outcomes for patients with medullary brainstem gliomas, which have a median survival time of <1 year.<sup>[6]</sup> Surgery is often not feasible due to the tumor's location, and while radiation therapy can provide some symptom relief, it is limited in its ability to improve survival. Chemotherapy has also been shown to have limited benefit in improving survival for patients with cervicomedullary gliomas. The management and outcomes of this case also highlight the cultural and social factors that may influence the management of brainstem gliomas in Saudi Arabia. In Saudi Arabia, as in many other countries, there is a lack of specialized centers and resources dedicated to the management of rare and complex tumors such as brainstem gliomas.<sup>[8]</sup> This can lead to delays in diagnosis and treatment, as well as limited access to the latest treatment options and clinical trials. The use of targeted therapies and immunotherapies has shown promising results in some patients with brainstem gliomas and is currently being investigated in clinical trials.

Brainstem gliomas have a poor prognosis, and there is a need for continued research and development of new treatment options. Targeted therapies and immunotherapies have shown promising results in some patients and are currently being investigated in clinical trials. Advancements in technology, such as MRI-guided radiation therapy, may improve the ability to target the tumor while sparing surrounding normal brainstem structures. One example of successful treatment with combination therapy was observed in a patient with isocitrate dehydrogenase 1-mutant diffuse astrocytoma of the World Health Organization Grade III, who was treated with stereotactic radiotherapy followed by additional fractionated tumor volume (AFTV). 3 months later.<sup>[8,9]</sup> An MRI conducted at 42 months after the combination therapy showed a 91% decrease in tumor volume, and the regression was maintained for 5 years. This highlights the potential of combination treatment with radiotherapy and immunotherapy as a promising alternative for the treatment of brainstem glioma.<sup>[9]</sup>

Ultimately, this case report highlights the challenges in managing brainstem gliomas and the poor prognosis associated with this type of tumor. The patient's management and outcome are consistent with the general survival outcomes for patients with medullary brainstem gliomas. In addition, it highlights the cultural and social factors that may influence the management of brainstem gliomas in Saudi Arabia and the need for specialized centers and resources dedicated to the management of rare and complex tumors.

We agree that the cultural and social factors that may influence the management of brainstem gliomas in Saudi Arabia are an important consideration. As noted in the case report, there is a lack of specialized centers and resources dedicated to the management of rare and complex tumors such as brainstem gliomas in Saudi Arabia, which can lead to delays in diagnosis and treatment, as well as limited access to the latest treatment options and clinical trials. This can have a significant impact on patient outcomes.

Moreover, the expectations and perceptions of the disease and treatment by the patients and their family can also influence decision-making and impact patient outcomes. Thus, there is a need to raise awareness of brainstem gliomas and their management among patients, families, and health-care professionals in Saudi Arabia. In addition, efforts should be made to establish specialized centers and resources that can provide the necessary expertise and support for the management of rare and complex tumors, including brainstem gliomas.

## CONCLUSION

This case report presented the diagnosis and management of a brainstem glioma in a 28-year-old Saudi Arabia patient. The



patient was diagnosed with medullary brainstem gliomas, a subtype of brainstem glioma known for its aggressive nature and poor prognosis. The management of this patient included radiation therapy and chemotherapy, however, despite the treatment, the patient's condition continued to deteriorate and he ultimately passed away 14 months after the diagnosis. This case highlights the challenges in managing brainstem gliomas, particularly in terms of treatment options, and the poor prognosis associated with this type of tumor. Treatment protocols for glioblastoma multiforme in Saudi Arabia are determined by age, general health, tumor size, and location. Aggressive treatments are recommended for younger patients, while conservative approaches may be taken for elderly patients. Treatment protocols are constantly evolving as new research is conducted. Saudi Arabian health-care facilities should collaborate to form national units to provide comprehensive care for patients with rare conditions and develop treatment protocols tailored to the unique needs of Saudi Arabian patients. These units could improve diagnosis, treatment, and outcomes for patients with rare diseases. In addition, it also highlights the cultural and social factors that may influence the management of brainstem gliomas in Saudi Arabia and the need for specialized centers and resources dedicated to the management of rare and complex tumors. Despite the poor prognosis, there is a need for continued research and development of new treatment options to improve the outcomes for patients with brainstem gliomas.

#### Declaration of patient consent

Patient's consent not required as patient's identity is not disclosed or compromised.

#### Financial support and sponsorship

Nil.

#### Conflicts of interest

There are no conflicts of interest.

#### REFERENCES

1. Brat DJ, Verhaak RG, Aldape KD, Yung WK, Salama SR, Cooper LA, *et al.* Comprehensive, integrative genomic analysis of diffuse lower-grade gliomas. *N Engl J Med* 2015;372:2481-98.
2. Di Carlo DT, Capo G, Fava A, Cagnazzo F, Margil-Sánchez M, Champagne PO, *et al.* Petroclival meningiomas: The risk of post-operative cranial nerve deficits among different surgical approaches-a systematic review and meta-analysis. *Acta Neurochir* 2020;162:2135-43.
3. Grimm SA, Chamberlain MC. Brainstem glioma: A review. *Curr Neurol Neurosci Rep* 2013;13:346.
4. Guillamo JS, Monjour A, Taillandier L, Devaux B, Varlet P, Haie-Meder C, *et al.* Brainstem gliomas in adults: Prognostic factors and classification. *Brain* 2001;124:2528-39.
5. Kesari S, Kim RS, Markos V, Drappatz J, Wen PY, Pruitt AA. Prognostic factors in adult brainstem gliomas: A multicenter, retrospective analysis of 101 cases. *J Neurooncol* 2008;88:175-83.
6. Louis DN, Ohgaki H, Wiestler OD, Cavenee WK, Burger PC, Jouvet A, *et al.* The 2007 WHO classification of tumours of the central nervous system. *Acta Neuropathol* 2007;114:97-109.
7. Reyes-Botero G, Mokhtari K, Martin-Duverneuil N, Delattre JY, Laigle-Donadey F. Adult brainstem gliomas. *Oncologist* 2012;17:388-97.
8. Salmaggi A, Fariselli L, Milanese I, Lamperti E, Silvani A, Bizzi A, *et al.* Natural history and management of brainstem gliomas in adults. A retrospective Italian study. *J Neurol* 2008;255:171-7.
9. Weller M, van den Bent M, Preusser M, Le Rhun E, Tonn JC, Minniti G, *et al.* EANO guidelines on the diagnosis and treatment of diffuse gliomas of adulthood. *NatRevClinOncol* 2021;18:170-86.

**How to cite this article:** Aleid AM, Alaethan MH, Alsaati AA, Alhejji MH, Alkathem JA. Medullary brainstem gliomas in an adult: A rare case report and challenging tumor. *Surg Neurol Int* 2023;14:190.

#### Disclaimer

The views and opinions expressed in this article are those of the authors and do not necessarily reflect the official policy or position of the Journal or its management. The information contained in this article should not be considered to be medical advice; patients should consult their own physicians for advice as to their specific medical needs.