



Arthroscopy Primary Double-Bundle Repair of Anterior Cruciate Ligament With Internal Brace Augmentation and a Knotless Anchor Implant

Lilian Zhao, Ph.D., Mingfeng Lu, M.D., Mingcong Deng, M.D., Jisi Xing, M.D., and Ting Xu, M.D.

Abstract: The primary repair technique of acute anterior cruciate ligament (ACL) tears has been controversially discussed over the past few decades. Many different suture techniques have been reported for ACL repair, but these procedures showed high re-rupture rates and poor results. Recently, the literature has reported excellent outcomes with primary ACL repair. There has been a resurging interest in modernizing and augmenting primary ACL repair. This article describes a technique that uses internal brace augmentation and a knotless anchor (Arthrex) implant for primary anatomic double-bundle ACL repair after an acute proximal ACL tear. This technique aims to advocate natural healing by the high-strength internal brace augmentation and knotless anchor as a provisional scaffold during the healing phase and early mobilization. This technique might be an alternative to conventional ACL reconstruction in the appropriate selection of patients.

Anterior cruciate ligament (ACL) tear is one of the most common sports injuries.¹ ACL reconstruction has been the standard treatment for an ACL rupture to avoid instability and subsequent meniscus and cartilage tears.² However, a range of complications becomes increasingly apparent after ACL reconstruction, such as weakened hamstring muscle strength, pain in the anterior tibial region, weak recovery of proprioception, and the low ratio of patients returning to sports.³⁻⁵ Contemporary ACL repair techniques have attracted more interest in recent years. Recent literature has reported good outcomes with primary ACL repair.^{6,7} However, strict patient selection for ACL

repair must be considered for it to succeed. Some studies have confirmed that acute Sherman type 1 tear patterns of the femoral avulsion are the best indication.⁸⁻¹⁰

As the popularity of primary ACL repair grows, practical repair techniques are urgently needed. This article describes a repair technique, primary anatomic double-bundle ACL reparation, which applies to acute Sherman type 1 tear patterns of the femoral avulsion, using high-strength internal brace augmentation and a knotless anchor as a provisional scaffold during the healing phase, as well as early mobilization.

Surgical Technique (With Video Illustration)

General Recommendations

We recommend this technique for patients with acute proximal avulsion-type ACL injuries. According to the Sherman method, which classifies the injuries, Sherman type 1 (Fig 1) tear is the best indication. Acute mid-substance ACL injury of Sherman type 2 or 3 not suitable (Table 1).¹¹

General Preparation

The patient is placed in the supine position (Video 1), with a tourniquet inflated to 260 mm Hg. Then, an anterolateral viewing and anteromedial (AM) working portal are established to start standard arthroscopy. In addition, a far AM portal also can be added as necessary.

From the Department of Sports Medicine, Foshan Hospital of Traditional Chinese Medicine, Guangzhou University of Chinese Medicine, Foshan (L.Z., M.L., J.X., T.X.); and Guangzhou University of Traditional Chinese Medicine, Guangzhou, Guangdong province, Guangzhou (M.D.), China.

The authors report that they have no conflicts of interest in the authorship and publication of this article. Full ICMJE author disclosure forms are available for this article online, as [supplementary material](#).

Received March 3, 2020; accepted August 3, 2020.

Address correspondence to Dr. Mingfeng Lu, M.D., Sports Medicine Department, Foshan TCM Hospital of Guangzhou University of Chinese Medicine, No. 6, Qin Ren Rd., Chan Cheng District, 528000, Foshan City, Guangdong Province, China. E-mail: 17820185108@163.com

© 2020 by the Arthroscopy Association of North America. Published by Elsevier. This is an open access article under the CC BY-NC-ND license (<http://creativecommons.org/licenses/by-nc-nd/4.0/>).

2212-6287/20307

<https://doi.org/10.1016/j.eats.2020.08.025>

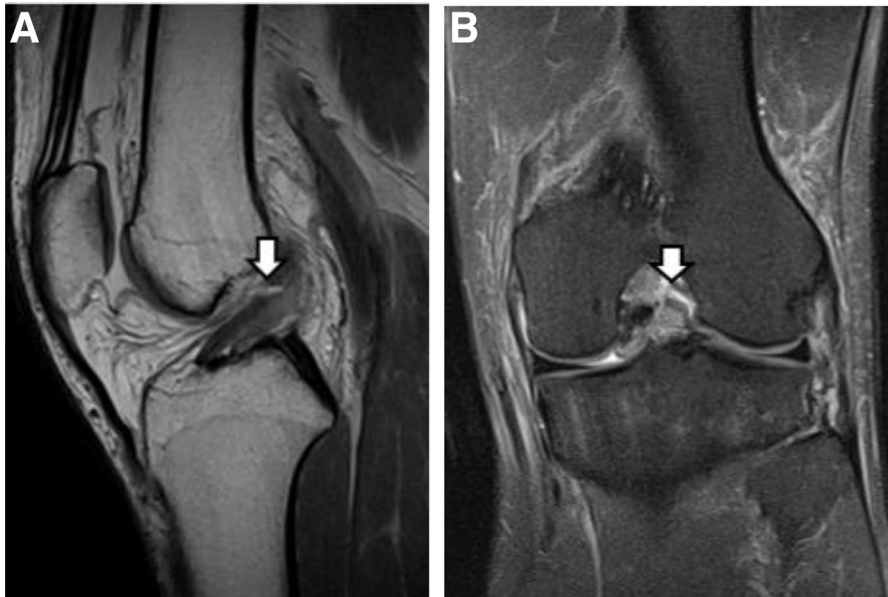


Fig 1. Sagittal (A) and coronal (B) magnetic resonance imaging of left knee showing Sherman type 1 tear patterns of the femoral avulsion (arrows).

ACL Inspection

With the scope placed in the anterolateral portal, assessment of tissue length and tissue quality is made for the primary repair technique during the general inspection of the knee (Video 1). If the AM bundle and posterolateral (PL) bundle have sufficient length and good tissue quality is confirmed (Fig 2 A and B), it is saved and used for the associated repair.

Internal Brace Preparation

The 15-mm ENDOBUTTON (Smith & Nephew, Andover, MA) is selected.⁶ ULTRABRAID sutures (Smith & Nephew) are suspended on the loop (Fig 3 and Video 1).

Suturing of ACL Bundles and ACL Fixation

First, the AM and PL bundles are identified. A Scorpion Suture Passer (Depuy Mitek, Inc., Raynham, MA) is used to pass a No. 2 ULTRABRAID suture (Smith & Nephew) proximally in the AM bundle in an alternating fashion (Fig 4 A and B). The same process is repeated for the PL bundle using a No. 2 ULTRABRAID suture (Smith & Nephew) (Fig 4 C and D). The suture is passed across the ACL from the

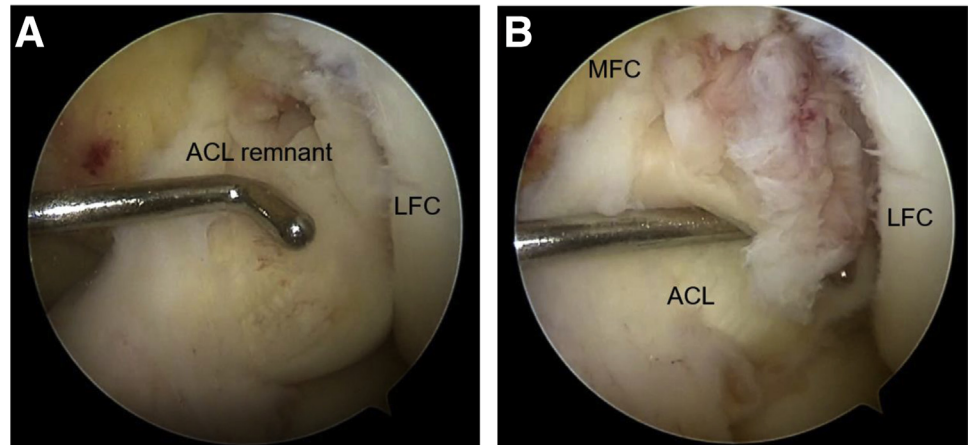
middle one third to the proximal and from medial to lateral.

A wire gripper (Arthrex) is used to retract the ligament away, as it allows better visibility of the femoral footprint. Approaching from the AM portal, a 30° microfracture awl (Smith & Nephew) is inserted (Fig 5). Multiple holes are made respectively in the AM and PL footprint of the ACL at 90° and 120° of knee flexion with the awl to stimulate bone marrow extravasation. To guide the femoral footprint area of the AM bundle, a 6.5-mm offset guide is used (Arthrex, Naples, FL) to drill a femoral tunnel by 2.0-mm guidewire (Fig 6 A and B) and then reamed with a 4.5-mm hollow drill (Arthrex) in an anatomic manner (Fig 6C) at the femoral footprint of the AM bundle with 120° knee flexion. Bony debris is removed; a passing suture for later use is placed in the femoral tunnel and brought out the AM portal as a passing wire. One suture of the braided AM bundle is passed across the loop, and then the internal brace augmentation is pulled intra-articularly along with the passing wire (Fig 7A). Under the monitoring of an arthroscope (Smith & Nephew), pull out from the femoral tunnel and make the loop plate across the femoral cortex (Fig 7B) and then guide the femoral footprint of the PL bundle with 120° of knee flexion. To ensure that the location is close to the cartilage edge of the femoral condyle, use the 4.0-mm anchor tap (Arthrex) to create a site for anchor placement at the PL bundle of the native ACL femoral footprint (Fig 8A). The sutures of the braided PL bundle pierced through the 4.5-mm knotless suture implant (Arthrex). The anchor (Arthrex) is inserted into place (Fig 8B); a gentle pull on the repair suture helps seat

Table 1. Sherman classification¹¹

Type	
Type 1	Tears are defined as true soft-tissue avulsions with minimal ligament tissue left on the femur
Type 2	Tears have up to 20% of the tissue left on the femur
Type 3	Tears have up to 33%
Type 4	Tears are correlated as true midsubstance tears.

Fig 2. Left knee viewed from the anterolateral portal with the patient supine and the knee in 90° of flexion. (A) Probing of the ACL reveals a Sherman type 1 tear of the ACL; (B) the posterolateral bundle and parts of the anteromedial bundle show no fraying and excellent quality. (ACL, anterior cruciate ligament; LFC, lateral femoral condyle; MFC, medial femoral condyle.)



this implant. Then, the suture of the braided AM bundle is knotted with pushing the junction device (Smith & Nephew) (Fig 9A). Finally, the excess suture is cut using an arthroscopic suture cutter (Smith & Nephew) (Fig 9B).

Subsequently, attention is now turned to the tibial side. According to the C-type structure of the tibial footprint of the ACL, determine the position of the 2 tibial tunnels of the AM bundle with a 50° tibial aiming device (Smith & Nephew). After a longitudinal skin incision is established on the AM side of the proximal tibia, tibial tunnels are drilled in the anterior and medial tibial footprint of ACL (Fig 10 A and B). Then, the SutureLasso is used to lead out the internal brace, respectively (Fig 10 C and D). All the high-strength wires are passed through another ENDOBUTTON (Smith & Nephew) (Fig 11), then tied and fixed at the tibial tunnel entrance.

Finally, the knee is cycled through its range of motion to test for impingement. Once it is deemed




Fig 3. The 15-mm ENDOBUTTON (Smith & Nephew) (arrow) and 12-strand ULTRABRAID suture (star) (Smith & Nephew), used as high-strength internal brace augmentation.

that the position of the repaired ACL is suitable, the incisions are closed. The anterior drawer test and the Lachman test should be checked again. Pearls and pitfalls of this technique are shown in Table 2.

Rehabilitation

Patients are allowed to fully bear weight for the first 4 weeks postoperatively. Quadriceps contraction, straight leg raising, and ankle pump exercises are started after the operation. Under the protection of the brace, the knee joint is maintained at 0 to 90° for 4 weeks. After 4 weeks, the patient starts a progressive range of motion and strengthening. A gradual return to sports is allowed at approximately 9 months to 1 year postoperatively.

Discussion

Primary repair of the acute ACL tears has been discussed controversially in the past.¹² Although some authors reported the promising short-term outcomes of ACL primary repair, the mid-term results appeared to be disappointing.^{13,14} With the development of successful ACL-reconstruction techniques, ACL repair was abandoned during the 1990s.¹⁵ However, with modern technological advances in arthroscopic surgery, advances in rehabilitation, and strict patient selection, primary ACL repair has seen renewed interest.¹⁶ Recently, some authors have shown promising outcomes after primary repair of proximally avulsed ACL tears.¹⁰ This technique describes arthroscopy primary double-bundle repairing by high-strength internal brace augmentation and a knotless anchor as a provisional scaffold during the healing phase.

For most ACL-repair techniques, patient selection is restricted to patients with proximal tears of Sherman type 1.¹¹ Compared with other ACL primary repair techniques, the critical feature of the double-bundle

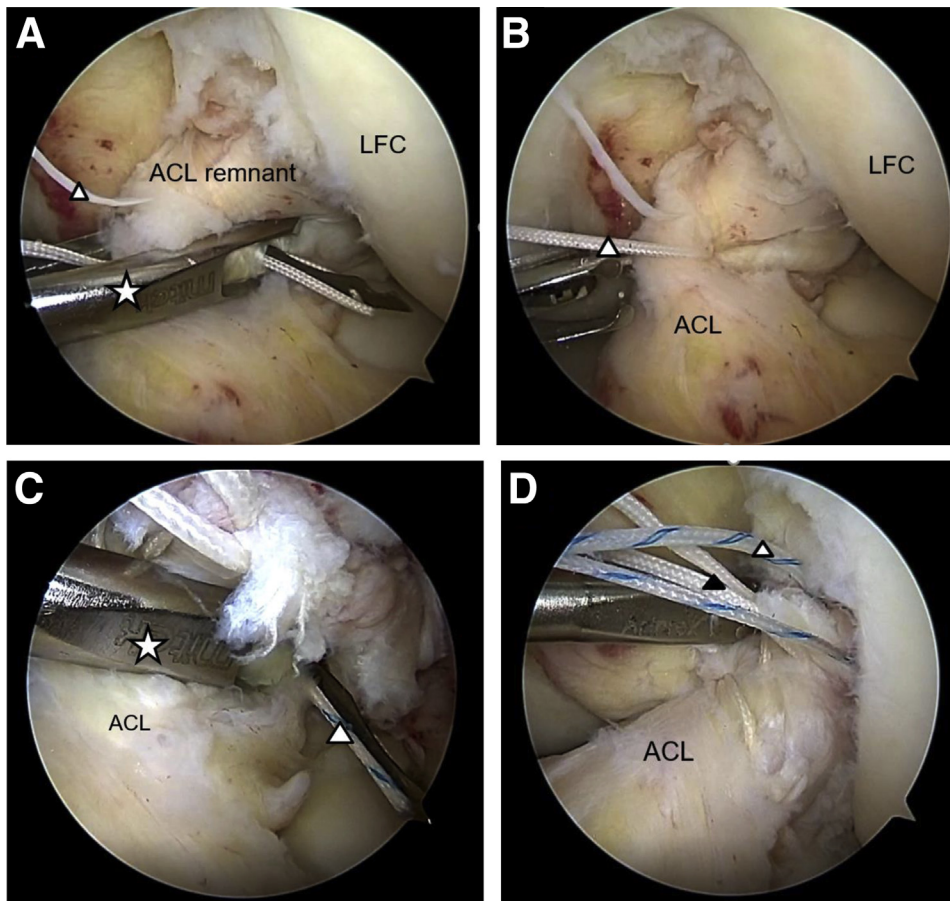


Fig 4. (A) Left knee viewed from the anterolateral portal with the patient supine and the knee in 90° of flexion showing the first suture of the AM bundle using a Scorpion Suture Passer (Depuy Mitek, star). (B) Frontal view of the left knee through anterolateral portal showing white high-strength tape (ULTRABRAID, triangle) passing through the AM bundle of ACL stump. (C) Frontal view of the left knee through the anterolateral portal showing the second blue high-strength tape (ULTRABRAID, triangle) of the PL bundle using a scorpion suture passer (Depuy Mitek, star). (D) Left knee viewed from the anterolateral portal showing that the 2 bundles of the ACL have been sutured with 2-strand high-strength tape (ULTRABRAID, triangle). (ACL, anterior cruciate ligament; LFC, lateral femoral condyle.)

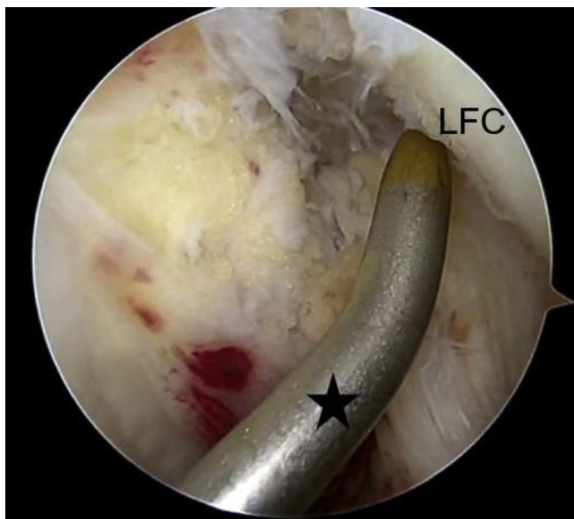
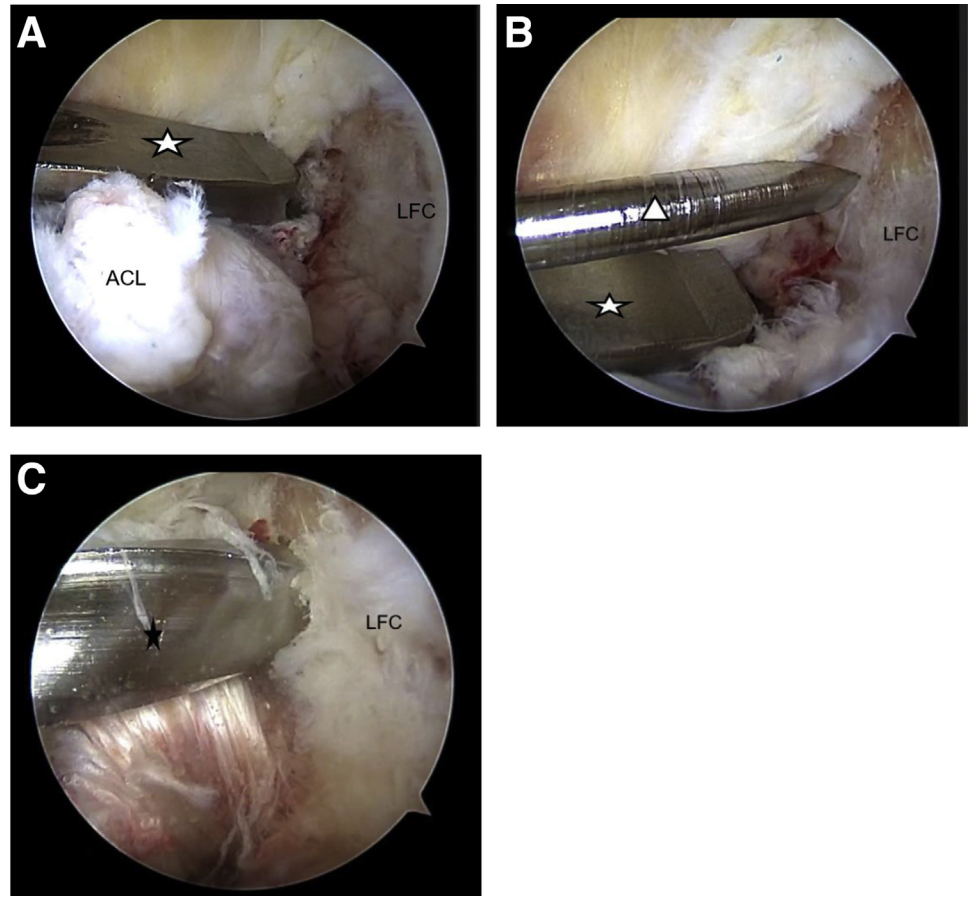


Fig 5. Approaching from the AM portal, a 30° microfracture awl (Smith & Nephew, star) is inserted. Multiple holes are made respectively in the AM and PL bundle footprint of the ACL at 90° and 120° of knee flexion with the awl to stimulate bone marrow extravasation. (ACL, anterior cruciate ligament; AM, anteromedial; PL, posterolateral.)

repair technique is using No. 2 6 ULTRABRAID suture (Smith & Nephew) as high-strength internal brace augmentation. The 12-strand ULTRABRAID suture (Smith & Nephew) provides a temporary scaffold to eliminate gap formation. The strength of 1-strand ULTRABRAID suture (Smith & Nephew) is about 294 N. Twelve strands of the high-strength suture is about 3528 N, whereas the ultimate tensile strength of standard ACL is 2020 ± 264 N.¹⁷ This construct theoretically adds strength to the biomechanical properties of the ACL through the addition of the tape. The suture scaffold will contribute to creating a stable fibrin–platelet clot, which can make the ruptured ends of the ACL heal.¹⁸

Another feature of this technique is the preservation of the patient's original double-bundle ACL. This technique can avoid some surgical complications of ACL reconstruction and other repair techniques, such as donor-site pain after harvesting tendons, loss of vascularity, and destruction of proprioceptive fibers.¹⁶ Experimental studies have shown that the native ACL has proprioceptive receptors, and patients with ACL-deficient knees have known loss of

Fig 6. (A-B) Left knee viewed from the anterolateral portal showing the use of a 6.5-mm offset guide (Smith & Nephew) to drill a femoral tunnel by 2.0-mm guidewire. (C) Left knee viewed from the anterolateral portal showing the ream with a 4.5-mm hollow drill in an anatomic manner at the femoral footprint of the anteromedial bundle with 90° knee flexion. (ACL, anterior cruciate ligament; LFC, lateral femoral condyle.)



proprioception.¹⁹⁻²¹ What is more, some studies have confirmed that proprioception correlates better with postoperative function and satisfaction than

mechanical stability.²² Furthermore, this technique preserves the native ligament tissue to maintain blood supply and native biology, and retaining the synovial

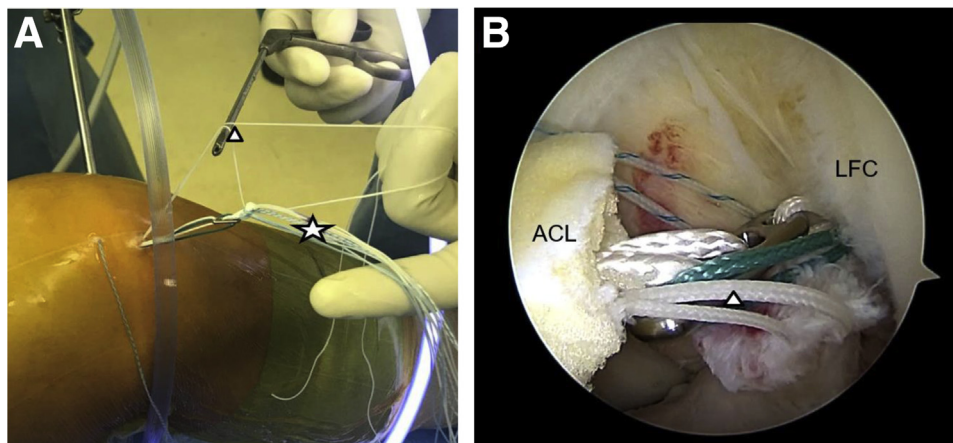


Fig 7. (A) A passing suture for later use is placed in the femoral tunnel and brought out the anteromedial portal as a passing wire. One suture (ULTRABRAID, triangle) of the braided anteromedial bundle is passed across the loop. The internal brace augmentation (star) is pulled into the intra-articular of the knee joint cavity along with the passing wire (B). Under the monitoring of an arthroscope (Smith & Nephew), pull out from the femoral tunnel and sit on the femoral cortex. (ACL, anterior cruciate ligament; LFC, lateral femoral condyle.)

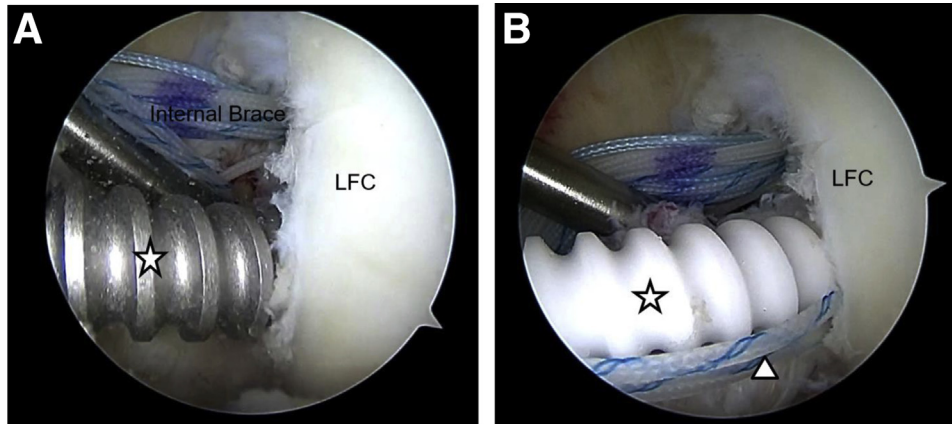


Fig 8. (A) Frontal view of left knee through the anterolateral portal showing the use of the 4.0-mm anchor tap (star) to create a site for anchor placement at the PL bundle of native ACL femoral footprint. (B) Frontal view of left knee through the anterolateral portal showing that the suture of the braided posterolateral bundle (ULTRABRAID, triangle) was pierced through the 4.5-mm knotless suture implant (Arthrex, star). Without removal of the drill guide, a 4.5-mm knotless suture implant (Arthrex) is inserted into place; a gentle pull on the repair suture helps seat this implant. (ACL, anterior cruciate ligament; LFC, lateral femoral condyle.)

sheath also plays a significant role in vascularization and cell proliferation.

Some studies have supported these theoretical advantages by reporting excellent outcomes after different repair techniques. Some studies have shown that ACL repair combined with dynamic augmentation technology or knotless suture anchor technology for ACL injury has achieved success.^{23,24} Hoffmann et al.²⁵ advocated for single suture anchor re-fixation of ACL proximal avulsion tears leads. They reported stable clinical and radiologic healing in 12 patients. In addition, there are many other repair techniques, such as the internal bracing and biologic healing. However, all these techniques are different from the current technique. This technique does not require harvesting of tendons. Instead, the whole distal stump of the ACL is brought to its femoral footprint

on the lateral notch wall with a provisional scaffold and static augmentation of the internal brace. One of the disadvantages of this technique is the risk of potential for overconstraining the joint (Table 3). There is a certain degree of technical difficulty, and a specific learning curve is needed. Compared with other techniques described in this article, the superior outcomes of our repair technique are still a matter of further research.

With the development of new arthroscopic techniques and the comprehension of the underlying ACL biology, we believe that application of the high-strength internal brace augmentation and a knotless anchor as a provisional scaffold can protect the ligament and reduce the failure rate of operation in the period of ligament fragility, although its clinical effect needs further study.

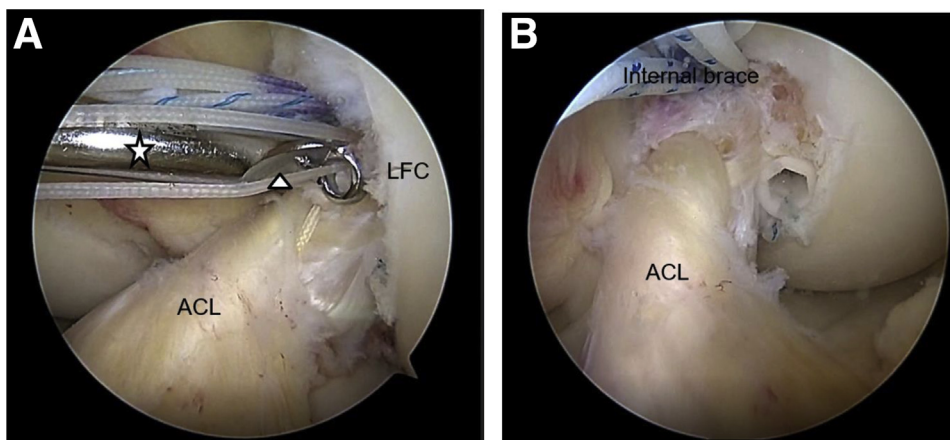


Fig 9. (A) Frontal view of the left knee through the anterolateral portal showing that the suture (ULTRABRAID, triangle) of the braided AM bundle is knotted with pushing of the junction device (Smith & Nephew, star). (B) Frontal view of the left knee through the anterolateral portal showing that the excess suture is cut using an arthroscopic suture cutter. (ACL, anterior cruciate ligament; AM, anteromedial; LFC, lateral femoral condyle.)

Fig 10. (A-B) Left knee viewed from the anterolateral portal showing the guiding of the position of the 2 tibial tunnels of the anteromedial bundle with a tibial-aiming device (Smith & Nephew, star) according to the C-type structure of tibial footprint of the ACL. Tibial tunnels are drilled in the anterior and medial tibial footprints of ACL. (C-D) Left knee viewed from the anterolateral portal showing the use of the SutureLasso (Smith & Nephew, star) to lead out the internal brace (ULTRABRAID, triangle), respectively.

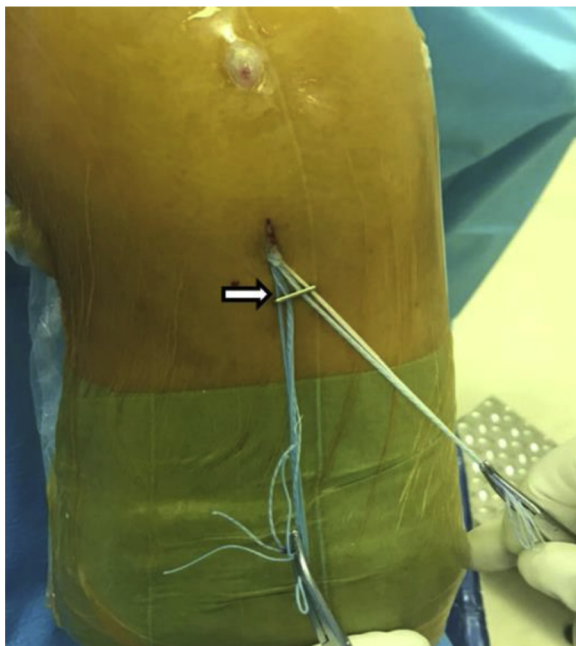
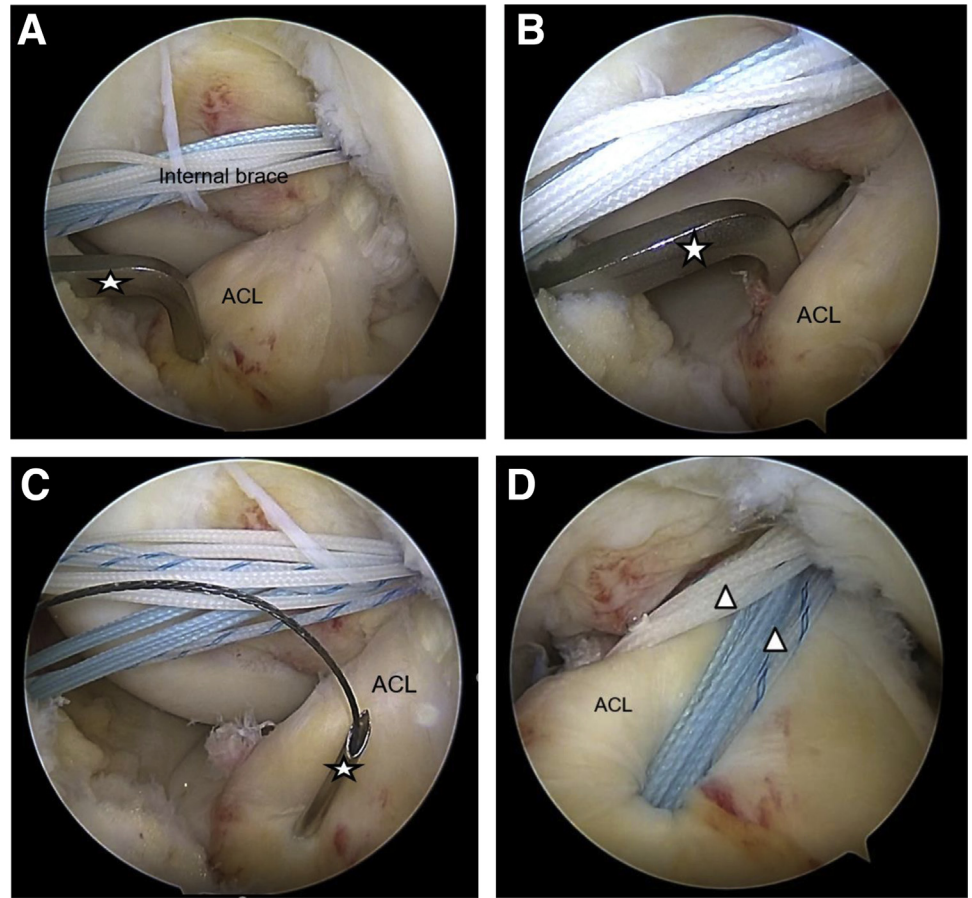


Fig 11. All the high-strength wires are passed through another ENDOBUTTON (Smith & Nephew, arrow), then tied and fixed at the tibial tunnel entrance.

Table 2. Pearls and Pitfalls of Double-Bundle Repair of the ACL With Internal Brace Augmentation and a Knotless Suture Implant

Pearls and Pitfalls
<ul style="list-style-type: none"> Establishing a far anteromedial portal as a grasping approach is helpful for the management of sutures during the operation. Use the probe to reset the ACL stump according to its anatomic direction during the process of suture ACL, which helps to distinguish the anteromedial bundle from the posterolateral bundle of the ACL. The internal brace is marked with different-colored sutures, and the end of the same suture is marked. The guide of the posterolateral bundle is lower and close to the cartilage margin, and the anchor has less obstruction to the tendon–bone interface. Fix the appropriate position of the internal brace in the process of knee flexion and extension. Otherwise, it will limit the flexion and extension of the knee. Take care not to damage the remnant while drilling the tibial tunnel. Avoid inappropriate selection of patients on whom ACL repair is performed. Inadequately tensioning the remnant increases the risk of a cyclops lesion.

ACL, anterior cruciate ligament.

Table 3. Advantages and Disadvantages of Double-Bundle Repair of the Anterior Cruciate Ligament With Internal Brace Augmentation and a Knotless Suture Implant

Advantages	Disadvantages
Maintains the anatomical structure of the ACL and proprioceptive sensation	Possible stress shielding of repaired ACL
Enhances the mechanical properties of the repaired ACL and protects repaired ACL during the healing process	Potential for overconstraining the joint
Allows for accelerated rehabilitation	There is a certain degree of technical difficulty, and a certain learning curve is needed.
The bone mass and ACL stump are preserved, providing conditions for ACL reconstruction after failed ACL repair.	It is necessary to take enough ACL remnant to avoid failure.
Biocompatibility	

ACL, anterior cruciate ligament.

References

- Sanders TL, Maradit Kremers H, Bryan AJ, et al. Incidence of anterior cruciate ligament tears and reconstruction. *Am J Sports Med* 2016;44:1502-1507.
- Carey JL, Dunn WR, Dahm DL, Zeger SL, Spindler KP. A systematic review of anterior cruciate ligament reconstruction with autograft compared with allograft. *J Bone Joint Surg Am* 2009;91:2242-2250.
- Sanders TL, Pareek A, Hewett TE, et al. Long-term rate of graft failure after ACL reconstruction: A geographic population cohort analysis. *Knee Surg Sports Traumatol Arthrosc* 2017;25:222-228.
- Spindler KP, Kuhn JE, Freedman KB, et al. Anterior cruciate ligament reconstruction autograft choice: Bone-tendon-bone versus hamstring: Does it really matter? A systematic review. *Am J Sports Med* 2004;32:1986-1995.
- Harris JD, Abrams GD, Bach BR, et al. Return to sport after ACL reconstruction. *Orthopedics* 2014;37:103-108.
- Achtmich A, Herbst E, Forkel P, et al. Acute proximal anterior cruciate ligament tears: Outcomes after arthroscopic suture anchor repair versus anatomic single-bundle reconstruction. *Arthroscopy* 2016;32:2562-2569.
- Gobbi A, Whyte GP. Long-term outcomes of primary repair of the anterior cruciate ligament combined with biologic healing augmentation to treat incomplete tears. *Am J Sports Med* 2018;46:3368-3377.
- van der List JP, DiFelice GS. Primary repair of the anterior cruciate ligament: A paradigm shift. *Surgeon* 2017;15:161-168.
- Jonkergouw A, van der List JP, DiFelice GS. Arthroscopic primary repair of proximal anterior cruciate ligament tears: Outcomes of the first 56 consecutive patients and the role of additional internal bracing. *Knee Surg Sport Traumatol Arthrosc* 2019;27:21-28.
- van der List JP, Vermeijden HD, Sierevelt IN, et al. Arthroscopic primary repair of proximal anterior cruciate ligament tears seems safe but higher level of evidence is needed: A systematic review and meta-analysis of recent literature. *Knee Surg Sports Traumatol Arthrosc* 2020;28:1946-1957.
- Sherman MF, Lieber L, Bonamo JR, et al. The long-term follow-up of primary anterior cruciate ligament repair. Defining a rationale for augmentation. *Am J Sports Med* 1991;19:243-255.
- Taylor DC, Posner M, Curl WW, Feagin JA. Isolated tears of the anterior cruciate ligament: Over 30-year follow-up of patients treated with arthrotomy and primary repair. *Am J Sports Med* 2009;37:65-71.
- Hirschmann MT, Müller W. Complex function of the knee joint: The current understanding of the knee. *Knee Surg Sports Traumatol Arthrosc* 2015;23:2780-2788.
- Taylor SA, Khair MM, Roberts TR, DiFelice GS. Primary repair of the anterior cruciate ligament: A systematic review. *Arthroscopy* 2015;31:2233-2247.
- Mahapatra P, Horriat S, Anand BS. Anterior cruciate ligament repaired past, present and future. *J Exp Orthop* 2018;5:20.
- Youssefzadeh KA, Stein S, Limpisvasti O. Anterior cruciate ligament repair using a knotless suture implant. *Arthrosc Tech* 2020;9:623-626.
- Musahl V, Lehner A, Watanabe Y, et al. Biology and biomechanics. *Curr Opin Rheumatol* 2002;14:127-133.
- Perrone GS, Proffen BL, Kiapour AM, Sieker JT, Fleming BC, Murray MM. Bench-to-bedside: Bridge enhanced anterior cruciate ligament repair. *J Orthop Res* 2017;35:2606-2612.
- Fromm B, Kummer W. Nerve supply of anterior cruciate ligaments and of cryopreserved anterior cruciate ligament allografts: A new method for the differentiation of the nervous tissues. *Knee Surg Sport Traumatol Arthrosc* 1994;2:118-122.
- Kim HJ, Lee JH, Lee DH. Proprioception in patients with anterior cruciate ligament tears: A meta-analysis comparing injured and uninjured limbs. *Am J Sports Med* 2017;45:2916-2922.
- Relph N, Herrington L, Tyson S. The effects of ACL injury on knee proprioception: A meta-analysis. *Physiotherapy* 2014;100:187-195.
- Barret DS. Proprioception and function after anterior cruciate reconstruction. *J Bone Joint Surg B* 1991;73:833-837.
- Schliemann B, Glasbrenner J, Rosenbaum D, et al. Changes in gait pattern and early functional results after ACL repair are comparable to those of ACL reconstruction. *Knee Surg Sports Traumatol Arthrosc* 2018;26:374-380.

24. Hoogeslag RAG, Brouwer RW, Boer BC, de Vries AJ, Huis in 't Veld R. Acute anterior cruciate ligament rupture: Repair or reconstruction? Two-year results of a randomized controlled clinical trial. *Am J Sports Med* 2019;47:567-577.
25. Hoffmann C, Friederichs J, von Ruden C. Primary single suture anchor re-fixation of anterior cruciate ligament proximal avulsion tears leads to good functional midterm results: A preliminary study in 12 patients. *J Orthop Surg Res* 2017;12:171.