

PEDIATRIC UROLOGY
ORIGINAL ARTICLE

Clitoroplasty: A variant of the technique by Acimi

Smail Acimi^{a,*}, Mohammed Ali Acimi^a, Lamia Debbous^a, Mimouna Bessahraoui^b,
Ibtissem Bouanani^c

^a Department of Visceral Surgery, Children's Hospital Canastel, Faculty of Medicine, University of Oran, Oran, Algeria

^b Gastroenterology and Endocrinology, Children's Hospital Canastel, Faculty of Medicine, University of Oran, Oran, Algeria

^c Department of Pediatric Surgery, CHU of Sidi Bel Abbes, University of Sidi Bel Abbes, Sidi Bel Abbes, Algeria

Received 23 October 2017, Received in revised form 12 December 2017, Accepted 23 December 2017

Available online 22 February 2018

KEYWORDS

Disorders of sex development;
Ambiguous genitalia;
Feminising genitoplasty;
Clitoroplasty;
46,XX DSD;
Ovotesticular DSD

ABBREVIATION

DSD, disorders of sex development

Abstract Objectives: To evaluate the mid-term results of clitoroplasty through the reduction of the length and diameter of the corpus cavernosum, as well as the volume of the glans.

Patients and methods: From October 2003 to July 2015, we performed 29 clitoroplasties using the described procedure. The median (range) age of the patients was 18 (3–47) months. After surgery we evaluated the volume of the clitoris, the appearance of glans, and its sensitivity to light touch, pressure, and pain.

Results: The length of the apparent part of the glans remained large (> 10 mm) in four patients (14%), was an average size (between 5 and 10 mm) in 11 (39%), and small (< 5 mm) in 13 (46%). The length of the corpus cavernosum was < 20 mm and its diameter < 5 mm in all cases. The sensitivity of the reduced clitoris to touch, pressure and pain seemed normal in all patients. In addition, we never found the circumflex arteries and nerves of the penis (on histological examination of excised pieces of corpus cavernosum) in all children operated on during the first 3 years of life. The circumflex arteries of the penis begin to develop, only after the fourth year. This anatomical finding is an argument for performing clitoroplasty at an early age to avoid any risk of intraoperative and postoperative bleeding.

* Corresponding author. Fax: +213 41431115.

E-mail address: acimi_smail@yahoo.fr (S. Acimi).

Peer review under responsibility of Arab Association of Urology.



Production and hosting by Elsevier

Conclusions: The sensitivity of the clitoral glans appeared to be normal in all cases, with a good cosmetic appearance of the external genitalia in most patients.

© 2018 Production and hosting by Elsevier B.V. on behalf of Arab Association of Urology. This is an open access article under the CC BY-NC-ND license (<http://creativecommons.org/licenses/by-nc-nd/4.0/>).

Introduction

Disorders of sex development (DSD) or ambiguous genitalia are states in which the appearance of the external genitalia of a new-born, does not resemble that of a girl or a boy, but rather a form between the two. However, this definition remains incomplete. There are patients with DSD who have well-developed external genitalia, but the phenotype does not correspond to the genetic sex. In such cases, this is usually discovered later, at puberty.

In patients with 46,XX DSD and some other forms of DSD, the female gender is proposed and surgical correction should be performed as early as possible. Feminising genitoplasty includes clitoroplasty, creating a labia minora, and vaginoplasty.

In the past, the hypertrophied clitoris was excised (clitorrectomy) [1,2]. However, the glans is an important erotic sensitivity organ of a woman and its ablation is a mutilating and illogical practice. Thus, the preservation of a sensitive glans (clitoroplasty) has become the most common technique. Several procedures of clitoroplasty have been described [3–5]. However, a voluminous glans is often considered ugly due to its disproportionate size compared to the surrounding genitalia, which may be a source of dissatisfaction to the parents and patients.

We used a variant of clitoroplasty [6] characterised by a reduction in the length and the diameter of the corpus cavernosum, as well as the volume of the glans after complete mobilisation of the glans with its neurovascular bundle.

The present study provides the results of this variant of the clitoroplasty technique.

Patients and methods

From October 2003 to July 2015, 29 clitoroplasties were performed using the described technique, 28 of the patients had 46,XX DSD (two patients had 11-hydroxylase deficiency and 26 had 21-hydroxylase deficiency) and one ovotesticular DSD. The Prader classification was used to classify the severity of 46,XX DSD; four of the patients had grade II, six grade III, and 18 grade IV and V.

The age of the patients at surgery varied from 3 to 47 months (the delay in the surgical repair encountered in some patients was due to the rarity of the centres that

treat this type of pathology and to the absence of a system that orient the patients to such centres). The mean (range) follow-up was 5 (0.5–12) years.

In all patients, we performed the described technique [6]. This technique is characterised by complete separation of the glans with its neurovascular bundle from the corpus cavernosum. Thus, the glans remained attached only by its pedicle, which facilitates the surgery allowing us to achieve a significant and symmetrical reduction of the length (by excision of the distal part of the corpora cavernosa) and diameter (by excision of the internal part of these bodies). Then, the two parts are reunited with continuous sutures (Fig. 1).

The released glans in the form of a cap is often voluminous. Thus, it requires a reduction of its size with a longitudinal incision made at the midline of its anterior wall, which allows us to make a suitable reduction by excision of the edges (these excisions depend on the size of the glans). Then, the glans is reconstructed with 6–0 absorbable sutures and fixed at the tip of the corpus cavernosum. However, despite the reduction in the volume of the glans, in some patients, we were obliged to cover and hide the proximal half of the glans with penile skin.

During the same operation, we proceed to create a vaginoplasty using the mucosa of the prepuce [6] and labia minora using penile skin.

The present study has two components: assessment of the cosmetic and functional results of this technique of clitoroplasty. However, there is no reliable way to measure the function of the clitoris from adolescence to adulthood. In five patients with an age range of 10–13 years, the sensitivity of the glans and body of the clitoris were assessed by light touch (with filaments), pressure, and pain. The clinical examination was performed with the agreement of parents and in presence of the mother, initially with the girl blindfolded, and then with open eyes.

Results

Despite the reduction in volume, the length of the apparent part of the glans remained large (>10 mm) in four patients (14%), was an average size (5–10 mm) in 11 (39%), and small (<5 mm) in 13 (47%). The length of the corpus cavernosum was <20 mm and its diameter <5 mm in all cases. In eight patients with an apparent part of glans >5 mm, we covered the proximal

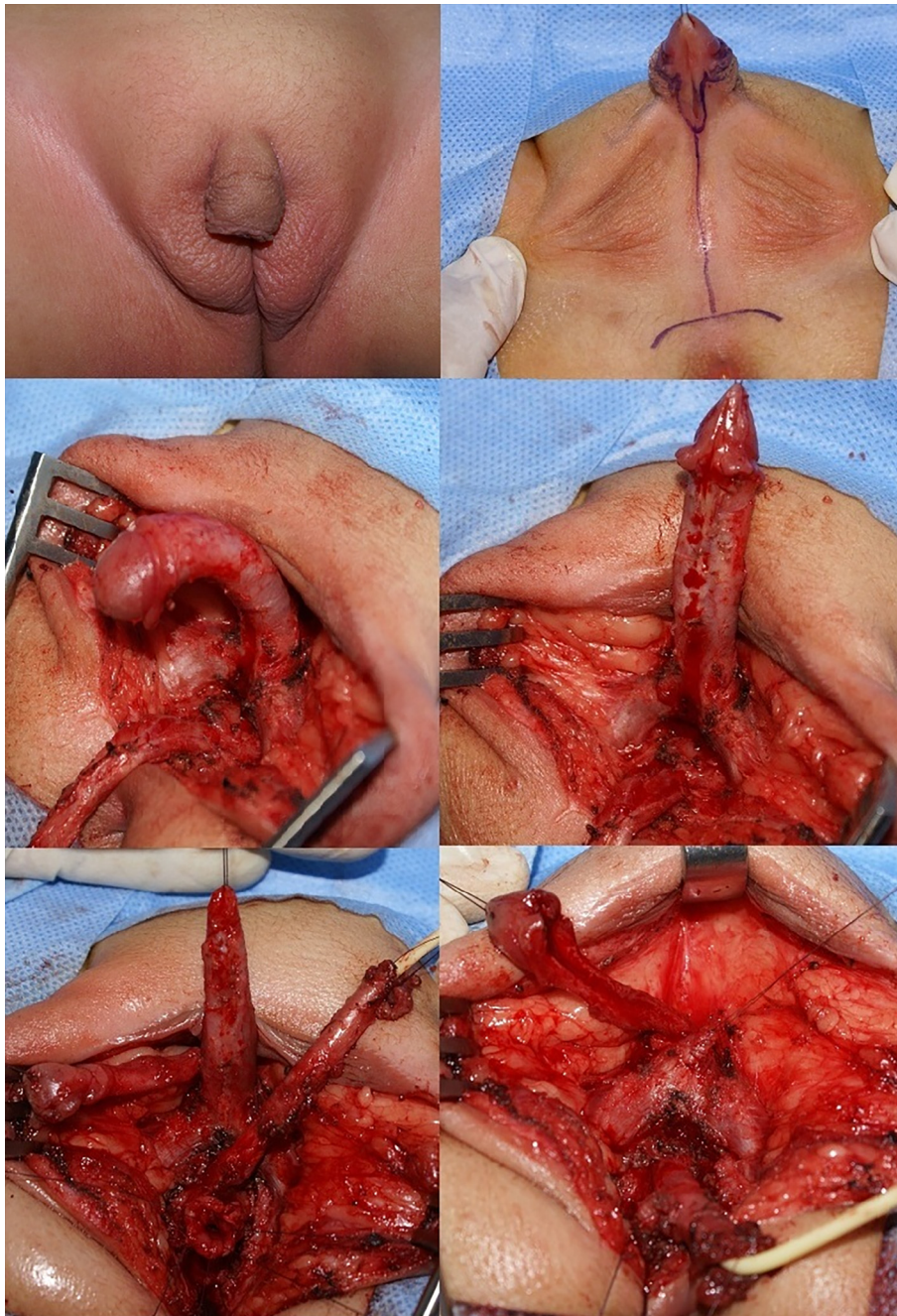


Fig. 1 The complete release of the glans and its neurovascular bundle allows us to achieve a significant and symmetrical reduction of the length and diameter of the corpora cavernosa, and the volume of the glans.

half of the glans with penile skin. Thus, the final appearance was considered by the parents and the surgeon as 'very satisfied' in 13 patients (47%), 'satisfied' in 11 patients (39%), and 'not satisfied' in four patients (14%).

The sensitivity of the reduced clitoris, using touch and pressure, seemed normal in all patients. However, it is impossible to fully assess the clitoris at this age, before puberty, and the role of the reduced clitoris in triggering sexual desire in these teenagers.

Discussion

It is clear from the high rate of poor cosmetic results in woman who have been treated in childhood for ambiguous genitalia [8] that feminising genitoplasty in childhood needs to be improved. The cosmetic results of feminising genitoplasty depend essentially on three criteria: the length and diameter of the corpus cavernosum, the volume of the glans, and the presence or not of labia minora.

Reduction of the phallus remains a challenge for a surgeon. It should be performed as early as possible to allow for the proper development of the patient's sexual identity. This surgical correction must create the appearance of external genitalia that correspond to the gender.

Several techniques have been described for clitoral reconstruction. In the past, the hypertrophied clitoris was excised (clitorectomy) [1,2]. However, the clitoris is a very important organ for the sexual life of a woman, as it is an erogenous organ, rich with nerve endings and highly vascularised. Its glans is covered by a mucosa extremely rich in Krause's corpuscles (sensory receptors for sensing temperature changes; essentially the perception of cold). Those corpuscles also are sensors of feeling pleasure (there are three-times more corpuscles on the clitoris glans than on the glans penis, for a much smaller surface).

In the 1930s, Young [1] performed an operation for clitoral reduction in a child with congenital adrenal hyperplasia, but the glans later sloughed leaving granulation tissue. In 1954, Jones and Jones [9] reported a modification to Young's operation, but the remaining erectile tissue was painful. However, the true first clitoroplasty was described by Lattimer in 1961 [3]. The principle of this technique was to dissect the corpora cavernosa, which are thereafter buried in a tunnel created under the skin. However, this technique does not correct the malformation, but hides it. In addition, this surgical technique was responsible for pain during erection at puberty [10]. However, the preferred technique for many medical centres was the technique described by Kumar et al. [4] in 1974. This technique is characterised by a partial resection of the corpus cavernosum after the release of the dorsal neurovascular pedicle, followed by suturing of the edges using nonabsorbable fine wire. But, this technique is responsible for an unacceptable cosmetic appearance with a large glans disproportionate to its surroundings. Both mentioned techniques, do not involve any reduction in the diameter of the corpus cavernosum responsible for a voluminous clitoris during erection. In 1983, Kogan et al. [4] proposed the subtunical resection of the cavernous tissue of the enlarged clitoris, a safe method that allows a reduction in shaft and glans size with maintenance of an intact blood supply to the glans.

Recently, two variants of the clitoroplasty technique, by complete separation of the glans with its neurovascular bundle, have been described for surgical correction of an enlarged clitoris. The technique is described by Pippi Salle et al. [11], which places the corpora cavernosa around the vaginal orifice and the glans repositioned at the bifurcation of the corpora cavernosa. The other technique is characterised by excision of the distal and internal part of the corpora cavernosa, as well as a reduction in the volume of the glans [6]. This technique gives a significant and symmetrical reduction in

the length and diameter of the corpus cavernosum. Reducing the diameter of corpus cavernosum is an important step in the surgical correction of clitoromegaly because this part of the bodies is very thin in a woman. This can only be achieved after complete release of the glans with its neurovascular bundle. In addition, when the glans is large, the reduction in its volume is needed and every effort should be made to protect the glans mucosa in this reduction of the volume.

The vascularisation of the glans is provided by two dorsal arteries, branches of the internal pudendal artery. They pass along the dorsal side of the clitoral or penis body, under the Buck's fascia, at the 11 and 1 o'clock positions. This artery has a winding path to accommodate for elongation during erection, an anatomical predisposition that explains the very low rate of necrosis of the glans encountered with this technique. Distally, these arteries enter the glans and form a network around the distal portion of the corpus cavernosum, which comes from the posterior part of the glans. Thus, any surgery of the clitoris should respect two principles: avoid injuring the dorsal pedicle of the phallus and not touching the dorsal part of the glans. On the other hand, some authors [12] criticise the complete release of the glans with its neurovascular bundle, which sacrifice the circumflex arteries of phallus, lateral branches of the dorsal artery of the phallus that supply the corpus spongiosum, and the circumflex nerves that surround the corpus cavernosum. However, these blood vessels were never found (on histological examination of pieces of excised corpus cavernosum) in children operated on during the first 3 years of life; they begin to develop only after the fourth year (Fig. 2). These anatomical findings were the result of prolonged study of a large number of patients operated upon at a young age. The absence of the circumflex arteries of phallus during the first three years of life is an argument to perform clitoroplasty at an early age to avoid any risk of intraoperative and postoperative bleeding. In addition, these vessels are destined to the distal part of the corpus spongiosum, which should be resected. The two clitoris nerves, which accompany the dorsal arteries of the penis at the 11 and 1 o'clock positions and end at the glans, are somatic branches of the pudendal nerve [12]. The published works on the innervations of the foetal penis do not show the presence of the circumflex nerves that surround the corpus cavernosum [13,14].

With this surgical variant of clitoroplasty, the cosmetic result can be excellent (Fig. 3), corresponding to the female gender, in half of the cases. However, a real assessment of the role of a reduced clitoris in the sexual life of the patient can only be made by thorough questioning of a sexually active woman who agrees to cooperate. There is no scientific way that allows us to evaluate the function of clitoris after clitoroplasty after reduction of the length of corpus cavernosum and com-

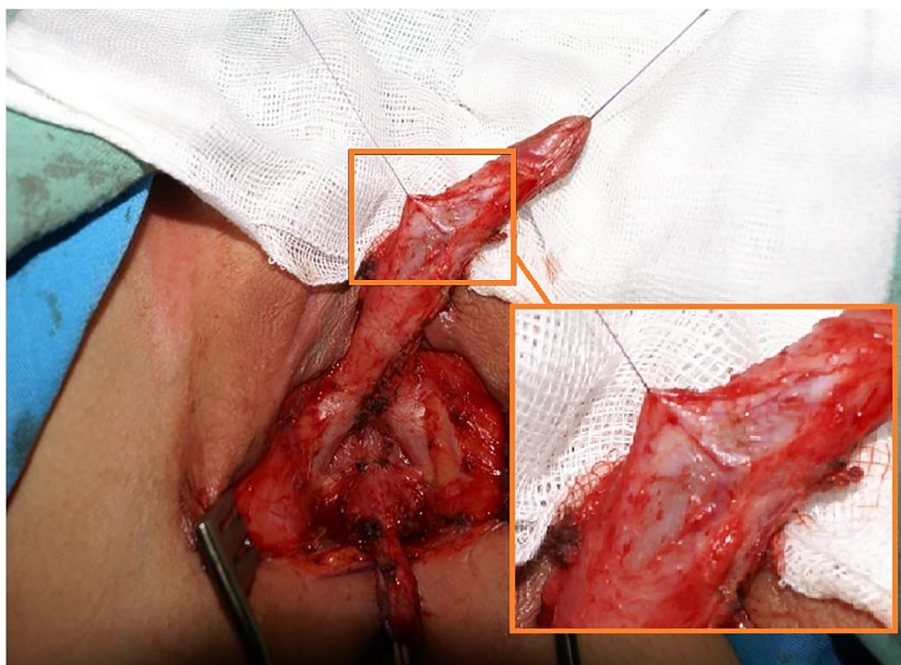


Fig. 2 The circumflex arteries of penis begin to develop from the fourth year.



Fig. 3 Good cosmetic appearance of the glans of the clitoris and external genitalia is achieved with this technique.

plete mobilisation of the glans with its neurovascular bundle. This explains the few studies devoted to this subject. Gearhart et al. [15] reported that electromyographic genital response after stimulation of the glans remains intact after the release of the pedicle and reduction in the length of the corpora cavernosa. However, it can be said with certainty that the sensitivity of the clitoris with this technique of clitoroplasty remains intact in all patients.

We hope to follow-up these patients as long as possible, in order to be able to evaluate the function of the clitoris in the long-term.

Conclusion

This variant of clitoroplasty provides a good cosmetic appearance of the external genitalia corresponding to gender and the sensitivity of the reduced clitoris, by touch and pressure, seemed normal in all patients.

Conflict of interest

The authors declare that they have no conflict of interest.

Source of funding

None.

References

- [1] Young HH. *Genital abnormalities, Hermaphroditism and Related Adrenal Diseases*. Baltimore: Williams & Wilkins; 1937.
- [2] Gross RE, Randolph J, Crigler Jr JF. Clitorectomy for sexual abnormalities: Indication and technique. *Surgery* 1966;**59**:300–8.
- [3] Lattimer JK. Relocation and recession of the enlarged clitoris with preservation of the glans: An alternative to amputation. *J Urol* 1961;**86**:113–6.
- [4] Kumar H, Kiefer H, Rosenthal IE, Clark SS. Clitoroplasty: experience during a 19-year period. *J Urol* 1974;**111**:81–4.
- [5] Kogan SJ, Smey P, Selwyn BL. Subtunical total reduction clitoroplasty: A safe modification of existing techniques. *J Urol* 1983;**130**:746–68.
- [6] Acimi S. Clitoroplasty: A variant of the technique. *Urology* 2008;**72**:669–71.

- [7] Acimi S. Vaginoplasty using the inner surface or mucosa of the prepuce in children with congenital adrenal hyperplasia. *J Pediatr Urol* 2013;**9**:1038–42.
- [8] Creighton SM, Minto CL, Steele SJ. Objective cosmetic and anatomical outcomes at adolescence of feminising surgery of ambiguous genitalia done in childhood. *Lancet* 2001;**358**:124–5.
- [9] Papageorgiou T, Hearn-Stokers R, Peppas D, Segars JH. Clitoroplasty with preservation of neurovascular pedicles. *Obstet Gynecol* 2000;**96**:821–3.
- [10] Allen TD. Reconstruction of the female with ambiguous genitalia. In: Kelalis PP, King LR, Belman AB, editors. *Clinical Pediatric Urology*, Vol. 2. Philadelphia: WB Saunders; 1976. p. 1023–8.
- [11] Pippi Salle JL, Braga LP, Macedo N, Rosito N, Bagli D. Corporeal sparing dismembered clitoroplasty: an alternative technique for feminizing genitoplasty. *J Urol* 2007;**178**:1796–800.
- [12] Ginger VA, Cold CJ, Yang CC. Surgical anatomy of the dorsal nerve of the clitoris. *Neurourol Urodyn* 2011;**30**:412–6.
- [13] Yucel S, Baskin LS. Identification of communicating branches among the dorsal, perineal and cavernous nerves of the penis. *J Urol* 2003;**170**:153–8.
- [14] Alsaid B, Moszkowicz D, Peschaud F, Bessedé T, Zaitouna M, Karam I, et al. Autonomic-somatic communications in the human pelvis: computer-assisted anatomic dissection in male and female fetuses. *J Anat* 2011;**219**:565–73.
- [15] Gearhart JP, Burnett A, Owen JH. Measurement of pudendal evoked potentials during feminizing genitoplasty: Technique and application. *J Urol* 1995;**153**:486–7.