

CASE REPORT



## Isolated pulmonary embolism in a patient with progestin intrauterine device and factor V Leiden

Soluny Jean 

Department of Medicine, Interfaith Medical Center, Brooklyn, NY, USA

### ABSTRACT

The risk of venous thromboembolism (VTE) in patients using estrogen contraception is well known. However, the association of progestin-only contraception (POC) and the risk of thrombosis is poorly investigated. Few studies on this topic have failed to prove a significant increase in VTE in patients using POC, including patients with a medical condition associated with an increased risk of thrombosis. Therefore, no specific consideration is warranted when using a POC in healthy young females, regardless of an inherited thrombophilia. We present a case of a young woman who has Factor V Leiden (FVL), presenting with an isolated pulmonary embolism (PE) while using a progesterone containing intrauterine device (IUD). The risk of VTE in FVL carriers seems to outweigh the benefit of contraception even when using progestin-only contraception. Therefore, non-hormonal contraception, such as copper IUD, seems to be the only safe alternative for contraception in this population. Further studies are needed to elucidate this observation.

**Abbreviation:** PE: pulmonary embolism; FVL: factor V Leiden; VTE: venous thromboembolism; POC: progestin only contraception; CBC: complete blood count; CMP: complete metabolic panel; ABG: arterial Blood gas; CTPA: CT pulmonary angiography

### ARTICLE HISTORY

Received 31 January 2019  
Accepted 22 March 2019

### KEYWORDS

Factor V Leiden; pulmonary embolism; progestin-only contraception; copper IUD; progestin IUD; venous thromboembolism

## 1. Introduction

Acute pulmonary embolism (PE) is a common and sometimes fatal condition [1,2]. Primary prevention, by acting on the modifiable risk factors, is one of the best ways to decrease mortality from PE [3].

Patients with factor V Leiden (FVL) have a mutant factor V that is resistant to protein C, putting them at an increased risk for venous thromboembolism (VTE) [4,5]. The risk of VTE in patients using estrogen contraception is well known. However, the association of progestin-only contraception and the risk of thrombosis is poorly investigated. Few studies on this topic have failed to prove a significant increase in VTE in patients using POC, including patients with a medical condition associated with an increased risk for thrombosis like FVL [1,6,7,8]. Therefore, no specific consideration is warranted when using a POC in a young healthy woman, regardless of inherited thrombophilia. However, this case report presents a patient with FVL using a progesterone-containing contraceptive who presented with a different clinical picture.

## 2. Case presentation



A 33-year-old Caucasian female, Gravida 2 Para 2, presented to the emergency department with sudden onset of moderate sharp left-sided pleuritic chest pain

and SOB for one day. She had a past medical history of factor V Leiden (diagnosed at age 16) and a family history of factor V Leiden and deep venous thrombosis (DVT) in her mother. She denied any previous VTE, recent surgery, prolonged immobilization, anticoagulant use, smoking or cancer. On further questioning, she admitted having a progestin intrauterine device placed nine months ago.

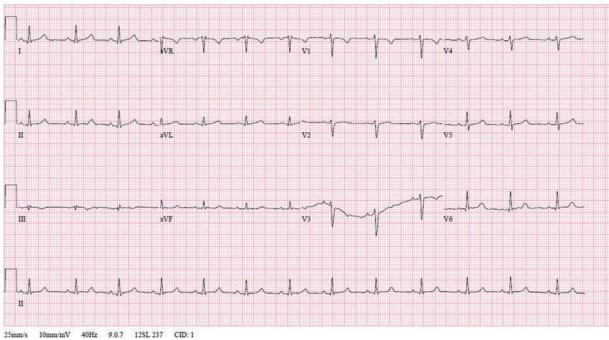
Review of systems was positive only for the chief complaints. Physical exam showed shallow breathing due to pain on deep inspiration. Heart rate was 88 beats/minute and temperature 98.8°F; lung exam revealed bilateral normal vesicular breath sounds with no wheezes or crepitation; no leg edema, or calf tenderness. The rest of the physical exam was unremarkable.

First sets of labs including, complete blood count (CBC), complete metabolic panel (CMP), troponin, arterial blood gas (ABG) and urine toxicology were within normal limits.

Electrocardiogram (EKG) (Figure 1) showed sinus rhythm with a rate of 78, T wave inversion in Lead 3 and V3. Echocardiogram showed normal ejection fraction (55–60%) with no right ventricular strain pattern. Her D-dimer level was elevated, 1440 ng/ml, (normal limits 0–500 ng/ml). Lower extremity venous Doppler showed no evidence of deep venous thrombosis.

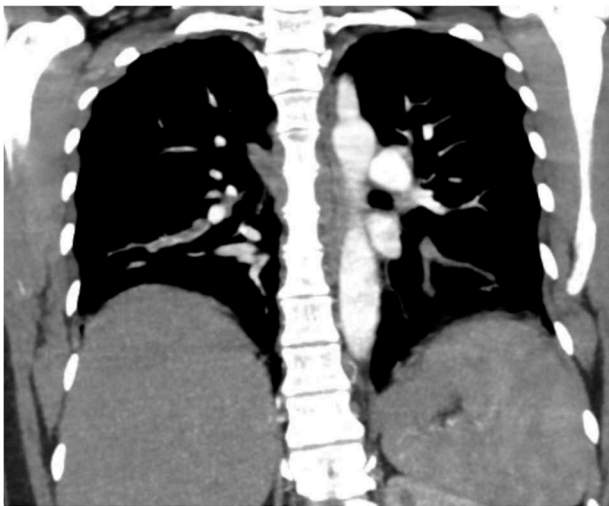
**CONTACT** Soluny Jean  [sojean@interfaithmedical.com](mailto:sojean@interfaithmedical.com)  Department of Internal Medicine, Interfaith Medical Center, 1545 Atlantic avenue, Brooklyn, NY 11213, USA

© 2019 The Author(s). Published by Informa UK Limited, trading as Taylor & Francis Group on behalf of Greater Baltimore Medical Center. This is an Open Access article distributed under the terms of the Creative Commons Attribution-NonCommercial License (<http://creativecommons.org/licenses/by-nc/4.0/>), which permits unrestricted non-commercial use, distribution, and reproduction in any medium, provided the original work is properly cited.

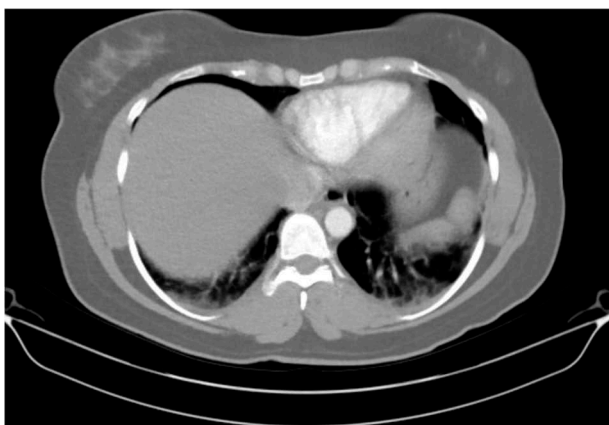


**Figure 1.** EKG showing sinus rhythm with a rate of 78, T wave inversion in Lead 3 and V3.

Due to the high suspicion of PE, computerized tomography pulmonary angiography (CTPA) (Figures 2 and 3) was done which revealed bilateral subsegmental pulmonary embolism. It also showed mild subsegmental pulmonary infarctions of the lower lobes. She was started on subcutaneous enoxaparin and later transitioned to



**Figure 2.** CTPA showing bilateral subsegmental pulmonary embolism.



**Figure 3.** CTPA showing mild subsegmental pulmonary infarctions of the lower lobes.

apixaban (Eliquis). During her hospital stay, she was hemodynamically stable. Her chest pain persisted for a couple of days and ultimately resolved with analgesia. She was discharged on the 3<sup>rd</sup> day, to follow up as outpatient.

She was counseled about avoidance of risk factors and to follow up with hematology and gynecology clinic for removal of her IUD on discharge.

### 3. Discussion

Hormonal contraception is known to increase the risk of VTE in the general population. Over the years, several combinations of estrogen and progesterone have been studied. The risk of thrombosis depends on the proportion and the type of each of these two hormones in the combination. The estrogen component is known to be the major risk factor. However, the progestin component and its association with VTE has not been well studied. One study suggested the use of second-generation combined oral contraception (COC) as the first choice when prescribing contraception in the general population. However, that same study stated that COC's are contraindicated in patient with thrombophilia, and progesterone-only contraception can be safely used in this patient group [7]. Another study revealed that the levonorgestrel-releasing IUD doesn't have any prothrombotic effect [9]. In a systematic review of POC and VTE, few articles revealed a potential increase in risk of VTE in patients with thrombophilia who use injectable depot medroxyprogesterone acetate. But, no increase in risk was found for other form of progesterone [6]. Because of the safety profile of POC shown by these few studies, no specific considerations are needed when using them as contraception even for patient with FVL.

Factor V Leiden (FVL) is a mutant form of coagulation factor V. The mutated factor V becomes resistant to the action of protein C, which is a natural anticoagulant. As a result, individuals who inherit the FVL mutation are at increased risk of venous thromboembolism (VTE) [10].

Our patient had two previous vaginal deliveries more than three years ago and no history of VTE. She had no other risk factors including smoking, recent surgery, cancer, prolonged immobilizations or previous pneumopathy. Other than her thrombophilia, the only potential risk factor found was the fact that she had a progestin IUD in place for 9 months. It's reasonable to conclude that her PE was likely a result of the association of her progestin IUD and her FVL.

In the USA, PE accounts for approximately 100,000 annual deaths [2]. Although mortality has been declining over the last decade, it remains high [11]. It is

always better to avoid hormonal contraceptive method in a patient with thrombophilia.

For our patient, beside the anticoagulant therapy, the management plan consisted of an extensive counseling regarding the avoidance of the risk factors and follow up in the gynecology outpatient clinic to replace the progestin IUD with a copper IUD as it is the first line contraception for patient at risk for thrombosis.

#### 4. Conclusion

The risk of VTE in Factor V Leiden carriers seems to outweigh the benefit of hormonal contraception even when using progestin-only contraception. Therefore, non-hormonal contraception, like copper IUD seems to be the only safe alternative for contraception in this population. Further studies are needed to elucidate this observation.

#### Consent

The patient has given written consent to the inclusion of material pertaining to herself and the study. She acknowledged that she cannot be identified via the paper because I have fully anonymized her.

#### Disclosure statement

No potential conflict of interest was reported by the author.

#### Funding

This work was not supported by any organization.

#### ORCID

Soluny Jean  <http://orcid.org/0000-0002-3559-1328>

#### References

- [1] Bergendal A, Odland V, Persson I, et al. Limited knowledge on progestogen-only contraception and risk of venous thromboembolism. *Acta Obstet Gynecol Scand.* 2009 Jan;88(3):261–266.
- [2] Horlander KT, Mannino DM, Leeper KV. Pulmonary embolism mortality in the USA, 1979–1998: an analysis using multiple-cause mortality data. *Arch Intern Med.* 2003 Jul;163(14):1711–1717.
- [3] Bagot CN, Arya R. Virchow and his triad: a question of attribution. *Br J Haematol.* 2008 Oct;143(2):180–190.
- [4] de Moerloose P, Reber G, Perrier A, et al. Prevalence of factor V Leiden and prothrombin G20210A mutations in unselected patients with venous thromboembolism. *Br J Haematol.* 2000 Jul;110(1):125–129.
- [5] Ridker PM, Hennekens CH, Lindpaintner K, et al. Mutation in the gene coding for coagulation factor V and the risk of myocardial infarction, stroke, and venous thrombosis in apparently healthy men. *N Engl J Med.* 1995;332(4):912–917.
- [6] Tepper NK, Whiteman MK, Marchbanks PA, et al. Progestin-only contraception and thromboembolism: a systematic review. *Contraception.* 2016 ;94(6):678–700.
- [7] Rott H. Thrombotic risks of oral contraceptives. *Curr Opin Obstet Gynecol.* 2012 Aug;24(4):235–240.
- [8] Plu-Bureau G, Maitrot-Mantelet L, Hugon-Rodin J, et al. Hormonal contraceptives and venous thromboembolism: an epidemiological update. *Best Pract Res Clin Endocrinol Metab.* 2013 Feb;27(1):25–34.
- [9] van Vliet HAAM, Tchaikovski SN, Rosendaal FR, et al. The effect of the levonorgestrel-releasing intrauterine system on the resistance to activated protein C (APC). *Thromb Haemost.* 2009 Apr;101(4):691–695.
- [10] Kovac M, Mitic G, Mikovic Z, et al. Type and location of venous thromboembolism in carriers of factor V Leiden or prothrombin. *Clin Appl Thromb.* 2010;16:66–70.
- [11] Søgaard KK, Schmidt M, Pedersen L, et al. 30-year mortality after venous thromboembolism: a population-based cohort study. *Circulation.* 2014 Sep;130(10):829–836.