



Shoulder Injury after Vaccination: A Systematic Review

Lesão de ombro após a vacinação: Uma revisão sistemática

Paul J. Cagle Jr¹

¹ Department of Orthopaedic Surgery, Icahn School of Medicine at Mount Sinai, New York, New York, United States

Rev Bras Ortop 2021;56(3):299–306.

Address for correspondence Paul J. Cagle Jr, MD, Assistant Professor, Associate Program Director Department of Orthopaedic Surgery, Icahn School of Medicine at Mount Sinai, New York, NY, United State (e-mail: PaulJCagleMD@gmail.com).

Abstract

Adverse reactions to vaccine injections are usually mild and incredibly rare in nature, but multiple cases of shoulder events including bursitis, generalized pain or decreased range of motion have been reported following routine vaccine administrations. These events are known as Shoulder Injury Related to Vaccine Administration or SIRVA.

A systematic review of literature was performed to identify all published accounts of SIRVA. Twenty-seven papers reporting one or more accounts of SIRVA were identified. The most common vaccination involved was the Influenza vaccine. The most common symptoms were pain that began in 48 hours or less and loss of shoulder range of motion. The most common treatment modalities were physical therapy, corticosteroid injections and anti-inflammatory medication; but in some patients, surgery was required. Regardless of intervention, the vast majority of outcomes demonstrated improved pain and functional except in the occasions of nerve injury.

The etiology of SIRVA injuries has multiple possibilities including needle length, mechanical injury from needle overpenetration and the possibility of an immune inflammatory response from the vaccine components, but a unique definitive test or quantifiably result does not yet exist.

Keywords

- ▶ bursitis
- ▶ impingement, shoulder
- ▶ shoulder pain
- ▶ influenza vaccines

Resumo

As reações adversas às injeções de vacina tendem a ser brandas e são incrivelmente raras. No entanto, vários casos de eventos em ombros, como bursite, dor generalizada ou diminuição da amplitude de movimento, foram relatados após vacinações de rotina. Esses eventos são conhecidos como lesões em ombro relacionadas à administração de vacina (SIRVA, do inglês *shoulder injury related to vaccine administration*).

Uma revisão sistemática da literatura foi realizada para identificar todos os relatos publicados de SIRVA. Vinte e sete artigos que relataram um ou mais casos de SIRVA foram encontrados. A vacina mais comumente citada foi a vacina contra influenza. Os sintomas mais comuns foram dor com início em até 48 horas e perda da amplitude de movimento do ombro. As modalidades de tratamento mais comuns foram fisioterapia,

received
May 20, 2020
accepted
September 16, 2020
published online
December 16, 2020

DOI <https://doi.org/10.1055/s-0040-1719086>.
ISSN 0102-3616.

© 2020. Sociedade Brasileira de Ortopedia e Traumatologia. All rights reserved.
This is an open access article published by Thieme under the terms of the Creative Commons Attribution-NonDerivative-NonCommercial-License, permitting copying and reproduction so long as the original work is given appropriate credit. Contents may not be used for commercial purposes, or adapted, remixed, transformed or built upon. (<https://creativecommons.org/licenses/by-nc-nd/4.0/>)
Thieme Revinter Publicações Ltda., Rua do Matoso 170, Rio de Janeiro, RJ, CEP 20270-135, Brazil

Palavras-chave

- ▶ bursite
- ▶ impacto no ombro
- ▶ dor em ombro
- ▶ vacinas contra influenza

injeções de corticosteroides e administração de medicamentos anti-inflamatórios; alguns pacientes, porém, precisaram de cirurgia. Independentemente da intervenção, a grande maioria dos casos apresentou melhora da dor e da função, à exceção dos pacientes com lesão nervosa.

A SIRVA tem múltiplas possíveis etiologias, inclusive comprimento da agulha, lesão mecânica por penetração excessiva da agulha e resposta inflamatória aos componentes da vacina; no entanto, ainda não há um exame definitivo ou resultado quantificável.

Introduction

Shoulder pain is a common finding in the primary care setting, and the prevalence in United States has been reported from 6.7% to 26%.^{1,2} After the establishment of the Vaccine Adverse Event Reporting System in 1990, accounts of prolonged shoulder symptoms after vaccinations have been documented.^{3,4} The Injection-Related Work Group of the U.S. Department of Health and Human Services Health Resources and Services Administration Centers for Disease Control published the 2011 Institute of Medicine Report, which generated “Proposals for Updates to the Vaccine Injury Table.” This report suggests Shoulder Injury Related to Vaccination Administration (SIRVA) applies when the vaccine recipient had a shoulder without prior pain or dysfunction, and subsequently within 48 hours of vaccination had shoulder pain with limited range of motion.⁵

SIRVA represents a complex series of reported injuries, onset of symptoms, treatments and outcomes, and SIRVA was added to the Vaccine Injury Compensation Table published by the Health Resources and Services Administration.⁶ The structures reportedly involved have included the rotator cuff, labrum, capsule, bursa, deltoid muscle, and this included diagnoses of bursitis, rotator cuff tears, adhesive capsulitis, chondral injury, nerve injury and infection.⁷⁻³³ The most common mechanism proposed is overpenetration of the deltoid muscle leading to injury either from a mechanical injury and/or from an immune response to the vaccine and/or adjuvants, and these events have frequently been correlated with an incorrect injection technique.⁷⁻³³ Thus, the primary outcome of this review was to identify unique features of SIRVA and the clinical results. The secondary outcome was to evaluate the etiology of the proposed injury mechanism with regard to the most commonly suggested reasons for a SIRVA (needle length, vaccination technique and autoimmune response).⁷⁻³³ We hypothesize that unique diagnostic findings will be identified and generalizable clinical results will be demonstrated, and we further hypothesize that a critical analysis of the factors associated with the proposed mechanism will provide guidance for avoiding additional shoulder injuries.

Methods

A systematic review of PubMed and Ovid MEDLINE was performed on February 1, 2020. The search terms “shoulder”

and “vaccination” in were utilized in combination. Search results were completed according to the Preferred Reporting Items for Systematic Reviews and Meta-Analyses guidelines³⁴ (PRISMA), and a PRISMA checklist was employed for analysis of the search results. In addition, a search of all citations present in the articles was performed. Level I to V studies published in English were considered under the inclusion criteria,³⁵ and any clinical outcomes including but not limited to pain, reduced range of motion, infection, tendon injury and chondral injury diagnoses. Exclusion criteria included biomechanical studies, non-human related publications, non-English publications, review articles without new cases reported or tumor events following vaccination.³⁶

Results

Seventy-five unique studies were identified (▶ **Fig. 1**). After selecting for studies that included shoulder vaccination in humans, forty-four remained. Excluding papers that were not written in English left thirty-nine. Selecting out cadaveric, biomechanical, incomplete, or studies without clinical data excluded an additional twelve publications. The remaining twenty-seven studies were closely examined and reviewed.

A total of 56 reported accounts of shoulder pain, injury or infection were identified following a reported vaccination event. Data demonstrating vaccination type, time to onset of symptoms, time to presentation, and age are demonstrated in ▶ **Table 1**. The age range was 21 months to 90 years old. The most common type of vaccination reported was Influenza representing 61% of the cases (34/56). The second most common vaccination reported was the Pneumococcal Polivalent Vaccination (PPV) representing 14% (8/56). The exact onset of symptoms was not reported in five cases, but 3 of those cases presented within two weeks of vaccination. In the remaining 51 accounts, the onset of pain was reported to have occurred in two days (48 hours) or less in 84% of the cases (43/51). Time to clinical presentation was not reported in 38% (21/56) of cases. In papers including clinical presentation time, time at clinical presentation was three weeks or less for 63% (22/35). Clinical findings, treatments and reported outcomes are demonstrated in ▶ **Table 2**. Clinical treatment methods were reported in all but two accounts. The two most common treatment modalities were physical therapy 41% (22/54) and CSI 33% (18/54). 12 cases (22%) were treated with surgery. Follow up clinical results were not available in 12 accounts (21%). In accounts reporting clinical

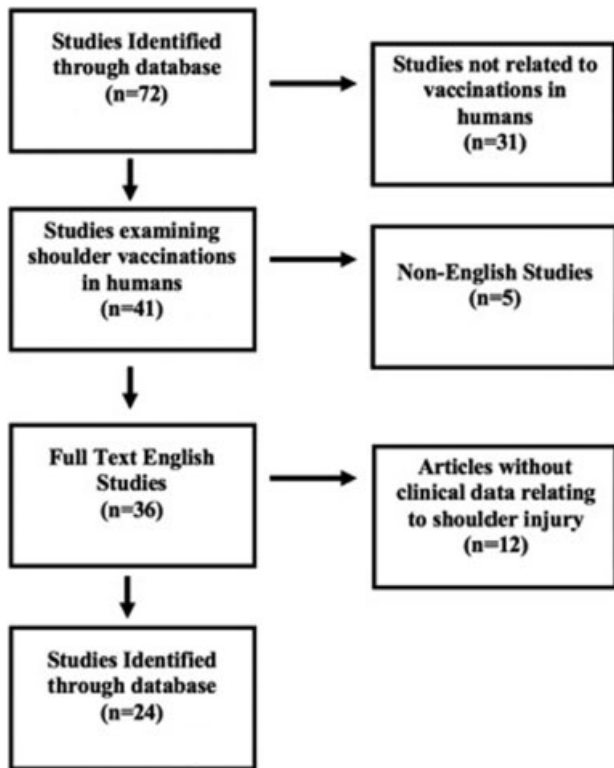


Fig. 1 Demonstration of Systematic Review Progression.

outcomes, 30% (13/44) were reported to have persistent symptoms beyond the follow up period. Nine of the 12 were part of one case series in which the presentation time for treatment was not reported.⁷ The remaining 70% (31/44) of reports were noted to have improved functions and/or symptoms.

Discussion

The collection of data regarding vaccine-related shoulder dysfunction is relatively new with only 56 published reports. According to the Vaccine Injury Table,⁶ the onset of symptoms needs to occur within 48 hours of the vaccination. This review demonstrated that 84% of the published accounts, with time to onset reported, actually met the 48 hours or less criteria, and this suggests a portion of the published literature would not fall under the Vaccine Injury table description of a SIRVA. In addition, the onset reporting symptoms was variable. Several of the presentations were reported greater than three months from the vaccination event, with the longest reported presentation event occurring 2 years later.^{14,16,21,22,29} Multiple studies also referenced pathologies such as rotator cuff tears, and many of the accounts were in people over the age of 60. Several studies have demonstrated MRI findings such as rotator cuff tears may be found in asymptomatic individuals with rates of 50% progression to symptomatic tears in an average of 2.8 years.^{7,37-39} Thus delays in initial presentation compounded with the potential for other underlying conditions does not allow for trend to be demonstrated, but the majority of studies did conform to the less than 48 hour definition.

The most common physical exam findings were consistent with impingement and loss of range of motion. Despite this, there was not one unique physical examination finding for SIRVA. There was also no clear correlation between a type of vaccine and severity of symptom presentation or duration. There was variability in the time before treatment was initiated. These treatments included physical therapy, corticosteroid injections, anti-inflammatory medications and/or surgical interventions, and patients who began a physician directed treatment pathways within three weeks of pain demonstrated a trend towards good to excellent outcomes. This was with the exception of patients who sustained a nerve injury or patients who ultimately required surgery. In the nerve injury patients, persistent symptoms were noted, and the surgical cases had a more prolonged course. Though many of the cases treated surgically were also noted to make an excellent recovery. Overall this demonstrates that there was not one particular physical exam findings unique to SIRVA patients, but in patients who do not sustain a neurologic injury, near or full recovery is the most common outcome. In addition, patients who begin treatment within three weeks of symptoms onset had overall good reported outcomes.

Imaging analysis with MRI did demonstrate a trend.^{8,10,12,13,21,24,26,32} Salmon et al.⁸ describes a MRI performed two days after the vaccination demonstrating a glenohumeral effusion, subacromial bursitis, subdeltoid bursitis and subscapular bursitis. A subsequent MRI 5 months later demonstrated regression of the joint effusion and decreased bursitis. Kuether et al.¹³ illustrated an initial MRI with minor effusions in the subacromial and subdeltoid bursa. Subsequent MRIs at 4 months and 12 months demonstrated decreasing bursitis. Barnes et al.¹⁰ demonstrated an MRI 8 weeks after a vaccination with an effusion in the subacromial bursa. Uchida et al.²⁶ also demonstrated an MRI with subacromial bursitis after a vaccination. Atanasoff reviewed 13 cases when MRI findings were available, and 69% of MRIs demonstrated fluid collections in the bursa or rotator cuff tendinitis. Thus, early MRI findings after a SIRVA event correlated with inflammatory changes such as increased fluid, bursitis and tendinitis, but MRIs taken months later may not be an accurate method of assessment.

As a secondary outcome of this review, the mechanism associated with SIRVA was evaluated. This is suggested to involve an overpenetration of the deltoid muscle allowing for a mechanical injury from the needle and/or an immune response from the injected material. One possible cause is utilization of a long needle. The Centers for Disease Control and Prevention guidelines recommend a 1-inch needle for patients in all but two categories.⁴⁰ The first is for females over 200 pounds and males over 260 pounds. In those settings, a 1.5 inch needle is recommended. The second exception is for newborns, where 5/8th inch needle is recommended.³⁸ Poland et al.⁴¹ evaluated deltoid fat pad thickness with ultrasound and suggested a 1 inch needle for men but stratified the recommendation for women for 5/8th inch needle for less than 60 kg, a 1 inch needle for 60-90 kg and a 1.5 inch needle for over 90 kg. A similar study was

Table 1 Reports of Vaccination Related Shoulder Injuries

AUTHOR	Onset Time	Presentation Time	N	Vaccination	Age
Barnes et al.	< 24 hours	3 weeks	1	Influenza	22
Shaikh et al.	< 1 week	1 month	1	Influenza	46
Messerschmitt et al.	< 24 hours	3 weeks	1	Influenza	46
Floyd et al.	< 24 hours	3 days	1	PPV	59
Kuether et al.	< 24 hours	4 weeks	1	Influenza	48
Terreri et al.	Unknown	1 week	1	BCG	21 months
Bodor et al.	2 days	5 months 2 months	2	PPV and Influenza	71 and 89
Cross et al.	< 24 hours	3 days	2	PPV and dTpa	82 and 23
Saleh et al.	< 24 hours	6 weeks 3 months 2 years	3	PPV and 2 Influenza	67, 30, 69
Hexter et al.	< 24 hours	Immediate	1	Influenza	50
Salmon et al.	< 24 hours	2 days	1	Revaxis®	26
Okur et al.	< 24 hours: 1/4 Unknown: 3/4	1-2 week: 3/4 2 months: 1/4	4	All Influenza	66, 59, 39, 36
Cook et al.	< 24 hours	3 days	1	Influenza	76
Arias et al.	< 24 hours: 3/8 < 1 week: 3/8 1-2 months: 2/8	Unknown	8	6/8 Influenza 1/8 PPV 1/8 Diphtheria, Tetanus toxoid	22-89
Anasoff et al.	< 24 hours: 12/13 4 days: 1/13	Unknown	13	8 Influenza, 2 Td, 2 Tdap, 1 HPV	22-83
Degreeef I and Debeer P	< 24 hours: 2/3 < 1 week: 1/3	2 months 2/3 6 months 1/3	3	Hep A, Influenza, Tetatus	36, 54, 73
McColgan BP and Borschke FA	< 24 hours	< 24 hours	1	PPV	73
Bathia NA and Stitik T	< 24 hours	3 weeks	1	Influenza	34
Shafer B and Burroughs K	< 24 hours	3 weeks	1	Influenza	25
Uchida et al.	< 24 hours	3 weeks	1	HPV	45
DeRogatis et al.	< 24 hours	1 week	1	PPV	90
Jotwani et al.	< 24 hours	2 weeks	1	Influenza	61
Imran et al.	< 24 hours	Unknown	1	Influenza	73
Meirelles et al.	< 24 hours	1 day	1	Influenza, Diphtheria, Tetanus	67
Erickson et al.	Unknown	2 weeks	1	Influenza	51
Shahbaz et al.	< 24 hours	1 hour	1	Influenza	34
Macomb et al.	< 24 hours	< 24 hours 4 days	2	PPV, Zoster	69, 84

Pneumococcal Polyvalent Vaccination (PPV); Bacillus Calmette-Guerin (BCG); Diphtheria, Tetanus, and *Pertussis* (dTpa); Diphtheria, Tetanus and Poliomyelitis (Revaxis®).

Human Papillomavirus (HPV); Tetanus, Diphtheria and *Pertussis* (Tdap).

performed by Lippert et al.⁴² using 250 imaging series but focused on overpenetration. This study suggested needle overpenetration would have been experienced by 11% of patients with a 5/8th inch needle, 55% of patients with a 7/8th inch needle and 61% of patients with a 1 inch needle. They suggested a weight-based scale that could possibly eliminate overpenetration rates with a 10% risk of under penetration. Cook et al.⁴³ discussed the importance of understanding body mass index (BMI) demonstrating that in all males

and females with a BMI less than 35 a 25 mm long needle could be safely utilized, but in females with a BMI greater than 35, a 32 mm needle would be required for adequate penetration. Atanasoffa et al.⁷ examined thirteen patients with persistent shoulder pain without a history of shoulder injury and supported the possible correlation of a SIRVA event and needle size. Overall these studies have demonstrated that a one size fits all approach is not appropriate, and this has been supported by other authors analyzes.⁴⁴ Thus, it

Table 2 Clinical Findings, Treatments, and Outcomes

AUTHOR	Findings	Treatment	Outcome
Barnes et al.	Shoulder pain, loss of ROM	PT	Improvement in pain at 11 weeks Resolution of symptoms 16 months
Shaikh et al.	EMG – axonal denervation of deltoid and supraspinatus	Oral Prednisolone	Resolved pain but persistent “mild” weakness 8 months
Messerschmitt et al.	Shoulder Pain, loss of ROM, cartilage lesion	Surgery - hemiarthroplasty	Resolution of pain and symptoms at 3 years
Floyd et al.	Shoulder Pain, loss of ROM	Surgery – arthroscopic debridement	Resolution of pain and symptoms at 12 weeks
Kuether et al.	Shoulder Pain, osteonecrosis of humeral head	PT, Oral NSAIDs	Resolution of pain and symptoms at 6 months
Terreri et al.	Shoulder Pain, fever, osteitis	Antibiotics	Improved symptoms at 19 days after antibiotics
Bodor et al.	Shoulder Pain, loss of ROM, tendinitis	PT and CSI	Resolution of pain and symptoms at 5 and 6 months
Cross et al.	Shoulder Pain both, infection markers for one patient	1) Surgery – Debridement 2) PT and CSI	Resolution of pain and symptoms 1 month after surgery and 3 months after PT and CSI
Saleh et al.	All 3 Shoulder Pain and loss of ROM	PT 3/3 CSI 2/3	Resolution of pain and symptoms 50 days for one patient, unknown for second, no results for 3 rd patient
Hexter et al.	Shoulder Pain	Surgical Debridement	Resolution of pain and symptoms
Salmon et al.	Shoulder Pain and effusion	NSAIDs and CSI	Resolution of pain and symptoms at 5 months
Okur et al.	Shoulder Pain	NSAIDs 3/4 No treatment 1/4	Resolution of pain and symptoms at 5 months 33 days, 5.5 months, 2 years and 2.5 years
Cook et al.	Shoulder Pain	CSI	Resolution of pain and symptoms at 1 months
Arias et al.	Shoulder Pain	Unknown	Unknown
Anasoff et al.	Shoulder Pain: 13/13 Loss of ROM: 11/13 Weakness: 4/13	NSAIDs: 8/13 CSI: 8/13 PT: 6/13 Surgery: 4/13	Full Recovery 4/13 Residual Symptoms: 9/13 Symptoms for at least 6 months 13/13
Degreef I and Debeer P	All 3 Shoulder Pain and loss of ROM	CSI: 1/3 PT: 3/3	Resolution of pain and symptoms at 1 month 6 weeks and 3 months
McColgan BP and Borschke FA	Shoulder Pain and Swelling	c	Improvement at 2 weeks postop
Bathia NA and Stitik T	Shoulder pain	Unknown	Unknown
Shafer B and Burroughs K	Shoulder Pain and loss of ROM	Unknown	Unknown
Uchida et al.	Shoulder pain	Surgery – arthroscopic debridement	Resolution of pain and symptoms at 1 year postop
DeRogatis et al.	Shoulder pain and infection	Surgical Debridement	Improvement at 2 weeks postop
Jotwani et al.	Shoulder pain	CSI	Improvement but no time frame noted
Imran et al.	Shoulder pain and weakness	PT	ROM limitations at 6 weeks follow up
Meirelles et al.	Shoulder pain and weakness	PT	Significant recovery at 1 year, return of sensation and function at 31 months
Erickson et al.	Shoulder pain	PT and CSI Surgical Debridement	Resolution of pain and symptoms at 1 year
Shahbaz et al.	Shoulder Pain and loss of ROM	PT and NSAIDs	8 month improvement with continued pain
Macomb et al.	Shoulder Pain and loss of ROM	NSAIDs, PT, CSI	Resolution of pain and symptoms at 1 month

Abbreviations: ROM, Range of Motion; PT, Physical Therapy; EMG, Electromyography; NSAIDs, Nonsteroidal anti-inflammatory medications; CSI, Corticosteroid Injection.

is conceivable that overpenetration is possible with lower weight, lower BMI, longer needles or a combination of needle length and lower body weight/BMI, but an appropriate needle length should significantly decrease the risk of overpenetration.

Vaccination technique is also commonly discussed with many of SIRVA cases reporting the vaccination was placed "Too High" (less than 3 cm from the lateral edge of the acromion).^{7,8,12,14,15,19,20,26} One account attempted to measure the bursa of two patients demonstrating it to extend 3.5 cm from the acromion in a female patient and 4 cm in a male patient.¹⁴ Beals et al.⁴⁵ examined the bursa of 17 cadaveric shoulders. They noted the average distance from the anterolateral corner of the acromion to the posterior bursal curtain was 2.8 cm and that the bursa margins were always 2 cm or more from the from the anterolateral corner of the bursal acromial surface. Avoidance of the bursa can potentially be obtained by a more distal placement of the injection. The national injection technique recommendations suggest the injection should be placed 2-3 finger breadths (2 inches) below the acromion and recommends "to avoid causing an injury, do not inject too high (near the acromion process) or too low",⁴⁶ but increasingly distal placement increases risk to the axillary nerve. Meirelles et al.³⁰ in fact illustrated a case of a 67 year old male who underwent a vaccination and experienced immediate pain and dysfunction. A nerve conduction study revealed axillary nerve compromise and return of function was not until 31 months. Imran et al.²⁹ described a case of a 73 year old male with acute pain following a vaccination. Physical examination and manual muscle testing demonstrated poor deltoid function, and the authors suggested a direct injury to the axillary nerve as the cause. This patient had follow up of 6 weeks demonstrating improvements in shoulder function but continued range of motion deficits. Thus shoulder vaccinations with overpenetration risks injury to the bursa with a superior location and risks injury to the axillary nerve with an inferior location.

Finally, penetration of the vaccination needle past the deltoid muscle also risks injection of the vaccine contents into the shoulder tissues. The capacity for an immune response from the injection material has been proposed by several authors.^{7,8,12,13} Dumonde and Glynn⁴⁷ demonstrated the capacity to cause an intraarticular reaction using an animal model.^{48,49} Jasin⁵⁰ also utilized a rabbit model to examine the mechanism of trapping of immune complexes in collagen tissues of joints and found the trapping depended on the presence of antibody in the extra-vascular space and the diffusion of antigen or soluble complexes into this space. Trollmo et al.⁵¹ evaluated peripheral blood of six healthy adults before and 14 days after antigen exposure. They demonstrated the influenza virus antigen induces a strong systemic antibody response, but no significant systemic level difference was detected between subjects injected in the intra-articular space when compared with a subcutaneous injection.

Several accounts of suspected inflammatory reaction have been reported in the literature. Anasoff et al.⁷ suggested

that an injection into the subacromial space would have the potential to cause a reaction. Salmon et al.⁸ report on an event following a vaccination where an MRI demonstrated a bony reaction. Kuether et al.¹³ reported on a 48 year old woman who had demonstrated signs of osteonecrosis in the humeral head in MRI scan immediately, at 4 months and at 12 months after a vaccination. They state that a direct causal relationship cannot be confirmed but propose an immune response to the injection as a possible cause of the osteonecrosis. Messerschmitt et al.¹² discussed a 46 year old male with immediate shoulder pain following a vaccination. The patient was ultimately taken for surgery, and the biopsies obtained demonstrated inflammatory cells and granulation tissue.

Although the capacity to cause an immune response has been supported by animal data, a definitive clinical study demonstrating a quantitative link between a vaccine antigen and/or vaccine adjuvant and an immune mediate shoulder inflammation causing prolonged clinical symptomatology is still lacking. This is supported by the statements at the end of several of the SIRVA accounts. Kuether et al.¹³ stated multiple times that a causal link could not be drawn. Messerschmitt et al.¹² suggested that they were uncertain if the chondrolytic changes predated the event. Uchida et al.²⁶ go further and stated that the consequences of improper injection technique are not currently known and the biopsy samples they obtained seven months after the vaccination cannot provide conclusive evidence. Furthermore, the diagnoses, duration and treatment following the cases reported in this review are heterogenous as were the types of vaccines which were reported. Thus, quantitative support for an immune response was not found in reported cases.

Conclusion

Overall this review demonstrated that in patients who do not sustain a neurologic injury, near or full recovery is the most common outcome. No unique physical exam feature was identified, but early MRI utilization may assist by demonstrating an increased fluid signal and bursitis. Because of the heterogenous treatments utilized, treatments such as physical therapy, CSIs, NSAIDs or surgery cannot be recommended cannot be individually recommended. Instead, a recommendation for treating the resulting pathology based on evidence based guidelines for the appropriate diagnoses would be appropriate. As patients who presented for treatment within three weeks of symptoms onset had overall good reported outcomes, a recommendation can be made that all patients who experience shoulder pain for greater than 14 days after a vaccination injection should seek immediate medical evaluation. In regards to needle length, a weight/BMI based scale should be utilized, and vaccination techniques must balance the need to avoid superior locations while minimizing axillary nerve risk. Finally it is still unclear as to whether or not shoulder injury related to vaccine administration "SIRVA" is a unique event. It would seem for SIRVA to remain a descriptive term these events would have to be unique to vaccinations and not simply an event that could happen with any over

penetrated injected material. Thus more data is needed to separate out a mechanical injury from an immune response.

Conflict of Interests

The authors have no conflict of interests to declare.

References

- Cunningham LS, Kelsey JL. Epidemiology of musculoskeletal impairments and associated disability. *Am J Public Health* 1984;74(06):574-579
- Luime JJ, Koes BW, Hendriksen IJM, et al. Prevalence and incidence of shoulder pain in the general population; a systematic review. *Scand J Rheumatol* 2004;33(02):73-81
- Current Trends Vaccine Adverse Event Reporting System-United States. Available at: <https://www.cdc.gov/mmwr/preview/mmwrhtml/00001804.htm>. [Accessed March 1, 2019]
- The National Childhood Vaccine Injury Act of 1986. Public Health Service Act *** 2125. (42 U.S.C. *** 300aa-25 (Supp. 1987))
- Ryan T. 2011 Institute of Medicine (IOM) Report generated Proposals for Updates to the Vaccine Injury Table
- Vaccine Injury Table. Available at: <https://www.hrsa.gov/sites/default/files/hrsa/vaccine-compensation/vaccine-injury-table.pdf>. [Accessed March 1, 2019]
- Atanasoff S, Ryan T, Lightfoot R, Johann-Liang R. Shoulder injury related to vaccine administration (SIRVA). *Vaccine* 2010;28(51):8049-8052
- Salmon JH, Geoffroy M, Eschard JP, Ohl X. Bone erosion and subacromial bursitis caused by diphtheria-tetanus-poliomyelitis vaccine. *Vaccine* 2015;33(46):6152-6155
- Terreri MT, Yamada AF. Osteitis caused by BCG vaccination. *Pediatr Radiol* 2008;38(04):481
- Barnes MG, Ledford C, Hogan K. A "needling" problem: shoulder injury related to vaccine administration. *J Am Board Fam Med* 2012;25(06):919-922
- Shaikh MF, Baqai TJ, Tahir H. Acute brachial neuritis following influenza vaccination. *BMJ Case Rep* 2012;2012:1-2
- Messerschmitt PJ, Abdul-Karim FW, Iannotti JP, Gobeze RG. Progressive osteolysis and surface chondrolysis of the proximal humerus following influenza vaccination. *Orthopedics* 2012;35(02):e283-e286
- Kuether G, Dietrich B, Smith T, Peter C, Gruessner S. Atraumatic osteonecrosis of the humeral head after influenza A-(H1N1) v-2009 vaccination. *Vaccine* 2011;29(40):6830-6833
- Bodor M, Montalvo E. Vaccination-related shoulder dysfunction. *Vaccine* 2007;25(04):585-587
- Cook IF. Subdeltoid/subacromial bursitis associated with influenza vaccination. *Hum Vaccin Immunother* 2014;10(03):605-606
- Saleh ZM, Faruqi S, Foad A. Onset of frozen shoulder following pneumococcal and influenza vaccinations. *J Chiropr Med* 2015;14(04):285-289
- Hexter AT, Gee E, Sandher D. Management of glenohumeral synovitis secondary to influenza vaccination. *Shoulder Elbow* 2015;7(02):100-103
- Martín Arias LH, Sanz Fadrique R, Sáinz Gil M, Salgueiro-Vazquez ME. Risk of bursitis and other injuries and dysfunctions of the shoulder following vaccinations. *Vaccine* 2017;35(37):4870-4876
- Floyd MW, Boyce BM, Castellán RM, McDonough EB. Pseudoseptic arthritis of the shoulder following pneumococcal vaccination. *Orthopedics* 2012;35(01):e101-e103
- Cross GB, Moghaddas J, Buttery J, Ayoub S, Korman TM. Don't aim too high: Avoiding shoulder injury related to vaccine administration. *Aust Fam Physician* 2016;45(05):303-306
- Okur G, Chaney KA, Lomasney LM. Magnetic resonance imaging of abnormal shoulder pain following influenza vaccination. *Skeletal Radiol* 2014;43(09):1325-1331
- Degreef I, Debeer P. Post-vaccination frozen shoulder syndrome. Report of 3 cases. *Acta Chir Belg* 2012;112(06):447-449
- McColgan BP, Borschke FA. Pseudoseptic arthritis after accidental intra-articular deposition of the pneumococcal polyvalent vaccine: a case report. *Am J Emerg Med* 2007;25(07):864.e1-864.e3
- Bathia NA, Stitik T. "Influenza vaccine shoulder"-vaccination related traumatic injury to the infraspinatus: a case report [Poster presentation]. *Assoc Acad Physiat Ann Meet* 2010;. PM R 2009 1:S118
- Shafer B, Burroughs K. Shoulder pain in a 25-year-old female following an influenza vaccination. *Am Med Soc Sport Med* 2010. Available at: https://www.amssm.org/shoulder_pain_in_a_25_year-csa
- Uchida S, Sakai A, Nakamura T. Subacromial bursitis following human papilloma virus vaccine misinjection. *Vaccine* 2012;31(01):27-30
- DeRogatis MJ, Parameswaran L, Lee P, Mayer TG, Issack PS. Septic Shoulder Joint After Pneumococcal Vaccination Requiring Surgical Debridement. *HSS J* 2018;14(03):299-301
- Jotwani V, Narducci DM. Pain in right shoulder - recent influenza vaccination - history of hypertension and myocardial infarction - Dx? *J Fam Pract* 2019;68(01):44-46
- Imran M, Hayley D. Injection-induced axillary nerve injury after a drive-through Flu shot. *Clin Geriatr* 2013;21(12):
- Meirelles H, Filho GRM. Axillary nerve injury caused by deltoid muscle intramuscular injection: case report. *Rev Bras Ortop* 2004;39(10):615-619
- Erickson BJ, DiCarlo EF, Brause B, Callahan L, Hannafin J. Lytic Lesion in the Proximal Humerus After a Flu Shot: A Case Report. *JBJS Case Connect* 2019;9(03):e0248
- Shahbaz M, Blanc PD, Domeracki SJ, Guntur S. Shoulder Injury Related to Vaccine Administration (SIRVA): An Occupational Case Report. *Workplace Health Saf* 2019;67(10):501-505
- Macomb CV, Evans MO, Dockstader JE, Montgomery JR, Beakes DE. Treating SIRVA Early With Corticosteroid Injections: A Case Series. *Mil Med* 2020;185(1-2):e298-e300
- Moher D, Liberati A, Tetzlaff J, Altman DG; Prisma Group. PRISMA Group. Preferred reporting items for systematic reviews and meta-analyses: the PRISMA statement. *PLoS Med* 2009;6(07):e1000097
- Obremsky WT, Pappas N, Attallah-Wasif E, Tornetta P III, Bhandari M. Level of evidence in orthopaedic journals. *J Bone Joint Surg Am* 2005;87(12):2632-2638
- Bilgili SG, Karadag AS, Ceylan MF, Calka O, Turktaş U, Bulut G. The development of giant lipoma on the BCG vaccine caused scar. *Cutan Ocul Toxicol* 2012;31(01):70-73
- Tempelhof S, Rupp S, Seil R. Age-related prevalence of rotator cuff tears in asymptomatic shoulders. *J Shoulder Elbow Surg* 1999;8(04):296-299
- Minagawa H, Yamamoto N, Abe H, et al. Prevalence of symptomatic and asymptomatic rotator cuff tears in the general population: From mass-screening in one village. *J Orthop* 2013;10(01):8-12
- Yamaguchi K, Tetro AM, Blam O, Evanoff BA, Teeffey SA, Middleton WD. Natural history of asymptomatic rotator cuff tears: a longitudinal analysis of asymptomatic tears detected sonographically. *J Shoulder Elbow Surg* 2001;10(03):199-203
- Centers for Disease Control and Prevention. Dose, route, site, and needle size. Available at: www.immunize.org/catg.d/p3085.pdf. [Accessed March 22, 2019]
- Poland GA, Borrud A, Jacobson RM, et al. Determination of deltoid fat pad thickness. Implications for needle length in adult immunization. *JAMA* 1997;277(21):1709-1711
- Lippert WC, Wall EJ. Optimal intramuscular needle-penetration depth. *Pediatrics* 2008;122(03):e556-e563

- 43 Cook IF, Williamson M, Pond D. Definition of needle length required for intramuscular deltoid injection in elderly adults: an ultrasonographic study. *Vaccine* 2006;24(07):937-940
- 44 Zuckerman JN. The importance of injecting vaccines into muscle. Different patients need different needle sizes. *BMJ* 2000;321(7271):1237-1238
- 45 Beals TC, Harryman DT 2nd, Lazarus MD. Useful boundaries of the subacromial bursa. *Arthroscopy* 1998;14(05):465-470
- 46 How to Administer Intramuscular and Subcutaneous Vaccine Injections to Adults. Available at. <http://www.immunize.org/catg.d/p2020A.pdf>. [Accessed March 15, 2019]
- 47 Dumonde DC, Glynn LE. The production of arthritis in rabbits by an immunological reaction to fibrin. *Br J Exp Pathol* 1962;43(04):373-383
- 48 Cooke TD, Jasin HE. The pathogenesis of chronic inflammation in experimental antigen-induced arthritis. I. The role of antigen on the local immune response. *Arthritis Rheum* 1972;15(04):327-337
- 49 Cooke TD, Hurd ER, Ziff M, Jasin HE. The pathogenesis of chronic inflammation in experimental antigen-induced arthritis. II. Preferential localization of antigen-antibody complexes to collagenous tissues. *J Exp Med* 1972;135(02):323-338
- 50 Jasin HE. Mechanism of trapping of immune complexes in joint collagenous tissues. *Clin Exp Immunol* 1975;22(03):473-485
- 51 Trollmo C, Carlsten H, Tarkowski A. Intra-articular immunization induces strong systemic immune response in humans. *Clin Exp Immunol* 1990;82(02):384-389