



Original Article

Symptomatic intracranial hemorrhages and frame-based stereotactic brain biopsy

Monica Lara-Almunia¹, Javier Hernandez-Vicente²

¹Department of Neurosurgery, Jimenez Diaz Foundation University Hospital, Madrid, ²Department of Neurosurgery, University Hospital of Salamanca, Salamanca, Spain.

E-mail: *Monica Lara-Almunia - mnclr23@gmail.com; Javier Hernandez-Vicente - hodghkin@hotmail.com



***Corresponding author:**

Monica Lara-Almunia,
Department of Neurosurgery,
Jimenez Diaz Foundation
University Hospital, Av. de los
Reyes Catolicos, 2., Madrid,
Spain.

mnclr23@gmail.com

Received : 16 March 2020

Accepted : 05 July 2020

Published : 01 August 2020

DOI

10.25259/SNI_102_2020

Quick Response Code:



ABSTRACT

Background: Stereotactic biopsy is a well-established procedure in neurosurgery. Our objective is to define the clinical, radiological, and technical factors that can condition the emergence of postbiopsy symptomatic intracranial hemorrhage. Based on our findings, we suggest recommendations to improve its usual clinical practice.

Methods: We made a retrospective study of 429 cases with stereotactic biopsies performed in the past 37 years. The surgical procedure was adapted in terms of the stereotactic frames (Todd-Wells, CRW, Leksell), neuroimaging tests, and planning programs available in the hospital. Fifty-three variables were analyzed for each patient (SPSS.23).

Results: The diagnostic yield was 90.7%. Forty-one patients (9.5%) suffered a symptomatic postbiopsy hemorrhage; only 17 (3.9%) had permanent morbidity. The mortality was 0.93% ($n = 4$). A postsurgical CT scan was requested only in 99 patients (23%) of our series. Lesion mass effect, cystic component, contrast enhancement, histological nature, or number of targets were not associated with a greater risk of symptomatic postbiopsy hemorrhage ($P > 0.05$). On the other hand, the biopsies made by nonexpert neurosurgeons ($P = 0.01$) or under general anesthesia ($P = 0.02$) resulted in a greater risk of symptomatic postbiopsy hemorrhage. Anesthetic type was the clearest predictive factor of bleeding with this technique (OR: 0.24).

Conclusion: Stereotactic biopsy is a very valuable tool. To optimize its safety and minimize the risk of intracranial bleeding, it requires both a knowledge of stereotactic techniques and very careful surgical planning. While the patient's stay in intensive vigilance units after the procedure is a useful strategy, the request for control CT scans should be conditioned by the clinical evolution of each patient.

Keywords: Brain tumors, Intracranial postbiopsy hemorrhage, Stereotactic biopsy, Stereotactic procedures

INTRODUCTION

Stereotactic biopsy is the least invasive technique for obtaining a sample of brain tissue for subsequent diagnosis and treatment. With more than 70 years in the neurosurgical field, the stereotactic biopsy has been able to adapt to the technological advances at every moment.^[17,18,54,55] In this way, currently, it constitutes a simple and precise procedure.

The accuracy of stereotactic biopsy has been presented in many works, reaching a high diagnostic yield $>90\%$.^[1,8,22,28] Moreover, larger published series in the literature show an estimated morbidity of 1–10.8%,^[1,20,21] and estimated mortality of 0–2.3%.^[5,37,45,60]

This is an open-access article distributed under the terms of the Creative Commons Attribution-Non Commercial-Share Alike 4.0 License, which allows others to remix, tweak, and build upon the work non-commercially, as long as the author is credited and the new creations are licensed under the identical terms.

©2020 Published by Scientific Scholar on behalf of Surgical Neurology International

The most common complications associated with this procedure are seizures, *de novo* neurological deficits, infections, and hemorrhages.^[7,11,21] Postbiopsy intracranial hemorrhages are both the most important and the most frequently complication reflected in the literature, with a presentation of 1.4–9.6%.^[5,12,16,21,25,29,32–34,37,40,45,52,63] There is a great variability between the different studies with respect to when a postbiopsy bleeding, is considered a complication or not.

Despite the role of stereotactic biopsy is well-known in contemporary medicine, its potential risks are occasionally undervalued. This attitude is erroneous. The possible complications of this procedure should be weighed up against the peculiarities of each patient and the benefits of obtaining a histological diagnosis in every case.

In previous published works, we have studied the association between different variables and diagnostic yield of this technic. Now, we analyze our wide experience in stereotactic biopsies with the aim of determining which factors could condition the appearance of postbiopsy intracranial hemorrhage and minimize this complication.

MATERIALS AND METHODS

Data collection

We have performed the retrospective study of 429 patients submitted to stereotactic biopsy between 1982, when we started using this technic, and 2019.

A total of 53 variables referring to the characteristics of the patient, the characteristics of the brain lesion,^[23,26,44,46] the peculiarities of the surgical technique, the diagnostic/therapeutic orientation, and the prognosis were analyzed for each patient to configure the database. The information was obtained with a thorough revision of the clinical histories.

Surgical planning

Inclusion and exclusion criteria

The inclusion and exclusion criteria considered for stereotactic biopsy have previously been described in the literature.^[1,2,5,8,21,22,32,34,37,63]

Surgical technique

The surgical methodology employed throughout the decades was determined by the equipment available in the center. In this way, three methodological periods can be distinguished, as our group has already published. Briefly:

- I Period (1982–1991). The employed surgical instruments were the Todd-Wells stereotactic device (Integra Radionics®, USA),^[57] along with the Backlund spiral needle.^[5] The radiological equipment were a portable

X-ray devices (C-arm; Philips®, The Netherlands) and a 16-slice CT scanner (Siemens®, Germany) since 1985. The calculations and coordinates were estimated by a locally developed MS-DOS program [Figure 1]

- II Period (1991–2011). The used surgical instruments were the CRW stereotactic guide (Cosman–Roberts–Wells; Integra Radionics®, USA),^[3,9] along with a Sedan–Nashold biopsy needle.^[53] CT scans, both 16-slice (Siemens®, Germany) and 40-slice (Philips®, The Netherlands) since 2002, were used. The targets were established on the CT images and calculated by CT software until 1998. Then, a workstation with the Target 1.19 planning program was introduced (Brainlab®) [Figure 2]
- III Period (2011–2019). The stereotactic instruments were the Leksell stereotactic system (Elekta Instruments®, Inc., Sweden)^[15] and a Sedan/Nashold biopsy needle (Elekta Instruments®, Inc., Sweden).^[53] A 64-slice CT scanner (General Electric®, USA) and a 3T MRI (General Electric®, USA) were employed. In most cases, the target was established on the most suitable sequence of the MRI. The coordinates were obtained with Framelink and the Cranial 3.0 planning programs (Medtronic®) [Figure 3].

The senior stereotactic neurosurgeon retired during this period.

The type of anesthesia that was mostly used during the surgical intervention was local anesthesia (bupivacaine 0.25% + epinephrine) along with light sedation. Exceptionally, general anesthesia was used in some pediatric patients or in patients with significant mental alteration.

During all three methodological periods, the biopsy technique consisted of making a twist drill or a burr hole, and obtaining tissue samples, between 3 and 4 cylinders, at different depths of the trajectory of the needle on its way across the target, or targets, established on the lesion.

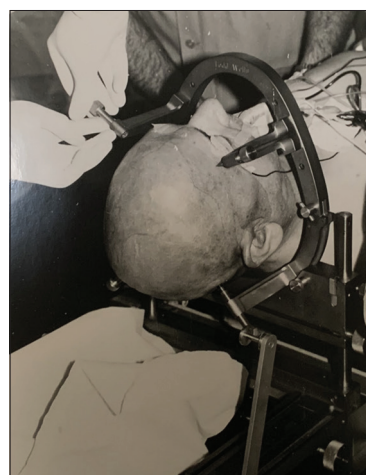

Figure 1: I Period (1982–1991), surgical planning. Patient and Todd-Wells stereotactic guide.

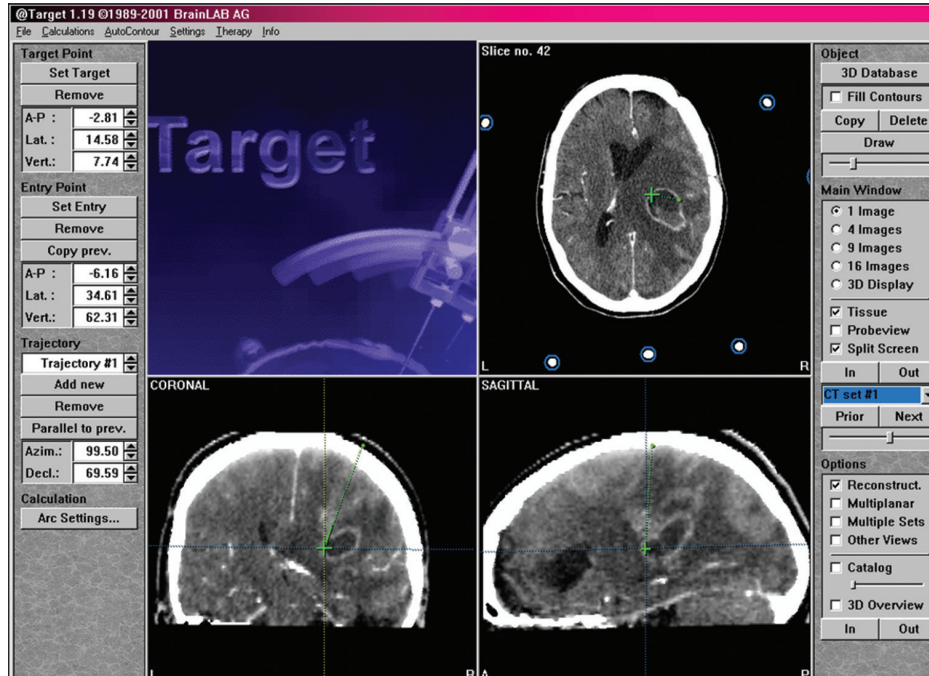


Figure 2: II Period (1991 – 2011), surgical planning. Contrast-enhanced CT scan 1 mm-thickness. Right parietal lesion. Calculations with Target 1.19 programme (Brainlab®).

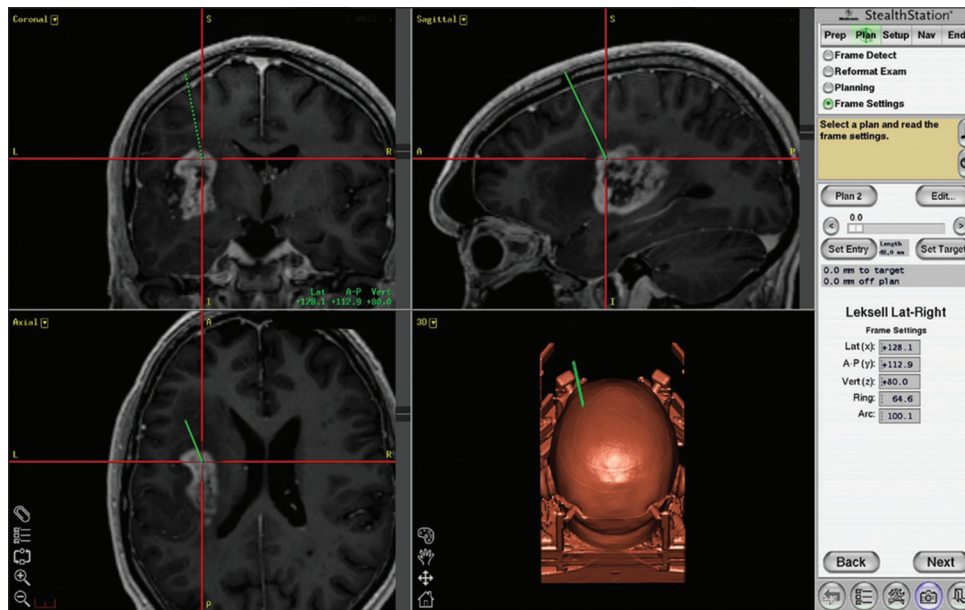


Figure 3: III Period (2011-2019), surgical planning. Contrast-enhanced 3D-T1-weighted 1 mm-thickness. Left thalamic lesion. Calculations with Framelink programme (Medtronic®).

Intraoperative histological evaluation was performed in tissue smears. The definitive histopathological evaluation was performed with fixation and staining techniques.

The WHO classification of central nervous system corresponding to 2007 and 2016 was used,^[38,39] due to the period in which the biopsies were performed.

Evaluation of morbidity-mortality

In our work, we term “symptomatic hemorrhage” as those which caused a worsening of the level of consciousness of the patient and/or the emergence of a new neurological deficit: aphasia, motor (paresis, paralysis) or sensory (numbness or anesthesia) deficits, or a worsening of the neurological

symptoms that the patients showed on admission. On the contrary, “asymptomatic hemorrhage” refers to those that, despite being found in the postoperative neuroimaging tests, had no repercussions on the clinical state of the patient.

The mortality was defined as those who died within 30 days of having the hemorrhage despite the established therapeutic measures.

After the stereotactic biopsy, patients were monitored in the intensive care unit or recovery room for 24 h. During I and II periods, postoperative control brain CT scans were only requested if there was a clinical deterioration of the patient, while in the III period, brain CT scans were routinely requested 24 h after the intervention.

Statistical analysis

Statistical analysis was developed with SPSS 26 for Windows (SPSS Inc., Chicago, Illinois, USA), using parametric tests.

The descriptive statistical study was developed on qualitative and quantitative variables.

The tests employed for the study of the statistical association between two independent variables were the Student's *t*-test and ANOVA test, along with the Bonferroni test, for the analysis of association between qualitative and quantitative variables with 2 or more than 2 categories, respectively, and the χ^2 test, with correction by means of the Fisher's exact test when necessary, for the qualitative variables. For the studies of association between two or more independent variables, the binary logistic regression test was applied (multivariate analysis).

The results were considered statistically significant for $P < 0.05$.

RESULTS

Demographic characteristics

We analyzed 429 different patients submitted to stereotactic biopsy in our department. More specifically, in the I period, 148 cases (34.5%) were biopsied, in the II period, 217 cases (50.6%), while in the III period, 64 cases (15%) were biopsied.

The series included 279 (65%) men and 150 (35%) women. The average age was 54.4 years. The age range was situated between 3 and 86 years; 14 patients (3.4%) belonged to the pediatric age group (≤ 16 years).

On neurological examination, the most relevant clinical signs were motor deficit in 31.5% ($n = 135$), followed by the absence of findings in 29.1% ($n = 125$), intracranial hypertension in 15.9% ($n = 68$), and intellectual function disorders in 11% ($n = 47$).

The lesions presented mainly left lateralization (42.7%; $n = 183$). The most frequently biopsied anatomical regions were

frontal (30.5%; $n = 131$), frontoparietal (15.4%; $n = 66$), parietal (13.5%; $n = 58$), and temporal (9.6%; $n = 41$). The least biopsied were intraventricular lesions (3%; $n = 13$), brainstem (1.4%; $n = 6$), and cerebellum (1.1%; $n = 5$).

After histological evaluation, the most frequently diagnosed pathologies were the tumors, and within the tumor pathology, the most frequent diagnoses were high-grade glioma (42.4%; $n = 182$) and low-grade glioma (22%; $n = 94$). We had 9.3% ($n = 40$) of nondiagnostic biopsies. In these patients, the stereotactic biopsy was repeated once in 72.5% of the cases ($n = 29$) and twice in 10% ($n = 4$). In 17.5% ($n = 7$), it was possible to perform a craniotomy.

In our work, the percentage of symptomatic intracranial hemorrhages that worsened the level of consciousness of the patient and/or meant the appearance of new neurological deficit after the biopsy was 9.5% ($n = 41$). A total of 21 patients (51.1%) had motor deficits, 10 cases (24.3%) had a worsening of the level of consciousness, 6 patients (10%) had aphasia, and 4 patients (14.6%) had sensory deficits. However, a large majority of those patients significantly improved or completely solved their symptomatology in the following days. Twenty-four of the patients (58.5%) were discharged with a Karnofsky Performance Status >80 . In this way, in our series, the permanent morbidity due to symptomatic hemorrhages was 3.9% ($n = 17$), whereas the associated mortality for this procedure was 0.93% ($n = 4$).

The demographic characteristics of the patients and pathologies, in the series and according to the methodological period, are shown in Table 1.

Hemorrhagic complications and associated factors

We found no statistically significant differences between the percentage of symptomatic intracranial hemorrhages or the percentage of mortality of the distinct methodological periods ($P = 0.780$).

• Characteristics of the lesion

In our series, we did not find that radiological characteristics of the lesion such as the effect of the mass on the surrounding cerebral parenchyma ($P = 0.81$) or the greater contrast enhancement ($P = 0.33$) were associated with a higher percentage of hemorrhagic complications.

On the other hand, and in terms of the biopsies on the lesions with a presence of a relevant cystic component in its structure, we obtained a greater percentage of symptomatic hemorrhages in biopsies of cystic lesions (13.7%) compared to the percentage of symptomatic hemorrhages in noncystic lesion biopsies (7.6%). However, there were no statistically significant differences ($P = 0.07$).

Symptomatic hemorrhage was produced in 8.6% of the total cases of biopsies performed on deep areas, specifically, in

Table 1: Descriptive profiles of patients and pathology.

	Series (n = 429) (%)	I Period (n = 148) (%)	II Period (n = 217) (%)	III Period (n = 64) (%)
Patient (no. of patients [%])				
Gender				
Men	279 (65)	94 (63.5)	146 (67.3)	39 (61)
Women	150 (35)	54 (36.5)	71 (32.7)	25 (39)
Age (years)				
Mean	54.4	49.6	55.2	58.6
Median	57	55	58	63
Range	3–86	3–86	4–82	15–81
Signs				
None	125 (29.1)	26 (17.5)	71 (32.7)	28 (44)
Intellectual disorders	47 (11%)	9 (6%)	30 (13.9)	8 (12.5)
Intracranial hypertension	68 (15.9)	51 (34.5)	17 (7.8)	0 (0)
Motor	135 (31.5)	49 (33.1)	64 (29.5)	22 (34.4)
Sensory	10 (2.3)	2 (1.4)	7 (3.2)	1 (1.4)
Others	44 (10.2)	11 (7.5)	28 (12.9)	5 (7.7)
Pathology (no. of patients [%])				
Side				
Right	163 (38)	61 (41.2)	73 (33.7)	29 (45.3)
Left	183 (42.7)	69 (46.2)	90 (41.5)	24 (37.5)
Bilateral	83 (19.3)	18 (12.6)	54 (24.8)	11 (17.2)
Region				
Frontal	131 (30.5)	48 (32.4)	61 (28.1)	22 (34.4)
Parietal	58 (13.5)	19 (12.8)	24 (11)	15 (23.4)
Frontoparietal	66 (15.4)	30 (20.3)	36 (16.6)	0 (0)
Temporal	41 (9.6)	12 (8.1)	24 (11)	5 (7.8)
Occipital	16 (3.8)	5 (3.4)	11 (5.1)	0 (0)
Intraventricular	13 (3)	5 (3.4)	8 (3.7)	0 (0)
Diencephalon	50 (11.7)	19 (12.8)	18 (8.3)	13 (20.3)
Cerebellum	5 (1.1)	2 (1.4)	2 (0.9)	1 (1.6)
Brainstem	6 (1.4)	2 (1.4)	1 (0.5)	3 (4.7)
Multiple	43 (10)	6 (4)	32 (14.8)	5 (7.8)
Diagnosis				
Tumoral pathology	340 (79.2)	113 (76.9)	173 (79.8)	54 (84.3)
High-grade glioma	182 (42.4)	59 (40.2)	88 (40.5)	35 (54.6)
Low-grade glioma	94 (22)	34 (23.1)	54 (24.8)	6 (9.3)
Ependymoma	1 (0.2)	0 (0)	1 (0.4)	0 (0)
Neuroblastoma	1 (0.2)	1 (0.7)	0 (0)	0 (0)
Lymphoma	21 (4.9)	2 (1.4)	7 (3.2)	12 (18.7)
Germinoma	2 (0.5)	0 (0)	2 (0.9)	0 (0)
Craniopharyngioma	5 (1.2)	2 (1.3)	3 (1.4)	0 (0)
Metastases	29 (6.8)	13 (8.9)	15 (6.9)	1 (1.5)
Arachnoid cyst	5 (1.2)	2 (1.3)	3 (1.4)	0 (0)
Vascular pathology (stroke)	22 (5.1)	16 (10.9)	6 (2.7)	0 (0)
Infectious disease	22 (5.1)	5 (3.4)	15 (6.9)	2 (3.1)
Radionecrosis	2 (0.5)	0 (0)	2 (0.9)	0 (0)
Neurological pathology	2 (0.5)	0 (0)	0 (0)	2 (3.1)
Nondiagnostic biopsy	40 (9.3)	13 (8.8)	21 (9.7)	6 (9.3)
Hemorrhagic complications	41 (9.5)	16 (10.8)	19 (8.7)	6 (9.3)
Permanent morbidity (KPS≤70)	17 (3.9)	7 (4.7)	8 (3.7)	2 (3.1)
Mortality	4 (0.93)	0 (0)	1 (0.4)	3 (4.6)

diencephalic structures (13.5%; $n = 58$), against 9.3% of the total biopsies performed on other areas (86.4%; $n = 371$). We found no association between the depth of the lesion and the hemorrhagic complications ($P = 0.91$).

In the case of biopsied lesions situated in the brainstem ($n = 6$), the morbidity and mortality were 0%.

We observed 11.6% of symptomatic hemorrhagic complications in biopsies of lesions with relevant

vascularization in their histological structure (high-grade gliomas, lymphomas, metastasis, and vascular tumors), compared with 8.1% of symptomatic hemorrhages in biopsies taken from other types of lesions ($P = 0.238$).

- Peculiarities of surgical procedure.

In our patients, general anesthesia was only used in 17 cases (3.9%), 6 of which were in children.

Our results showed that a greater percentage of symptomatic hemorrhages was produced if the biopsies were performed under general anesthesia (27.4%) compared to local anesthesia (9.1%). These differences were statistically significant ($P = 0.02$).

Furthermore, the analysis of multivariate logistical regression showed that the anesthetic technique constituted a predictive factor for symptomatic hemorrhage. Patients biopsied with general anesthesia were 19% more probable of presenting a hemorrhage than if they had been biopsied under local anesthesia (odds ratio = 0.24).

The incidence of symptomatic hemorrhages regarding the different modalities of image used was 8% (conventional radiology; 1982–1985), 10.1% (conventional radiology + CT scan; 1985–2002), 11.7% (CT scan; 2002–2011), and 9.5% (MRI; 2011–2019), without statistically significant differences ($P = 0.151$).

On the other hand, we observed a greater percentage of symptomatic hemorrhages when there were 2 or more targets (16.9%) compared with sample obtaining from only 1 target (9.7%), without reaching statistical significance ($P = 0.23$). Furthermore, we obtained 10.9% of symptomatic hemorrhages if a drill was performed compared with 6.7% of symptomatic hemorrhages if a burr hole was made ($P = 0.18$). However, during I period, we observed a greater number of symptomatic hemorrhages if a drill was performed ($P = 0.03$).

In this series, the biopsy tissue was obtained from 80.1% of the patients ($n = 344$) by a neurosurgeon with experience in stereotactic techniques (knowledge about the principles of stereotactic neurosurgery, planning programs, and stereotactic frames and instrumental). The percentages were 80.4% ($n = 119$) in I period, 89.8% ($n = 195$) in II period, and 68.7% ($n = 44$) in III period.

The analysis showed that hemorrhagic complications were produced in 8.5% of the total biopsies obtained by an experienced neurosurgeon in stereotactic techniques compared with 14.3% of symptomatic hemorrhages in the stereotactic biopsies performed by inexperienced neurosurgeons. No significant differences were found ($P = 0.13$).

On the other hand, in the III methodological period, we observed 2.7% of symptomatic hemorrhages if the biopsy was performed by experienced neurosurgeons compared with

26.3% of hemorrhagic complications in biopsies performed by inexperienced neurosurgeons ($P = 0.01$).

The analytical results, in the series and according to the methodological period, are found in Table 2.

Handling of postbiopsy patient

After the stereotactic biopsy, all the patients were under surveillance in the ICU or recovery room for 24 h.

During Periods I and II, where postoperative control brain CT scans were only requested if there was a clinical deterioration of the patient, this neuroimaging test was performed on 16 and 19 patients, respectively. All these cases could be observed postbiopsy hemorrhages. While, in Period III, where the brain CT scans were systematically requested 24 h after the intervention, we found hemorrhage in the postoperative CT scan of 14 patients (21.8%). In six cases, the hemorrhage resulted in neurological deterioration while in the other eight, the hemorrhage was small and asymptomatic.

In all the cases of symptomatic hemorrhage, neurological changes were observed within 3 h after the biopsy. In 17 patients, surgery was indicated due to the location and size of the hemorrhage.

DISCUSSION

Since the early 80s, stereotactic brain biopsy has been used to sample areas of the brain. Notwithstanding the rapid advances in methods of investigation, the treatment of intracranial lesions, especially gliomas, largely depends on obtaining a histological diagnosis. However, while early reports focused on the technical aspects of this procedure, recent reports addressed the diagnostic yield or the incidence and timing of complications after stereotactic biopsy.^[4,24,35,43,47-49,54]

Hemorrhagic complications of the stereotactic biopsy

Due to the nature of the minimally invasive technique, the potential risks and complications of the stereotactic biopsy are, sometimes, underestimated. In terms of symptomatic hemorrhagic complications, we have permanent morbidity figures lower than 4% and mortality lower than 1%. This is comparable to the figures in the literature [Table 3].^[1,5,8,16,22,25,29,32,33,37,45,52,61,63]

Patients with signs and symptoms of high intracranial pressure present a decrease of cerebral adaptation capacity and they could become incapable of absorbing small changes of volume in the intracranial content as a consequence of the appearance of hematomas, edema, or even, the insertion of surgical instruments after performing the biopsy. On the other hand, when this aspect has been studied closely, no relation between the lack of cerebral compliance expected in

Table 2: Symptomatic hemorrhagic complications and related variables.

	Series (n = 429) p*	I Period (n = 148) p*	II Period (n = 217) p*	III Period (n = 64) p*	Predictive factor (OR)
Lesion					
Radiological variables					
Contrast	P=0.33	P=0.15	P=0.41	P=0.59	-
Mass effect	P=0.81	P=0.78	P=0.81	P=0.31	-
Cyst	P=0.07	P=0.23	P=0.33	P=0.05	-
Location	P=0.91	P=0.83	P=0.72	P=0.79	-
Histopathology	P=0.27	P=0.06	P=0.97	P=0.87	-
Surgery					
Procedure					
Anesthesia	P=0.02*	P=0.03*	P=0.19	-	0.24
Image and target	P=0.15	-	-	-	-
Biopsy technique	P=0.18	P=0.03*	P=0.13	-	-
Number of targets	P=0.23	P=0.07	P=0.41	P=0.71	-
Operator's experience	P=0.13	P=0.89	P=0.51	P=0.01*	-

*The results were considered statistically significant if $P < 0.05$

Table 3: Review. Frame-based biopsies, large series. Diagnostic yield, symptomatic intracranial hemorrhages, and mortality.

Author	Patients (n)	Stereotactic device	Nondiagnostic biopsy (n [%])	Symptomatic hemorrhages (n [%])	Mortality (n [%])
Ostertag <i>et al.</i> ^[45] (1980)	302	Riechert-Mundinger	26 (8.7)	9 (2.9)	2 (2.3)
Edner ^[12] (1981)	345	Leksell	-	5 (1.4)	3 (0.9)
Sedan <i>et al.</i> ^[52] (1984)	318	Talairach	27 (8.5)	(3.5)	2 (0.6)
Apuzzo <i>et al.</i> ^[11] (1987)	500	BRW/CRW	22 (4.4)	2 (0.4)	1 (0.2)
Kelly ^[29] (1992)	547	COMPASS	10 (1.8)	5 (0.9)	2 (0.3)
Heilbrun <i>et al.</i> ^[25] (1993)	357	BRW	11 (3.1)	7 (2)	6 (1.7)
Bernstein and Parrent ^[5] (1994)	300	BRW	14 (4.7)	16 (5.3)	5 (1.7)
Yu <i>et al.</i> ^[63] (2000)	550	Leksell	19 (3.4)	41 (7.5)	0 (0)
Field <i>et al.</i> ^[16] (2001)	500	CRW	28 (5.6)	48 (9.6)	1 (0.2)
Kreth <i>et al.</i> ^[33] (2001)	345	Riechert (modified)	7 (2)	11 (3.1)	0 (0)
Grossman <i>et al.</i> ^[19] (2003)	355	CRW	22 (6.1)	13 (3.6)	2 (0.6)
Kongkham <i>et al.</i> ^[32] (2008)	622	CRW	10 (1.6)	42 (6.9)	8 (1.3)
Waters <i>et al.</i> ^[61] (2013)	267	Riechert-Mundinger	18 (6.7)	0 (0)	0 (0)
Livermore <i>et al.</i> ^[37] (2014)	302	CRW	14 (5.5)	9 (3.7)	5 (1.7)
Authors (2020)	429	Todd-Wells CRW Leksell	40 (9.3)	17 (3.9) (permanent morbidity)	4 (0.93)

patients with intracranial hypertension, and the appearance of symptomatic postbiopsy hemorrhagic complications has been found. In this line, we could cite studies such as Kreth *et al.*,^[33] Bernstein *et al.*,^[5] and Grossman *et al.*,^[21] as well as our own findings.

The location of the lesion, especially its depth, could condition the appearance of hemorrhagic complications during, or after, the procedure. In this manner, authors such as McGirt *et al.* found that the risk of presenting symptomatic postbiopsy hemorrhage of the basal ganglia or thalamus was 4.1 and 3.3 times more frequent, respectively, than if tissue sample was taken from other cerebral areas.^[42] Other authors obtained similar findings.^[31,37]

In contrast, an evaluation of 355 cases by Grossman *et al.* did not find association between the depth and a greater probability of suffering a hemorrhage ($P > 0.05$).^[21] Our results are similar ($P = 0.956$). We believe that these findings, in such a large series as ours, are the product of careful planning, in which we have aimed to minimize the length of the intracerebral trajectories to diminish the probability of inadvertent damage to the cerebral vessels.

With respect to the biopsies performed in the brainstem, the most extensive series, such as the work of Kickingereder *et al.*, with 1480 cases, or the meta-analysis of Samadami *et al.*, with 381 cases, gave figures of permanent morbidity <2% and mortality of 0.9% and 0.3%, respectively.^[30,50]

These good results could be justified by the fact that the approach trajectories to this region with stereotactic techniques are standardized and described in detail.

Malignant lesions with neovascularization and/or abnormal blood vessels such as high-grade gliomas, lymphomas, and metastases should be more prone to postbiopsy hemorrhage than other less aggressive lesions. In this way, Bernstein *et al.* observed that the percentage of hemorrhagic complications in patients biopsied with a high-grade glioma was 6.4%, in patients with lymphoma 6.3%, and in patients with metastasis 2.8%.^[5] Similar descriptive findings were reflected by Kulkarni *et al.*,^[34] Malikova *et al.*,^[41] and Dammers *et al.*^[10] While, analytical studies such as Kim *et al.*^[31] and Sawin *et al.*,^[51] in the case of gliomas, and Livermore *et al.*,^[37] in the case of lymphomas, found an association between the histology of these lesions and the appearance of postbiopsy intracranial hemorrhage ($P < 0.05$), compared with other colleagues such as Grossman *et al.*^[21] and Konghkhram *et al.*^[32] who found no association ($P > 0.05$). Our results are similar to the last works, as we found no association between variables ($P = 0.27$). We consider that this is a consequence of careful planning on the most appropriate neuroimaging sequences in each case.

Furthermore, and different to most published studies, we studied other radiological features of the pathology. We found that features strongly related with the vascularization of the pathology such as the degree of contrast enhancement ($P = 0.33$), or some structural peculiarities of the lesions such as the cystic component ($P = 0.07$), were not associated with a greater percentage of postbiopsy symptomatic hemorrhage. If we look at cystic lesions, it has been observed that a possible hemorrhage after taking the sample resolves itself spontaneously with more difficulty. In this manner, some authors suggest previously collapsing the cyst and then taking the histological sample.^[41] On the other hand, in view of our results and, with the objective of assuring the best diagnostic yield of the technique, we believe that an appropriate strategy is first to obtaining a sample from the wall of the lesion to coincide with the preplanned target and, once the quality of the sample by means of an intraoperative pathological study has been confirmed, to proceed with the drainage of the cystic component and/or insertion on the intracyst catheter if its size or nature so requires.

There are few works in the literature that study the type of anesthesia used during the stereotactic biopsy and the risk of the appearance of complications. We highlight the study by Weise *et al.*, with 274 patients, where he made clear that there were no differences in terms of the postbiopsy hemorrhagic complications when the intracranial sample was obtained under local anesthesia or general anesthesia ($P > 0.05$). However, general anesthesia caused greater percentages of postbiopsy respiratory complications and longer operation

times ($P < 0.05$).^[62] On the other hand, in our work, we could see a relation between general anesthesia and a greater frequency in the appearance of postbiopsy hemorrhagic complications ($P = 0.02$). Furthermore, as mentioned, with an odds ratio of 0.24, the anesthetic technique was configured as a predictor factor for symptomatic postbiopsy hemorrhages. These results could be explained by the lack of monitorization at the level of consciousness of the patient during the surgical intervention if performed with general anesthesia and the consequent late diagnosis of a possible intracranial bleeding. However, we are aware of having the patient awake is more likely to generate discomfort and motion that could lead to higher blood pressure (and thus increase risk of bleeding) than under controlled general anesthesia conditions. In this way, we consider that anesthetic technique should be established considering, mainly, the characteristics of the patients, and second, the intraoperative times and economic cost (local anesthesia is less expensive than general anesthesia) of these procedures.

During the stereotactic biopsy, an appropriate balance should be reached between an adequate histological sample to assure a good diagnosis and the possible risk of intracranial hemorrhage because of obtaining multiple biopsies. Diverse works refer to the relation between the number of biopsies performed and hemorrhagic complications. However, even though in most, the number and places of biopsies are not specified, the conclusion is that there is no relation between both variables,^[13,16,29,31,37,42] except in the case of the study of Sawin *et al.*, where this association was noted. Nevertheless, when evaluating this result objectively, it should be considered that the authors cite the average number of samples taken in each lesion was 22.^[51] From our point of view, this is excessive. If we concentrate on our findings, considering that we analyze the obtaining of between 3 and 4 samples from one or more targets, we observe a higher percentage of symptomatic hemorrhages in the case of having established two or more targets. However, there is no statistical significance ($P = 0.23$). Furthermore, this variable is not configured as a predictor factor of postbiopsy symptomatic hemorrhage.

In this series, the overall association of the biopsy technique (drill vs. burr hole) and symptomatic hemorrhages was not significant ($P = 0.18$). I period was an exception possibly because of the degree of heterogeneity in the technique (twist drills were made in 62.1% of the cases in I period, whereas, i.e., burr holes, and not twist drills, were performed in 100% of the patients in III period). We could see a greater number of symptomatic hemorrhages if a twist drill was made. This result can be explained by the greater visual control of the cortical vessels with a burr hole.

In this way, we believe that the ideal strategy for minimizing the risk of complications would be to establish a sole target

with a sole trajectory and take between 3 and 4 tissue samples. This strategy is facilitated by modern software planning.

Finally, among the reasons that have been mentioned as a possible cause of complications in stereotactic procedures, we find the experience of planning and developing the biopsy.^[5] Nevertheless, and as in other aspects, the studies of the relation between experience and complications have only been developed in a few works. The widest series was presented by McGirt *et al.* on 270 stereotactic biopsies, which found no differences between symptomatic hemorrhagic complications in biopsies developed by an experienced surgeon compared with an inexperienced surgeon ($P > 0.05$).^[42] The results obtained in our series are congruent with those shown in the literature ($P = 0.13$). However, when we carried out the analysis by methodological periods, we can see that in Period III, the percentage of symptomatic hemorrhages derived from biopsies performed by inexperienced surgeons (26.3%) was nearly 10 times greater than the percentage of symptomatic hemorrhages derived from experienced neurosurgeons (2.7%) ($P = 0.01$). In this period, there was a greater participation of inexperienced young neurosurgeons planning and performing the biopsies. Indeed, 27.7% ($n = 15$) were performed by neurosurgical residents without close supervision. In view of these findings, it should be emphasized that to minimize the risk of postbiopsy symptomatic hemorrhagic complications, both a sufficient level of knowledge of surgical anatomy and the principles of stereotactic neurosurgery are fundamental.

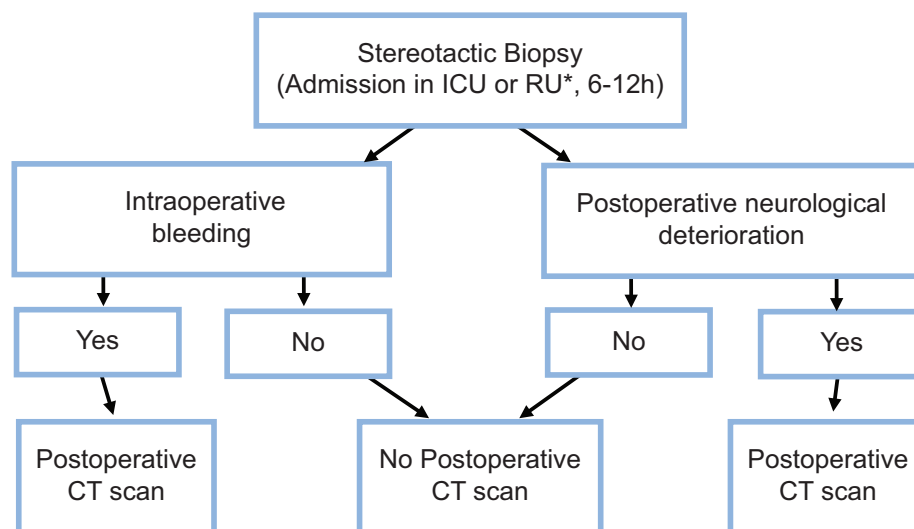
Handling of postbiopsy patient.

Despite the stereotactic biopsy is a procedure well established in neurosurgical departments, there are some works that have focused their attention on the immediate postoperative handling of the patients who have undergone this procedure.

With respect to the usefulness of performing a postsurgical control brain CT scan, some authors recommend its systematic implementation in the first few hours,^[42] compared to the majority who advise it to be performed only in specific situations.^[36,58,59]

In view of these works, and our results, and especially if we consider the findings from the III period where a postoperative CT scan was systematically made on all the patients, it can be stated that a routine postoperative CT scan does not seem to have any predictive value of the possible hemorrhagic complications during the admission of the patient. Thus, it seems reasonable to establish that a cerebral CT scan should be made if there is bleeding during the intervention or a postbiopsy neurological deficit. Furthermore, it should not be forgotten that the radiation derived from a brain CT scan is 2 mSv, a radiation dosage that needs 8 months to be eliminated,^[56] and that the cost of the study is around 70 \$.^[17]

With respect to the use of close patient surveillance during the 1st h after the surgery, most centers favor stays in intensive surveillance units during the first 24 h.^[14] Retrospective works such as by Warnick *et al.*^[59] and Kaakaji *et al.*^[27] found that all the neurological complications due to symptomatic hemorrhages were produced between 2 and 6 h, respectively, after the surgery. Similarly, prospective studies such as that by Bhardwaj *et al.*^[6] concluded that 4 h were enough observation period to detect a complication or not in the patient. In all our cases of symptomatic hemorrhagic complications, this happened in the first 3 h, during the period of intensive surveillance. Thus, the frequent neurological evaluation of these cases in units prepared for postoperative patient care is the most appropriate after stereotactic biopsies [Algorithm 1].



Algorithm 1: Handling of postbiopsy patient.

CONCLUSION

The stereotactic biopsy is a versatile, reliable, and safe procedure. It is a very valuable tool within the neurosurgical armamentarium for the diagnostic orientation and therapeutic handling of patients with intracranial lesions. In addition, the technological advances in the past decades and their adaptation to stereotactic biopsies facilitate this type of technique.

The appearance of symptomatic hemorrhagic complications after the biopsy of a cerebral lesion is not related with the anatomical site or its morphological features. While, both the use of the most appropriate MRI sequences for the planning of the biopsy and the local anesthesia during their carrying out are recommended actions to minimize the presentation of this complication. Furthermore, if we wish to minimize the risk of the hemorrhagic complications of this procedure, the neurosurgeon should have experience and interest in stereotactic techniques and different medical disciplines such as fundamental features before the selection of the patients, the effective establishment of the targets, and the appropriate handling of the stereotactic equipment.

Finally, it is fundamental that each patient submitted to a stereotactic biopsy is under surveillance in ICU or recovery units for 6–12 h. However, the request for postoperative CT scans should be conditioned by intraoperative events or by the neurological deterioration of the patient after the procedure.

Acknowledgements

I thank Javier Hernandez Vicente M.D., Ph.D, for his dedication, ideas and excellent labour as a Neurosurgeon. This series had not been possible without them.

Declaration of patient consent

Patient's consent not required as patients identity is not disclosed or compromised.

Financial support and sponsorship

Nil.

Conflicts of interest

There are no conflicts of interest.

REFERENCES

1. Apuzzo ML, Chandrasoma PT, Cohen D, Zee CS, Zelman V. Computed imaging stereotaxy: Experience and perspective related to 500 procedures applied to brain masses. *Neurosurgery* 1987;20:930-7.
2. Apuzzo ML, Sabshin JK. Computed tomographic guidance stereotaxis in the management of intracranial mass lesions. *Neurosurgery* 1983;12:277-85.
3. Arle J. Development of a classic: The Todd-wells apparatus, the BRW, and the CRW stereotactic frames. In: Lozano AM, Gildenberg PL, Tasker RR, editors. *Textbook of Stereotactic and Functional Neurosurgery*. New York: McGraw Hill; 2009. p. 453-67.
4. Bailey P, Stein SN. *A Stereotaxic Apparatus for Use on the Human Brain*. Atlantic City: AMA Scientific Exhibit; 1951.
5. Bernstein M, Parrent AG. Complications of CT-guided stereotactic biopsy of intra-axial brain lesions. *J Neurosurg* 1994;81:165-8.
6. Bhardwaj RD, Bernstein M. Prospective feasibility study of outpatient stereotactic brain lesion biopsy. *Neurosurgery* 2002;51:358-61.
7. Chen T, Apuzzo M. Biopsy techniques and instruments. In: Gildenberg PL, Tasker R, editors. *Textbook of Stereotactic and Functional Neurosurgery*. New York: McGraw-Hill; 1998. p. 397-410.
8. Colbassani HJ, Nishio S, Sweeney KM, Bakay RA, Takei Y. CT-assisted stereotaxic brain biopsy: Value of intraoperative frozen section analysis. *J Neurol Neurosurg Psychiatry* 1988;51:332-41.
9. Cosman E. Development and technical features of the Cosman-Roberts-Wells (CRW) stereotactic system. In: Pell F, Thomas DG, editors. *Handbook of Stereotaxy using the CRW Apparatus*. Baltimore: William & Wilkins; 1994. p. 1-52.
10. Dammers R, Haitsma IK, Schouten JW, Kros JM, Avezaat CJ, Vincent AJ. Safety and efficacy of frameless and frame-based intracranial biopsy techniques. *Acta Neurochir (Wien)* 2008;150:23-9.
11. De la Porte C. Technical possibilities and limitations of stereotaxy. *Acta Neurochir (Wien)* 1993;124:3-6.
12. Edner G. Stereotactic biopsy of intracranial space occupying lesions. *Acta Neurochir (Wien)* 1981;57:213-34.
13. Eibach S, Weise L, Setzer M, Seifert V, Senft C. Intraoperative bleeding in stereotactic biopsies and its implication on postoperative management: Can we predict CT findings? *Stereotact Funct Neurosurg* 2014;92:80-5.
14. Elder JB, Amar AP, Apuzzo MLJ. Stereotactic and image-guided biopsy. In: Lozano AM, Gildenberg PL, Tasker RR, editors. *Textbook of Stereotactic and Functional Neurosurgery*. New York: McGraw Hill; 2009. p. 646-62.
15. Elekta®. Leksell Stereotactic System. Sweden, Europe: Elekta; 2012.
16. Field M, Witham TF, Flickinger JC, Kondziolka D, Lunsford LD. Comprehensive assessment of hemorrhage risks and outcomes after stereotactic brain biopsy. *J Neurosurg* 2001;94:545-51.
17. Gelabert M. Administracion de la Comunidad Autonoma, Servicio de Salud de las Islas Baleares. Resolucion del Director General; 2014. Available from: <https://www.caib.es/eboibfront/ca/2014/8339/seccio-iii-altres-disposicions-i-actes-administrat/472>. [Last accessed on 2014].
18. Gildenberg PL. Spiegel and wycis-the early years. *Stereotact Funct Neurosurg* 2001;77:11-6.
19. Gildenberg PL. The history of stereotactic neurosurgery. *Neurosurg Clin N Am* 1990;1:765-80.

20. Gomez H, Barnett GH, Estes ML, Palmer J, Magdinec M. Stereotactic and computer-assisted neurosurgery at the Cleveland clinic: Review of 501 consecutive cases. *Cleve Clin J Med* 1993;60:399-410.
21. Grossman R, Sadetzki S, Spiegelmann R, Ram Z. Haemorrhagic complications and the incidence of asymptomatic bleeding associated with stereotactic brain biopsies. *Acta Neurochir (Wien)* 2005;147:627-31.
22. Hall WA. The safety and efficacy of stereotactic biopsy for intracranial lesions. *Cancer* 1988;82:1749-55.
23. Hariz M. CT scanning in stereotactic neurosurgery. In: Gildenberg PL, Tasker R, editors. *Textbook of Stereotactic and Functional Neurosurgery*. New York: McGraw-Hill; 1998. p. 265-70.
24. Hecaen H, Talairach T, David M, Dell MB. Memories origineux: Coagulations limitees du thalamus dans les algies du syndrome thalamique. *Rev Neurol (Paris)* 1949;81:917-31.
25. Heilbrun MP, Brockmeyer D, Sunderland P. Stereotactic surgery for mass lesions of the cranial vault. In: Apuzzo ML, editor. *Brain Surgery: Complications Avoidance and Management*. New York: Churchill-Livingston; 1993.
26. Hounsfield GN. Computerized transverse axial scanning. *Br J Radiol* 1973;46:1016-22.
27. Kaakaji W, Barnett GH, Bernhard D, Warbel A, Valaitis K, Stamp S. Clinical and economic consequences of early discharge of patients following supratentorial stereotactic brain biopsy. *J Neurosurg* 2001;94:892-8.
28. Kelly PJ. Applications and methodology for contemporary stereotactic surgery. *Neurol Res* 1986;8:2-12.
29. Kelly PJ. Stereotactic resection and its limitations in glial neoplasms. *Stereotact Funct Neurosurg* 1992;59:84-91.
30. Kickingeder P, Willeit P, Simon T, Ruge MI. Diagnostic value and safety of stereotactic biopsy for brainstem tumors: A systematic review and meta-analysis of 1480 cases. *Neurosurgery* 2013;72:873-82.
31. Kim JE, Kim DG, Paek SH, Jung HW. Stereotactic biopsy for intracranial lesions: Reliability and its impact on the planning of treatment. *Acta Neurochir (Wien)* 2003;145:547-54.
32. Kongkham PN, Knifed E, Tamber MS, Bernstein M. Complications in 622 cases of frame-based stereotactic biopsy, a decreasing procedure. *Can J Neurol Sci* 2008;35:79-84.
33. Kreth FW, Muacevic A, Medele R, Bise K, Meyer T, Reulen HJ. The risk of haemorrhage after image guided stereotactic biopsy of intra-axial brain tumours-a prospective study. *Acta Neurochir (Wien)* 2001;143:539-45.
34. Kulkarni AV, Guha A, Lozano A, Bernstein M. Incidence of silent hemorrhage and delayed deterioration after stereotactic brain biopsy. *J Neurosurg* 1998;89:31-5.
35. Leksell L. A estereotaxic apparatus for intracerebral surgery. *Acta Chir Scand* 1949;99:229-33.
36. Levin AB. Experience in the first 100 patients undergoing computerized tomography-guided stereotactic procedures utilizing the Brown-Roberts-Wells guidance system. *Appl Neurophysiol* 1985;48:45-9.
37. Livermore LJ, Ma R, Bojanic S, Pereira EA. Yield and complications of frame-based and frameless stereotactic brain biopsy-the value of intra-operative histological analysis. *Br J Neurosurg* 2014;28:637-44.
38. Louis DN, Ohgaki H, Wiestler OD, Cavenee WK, Burger PC, Jouvet A, *et al*. The 2007 WHO classification of tumours of the central nervous system. *Acta Neuropathol* 2007;114:97-109.
39. Louis DN, Perry A, Reifenberger G, Von Deimling A, Figarella-Branger D, Cavenee WK, *et al* The 2016 World Health Organization classification of tumors of the central nervous system: A summary. *Acta Neuropathol* 2016;31:803-20.
40. Lunsford LD, Coffey RJ, Cojocaru T, Leksell D. Image-guided stereotactic surgery: A 10 years evolutionary experience. *Stereotact Funct Neurosurg* 1990;54-55:375-87.
41. Malikova H, Liscak R, Latnerova I, Guseynova K, Syrucek M, Pytlik R. Complications of MRI-guided stereotactic biopsy of brain lymphoma. *Neuro Endocrinol Lett* 2014;35:613-8.
42. McGirt MJ, Woodworth GF, Coon AL, Frazier JM, Amundson E, Garonzik I, *et al*. Independent predictors of morbidity after image-guided stereotactic brain biopsy: A risk assessment of 270 cases. *J Neurosurg* 2005;102:897-901.
43. Narabayashi H. Stereotaxic instrument for operation on the human basal ganglia. *Psychiatr Neurol Jpn* 1952;54:669-71.
44. Netter FH. *Atlas of Human Anatomy*. New Jersey: Saunders; 2014.
45. Ostertag CB, Mennel HD, Kiessling M. Stereotactic biopsy of brain tumors. *Surg Neurol* 1980;14:275-83.
46. Paulsen F. *Sobotta: Atlas of Human Anatomy*. USA: Urban & Fischer; 2013.
47. Ranjan A, Vendatam R, Joseph T, Chandy MJ, Chandi SM. Nondiagnostic CT-guided stereotactic biopsies in a series of 407 cases: Influence of CT morphology and operator experience. *J Neurosurg* 1993;79:839-44.
48. Riechert T, Mundinger F. Indications, technique and results of the estereotactic operations upon the hypophysis using radioisotopes. *J Nerv Ment Dis* 1960;13:1-9.
49. Riechert T, Wolff M. Über ein neues Zielgeraet zur intrakraniellen elektrischen abteilung und ausschaltung. *Arch Psychiatr Z Neurol* 1951;186:225-30.
50. Samadani U, Judy KD. Stereotactic brainstem biopsy is indicated for the diagnosis of a vast array of brainstem pathology. *Stereotact Funct Neurosurg* 2003;81:5-9.
51. Sawin PD, Hitchon PW, Follett KA, Torner JC. Computed imaging-assisted stereotactic brain biopsy: A risk analysis of 225 consecutive cases. *Surg Neurol* 1998;49:640-9.
52. Sedan R, Peragut JC, Farnarier P. Modern imaging and stereotaxy. *Neurochirurgie* 1987;33:29-32.
53. Sedan R, Peragut JC, Farnarier PH. Intraencephalic stereotactic biopsies (309 patients/319 biopsies). *Acta Neurochir Suppl (Wien)* 1984;33:207-10.
54. Spiegel EA, Wycis HT, Marks M, Lee AJ. Stereotaxic apparatus for human brain. *Science* 1947;106:349-50.
55. Spiegel EA. *Guided Brain Operations: Methodological and Clinical Developments in Stereotactic Surgery, Contributions to the Physiology of Subcortical Structures*. New York: John Wiley & Sons; 1983.
56. Task Group on Radiation Quality Effects in Radiological Protection, Committee 1 on Radiation Effects, International Commission on Radiological Protection. Relative biological effectiveness (RBE), quality factor (Q), and radiation weighting factor (wR). A report of the international commission on radiological protection. *Ann ICRP* 2013;33:1-117.

57. Todd EM. Todd-Wells Manual for Stereotactic Procedures. Randolph, MA: Codman and Shurtleff; 1967.
58. Voges J, Schröder R, Treuer H, Pastyr O, Schlegel W, Lorenz WJ, *et al.* CT-guided and computer assisted stereotactic biopsy. Technique, results, indications. *Acta Neurochir (Wien)* 1993;125:142-9.
59. Warnick RE, Longmore LM, Paul CA, Bode LA. Postoperative management of patients after stereotactic biopsy: Results of a survey of the AANS/CNS section on tumors and a single institution study. *J Neurooncol* 2003;62:289-96.
60. Watanabe E, Watanabe T, Manaka S, Mayanagi Y, Takakura K. Three-dimensional digitizer (neuronavigator): New equipment for computed tomography-guided stereotaxic surgery. *Surg Neurol* 1987;27:543-7.
61. Waters JD, Gonda DD, Reddy H, Kasper EM, Warnke PC, Chen CC. Diagnostic yield of stereotactic needle-biopsies of sub-cubic centimeter intracranial lesions. *Surg Neurol Int* 2013;4:S176-81.
62. Weise LM, Bruder M, Eibach S, Seifert V, Byhahn C, Marquardt G, *et al.* Efficacy and safety of local versus general anesthesia in stereotactic biopsies: A matched-pairs cohort study. *J Neurosurg Anesthesiol* 2013;25:148-53.
63. Yu X, Liu Z, Tian Z, Li S, Huang H, Xiu B, *et al.* Stereotactic biopsy for intracranial space-occupying lesions: Clinical analysis of 550 cases. *Stereotact Funct Neurosurg* 2000;75:103-8.

How to cite this article: Lara-Almunia M, Hernandez-Vicente J. Symptomatic intracranial hemorrhages and frame-based stereotactic brain biopsy. *Surg Neurol Int* 2020;11:218.