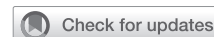

Patient-specific simulation for tracheobronchial reconstruction procedures using 3-dimensional operable models: A proof-of-concept study



Kohei Hashimoto, MD, PhD, Kenshiro Omura, MD, Naoya Iwamoto, MD, Junji Ichinose, MD, PhD, Yosuke Matsuura, MD, PhD, Masayuki Nakao, MD, PhD, and Mingyon Mun, MD, PhD, Tokyo, Japan

From the Department of Thoracic Surgical Oncology, Cancer Institute Hospital, Japanese Foundation for Cancer Research, Tokyo, Japan.

Supported by divisional funding and Grant-in-Aid for Scientific Research, the Ministry of Education, Culture, Sports, Science and Technology, Japan (20K17762).

Disclosures: The authors reported no conflicts of interest.

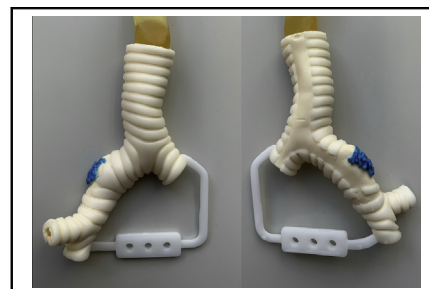
The *Journal* policy requires editors and reviewers to disclose conflicts of interest and to decline handling or reviewing manuscripts for which they may have a conflict of interest. The editors and reviewers of this article have no conflicts of interest.

Received for publication Nov 30, 2021; accepted for publication Feb 16, 2022; available ahead of print Feb 21, 2022.

Address for reprints: Kohei Hashimoto, MD, PhD, Department of Thoracic Surgical Oncology, Cancer Institute Hospital, Japanese Foundation for Cancer Research, 3-8-31 Ariake, Koto, Tokyo, 135-8550 Japan (E-mail: kohei.hashimoto@jfc.or.jp).

JTCVS Techniques 2022;14:138-40
2666-2507

Copyright © 2022 The Author(s). Published by Elsevier Inc. on behalf of The American Association for Thoracic Surgery. This is an open access article under the CC BY license (<http://creativecommons.org/licenses/by/4.0/>).
<https://doi.org/10.1016/j.jtc.2022.02.023>



An operable 3D airway model for patient-specific simulation based on computed tomography.

CENTRAL MESSAGE

Operable 3D printed airway models with precise human anatomy, including invasive lesions, demonstrate promise for practical, patient-specific surgical simulation for tracheobronchial reconstruction.

▶ Video clip is available online.

In the Cone of Experience claimed by Edgar Dale in 1946, simulated activity was considered the second-best learning experience after actual activity.¹ This is still valid in modern surgical practice where both patient safety and learning experience need to be protected. Surgical simulation may be particularly beneficial for rare, complex, and high-risk procedures such as tracheobronchial reconstruction. Operable airway models using preoperative computed tomography (CT) data were developed to assist in the patient-specific simulation of tracheobronchial reconstruction procedures.

METHODS

This retrospective study included 3 patients with non-small cell lung cancers who underwent sleeve lobectomies: right upper sleeve lobectomy (case 1, a 76-year-old man), right middle and lower sleeve lobectomy (case 2, a 60-year-old woman), and left lower and lingular segment extended sleeve lobectomy (case 3, a 59-year-old man). The invasive lesion in the central airway was annotated (Synapse Vincent; Fujifilm) in each preoperative enhanced chest CT (slice thickness, 1.25 mm) image (Figure 1, A). The Digital Imaging and Communications in Medicine data were converted to 3-dimensional (3D) data (OsiriX MD version 12.0; Pixmeo). The invasive lesion was demarcated by subtracting the CT data from the

annotated CT data (Figure 1, B). The airway structure was determined, and the cartilage was distinguished from other connective tissues (Geomagic Freeform; 3D Systems) (Figure 1, C). The data were then converted into the Standard Triangle Language format for 3D printing using the Geomagic Freeform software. The hard plastic models of the cartilage and other tissues were separately 3D-printed (SCS-8100; Sony Manufacturing Systems) to serve as frameworks for the creation of silicone molds. Two urethane materials mimicking the cartilage (Hapla Pudding Gel-PL00; Polysis) and the remaining connective tissue, including the invasive lesion (Adapt, RU-843A-N80; Nisshin Resin) were poured into the molds, while the 2 parts were combined using a vacuum casting method (CrossMedical). Gauze strips were integrated into the connective-tissue part to strengthen the cut-resistance. The invasive lesions were highlighted in blue. Each model was evaluated by the surgeon of each operation. This study was approved by our institutional ethical review board (No. 2020-GA-1334) on May 28, 2021, and consent was waived because of its retrospective nature.

RESULTS

Three models, including invasive lesions, were successfully created (Figure 2). Three surgeons successfully reproduced the surgical procedures in the 3D airway

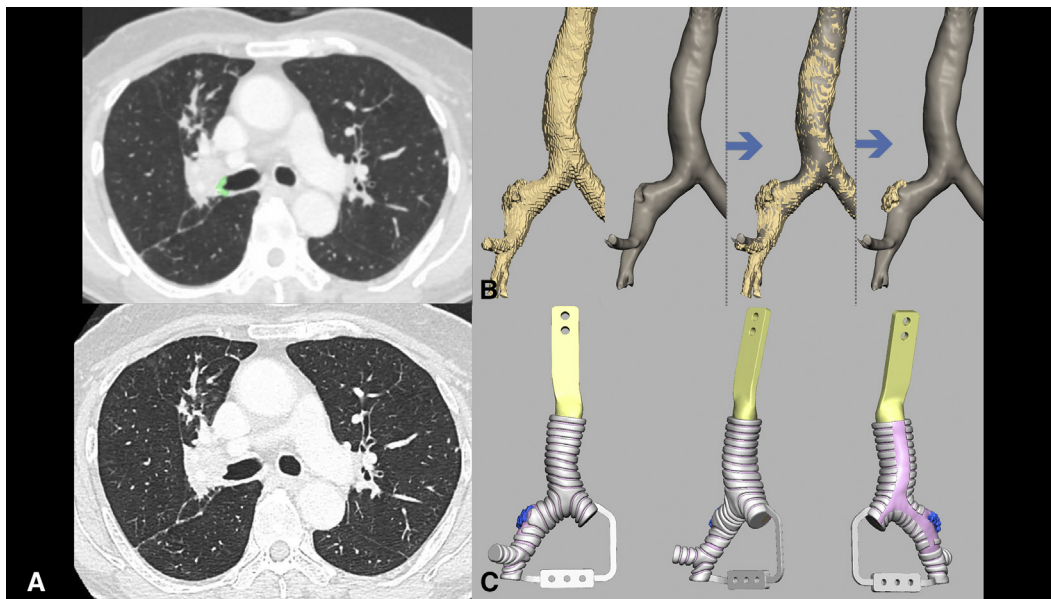


FIGURE 1. The sequence of the creation of the model (case 1: right upper sleeve lobectomy). A, Upper: The invasive area on the central airway was annotated (green) on preoperative chest computed tomography (CT) images. Lower: The same slice of the chest CT without annotation (raw CT data). B, The demarcation of the invasive lesion in the central airway by subtracting raw CT data from annotated CT data. C, The design of a 3-dimensional airway model using data obtained from chest CT. Note that the pink-area (connective tissue) is separately recognized from the white area (cartilage).

models (Video 1). The models were rated based on how closely these reproduced actual surgeries (Likert scale where 1 = poor to 5 = excellent). The median scores were acceptable: anatomical reproducibility, 5 (range, 4-5); disease reproducibility, 4 (range, 4-5); surgical exposure, 4 (range, 3-5); rigidity, 3 (range, 2-4); elasticity, 4 (range, 3-5); resistance to needles, 3 (range, 2-4); and resistance to tying, 3 (range, 3-4). The time from initial planning chest CT (re-evaluation CT was

performed, when necessary, which did not change the surgical plan) to actual surgeries in cases 1, 2, and 3 were 25, 36, and 27 days, respectively. The time from data extraction to receiving of the model was 31, 17, and 17 days, respectively in these retrospective settings. The authors (thoracic surgeons) needed approximately an hour to depict disease lesions using the software, extract data, and examine the 3D design of the model before manufacturing each model.

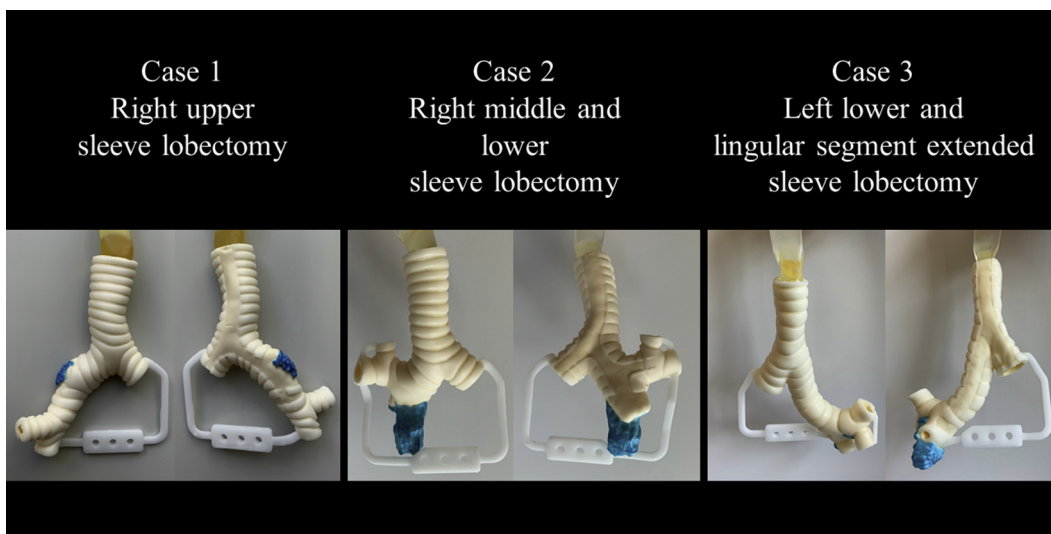
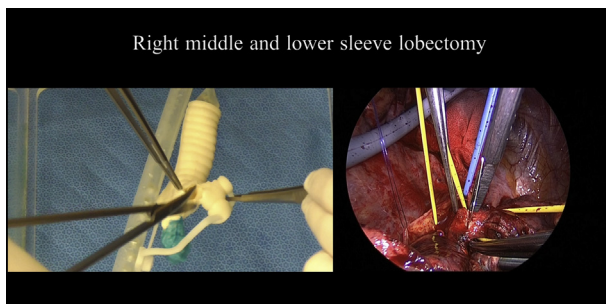


FIGURE 2. A 3-dimensional airway model consisting of multiple urethan materials representing the cartilage and the remaining connective tissue, including the invasive lesion in the central airway. Note that the invasive lesion is highlighted in blue color on the outer surface.



VIDEO 1. The demonstration of comparison between sleeve lobectomies reproduced using the airway model and the actual surgeries (cases 2 and 3). Video available at: [https://www.jtcvs.org/article/S2666-2507\(22\)00131-6/fulltext](https://www.jtcvs.org/article/S2666-2507(22)00131-6/fulltext).

DISCUSSION

In this retrospective study, the feasibility of creating an interactive 3D airway model for a patient-specific tracheobronchial simulation was proven. Theoretically, any type of invaded airway can be created using this methodology. The cases included in this study are usually manageable without simulation by experienced surgeons. However, simulation may benefit junior surgeons and even experienced surgeons when they encounter highly complex reconstruction, such as carinal reconstruction.^{2,3} In the field of thoracic surgery, 3D-printed models have been proposed for the purpose of surgical simulation by appreciating real-size anatomy.⁴ However, our airway model is the first interactive patient-specific model for tracheobronchial surgery to our

knowledge. Compared with existing simulation models based on animals or cadavers, we believe that our model has an advantage due to its portability and better anatomical clarity, including target diseases.

We required 31 days for creating a model for case 1 because it involved a trial-and-error process. Based on the knowledge obtained from the first model, the latter 2 models, for cases 2 and 3, were successfully made within 3 weeks. With this model, we plan to create a program of patient-specific simulation for tracheobronchial surgery.

CONCLUSIONS

3D-printed operable airway models representing precise airway anatomy, including invasive lesions, were successfully created based on preoperative CT data, demonstrating promise for prospective patient-specific simulation for tracheobronchial reconstruction.

The authors thank Drs. Takashi Yamamichi, Satoru Tamagawa, Yasuto Kondo, and Hiroki Ozawa for assisting with surgical simulation on the models.

References

1. Dale E. *Audio-Visual Methods in Teaching*. Dryden Press; 1946.
2. Grillo HC. Carinal reconstruction. *Ann Thorac Surg*. 1982;34:356-73.
3. Costantino CL, Geller AD, Wright CD, Ott HC, Muniappan A, Mathisen DJ, et al. Carinal surgery: a single-institution experience spanning 2 decades. *J Thorac Cardiovasc Surg*. 2019;157:2073-83.e1.
4. Hoetzenecker K, Chan HHL, Frommlet F, Schweiger T, Keshavjee S, Waddell TK, et al. 3D models in the diagnosis of subglottic airway stenosis. *Ann Thorac Surg*. 2019;107:1860-5.