



Thoracic vertebral canal stenosis due to articular process hypertrophy in two cats treated by hemilaminectomy with partial osteotomy of the spinous process

Journal of Feline Medicine and Surgery Open Reports
1–5

© The Author(s) 2019

Article reuse guidelines:

sagepub.com/journals-permissions

DOI: 10.1177/2055116919863176

journals.sagepub.com/home/jfmsopenreports

This paper was handled and processed by the European Editorial Office (ISFM) for publication in *JFMS Open Reports*



Beatrice Enrica Carletti, Irene Espadas 
and Daniel Sanchez-Masian

Abstract

Case summary A 9-year-old neutered female British Shorthair cat (case 1) and a 13-year-old neutered male domestic shorthair cat (case 2) showed signs of chronic T3–L3 myelopathy, which progressed over 6 and 12 months, respectively. On presentation, case 1 had moderate pelvic limb proprioceptive ataxia and ambulatory paraparesis, and case 2 was non-ambulatory paraparetic and had urinary incontinence. Bilateral enlargement of the articular process joints at T11–T12 in case 1 and T3–T4 in case 2 causing dorsolateral extradural spinal cord compression was shown on MRI. Surgical decompression by a unilateral approach through hemilaminectomy with partial osteotomy of the spinous process was performed in both cases. The side of the approach was chosen based on the severity of the cord compression. Surgery resulted in a satisfactory outcome with short hospitalisation times. On discharge, case 1 showed mild postural reaction deficits on both pelvic limbs. Case 2 had regained urinary continence and could ambulate unassisted, although it remained severely ataxic. The 6 month follow-up showed very mild paraparesis and proprioceptive ataxia in both cats. No chronic medical treatment was required.

Relevance and novel information This is the first report to describe clinical presentation, imaging features, surgical treatment and outcomes of thoracic vertebral canal stenosis owing to bilateral articular process hypertrophy in cats with no adjacent spinal diseases. Thoracic articular process hypertrophy should be included in the differential diagnosis of adult cats with chronic progressive myelopathy. Hemilaminectomy with partial osteotomy of the spinous process might be an appropriate surgical technique in these cases.

Keywords: Articular process hypertrophy; thoracic spine; hemilaminectomy; spinal decompression surgery

Accepted: 19 June 2019

Introduction

Articular process degeneration and hypertrophy is a rarely described cause of vertebral canal stenosis and spinal cord compression in cats; however, it is a well-recognised and frequently described pathology in dogs. The most commonly reported osteoarthritic changes of the articular processes and pedicles are found in the cervical spine of young giant breeds with osseous-associated cervical spondylomyelopathy.¹ Thoracic spinal canal stenosis due to congenital hypertrophy of the articular processes and/or the dorsal lamina has been described in

juvenile, large and giant, brachycephalic breeds.^{2–6} Similar but malformed, rather than hypertrophic, articular

Department of Small Animal Clinical Science, Institute of Veterinary Science, University of Liverpool, Neston, UK

Corresponding author:

Beatrice Enrica Carletti DVM, University of Liverpool, Department of Small Animal Clinical Science, Institute of Veterinary Science, Leahurst Campus, Chester High Road, Neston, Cheshire CH64 7TE, UK

Email: beatrice.carletti@gmail.com



Creative Commons Non Commercial CC BY-NC: This article is distributed under the terms of the Creative Commons

Attribution-NonCommercial 4.0 License (<http://www.creativecommons.org/licenses/by-nc/4.0/>) which permits non-commercial use, reproduction and distribution of the work without further permission provided the original work is attributed as specified on the SAGE and Open Access pages (<https://us.sagepub.com/en-us/nam/open-access-at-sage>).

process have been reported recently in the thoracic and lumbar spine of adult dogs adjacent to fused vertebral segments affected by diffuse idiopathic skeletal hyperostosis (DISH).^{7,8} An association between increased biomechanical stress of the vertebral joints contiguous to fused vertebral segments affected by DISH, leading to facet degeneration, is suspected in these cases, in a phenomenon known in humans as adjacent segment disease.⁹

Thoracic vertebral canal stenosis owing to articular process hypertrophy has been reported only once in the cat.¹⁰ In this particular case the articular degenerative process was thought to be secondary to contiguous DISH, in a similar pathophysiological process to that described in dogs and humans.

We present a report of two feline cases of thoracic vertebral canal stenosis where articular process hypertrophy presented alone, with no concurrent adjacent spinal disease. Clinical presentation, imaging characteristics, surgical treatment and outcomes are described.

Case description

Case 1

A 9-year-old neutered female British Shorthair cat presented with chronic pelvic limb ataxia, which progressed over 6 months. Neurological examination showed moderate pelvic limb proprioceptive ataxia and ambulatory paraparesis with markedly delayed postural reaction, which was worse on the left-hand side, and normal myotactic spinal reflexes. No obvious spinal hyperaesthesia was noted; however, the owners reported improved exercise tolerance when non-steroidal anti-inflammatory drugs were administered. The lesion was localised to the T3–L3 spinal cord segments.

MRI (Ingenia 1.5 Tesla; Philips) and CT (Toshiba Prime Aquilion; Toshiba Medical Systems) of the thoracolumbar spine were performed (Figure 1) and revealed the presence of bilateral smooth enlargement of the articular processes at T11–T12, with these projecting into the vertebral canal and causing moderate bilateral

dorso-lateral extradural compression of the spinal cord, which was slightly more evident on the left-hand side. On T2-weighted MRI there was a focal area of intramedullary hyperintensity (compared with normal spinal cord grey matter) extending from caudal T10 to cranial T13, compatible with gliosis or spinal cord oedema secondary to the compression. Mild ventral spondylosis was apparent at T11–T12. The remainder of the thoracolumbar spine was unremarkable.

Case 2

A 13-year-old neutered male domestic shorthair cat was referred with a 12 month history of pelvic limb proprioceptive ataxia and paraparesis, which progressed to non-ambulatory paraparesis and an inability to completely empty the bladder. On presentation, the cat was non-ambulatory paraparetic. Mild voluntary motor movement of the pelvic limbs was present, and this was significantly worse on the right-hand side. The postural reactions were absent bilaterally in the pelvic limbs. The myotactic spinal reflexes were normal and the cutaneous trunci reflex was absent. Mild thoracic hyperaesthesia was elicited on palpation of the cranial thoracic spine. The lesion was neuroanatomically localised to the T3–L3 spinal cord segments, most likely to the cranial thoracic segments, owing to the absence of the cutaneous trunci reflex.

MRI of the thoracolumbar spine (Figure 2) revealed enlargement and sclerosis of the articular processes at T3–T4, which was more marked on the right-hand side. The dorsal lamina of T3 was also bilaterally smoothly enlarged. Mild intervertebral disc protrusion and ventral spondylosis deformans were also present at T3–T4. As a result, the spinal cord was severely dorsoventrally compressed, more significantly dorsally and on the right-hand-side, and severely flattened in a triangular shape. There was focal intramedullary hyperintensity at the site of the compression compatible with gliosis or oedema. Multiple mild disc protrusions without significant spinal cord compression were observed in the caudal thoracic and lumbar spine.

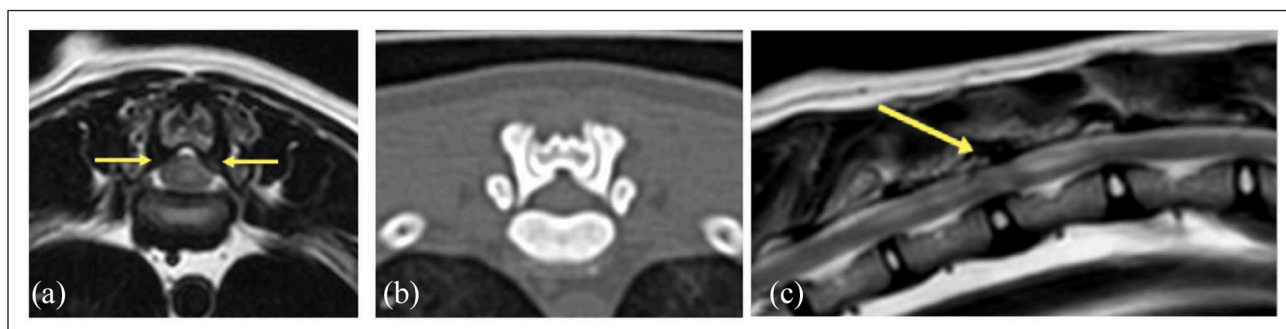


Figure 1 Case 1: (a) T2-weighted transverse MRI; (b) CT transverse at the level of T11–T12; and (c) T2-weighted sagittal MRI showing enlargement and misshaping of the articular process (arrow) causing dorsolateral spinal cord compression bilaterally and intramedullary hyperintensity extending cranially and caudally

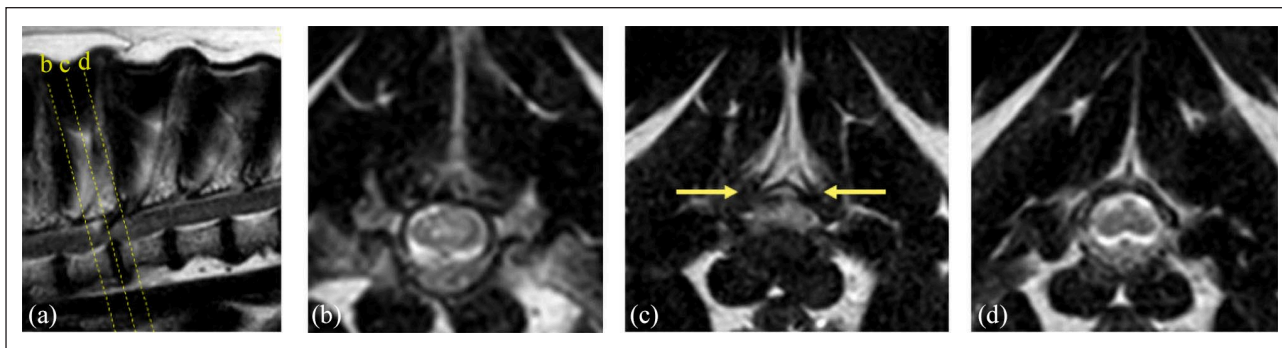


Figure 2 Case 2: (a) T2-weighted sagittal and (b–d) T2-weighted transverse MRI at the level of T3–T4 showing similar triangular misshaping of the spinal cord and focal intramedullary hyperintensity owing to dorsolateral extradural compression caused by articular process and mild lamina hypertrophy (arrows) at T3–T4 in case 2. Mild associated intervertebral disc protrusion was also present in this case

Surgical procedure and outcome

Both cats were premedicated with medetomidine (4 µg/kg IV) and methadone (0.2 mg/kg IV), induced with alfaxalone (2 mg/kg IV) and maintained with 1–2% isoflurane alongside a continuous rate infusion (CRI) of ketamine (0.5 mg/kg/h) (case 1), or fentanyl (2 µg/kg/h) and medetomidine CRI (22 µg/kg/h) (case 2). Lactated Ringer's solution (10 ml/kg/h IV) was administered throughout surgery. Cefazolin (10 mg/kg IV) was administered immediately before induction and every 2h during the procedure. Monitoring included electrocardiography, end-tidal CO₂ concentration, SpO₂ and invasive blood pressure measurement. The anaesthetised cats were positioned in light oblique sternal recumbency.

A conventional dorsolateral approach was made to the transverse processes of T11–T12 (case 1) and T3–T4 (case 2). The side of the approach was chosen based on the severity of the cord compression (case 1, left-sided; case 2, right-sided). The vertebral lamina and articular process were removed by pneumatic drilling (5058-01 Hall Surgairtome Two; ConMed). In order to allow further dorsal decompression, the hemilaminectomy was extended dorsally by removing the base of the spinous processes and the portion of dorsal lamina underlying the spinous process.

Satisfactory decompression of the dorsolateral aspect of the spinal cord was achieved. No intraoperative complications were noted. Postoperative care consisted of analgesia (methadone 0.2 mg/kg IV q4h or buprenorphine 0.02 mg/kg IV q8h, meloxicam 0.05 mg/kg PO q24h and gabapentin 5 mg/kg q12h), exercise restriction for 4 weeks and physical therapy.

Surgery resulted in satisfactory outcomes with short hospitalisation times (median 5 days) in both cases. On discharge, case 1 showed only mild postural reaction deficits. Case 2 regained urinary continence and could ambulate unassisted but remained severely ataxic. The 6 month follow-up showed very mild paraparesis and

proprioceptive ataxia in both cats. No chronic medical treatment was required.

Discussion

This paper describes two feline cases of thoracic articular process hypertrophy causing vertebral canal stenosis and subsequent myelopathy. Articular process hypertrophy is a well-recognised pathological entity as a cause of cervical spinal canal stenosis in dogs.¹ Although such changes are less commonly found in the thoracic spine, articular process and/or dorsal lamina hypertrophy leading to stenosis of the thoracic vertebral canal have been described in juvenile, large and giant, mostly brachycephalic, breeds.^{2–6} Often more than one vertebral site was affected by the stenosis in these dogs, with T2–T3 being the most commonly affected site.² In these cases, the pathogenesis of the articular process hypertrophy was thought to be due to developmental abnormalities, bone dysplasia or malarticulation, and in some cases concurrent osseous cervical spondylomyelopathy was present.² Malformed articular and spinous processes can develop in the thoracic and lumbar spine adjacent to fused vertebral segments in adult dogs affected by DISH.^{7,8}

In cats, similar degenerative changes of the articular process were previously described in a 9-year-old domestic shorthair cat at T4–T5 alongside adjacent DISH, extending from T5–S1.¹⁰ In this case, the articular facet degeneration was thought to be subsequent to altered biomechanical forces of the mobile vertebral segments, contiguous to the fused vertebral segments involved in the DISH process. This phenomenon is known as adjacent segment disease and, although its exact mechanism is still unknown, it has been reported in humans and dogs.^{7–9}

The cases reported here had no adjacent spinal disease. Spondylosis deformans was detected in both our cases at the same intervertebral disc space of the

articular process hypertrophy. Spondylosis deformans is a non-inflammatory bony response to intervertebral disc degeneration or vertebral instability in an 'attempt' by the body to re-establish stability of the intervertebral disc space.¹¹ It commonly embraces ventrally the cranial and caudal vertebral endplates but does not involve the whole ventral surface of the vertebral body, as typically seen in DISH.¹¹ As such, in these cases spondylosis deformans represents most likely the result of chronic vertebral instability rather than the origin of biomechanical forces alteration.

The origin of the vertebral instability in case 1 is uncertain as no obvious concomitant spinal pathology was detected in the MRI or CT images. However, by nature, the caudal thoracic spine is subjected to increased torsional biomechanical forces compared with other spinal regions and this can contribute to the formation of the degenerative changes in the facets joints. In case 2, the articular process hypertrophy developed at T3–T4. The cranial thoracic vertebral region is considered the most stable along the spine; however, the presence of the chronic intervertebral disc protrusion may have predisposed to instability and subsequent hypertrophic changes of the articular processes.

Articular process hypertrophy is often associated with mild, slowly progressive, neurological deficits and therefore conservative medical management can result in satisfactory control of the clinical signs.^{2,10} However, owing to the progressive nature of the disease, once the neurological signs become more severe, surgical intervention by hemilaminectomy or dorsal laminectomy should be considered.

While dorsal laminectomy is generally preferred for lesions located dorsally or dorsolaterally within the spinal canal, it requires extensive, bilateral paraspinal muscle dissection.¹² Removal of the dorsal spinous processes and median ligament increases spinal instability compared with unilateral hemilaminectomy.^{12,13} Therefore, not uncommonly, hemilaminectomy is chosen in the case of articular process hypertrophy, despite the bilateral nature of the stenosis.^{1,4} This choice is aimed at decompressing the spinal cord on the most affected side, without compromising vertebral stability. Decreased soft tissue trauma and preservation of stability represent the main advantages of the latter technique. In human patients, successful treatment of bilateral spinal cord compression via a unilateral approach has been reported.^{14,15} A significant increase in immediate postoperative deterioration has been reported for dachshunds treated by dorsal laminectomy vs hemilaminectomy for thoracolumbar intervertebral disc disease.¹⁶

In the cases described here spinal decompression by a unilateral approach through a combination of dorsal laminectomy and hemilaminectomy, similar to the

approach described by Forterre et al,¹² was chosen in order to decompress dorsolaterally the spinal cord without compromising vertebral stability. By performing partial osteotomy of the spinous processes overlying the hypertrophic articular process, partial dorsal decompression was allowed in order to further relieve the spinal cord compared with a routine hemilaminectomy.¹² Although the compression caused by the hypertrophic articular process on the opposite side of the surgery was not relieved, the marked postoperative improvement shown in both cases suggests that the chosen surgical procedure can satisfactorily decompress the spinal cord without the requirement for more extended or invasive techniques, such as spinal stabilisation secondary to decompression. However, it cannot be excluded that spinal stabilisation was not required in the cases described in this report owing to the low body weight of the cats and that this may still be required when the same surgical procedure is performed in dogs with higher body weight and size.

Conclusions

This is the first case report to present imaging characteristics, surgical treatment and outcomes of thoracic vertebral canal stenosis due to articular process hypertrophy in two cats without a concomitant adjacent spinal disease. Articular process degeneration should be included in the differential diagnosis of adult cats with chronic progressive myelopathy. Additionally, this report suggests that surgical treatment may be the key for satisfactory outcomes and hemilaminectomy with partial osteotomy of the spinous process might be an appropriate treatment in these cases.

Conflict of interest The authors declared no potential conflicts of interest with respect to the research, authorship, and/or publication of this article.

Funding The authors received no financial support for the research, authorship, and/or publication of this article.

ORCID iD Irene Espadas  <https://orcid.org/0000-0001-8602-6532>

References

- 1 Da Costa RC. **Cervical spondylomyelopathy (wobbler syndrome) in dogs.** *Vet Clin North Am Small Anim Pract* 2010; 40: 881–913.
- 2 Johnson P, de Risio L, Sparkes A, et al. **Clinical, morphologic, and morphometric features of cranial thoracic spinal stenosis in large and giant breed dogs.** *Vet Radiol Ultrasound* 2012; 53: 524–534.
- 3 Hecht S, Michaels J, Childers S, et al. **Cranial thoracic stenotic spondylomyelopathy in a young Rottweiler.** *Vet Rec Case Rep* 2017; 5: DOI: 10.1136/vetreccr-2016-000382.

- 4 Miller A and Marchevsky A. **Cranial thoracic vertebral canal stenosis in three juvenile large breed brachycephalic dogs treated by unilateral hemilaminectomy.** *Vet Comp Orthop Traumatol* 2017; 30: 223–229.
- 5 McDonnell J, Knowles KE, deLahunta A, et al. **Thoracolumbar spinal cord compression due to vertebral process degenerative joint disease in a family of Shiloh Shepherd dogs.** *J Vet Intern Med* 2003; 17: 530–537.
- 6 Stalin C, Pratt JN and Smith PM. **Thoracic stenosis causing lateral compression of the spinal cord in two immature Dogues de Bordeaux.** *Comp Orthop Traumatol* 2009; 22: 59–62.
- 7 De Decker S and Volk HA. **Dorsal vertebral column abnormalities in dogs with disseminated idiopathic skeletal hyperostosis (DISH).** *Vet Rec* 2014; 174: 632–638.
- 8 Ortega M, Gonçalves R, Haley A, et al. **Spondylosis deformans and diffuse idiopathic skeletal hyperostosis (dish) resulting in adjacent segment disease.** *Vet Radiol Ultrasound* 2012; 53: 128–134.
- 9 Virk SS, Niedermeier S, Yu E, et al. **Adjacent segment disease.** *Orthopedics* 2014; 37: 547–555.
- 10 Bossens K, Bhatti S, Van Soens I, et al. **Diffuse idiopathic skeletal hyperostosis of the spine in a nine-year-old cat.** *J Small Anim Pract* 2016; 57: 33–35.
- 11 Kranenburg HC, Voorhout G, Grinwis GC, et al. **Diffuse idiopathic skeletal hyperostosis (DISH) and spondylosis deformans in purebred dogs: a retrospective radiographic study.** *Vet J* 2011; 190: 84–90.
- 12 Forterre F, Spreng D, Rytz U, et al. **Thoracolumbar dorsolateral laminectomy with osteotomy of the spinous process in fourteen dogs.** *Vet Surg* 2007; 36: 458–463.
- 13 McKee WA. **Comparison of hemilaminectomy (with concomitant disc fenestration) and dorsal laminectomy for the treatment of thoracolumbar disc protrusion in dogs.** *Vet Rec* 1992; 130: 296–300.
- 14 Di Pierro C, Helm G and Shaffrey C. **Treatment of lumbar spinal stenosis by extensive unilateral decompression and contralateral autologous bone fusion. Operative technique and results.** *J Neurosurg* 1996; 84: 166–173.
- 15 Palmer S, Turner R and Palmer R. **Bilateral decompressive surgery in lumbar spinal stenosis associated with spondylolisthesis: unilateral approach and use of a microscope and tubular retractor system.** *Neurosurg Focus* 2002; 13: E4.
- 16 Muir P, Johnson KA, Manley P, et al. **Comparison of hemilaminectomy and dorsal laminectomy for thoracolumbar intervertebral disc extrusion in dachshunds.** *J Small Anim Pract* 1995; 36: 360–367.