

Direct endoscopic necrosectomy: Pilot study of a new dedicated device



Authors

Dario Ligresti¹, Cecilia Binda^{2,3}, Alessandro Fugazza⁴, Marcello Maida^{5,6}, Mario Traina¹, Andrea Anderloni⁷, Carlo Fabbri⁸, Iliaria Tarantino¹

Institutions

- 1 Digestive Endoscopy Service, Department of Diagnostic and Therapeutic Services, IRCCS - ISMETT, Palermo, Italy
- 2 Unit of Gastroenterology and Digestive Endoscopy, Morgagni-Pierantoni Hospital, Forli, Italy
- 3 Unit of Gastroenterology and Digestive Endoscopy, Maurizio Bufalini Hospital, Cesena, Italy
- 4 Digestive Endoscopy Unit, Division of Gastroenterology, Humanitas Research Hospital, Rozzano, Italy
- 5 Department of Medicine and Surgery, Università degli Studi di Enna 'Kore', Enna, Italy
- 6 Gastroenterology Unit, Umberto I Hospital, Enna, Italy
- 7 Gastroenterology and Digestive Endoscopy Unit, Viale Camillo Golgi, 19, Fondazione I.R.C.C.S. Policlinico San Matteo, Pavia (PV) 27100, Italy
- 8 Digestive Endoscopy and Gastroenterology Unit, Forli-Cesena Hospitals, Azienda Unita Sanitaria Locale della Romagna, Forli-Cesena, Italy

Key words

Endoscopic ultrasonography, Intervention EUS, Pancreas

received 31.1.2024

accepted after revision 15.5.2024

Bibliography

Endosc Int Open 2024; 12: E962–E967

DOI 10.1055/a-2376-1913

ISSN 2364-3722

© 2024. The Author(s).

This is an open access article published by Thieme under the terms of the Creative Commons Attribution-NonDerivative-NonCommercial License, permitting copying and reproduction so long as the original work is given appropriate credit. Contents may not be used for commercial purposes, or adapted, remixed, transformed or built upon. (<https://creativecommons.org/licenses/by-nc-nd/4.0/>)

Georg Thieme Verlag KG, Rüdigerstraße 14,
70469 Stuttgart, Germany

Corresponding author

Dr. Dario Ligresti, IRCCS-ISMETT, Digestive Endoscopy Service, Department of Diagnostic and Therapeutic Services, Via Tricomi, 5, 90100 Palermo, Italy
dligresti@ismett.edu

ABSTRACT

Background and study aims Direct endoscopic necrosectomy (DEN) represents the first-line treatment for walled-off necrosis (WON). However, DEN has a non-negligible rate of overall adverse events (AE) and is time-consuming due to the lack of dedicated devices. This pilot study was designed to evaluate the feasibility and safety of a novel dedicated device for DEN named Necrolit.

Patients and methods In this multicenter retrospective analysis, 16 patients with WON who underwent DEN using Necrolit were compared with a control group treated with non-dedicated devices. Technical success, AEs, clinical success, number of procedures per patient, procedure time, and length of hospital stay were evaluated. Necrolit technical performance indicators were also studied.

Results Technical success was obtained in all patients in both groups. In the Necrolit group, the overall AE rate was 10.1% vs. 15.9% in the control group. Clinical success was 100% in the Necrolit group vs. 81.3% in the control group. Patients treated with Necrolit underwent a slightly lower mean number of procedures (4.1 ± 2.3 vs. 5.1 ± 1.9) with comparable mean procedure time (67.8 ± 39 minutes vs. 70.1 ± 32.6 minutes). Mean duration of hospital stay was 39.4 days (± 30.9) in the Necrolit group vs. 43 days (± 29.4) in the control group. Device-related technical performance was rated positively.

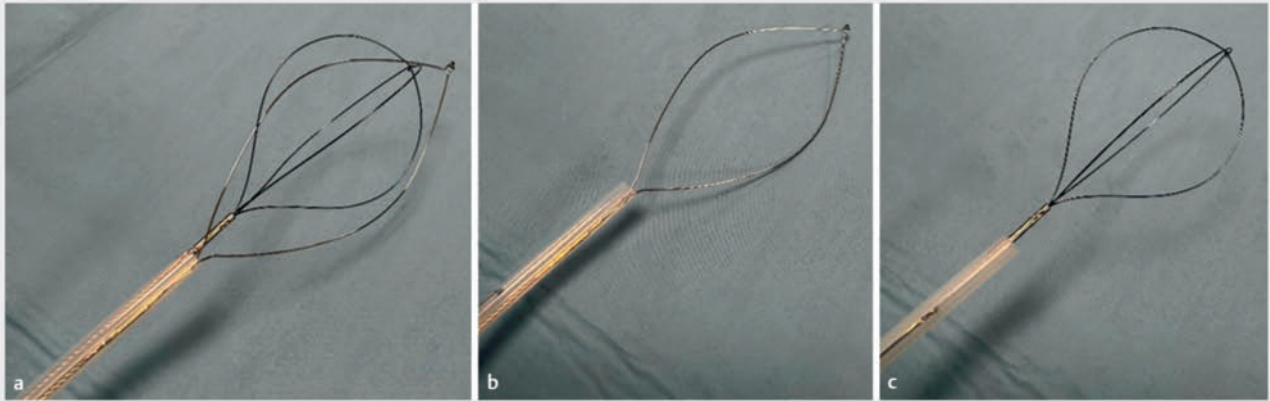
Conclusions DEN with Necrolit appears feasible and safe.

Introduction

Walled-off necrosis (WON) occurs over a period of about 2 to 4 weeks following necrotizing acute pancreatitis and remains

asymptomatic in about 50% of cases. In case of infection, mortality rates range from 20% to 30% (if untreated) [1, 2].

Until 2010, the standard approach to symptomatic or infected WONs was open surgery.



► **Fig. 1** Necrolit dedicated device for endoscopic necrosectomy. **a** Double-channel catheter (3.1 mm in diameter) with both loop and basket open. **b** 25-mm monofilament stainless steel ultra-stiff loop. **c** 25-mm nitinol basket.

Together with technology advancements, endoscopic ultrasound (EUS)-guided drainage and direct endoscopic necrosectomy (DEN) have outpaced surgery or percutaneous drainage and now represent first-line treatment for WON [3, 4].

However, DEN is burdened with an adverse event (AE) rate of 30%, with bleeding as the most severe and sometimes requiring percutaneous embolization or even surgery [5, 6]. Furthermore, it is also time-consuming procedure because of lack of dedicated devices.

In fact, DEN is performed using different tools, such as baskets, snares, nets or forceps not specifically designed for this purpose, except for some initial experience with a dedicated automatic mechanical endoscopic resection system (EndoRotor, Interscope, Inc., Whitinsville, Massachusetts, United States) [7].

In this article, we describe a series of patients who underwent DEN using a novel dedicated device named Necrolit (Meditalia, Palermo, Italy). This pilot study was designed to evaluate the feasibility and safety of Necrolit.

Patients and methods

Study design

A retrospective analysis was undertaken of cases performed in three tertiary Italian hospitals, referral centers for pancreatic diseases and interventional EUS (ISMETT-IRCSS, Palermo; Forlì-Cesena Hospitals; IRCCS Humanitas Research Hospital, Rozzano). The study protocol was reviewed and approved by the Research Ethical Committee from each institution (IRRB 24/21).

Patients

Sixteen patients with WON who underwent EUS-guided drainage and DEN with Necrolit from January 2018 to August 2022 were included and data from them were analyzed (Necrolit group). These patients were compared with a control group of 16 patients who underwent EUS-guided drainage and DEN with standard, non-dedicated devices during the study period. According to international guidelines, WONs were treated in case



► **Fig. 2** Independent handles: Three-ring hub maneuvering the loop and a stick moving handle maneuvering the basket.

of signs of infections or in the case of adjacent organ compression or persistent symptoms [8].


Device

Necrolit, is a new medical device (class II [9], CE mark number 2453) that consists of a double-lumen multiaction catheter specifically intended for use in DEN. This 3.1-mm catheter comprises both a 25-mm nitinol basket container and a 25-mm stainless steel ultra-stiff loop (► **Fig. 1**). These two tools are embedded in an “all-in-one” device and are controlled by a three-ring hub which maneuvers the loop and a stick which moves the handle to maneuver the basket (► **Fig. 2**). Use of a loop or basket can be alternated without the need for device exchange. The basket is used mainly for grasping and removal of muddy necrotic material. The ultra-stiff loop facilitates grasping of the thicker aspect of necrosis, which is ensnared and cut out with the monofilament oval wire (► **Video 1**).

Procedures

All procedures were performed under general anesthesia. A linear echoendoscope (GF-UCT180, Olympus, Tokyo, Japan; EG580UT, Fuji, Tokyo, Japan) was used during the index procedure to gain access to the WON cavity through placement of an electrocautery-enhanced lumen-apposing metal stent (LAMS)

▶ VIDEO



▶ **Video 1** DEN session using Necrolit multiaction catheter and showing how snare and basket are exchanged.

(HOT AXIOS stent, Boston Scientific, Marlborough, Massachusetts, United States). The stent was then dilated up to its maximum diameter using a CRE balloon catheter (Boston Scientific, Marlborough, Massachusetts, United States). DEN with an operative gastroscope (GIF-1TH190, Olympus, Tokyo, Japan; EG-760CT Fujifilm, Tokyo, Japan) was performed following LAMS placement at the index procedure or in subsequent sessions, depending on clinical conditions and per physician preference. Necrolit was used in all DEN sessions. In the control group, extraction nets, baskets, and snares were used per physician preference. In both groups, as much of the visualized necrotic tissue that could be removed was removed and irrigation with 3% hydrogen peroxide diluted at 1:2 was done at each session, followed by irrigation with saline and suction. Subsequent sessions were planned through the stent according to patient clinical conditions and control contrast-enhanced computed tomography (CT) scans were performed until complete the necrosis was completely removed. All procedures were performed using carbon dioxide inflation. Post-procedure antibiotics were given on the base of cultures and clinical conditions. Proton pump inhibitor therapy was discontinued if it had been prescribed. An oral diet was resumed 24 hours after the index procedure or a feeding tube was used for enteral nutrition.

At the end of the last session, the LAMS was removed with a grasping forceps. A control contrast-enhanced CT scan was scheduled 1 month after LAMS removal and outpatient clinical follow-up was planned.

Outcomes and definitions

The primary outcomes were feasibility and safety of using the new device during DEN.

Feasibility was defined as technical success of DEN when cleaning of the necrosis was satisfactory, as confirmed by CT scan, using the Necrolit catheter (or other devices in the control group). Safety was based on AEs including both intraprocedural and delayed AEs occurring within 1 month after WON resolution. AEs were recorded, classified, and graded according to the AGREE classification [10]. We evaluated bleeding, perforation, intraprocedure dislodgement of the stent or other unex-

pected events requiring any additional interventional treatment (endoscopic, radiologic, and surgical). Necrolit technical performance was also studied and measured in terms of pushability, ease of tool exchange, deformability, grasping, and tissue retrieval capacity. To do so, endoscopists experienced in performing DEN (A.A, C.F. and IT) were asked to rate these parameters on a scale from excellent to poor.

“Pushability” was intended as ease of device introduction through the working channel. “Ease of tool exchange” related to the smoothness and absence of friction when switching from basket to loop and vice versa. “Deformability” was defined as loss of shape of the tools due to wires distortion. “Grasping” and “tissue retrieval capacity” were defined as the ability to entrap and hold tissue until it was released from the WON.

Secondary outcomes included clinical success (defined as recovery from sepsis and other WON-related symptoms associated with disappearance of WON without the need for additional percutaneous or surgical intervention), number of procedures per patient, procedure time, and length of hospital stay.

Statistical analysis

Continuous variables were reported as mean \pm standard deviation or as median and interquartile range (IQR), and categorical variables were summarized as frequency and percentage. Comparisons of variables were made by t-test, Chi square test, and Fisher's exact test as appropriate. For all analyses, a $P < 0.05$ was considered statistically significant.

All statistical analyses were performed using SPSS v. 29.0 for Macintosh (SPSS Inc., Chicago, Illinois, United States).

Results

A total of 32 patients with infected or symptomatic WON were included: 16 each in the Necrolit group (12 males, mean age 67.2 ± 13.1) and the control group (11 males, mean age 62.7 ± 13.2). Patients and WON characteristics are summarized in

▶ **Table 1.**

As shown in ▶ **Table 1**, WONs were drained using a single or multiple approach on the basis of collection diameter. A multi-gate approach was used in five patients in the Necrolit group and in three patients in the control group. In the Necrolit group, a through-the-LAMS additional pigtail was placed in five patients and nasocystic drain in one. In the control group, two patients underwent through-the-LAMS double pigtail stent placement.

Technical success was obtained in all patients in both groups. In the first group, Necrolit was used for all procedures without the need for other accessories. The overall AE rate was 10.1% in the Necrolit group and 15.9% in the control group with mild intraprocedure bleeding being the most common (▶ **Table 2**).

Six minor intraprocedure bleedings were reported in the Necrolit group and 12 in the control group. For all of them, there was no drop in hemoglobin levels, modification of procedure course, or further need for surgical/radiologic intervention (grade I sec. AGREE classification). In both groups, one LAMS displacement occurred and was managed intraprocedurally by

► **Table 1** Patient and procedure characteristics.

	Necrolit (N = 16)	Controls (N = 16)	P value
Age, mean ± SD	62.7 ± 13.1	62.7 ± 13.2	0.989
Males, n (%)	12 (75%)	11 (68.8%)	0.694
Etiology of WON, n (%)			
▪ Biliary pancreatitis	6 (37.5%)	11 (68.8%)	0.175
▪ Idiopathic pancreatitis	5 (31.3%)	2 (12.5%)	
▪ Alcoholic pancreatitis	2 (12.5%)	0	
▪ Postoperative fistula	2 (12.5%)	1 (6.3%)	
▪ Hypertriglyceridemia pancreatitis	1 (6.3%)	0	
▪ Pancreas divisum	0	1 (6.3%)	
WON diameter (cm), mean ± SD	11.8 ± 3.1	10.6 ± 3.7	0.302
Multigate drainage, n (%)			
▪ Transgastric + transgastric	5 (31.3%)	3 (18.8%)	0.892
▪ Transgastric + transduodenal	2 (40%)	2 (66.6%)	
▪ Transgastric + transgastric + transgastric	1 (20%)	1 (33.4%)	
▪ Transgastric + percutaneous	1 (20%)	0	
Stent dimension (diameter x length), n (%)			
▪ 10 mm x 10 mm	0	1 (6.3%)	< 0.001
▪ 15 mm x 10 mm	4 (25%)	14 (87.5%)	
▪ 20 mm x 10 mm	12 (75%)	0	
▪ 8 mm x 10 mm	0	1 (6.3%)	
Through-the-LAMS plastic stent, n (%)	6 (37.5%)	2 (12.5%)	0.220
Double pigtail	5 (83.3%)	2 (100%)	0.220
Nasocystic catheter	1 (16.7%)	0	

LAMS, lumen-apposing metal stent; SD, standard deviation; WON, wall-off necrosis.

placement of a new LAMS without any clinical consequence (grade I sec. AGREE classification).

Device-related outcomes were evaluated on a scale of 3 (1-poor, 2-good, 3 excellent) as follows (► **Table 3**): “Pushability” was rated excellent in 13 patients, good in three patients; “ease of tool exchange” was rated excellent in 12 patients, good in four patients; “deformability” was rated excellent in 11 patients, good in 5; “grasping capacity” was rated excellent in 13 patients, good in 3; and “tissue retrieval capacity” was rated excellent in 11 patients, good in 5.

Clinical success was obtained in all patients treated with Necrolit. One patient, diagnosed with an advanced biliary cancer died 3 months later. In the control group, clinical success was achieved in 13 patients (81.3%); three patients died due to WON-related sepsis. One patient was admitted in severe clinical condition following percutaneous drainage at another institution and died of multiorgan failure (MOF) 4 days after the second DEN session. The other two patients were admitted in septic shock from another hospital and died from MOF in inten-

sive care unit during the treatment period. Another patient died during the follow-up period of other causes.

In the Necrolit group, the total number of procedures was 69 with a mean of 4.1 procedures (±2.3) per patient vs. 82 total procedures with a mean of 5.1 procedures (±1.9) per patient in the control group. Seven patients underwent first DEN session at the index procedure in the Necrolit group vs. 13 in the control group. In the Necrolit group, the mean number of DEN sessions per patient was 3.2 (±2.2) vs. 3.9 (±1.9) in the control group. Mean procedure time was 67.8 minutes (±39.8) vs. 70.1 (±32.6). For patients treated with Necrolit, the mean duration of hospital stay was 39.4 days (±30.9) vs. 43 days (±29.4) in the control group. In the Necrolit group, patients were followed-up for a median time of 90 days (IQR 30–300) vs. 75 days (IQR 30–225) in the control group (► **Table 2**).

► **Table 2** Procedure outcomes.

	Necrolit (N = 16)	Controls (N = 16)	P value
Technical success, n (%)	16 (100%)	16 (100%)	–
Adverse events per total procedures, n (%)	7/69 (10.1%)	13/82 (15.9%)	0.303
▪ Minor bleeding	6 (8.7%)	12 (14.6%)	0.319
▪ LAMS displacement	1 (1.4%)	1 (1.2%)	1.000
Clinical success, n (%)	16 (100%)	13 (81.3%)	0.069
Overall procedures per patient, mean ± SD	4.1 ± 2.3	5.1 ± 1.9	0.190
DEN sessions per patient, mean ± SD	3.2 ± 2.2	3.9 ± 1.9	0.308
DEN at index procedure, n (%)	7 (43.8%)	13 (81.3%)	0.066
Single procedure duration, min, mean ± SD	67.8 ± 39.8	70.1 ± 32.6	0.694
Duration of hospital stay, days, mean ± SD	39.4 ± 30.9	43.0 ± 29.4	0.741
Follow-up, days, median (IQR)	90 (30–300)	75 (30–225)	0.674
Deaths, n (%)	1 (6.3%)	4 (25%)	0.333

DEN, direct endoscopic necrosectomy; IQR, interquartile range; LAMS, lumen-apposing metal stent; SD, standard deviation.

► **Table 3** Device-related outcomes.

	Excellent	Good	Poor
Pushability	13	3	0
Ease of tool exchange	12	4	0
Deformability	11	5	0
Grasping capacity	13	3	0
Tissue retrieval capacity	11	5	0

Discussion

Even if safe and effective, DEN is a time-consuming technique that requires multiple sessions with subsequent prolonged hospital stays and increased costs. In actuality, the effectiveness of DEN currently is limited by the lack of dedicated tools. Endorotor, a dedicated system, recently has been described, with promising results but elevated costs [10].

In our series, we found that DEN with Necrolit was easy and technically successful for all patients.

The overall AE rate during DEN has been reported to be around 30% [8], with major bleeding representing the main concern.

In our series, we reported six minor bleeds across 69 DEN procedures (8.7%), slightly less than in the control group (12 over 82 procedures, 14.6%). Hence, we believe that the event “bleeding” could be overestimated in our study and generally in all papers where it is intended as an intraprocedure event that has been controlled with standard endoscopic technique without modifying the procedure course.

Patients treated with Necrolit underwent fewer procedures overall with a comparable number of DEN sessions in the control group.

As regards Necrolit technical characteristics, they were rated positively.

In particular, the design of the Necrolit monofilament loop, together with its ultra-stiffness, seems to overcome “slippage” that is often experienced with standard non-dedicated snares and limits the effectiveness of the procedure in terms of amount of necrosis removed. The device was perceived as having satisfactory grasping and retrieval capacity, allowing removal of even firmly adherent necrosis. Therefore, the possibility of rotating the loop via the maneuvering handle seems to be advantageous in terms of achieving ideal positioning. Furthermore the “round-shaped” tip of the snare was believed to favor an a-traumatic approach to the necrotic tissue and intended to improve grip and avoid bleeding, which may occur with a sharpened tip. Also, the 25-mm nitinol basket seemed to be satisfactory in terms of tissue retrieval capability. Neither the loop nor the snare showed any significant loss of shape that limited the procedure, resulting in a good shape memory. No significant friction or resistance were reported when switching from loop to basket (or vice versa) and “pushability” through the operative channel was rated excellent in the majority of cases.

The main limitations of this study are the small sample size, cohort heterogeneity, and subjective evaluation scale of Necrolit performance. However, use of the same device (Necrolit) in all patients in one cohort and comparison with a control group represent a strength of this article.

Conclusions

Although there were a limited number of patients in this pilot study, we conclude that DEN with Necrolit is feasible and safe. Prospective comparative studies are needed to better assess clinical outcomes.

Acknowledgement

This study was funded by the Italian Health Ministry, ricerca corrente 2024.

Conflict of Interest

The authors declare that they have no conflict of interest.

Funding Information

Italian Health Ministry ricerca corrente 2024

References

- [1] Working Group IAP/APA Acute Pancreatitis Guidelines. IAP/APA evidence-based guidelines for the management of acute pancreatitis. *Pancreatology* 2013; 13: e1–15
- [2] Yadav D, Lowenfels AB. The epidemiology of pancreatitis and pancreatic cancer. *Gastroenterology* 2013; 144: 1252–1261 doi:10.1053/j.gastro.2013.01.068
- [3] Mohamadnejad M, Anushiravani A, Kasaeian A et al. Endoscopic or surgical treatment for necrotizing pancreatitis: comprehensive systematic review and meta-analysis. *Endosc Int Open* 2022; 10: E420–E428 doi:10.1055/a-1783-9229
- [4] van Brunshot S, van Grinsven J, van Santvoort HC et al. Endoscopic or surgical step-up approach for infected necrotising pancreatitis: A multicentre randomised trial. *Lancet* 2018; 391: 51–58 doi:10.1016/S0140-6736(17)32404-2
- [5] Pinto S, Bellizzi S, Badas R et al. Direct endoscopic necrosectomy: Timing and technique. *Medicina* 2021; 57: 1305 doi:10.3390/medicina57121305
- [6] Fugazza A, Sethi A, Trindade AJ et al. International multicenter comprehensive analysis of adverse events associated with lumen-apposing metal stent placement for pancreatic fluid collection drainage. *Gastrointest. Endosc* 2020; 91: 574–583
- [7] van der Wiel SE, Poley JW, Grubben M et al. The EndoRotor, a novel tool for the endoscopic management of pancreatic necrosis. *Endoscopy* 2018; 50: E240–E241 doi:10.1055/a-0628-6136
- [8] Baron TH, Dimaio CJ, Wang AY et al. American Gastroenterological Association Clinical Practice Update: Management of Pancreatic Necrosis. *Gastroenterology* 2020; 158: 67–75 doi:10.1053/j.gastro.2019.07.064
- [9] European Commission. MEDDEV 2.7/1 revision 4. Clinical evaluation: a guide for manufacturers and notified bodies under directives 93/42/EEC and 90/385/EEC. <http://ec.europa.eu/Docs Room/documents/17522/attachments/1/translations/>
- [10] Nass KJ, Zwager LW, van der Vlugt M et al. Novel classification for adverse events in GI endoscopy: the AGREE classification. *Gastrointest Endosc* 2022; 95: 1078–1085 doi:10.1016/j.gie.2021.11.038