

Received: 2010.04.30
Accepted: 2010.09.16
Published: 2011.02.01

Authors' Contribution:

- A** Study Design
- B** Data Collection
- C** Statistical Analysis
- D** Data Interpretation
- E** Manuscript Preparation
- F** Literature Search
- G** Funds Collection

The minimally-invasive thyroidectomy incision: A histological analysis

Waleed H. Ezzat^{1ABCDE}, Brian J. O'Hara^{2ABCD}, Kyle J. Fisher^{1BEF}, David Rosen^{1BEF}, Edmund A. Pribitkin^{1ABCDE}

¹ Thomas Jefferson University, Department of Otolaryngology – Head and Neck Surgery, Philadelphia, PA, U.S.A.

² Thomas Jefferson University, Department of Pathology, Anatomy and Cell Biology, Philadelphia, PA, U.S.A.

Presented at The World Congress on Thyroid Cancer, Toronto, ON, CA, August 8, 2009

Source of support: Self financing

Summary

Background:

Minimally invasive thyroidectomy (MIT) has gained popularity in the surgical management of benign and malignant pathology of the thyroid. One of the main benefits of utilizing this technique is the use of smaller incisions resulting in increased cosmetic satisfaction. Unfortunately, the retraction required for adequate exposure during MIT may lead to skin damage, impaired wound healing and poor cosmetic outcomes. Some have proposed that excising incision edges prior to closure may improve cosmesis. A review of the literature does not reveal any histologic evidence to support this technique.

Material/Methods:

In this prospective observational study, nine subjects undergoing MIT were identified. Both the superior and inferior skin edges were excised and labeled for orientation. Specimens were sent for hematoxylin and eosin staining and histologic analysis by a staff pathologist.

Results:

All specimens showed no significant findings such as damage to the architecture of the dermis, acute inflammation, edema or evidence of hemorrhage. Focal blood vessel ectasia within the dermis was identified in three of nine subjects.

Conclusions:

Our findings do not yield a histological basis supporting the routine trimming of incisions during MIT. Although no significant findings were noted histologically, further studies are warranted to investigate the long-term cosmetic outcome of MIT incisions.

Key words:

minimally-invasive • thyroidectomy • cosmesis • incisions

Full-text PDF:

<http://www.medscimonit.com/fulltxt.php?ICID=881377>

Word count:

1125

Tables:

2

Figures:

2

References:

11

Author's address:

Edmund A. Pribitkin, Thomas Jefferson University, Department of Otolaryngology Head and Neck Surgery, 925 Chestnut St., 6th Floor, Philadelphia, PA 19107, U.S.A, e-mail: edmund.pribitkin@jefferson.edu

BACKGROUND

The minimally-invasive thyroidectomy (MIT) breaks from the traditional Kocher incision of 8 to 10 cm in length to an incision of less than 4 cm [1]. The utilization of smaller incisions during MIT often requires excessive retraction to gain adequate exposure to the thyroid. This often results in damage to the skin edges and the risk of hypertrophic scarring.

Hypertrophic scarring results from alterations in the normal process of healing [2]. With excessive retraction, damaged edges of incisions result in an increased inflammatory state which inhibits the normal process of healing [3]. A commonly described technique to avoid the risk of hypertrophic scarring after MIT is the routine trimming of the incision edges prior to skin closure [4]. Despite the wide acceptance of this technique, there are no studies in the literature that address its validity. The goal of this study was to investigate any alterations in the histological architecture of incisions after the MIT procedure.

MATERIAL AND METHODS

Subjects

This study was approved for investigation by the institutional review board (IRB) at our institution. Patients undergoing the MIT procedure between May, 2008 and October, 2008 were asked to participate in the study. Ten subjects gave consent to participate. A database was constructed listing information for each subject, including incision length, operative findings, pathology and post-operative course.

MIT procedure

The patient is marked in the pre-operative area in an upright position. A midline incision measuring less than 4 cm was drawn 2 cm above the clavicles in a naturally existing skin crease. The patient was intubated with a NIM-Response nerve integrity monitoring system tube (Medtronic USA, Inc., Jacksonville, FL, USA) and verified in position with direct laryngoscopy. Nerve monitoring was employed in all procedures.

An incision was made and carried below the platysma muscle. Dissection proceeded to the thyroid isthmus which was subsequently divided. The thyroid lobe was then mobilized from the underlying strap muscles. The superior pole was dissected and freed from the superior vessels. The recurrent laryngeal nerve (RLN) was visualized superiorly and traced along its course below the thyroid lobe. Once the thyroid lobe was separated from the RLN, Barry's ligament was divided and the lobe was removed.

The hemostasis was assured and, if no excessive bleeding was encountered during the procedure, the incision was closed through the platysma layer without a drain. Prior to closing the skin, 2mm of the incision edge was trimmed and sent off for examination. The freshened skin edges were closed with interrupted 6-0 nylon sutures.

Histological analysis

The incision specimens were fixed in a 10% formalin solution and underwent hematoxylin and eosin (H+E) staining.

Table 1. Breakdown of thyroid pathology.

Pathology	No. subjects
Follicular Adenoma	2
Multinodular Goiter	3
Chronic Lymphocytic Thyroiditis	1
Graves Disease	1
Papillary Carcinoma	2

The specimens were then evaluated by a pathologist (BJO), blinded to the procedure or intra-operative findings. Any instances of architecture disruption, evidence of ischemia, crush artifact, or other pertinent findings were recorded.

RESULTS

Subjects

A total of ten subjects were enrolled in this study. One subject was excluded from the study as records were not available for follow-up, leaving a total of nine subjects for analysis. All subjects were female with an average age of 43 years (range 20–66 years). None had prior surgery to the cervical area. The distribution of pathology is shown in Table 1.

MIT procedure

Six subjects underwent total thyroidectomy and three had a lobectomy performed. The average incision length was 3.5 cm (range 2.75–4 cm). The average diameter of the largest nodule of the specimen removed was 1.08 cm (range 0.4–2.0 cm). The average volume of the each lobe was 32.96 mL (range 5.4–120 mL). There were no intra-operative complications. Prior to the excision, the incision edges were noted to show gross signs of minor retraction damage. These were excised and sent for histologic analysis. Postoperatively, all incisions healed well with the exception of one subject who had mild hypertrophic scarring that was treated conservatively (Figure 1).

Thyroid incisions

Of the nine incision trimmings evaluated by H+E staining, none exhibited signs of architecture disruption, mechanical damage or histological evidence of ischemia (Figure 2). There was an incidental finding of solar elastosis in two specimens (Table 2).

DISCUSSION

Minimally-invasive techniques have been described for the treatment of thyroid and parathyroid diseases [3]. These include the use of the open minimally-invasive (MIT) thyroidectomy, the minimally-invasive video-assisted thyroidectomy (MIVAT), and the extra-cervical approaches (mammary, anterior chest, and axillary) [4–6]. Wilhelm and Metzger have recently reported their first experience with transoral, endoscopic thyroidectomy [7]. While their initial report is hopeful, this technique is not widely practiced and limited by the resources necessary to undertake this approach

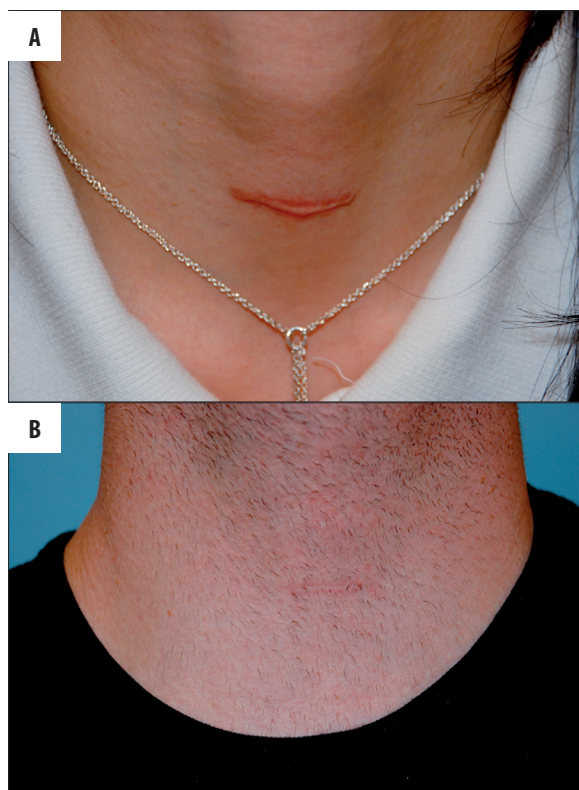

Figure 1. Postoperative photos of two MIT incisions which suffered mild hypertrophic scarring (A) and one that healed without incident (B).

Table 2. Histological findings of incision edges.

Subject	Findings
1	None
2	None
3	None
4	Solar elastosis
5	None
6	None
7	Solar elastosis
8	None
9	None
10	None

which are currently only found in academic centers. More cases need to be reported before this technique becomes commonplace. Furthermore, both the extra-cervical and transoral approaches paradoxically involve more dissection than one might think of when labeling an approach as minimally-invasive. While the traditional Kocher incision provides excellent exposure, smaller incisions have led to decreased post-operative pain and better cosmetic outcomes without an increase in complications [8,9]. Conversely, O’Connell, et al., reported no difference in subjective or

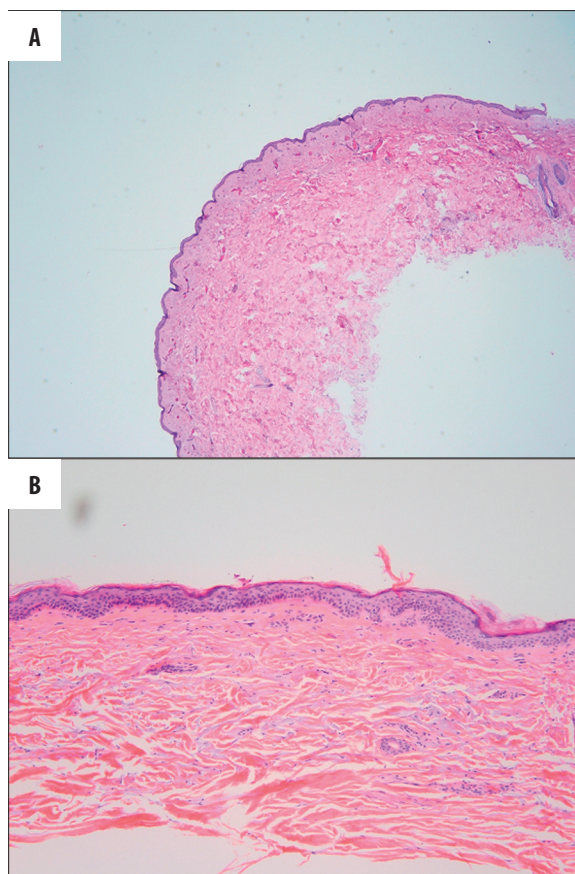


Figure 2. High and low powered views of thyroid incisions on H+E staining. There was no evidence of architectural damage or ischemia.

objective cosmetic outcomes when comparing conventional and minimally-invasive incisions [10]. However, there was a statistically significant improvement in overall patient satisfaction for those receiving smaller incisions.

Hypertrophic scarring results from alterations in the normal process of healing. Persistent inflammation and excessive deposition of fibroblast-derived extracellular matrix proteins occurs. The wound fails to undergo remodeling resulting in a raised, red and rigid scar [2]. Due to the limited access afforded by the MIT procedure, significant retraction is required to dissect the most superior and inferior extent of the thyroid gland. Increased trauma leads to increased postoperative inflammation, both of which can lead to disruptions in wound healing [2]. The current practice of trimming damaged incision edges is aimed to approximate fresh wound edges, reducing the risk of hypertrophic scarring.

In our study, we were unable to find any histological changes in incision edges. However, our results do not disprove the selective use of incision trimming during MIT. Evidence of inflammation does not become apparent until approximately 24–48 hours after trauma [11]. One would expect an increased infiltration of inflammatory cells within the wound to suggest increased inflammation. Due to the immediate fixation of our specimens these findings could not have been noted.

CONCLUSIONS

Despite this limitation, our preliminary study does show that physical damage to the incision edges does not occur during MIT. It is possible that that subsequent inflammation resulting from excessive retraction, and not physical trauma, could be the main factor in the risk of hypertrophic scarring. Nevertheless, trimming incision edges does not confer any increased morbidity to the procedure and does provide the approximation of fresh tissue edges for optimal cosmetic outcome. Further long-term, comparison studies are warranted, however, to further investigate the necessity of this procedure during MIT.

REFERENCES:

1. Henry JF: Minimally invasive thyroid and parathyroid surgery is not a question of length of the incision. *Langenbecks Arch Surg*, 2008; 393: 621–26
2. Atiyeh BS: Nonsurgical management of hypertrophic scars: Evidence-based therapies, standard practices, and emerging methods. *Aesth Plast Surg*, 2007; 31: 468–92
3. Kitagawa W, Shimizu K, Akasu H: Radioguided parathyroidectomy for primary hyperparathyroidism using the solid-state, multi-crystal gamma camera. *Med Sci Monit*, 2003; 9(6): CS53–56
4. Yeung GH: Endoscopic surgery of the neck: a new frontier. *Surg Laparosc Endosc*, 1998; 8(3): 227–32
5. Ikeda Y, Takami H, Sasaki Y et al: Endoscopic neck surgery by axillary approach. *J Am Coll Surg*, 2000; 191: 336–40
6. Ohgami M, Ishii S, Arisawa Y: Scarless endoscopic thyroidectomy: Breast approach for better cosmesis. *Surg Laparosc Endosc Percutan Tech*, 2000; 10: 1–4
7. Wilhelm T, Metzger A: Endoscopic minimally invasive thyroidectomy: first clinical experience. *Surg Endosc*, 2010; 24(7): 1757–58
8. Terris DJ, Seybt MW, Elchoufi M, Chin E: Cosmetic thyroid surgery: Defining the essential principles. *Laryngoscope*, 2007; 117: 1168–72
9. Sgourakis G, Sotiropoulos GC, Neuhauser M et al: Comparison between minimally invasive video-assisted thyroidectomy and conventional thyroidectomy: Is there any evidence-based information? *Thyroid*, 2008; 18(7): 721–27
10. O'Connell DA, Diamond C, Seikaly H, Harris JR: Objective and subjective scar aesthetics in minimal access vs conventional access parathyroidectomy and thyroidectomy surgical procedures. *Arch Otolaryngol Head Neck Surg*, 2008; 134(1): 85–93
11. Teller P, White TK: The physiology of wound healing: Injury through maturation. *Surg Clin N Am*, 2009; 89: 599–610