

CASE REPORT

Missed opportunity of deworming a Maasai boy from nomadic family leading to life threatening intestinal obstruction

Jeremia J. Pyuza^{1,*}, Alice A. Andongolile², Christain E. Issangya³, David Msuya³, James J. Yahaya⁴, Elichilia R. Shao⁵, and Alex R. Mremi¹

¹Department of pathology, Kilimanjaro Christian Medical Centre, Moshi, Tanzania, ²Kilimanjaro Clinical research Institute, Kilimanjaro Christian Medical Centre, Moshi, Tanzania, ³Department of General Surgery, Kilimanjaro Christian Medical Centre, Moshi, Tanzania, ⁴Department of Biomedical Sciences, College of Health Sciences, The University of Dodoma, Dodoma, Tanzania, and ⁵Department of Internal Medicine, Kilimanjaro Christian Medical Centre, Moshi, Tanzania

*Correspondence address. Department of pathology, Kilimanjaro Christian Medical Centre, PO Box 3010, Moshi, Tanzania.

Tel: +255-78-315-2962; E-mail: giisiraymond@gmail.com

Abstract

Mass deworming against soil-transmitted helminthiasis, including *Ascaris lumbricoides* (AL), is one of the largest public health interventions in low- and middle-income countries. The prevalence of *A. lumbricoides* in Tanzania is 6.8%. We present a 3-year-old male of a known Tanzanian nomadic tribe (Masaai tribe) with history of missed deworming, who was brought to the emergency department with a 3-day history of constipation, nonprojectile, bilious vomiting, generalized abdominal distension and pain.

He was diagnosed with intestinal obstruction by the use of a plain abdominal X-ray, which revealed marked gaseous distension of the stomach and bowels without significant air-fluid levels. He was initially treated with intravenous ceftriaxone 50 mg/kg, metronidazole 15 mg/kg and acetaminophen 15 mg/kg. An explorative laparotomy was then performed. Intraoperative findings demonstrated a dense collection of *A. lumbricoides* worms in the gangrenous proximal jejunum and duodenum. Thorough abdominal lavage was carried out and abdomen was closed.

INTRODUCTION

Mass deworming against soil-transmitted helminthiasis, including *Ascaris lumbricoides*, is one of the largest public health interventions in low- and middle-income countries (LMIC) [1]. Infection of the intestinal nematode, *A. lumbricoides* is one of the most common human helminth infections [2]. *Ascaris lumbricoides* infects 0.8–1.2 billion people worldwide, with a

high prevalence in tropical and subtropical areas [3]. It is estimated that 73% of infected individuals are found in LMIC [4]. The overall incidence of *A. lumbricoides* infestation in sub-Saharan Africa is 16% [9]. Schule *et al.* report the prevalence of *A. lumbricoides* infestation in Tanzania to be 6.8% and attributes the warmth and wet climate that favors year-round transmission [10].

Received: March 11, 2020. Accepted: March 30, 2020

Published by Oxford University Press and JSCR Publishing Ltd. All rights reserved. © The Author(s) 2020.

This is an Open Access article distributed under the terms of the Creative Commons Attribution Non-Commercial License (<http://creativecommons.org/licenses/by-nc/4.0/>), which permits non-commercial re-use, distribution, and reproduction in any medium, provided the original work is properly cited. For commercial re-use, please contact journals.permissions@oup.com

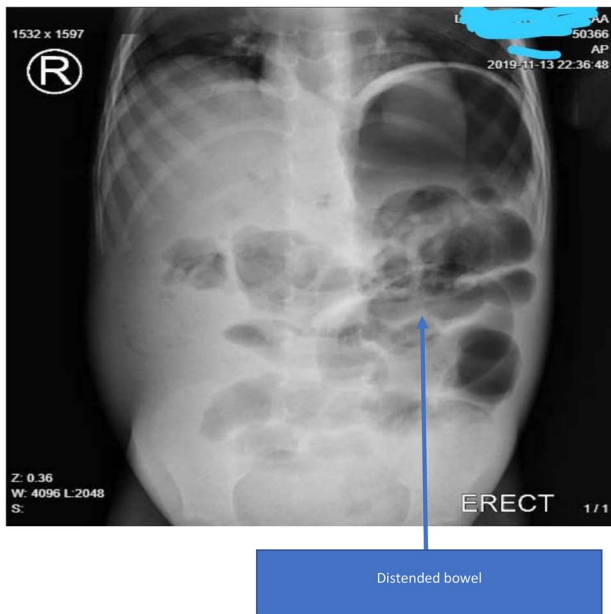


Figure 1: Plain X-ray of the patient showing gastrointestinal distention without air-fluid levels or 'railway tracks'.

The primary modes of *A. lumbricoides* transmission occur via ingestion of *A. lumbricoides* eggs secreted in human feces, which subsequently embryonate in the soil and contaminate food/water sources, or by consuming the raw meat of an infected pig or chicken [5]. Symptomatic cases typically occur in those with high worm burden and manifest with abdominal discomfort, pneumonitis and anorexia [4]. Left untreated, ascariasis may result in lethal complications such as intestinal obstruction, pancreatic damage, malnutrition, growth retardation and peritonitis [6]. Overall mortality caused by *A. lumbricoides* is reported to be very low. However, ascariasis has enormous health and social implications for school aged children, especially in LMIC, such as a decrease in school performance and permanent disability.

AL complications are preventable through well-organized deworming programs in areas of high infection prevalence. In 2017, the World Health Organization (WHO) produced recommendations for prevention of soil-transmitted infections including improvement in sanitation, health and hygiene behaviors like hand washing, footwear and use of toilets. For preschool and primary school children, the WHO recommends one- or two deworming treatments depending to the prevalence of disease. These interventions remain to be a major challenge especially in nomadic populations [7–8]. Worldwide, the prevalence of deworming among preprimary school children in endemic areas is low [1]. As a result, patients in LMIC may present with later sequelae of *A. lumbricoides* infections.

CASE PRESENTATION

A 3-year-old male of a known Tanzanian nomadic Masai tribe was brought to the emergency department with a 3-day history of constipation, nonprojectile, bilious vomiting, generalized abdominal distension and pain. His mother denied any history of deworming. His past medical and family history was unremarkable. On physical examination, the child was pale, weak with an altered level of consciousness, Glasgow Coma Score of




Figure 2: Marked ischemic changes of the small bowel with adult *A. lumbricoides* worms protruding from the bowel.

12/15 and febrile with a body temperature of 37.9°C. His blood pressure was 112/70 mm Hg with a pulse rate of 90 beats/min. The patient's abdomen was distended and tender with guarding and dullness to percussion. Laboratory investigations revealed hemoglobin of 9.2 g/dl (12.0–16.0) with normal white blood cells. A plain abdominal X-ray revealed marked gaseous distension of the stomach and bowels without air-fluid levels (Fig. 1). Similar findings were observed in the abdominal ultrasound scan.

Based on the clinical and physical examination findings, a working diagnosis of intestinal obstruction with peritonitis was made. Further investigations such as a computed tomography scan were not possible due to financial constraints. The patient was admitted and rehydrated with 2.0 L of ringer lactate (RL) alternated with dextrose normal saline. He was treated with intravenous ceftriaxone 50 mg/kg, metronidazole 15 mg/kg and acetaminophen 15 mg/kg. An explorative laparotomy was performed. Intraoperative findings demonstrated volvulus of the terminal ileum with gangrenous changes of the small intestine ~48 cm from the ileocecal junction. A dense collection of *A. lumbricoides* worms in the gangrenous proximal jejunum and duodenum (Fig. 2) accompanied by 1500 ml of foul-smelling peritoneal fluid was found.

Resection of the gangrenous portions of the bowel was performed with extraction of the *A. lumbricoides* worm collection (Fig. 3). An ileotransverse end-to-side anastomosis was then carried out. On microscopic examination slide showed *A. lumbricoides* on the sampled small bowel segment stained with hematoxylin and eosin (H&E) (Fig. 4). There was also an aggregation of lymphocytes forming granulomatous lesions with central necrosis (Fig. 5).

Postoperative management involved intravenous fluid 1.5 L of RL alternated with dextrose lactate solution. Intravenous ceftriaxone 50 mg/kg once a day, metronidazole 15 mg/kg every 8 h for 5 days, intramuscular pethidine 25 mg every 8 h for 1 day and a single dose of orally albendazole 400 mg. Postoperative period was uneventful and he was discharged 6 days following operation. We followed up the child for 4 months postdischarge and his condition remained stable with resumption of normal bowel function.

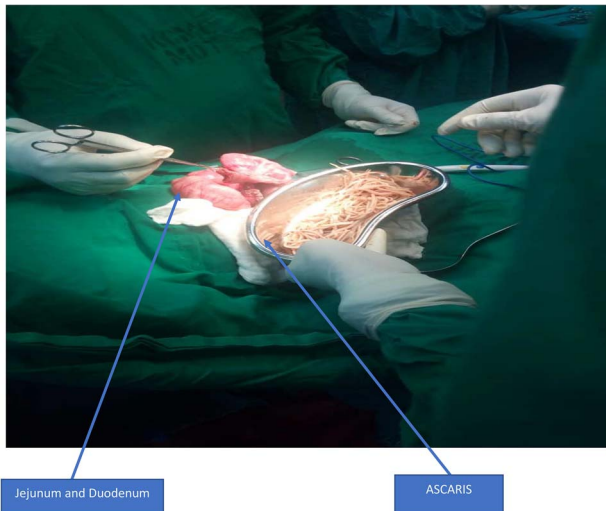


Figure 3: Extraction of *A. lumbricoides* from jejunum and duodenum by enterotomy.

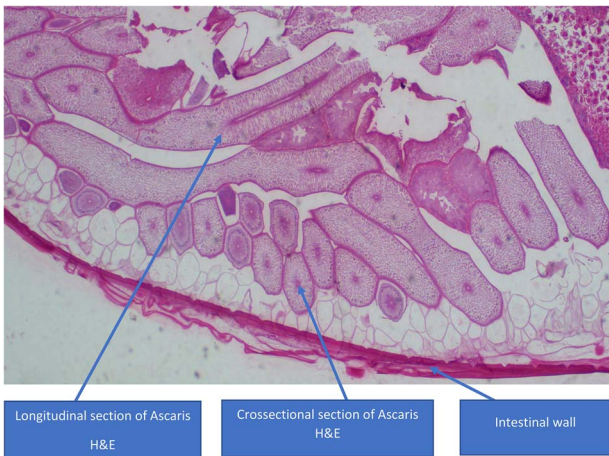


Figure 4: Showing *A. lumbricoides* on the sampled small bowel segment stained with H&E.

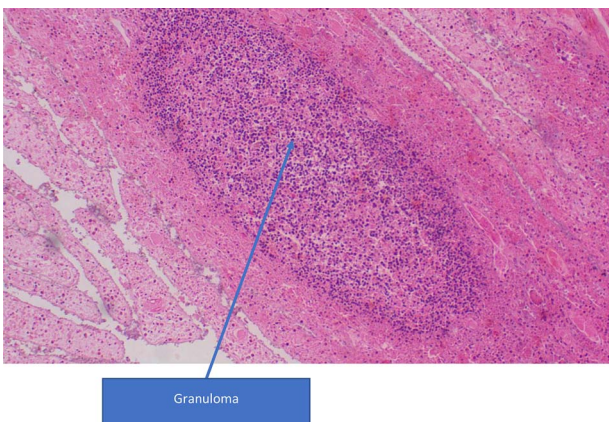


Figure 5: Infiltration of lymphocytic inflammatory cells with aggregation to form a granuloma in a necrotic tissue (H&E stains, $\times 100$).

DISCUSSION

Prevention and treatment of *A. lumbricoides* infections in rural and remote populations including the Tanzanian Maasai tribe continue to pose a challenge for healthcare providers. Although the Tanzania policy for once yearly deworming program for primary school and preprimary school children continues to be enacted, this does not necessarily reach all infected population. Rural and remote populations continue to experience barriers to routine and preventative care such as lack of reliable transportation, awareness of medical treatment and presentation and infrequent communication with medical care providers.

In this case, the child had several known risk factors for worm infestation, yet he was never taken to a clinic for deworming. It is important to consider distance to the nearest treatment facility, which was ~ 200 km. The relative lack of resources in this patient's case likely contributed to failed adherence to antenatally early deworming program and lack of timely diagnosis leading to detrimental complications of intestinal obstruction and severe anemia.

In Tanzania, children are entitled to receive necessary supplements and other interventions such as routine vaccines. Due to factors like remote populations, lack of community awareness and constant movements of family in search for animal pastures, certain children miss the opportunity to utilize their basic right of health care. The government of Tanzania attempts to address these barriers by offering mass treatment via mobile treatment camps; however, this temporary measure does not necessarily reach all infected population. Knowing how remote populations and special groups of people can most effectively be treated with deworming therapy is an important strategy to prevent occurrences of severe *A. lumbricoides* sequelae in Tanzania.

REFERENCES

- Nathan CL, Neal SH, Coulibaly JT, Leonard L, Bendavid E, Addiss DG. State of deworming coverage and equity in low-income and middle-income countries using household health surveys: a spatiotemporal cross-sectional study. *Lancet Global Health* 2019;7:e1511–20. doi: [10.1016/S2214-109X\(19\)30413-9](https://doi.org/10.1016/S2214-109X(19)30413-9).
- Wali K, Imran, Abdul W. Intestinal obstruction by *Ascaris lumbricoides* in a 12-year-old boy: a case report in Pakistan. *J Bacteriol Parasitol* 2016;7:262. doi: [10.4172/2155-9597.1000262](https://doi.org/10.4172/2155-9597.1000262).
- Wardell R, Clements AC, Lal A, Summers D, Llewellyn S, Campbell SJ, et al. An environmental assessment and risk map of *Ascaris lumbricoides* and *Necator americanus* distributions in Manufahi district, Timor-Leste. *PLoS Negl Trop Dis* 2017;11: e0005565. doi: [10.1371/journal.pntd.0005565](https://doi.org/10.1371/journal.pntd.0005565)
- Pullan RL, Smith JL, Jasrasaria R, Brooker SJ. Global numbers of infection and disease burden of soil transmitted helminth infections in 2010. *Parasites Vectors* 2014;7:37. doi: [10.1186/1756-3305-7-37](https://doi.org/10.1186/1756-3305-7-37).
- Abdellatif M, Belal U, Abdel-Hafeez E, Atiya A, Norose K. *Ascaris lumbricoides* causing acute abdomen: a case report. *East Mediterr Health J* 2013;19:1035–7. doi: [10.26719/2013.19.12.1035](https://doi.org/10.26719/2013.19.12.1035).
- Mbanga CM, Ombaku KS, Fai KN, Agbor VN. Small bowel obstruction complicating an *Ascaris lumbricoides* infestation

- in a 4-year-old male: a case report. *J Med Case Reports* 2019;13:155. doi: [10.1186/s13256-019-2103-y](https://doi.org/10.1186/s13256-019-2103-y).
7. WHO, *Guideline: Preventive Chemotherapy to Control Soil-Transmitted Helminth Infections in at-Risk Population Groups*. WHO Library Cataloguing-in-Publication Data. 2017; 7 978-92-4-155011-6. <https://apps.who.int/iris/handle/10665/258983> (20 February 2020, date last accessed).
 8. Savioli L, Albonico M, Daumerie D, Lo NC, Stothard JR, Asaolu S, et al. Review of the 2017 WHO guideline: preventive chemotherapy to control soil-transmitted helminth infections in at risk population groups. An opportunity lost in translation. *PLoS Negl Trop Dis* 2018;12:e0006296. doi: [10.1371/journal.pntd.0006296](https://doi.org/10.1371/journal.pntd.0006296).
 9. Yetim I, Ozkan OV, Semerci E, Abanoz R. Rare cause of intestinal obstruction, *Ascaris lumbricoides* infestation: two case reports. *Cases J* 2009;2:7970. doi: [10.4076/1757-1626-2-7970](https://doi.org/10.4076/1757-1626-2-7970).
 10. Schüle SA, Clowes P, Kroidl I, Kowuor DO, Nsojo A, Mangu C, et al. *Ascaris lumbricoides* infection and its relation to environmental factors in the Mbeya region of Tanzania, a cross-sectional, population-based study. *PLoS One* 2014;9:e92032. doi: [10.1371/journal.pone.0092032](https://doi.org/10.1371/journal.pone.0092032).