

# Prosthetic Treatment Possibilities for Extended Partially Edentulous and Completely Edentulous Patients, Depending on the Clinico-Morphological Characteristics of the Oral Mucosal Substrate

MONICA MIHAELA CRĂIȚOIU<sup>1</sup>, C. MĂRGĂRITESCU<sup>2</sup>,  
MONICA SCRIECIU<sup>1</sup>, ROXANA PASCU<sup>1</sup>,  
ALMA FLORESCU<sup>1</sup>, VERONICA MERCUȚ<sup>1</sup>

<sup>1</sup>University of Medicine and Pharmacy of Craiova, Romania, Department of Prosthetic Dentistry

<sup>2</sup>University of Medicine and Pharmacy of Craiova, Romania, Department of Pathology

**ABSTRACT:** The number of partially and completely edentulous patients requiring removable prosthetic treatment has increased constantly and denture wearers often have an associated oral status pathology. The purpose of this article is to present removable prosthetic treatment options that we chose for the extended partially edentulous and completely edentulous patients who required prosthetic rehabilitation treatment. We conducted this study on 52 extended partially edentulous and completely edentulous patients. We recorded in the examination chart the characteristics of the mucosal membrane covering the denture supporting structure and the peripheral structures and we performed a statistical analysis using Microsoft Excel. The prosthetic treatment phases were individualized according to morphological characteristics of the oral mucosal substrate.

**KEYWORDS:** edentulous patients, prosthetic treatment, oral mucosal substrate

## Introduction

Edentation represents the absence from the dental arch of 1 to 16 dentoperiodontal units. Rehabilitation of stomatognathic system's functions affected by edentation is obtained through various prosthetic restorations. The purpose of a removable prosthetic restoration, in addition to restoring the functions affected by the installation of the partially extended or completely edentulous condition, is to obtain a relationship as less harmful as possible with the oral mucosa, a structure which is in direct contact with the denture and which has a variable macroscopic and microscopic morphology from one area to another and from one patient to another [1].

The foundation for maxillary dentures is made up of bone of the residual ridge and hard palate and for mandibular dentures consists only of the bone of the residual ridge. The bone structure is covered by the mucous membrane, which serves as a cushion between the denture base and the supporting bone [2]. The transition to the partially or to the completely edentulous state is accompanied

by bone resorption and by changes in mucosal membrane.

The number of partially and completely edentulous patients requiring removable prosthetic treatment has increased constantly and denture wearers often have an associated oral status pathology in terms of mucosal membrane's appearance, of saliva quantity and quality and of microbial flora [3]. Also, there are structural changes that interest the thickness of the epithelium and of the stratum corneum and the degree of keratinization [4].

Quality and individual characteristics of the mucosal layer should be evaluated at the stage of clinical intraoral examination, an important cause of removable denture therapy failure being an insufficient and superficial clinical examination [5]. Successful treatment of partially and completely edentulous patients depends on thorough knowledge of the anatomy of the denture supporting and peripheral structures [6]. The incisive papilla, palatal rugae and median raphe - mucosal structures located on the hard palate - play an important role for the removable prosthetic treatment.

One important element in establishing a correct relationship between the denture base and the mucosal substrate is the impression

making, which is a phase of the prosthetic treatment. The preliminary impression solves support and removable denture stability issues only in exceptional circumstances [7]. Considering the individual and area morphological characteristics, these problems can only be solved in the final impression phase. There are a lot of final impression techniques described by literature, a lot of impression materials are available and we have to choose the final impression technique after a competent and thorough clinical examination of the mucosal membrane.

The purpose of this article is to present removable prosthetic treatment options that we chose for the extended partially edentulous and completely edentulous patients who required prosthetic rehabilitation treatment in our clinic. The chosen prosthetic solutions took into consideration the morphological characteristics of the mucosal layer of the denture support area and of the peripheral structures and the pro-prosthetic treatment phase and the impression phases were accordingly individualized.

### Patients And Methods

We conducted this study on 52 extended partially edentulous and completely edentulous patients, 31 women and 21 men who addressed the Prosthetic Dentistry Clinic of the University of Medicine and Pharmacy of Craiova between may 2014 - february 2015, requesting prosthetic treatment. Out of the total number, 32 patients were extended partially edentulous and 20 patients were completely edentulous (Fig. 1). We obtained the informed consent from all the patients included in this study.

The patients were clinically examined, according to the clinic's prosthetic observation form. Considering the alterations that some systemic diseases may cause to the mucosal substrate of the denture support area, we have sought to identify, through anamnesis, the presence of such conditions in our patients.

We recorded in the examination chart the characteristics of the mucosal membrane covering the denture supporting structure and the peripheral structures. We wrote down in each patient's examination chart the following mucosal characteristics: color, thickness, sensitivity, resilience, alterations - if they are present- such as color modifications, the

existence of flabby ridge, flabby maxillary tuberosity or flabby retromolar pad, mucosal hyperplasia. We also carefully examined the incisive papilla, palatal rugae and median raphe's aspect.

Prosthetic treatment was instituted for every patient and the treatment phases were individualized according to the existent clinical situation. All the patients received new, stable, function restoring dentures.

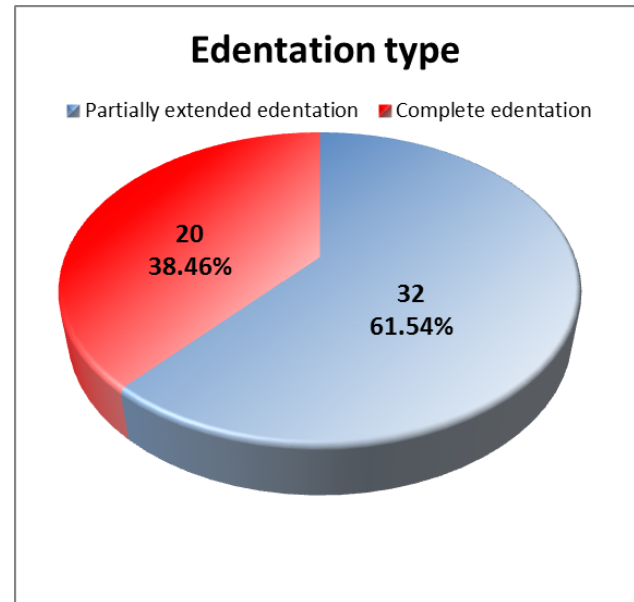


Fig.1. Patient distribution according to edentation type

Statistical analysis was performed using Microsoft Excel (Microsoft Corp., Redmond, WA, USA), and IBM SPSS Statistics 20.0 (IBM Corporation, Armonk, NY, USA) for processing the data.

Data Processing - descriptive analysis of the study group and their graphic representation was performed with MS Excel, while complex statistical tests (Fisher exact test) were performed using SPSS.

The Chi square test ( $\chi^2$ ) is a statistical test that shows if there is a connection (association or influence) between two factors. It is used to interpret incidence tables generated by cross tabulation of 2 factors monitored in the study. If, for the analyzed incidence table, the probable frequency is less than 1, or if more than 20% of probable frequencies are less than 5, it is recommended to use Fisher's exact test when its application is allowed (small groups with <100 cases, small incidence tables, with less than 10 cells, e.g. 2x2 - 5x2, 3x3).

Because the study group consisted of a small number of subjects and its division according to different factors that we investigated led to

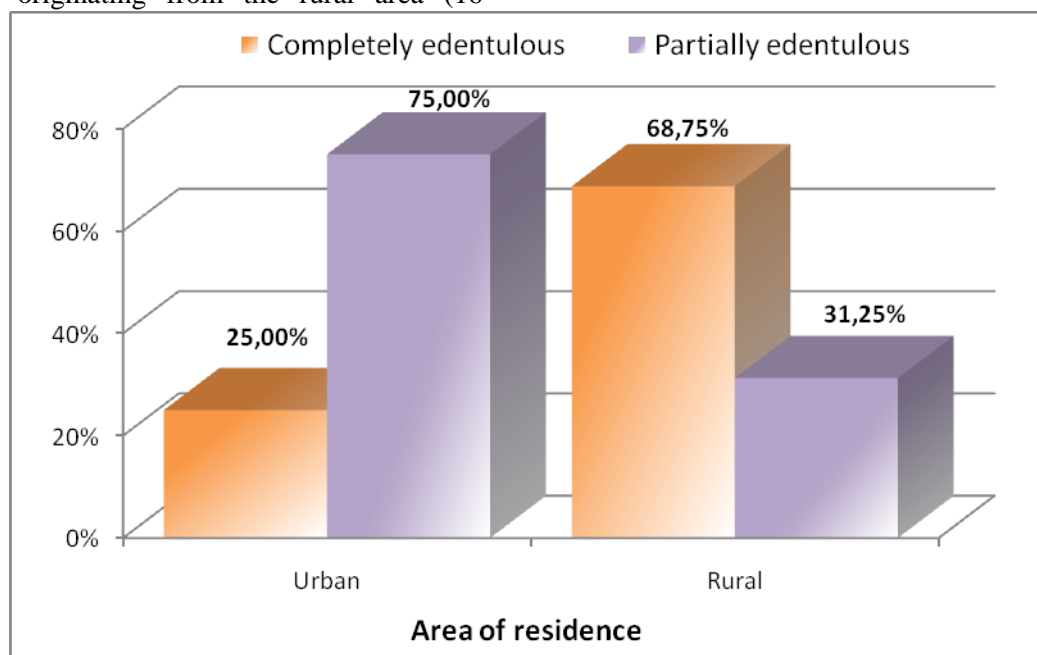
creation of subgroups with less than 5 subjects, we had to use Fisher's exact test. This test is used to compare the distribution of data over the categories of one factor for each of the categories of the second factor, when analyzing the relationship between two factors. A statistically significant result of this test ( $p < 0.05$ ) means the distributions are different, so the categories of the first factor have a different impact on the second factor, meaning there is a relationship between certain categories of the two factors.

## Results

Of the total 52 extended partially and completely edentulous patients, 29 (55,76%) presented different systemic diseases: cardiovascular diseases, type I and type II diabetes, liver diseases, autoimmune diseases, kidney diseases. The most frequent diseases we encountered were cardio-vascular diseases (12 patients) and diabetes (10 patients). 5 patients had both diabetes and cardio-vascular disease.

Of the total number of patients, the ones originating from the urban area predominated (36 patients, representing 69,23%), compared to patients originating from the rural area (16

patients representing 30,76%). Patient distribution according to the edentation type and to the urban/rural area, showed the prevalence of completely edentulous patients originating from the rural area (11 patients of the total of 20 completely edentulous patients, representing 55%). In the case of extended partially edentulous patients, the ones originating from the urban area prevailed (27 of the total 32 extended partially edentulous patients, representing 84,37%). Of the total number of 36 patients from the urban area of residence, 9 patients were completely edentulous (25%) and 27 were extended partially edentulous (75%); of the total number of 16 patients from the rural area of residence, 11 patients were completely edentulous (68,75%) and 5 patients were extended partially edentulous (31,25%) (**Fig. 2**). Using Fisher's exact test, we proved there is a statistically significant difference between subjects living in urban areas and subjects living in urban areas and subjects living in rural areas regarding the edentation type. Rural subjects tend to be completely edentulous in far greater percentage than urban subjects (68.75% vs. 25%,  $p = 0.0037 < 0.05$ ).



**Fig.2. Patient distribution according to edentation type and area of origin**

The patients were aged 52 to 83 years old. 65 to 75 years old group presented the highest rate of both partially extended edentation (10 patients – 31,25%) and complete edentation (6 patients – 20%). The edentation's etiology was carious for the majority of patients (46,15%), periodontal disease was the etiology

for 30,77% and 23,08% of patients plurifactorial etiology.

After the clinical examination, two groups resulted: the first group consisted of 24 patients who were not denture wearers, 7 of which were completely edentulous (29,17%) and 17 were extended partially edentulous (70,83%) and the

2<sup>nd</sup> group consisted of 28 patients who were denture wearers, but needed new dentures, of which 13 were completely edentulous (46,43%) and 15 were extended partially edentulous (53,57%) (Fig. 3). Even if previous denture

wearers tend to be completely edentulous in greater percentage, the analysis of our data couldn't sustain this, statistically, as Fisher's exact test result was  $p=0.161 > 0.05$ .

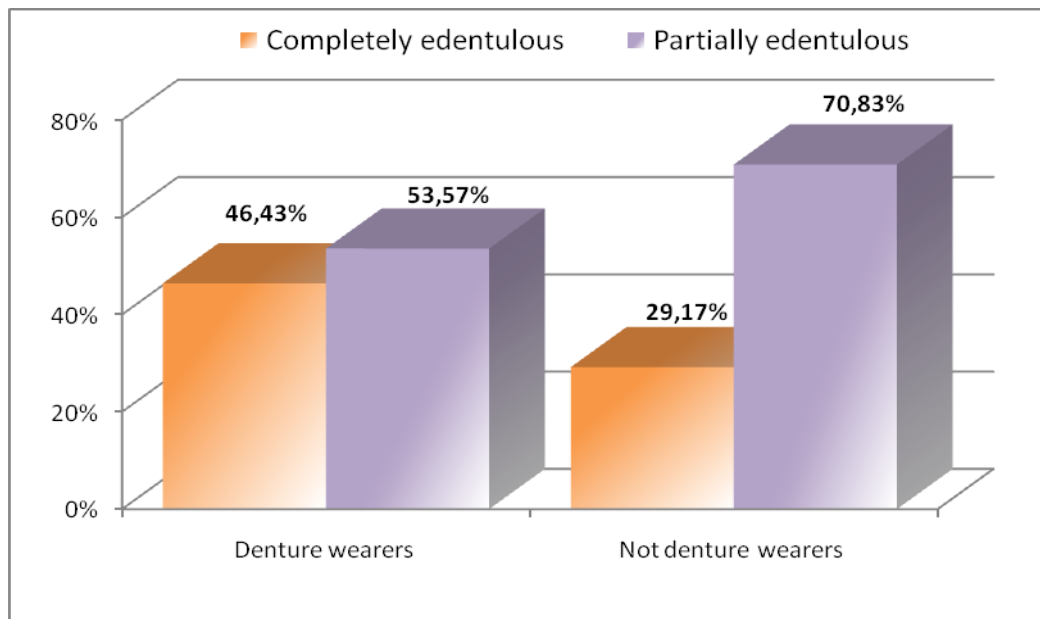


Fig.3. Patient distribution according to edentation type and the existence of a previous removable denture treatment

Intraoral clinical examination highlighted the denture support area's and the peripheral area's mucosal membrane characteristics. Out of the total of 28 denture wearers patients (representing 53,85%), we encountered 7 cases of mucosal hyperplasia (25%) and 21 cases without mucosal hyperplasia (75%). Of the 24 not-denture wearers patients (representing 46,15%), one

patient presented mucosal hyperplasia (4,17%) and in 23 cases we did not encounter mucosal hyperplasia (95,83%) (Fig. 4). Previous denture wearers are more prone to mucosal hyperplasia, as proven by the result we obtained for Fisher's exact test,  $p=0.042 < 0.05$ , which is statistically significant.

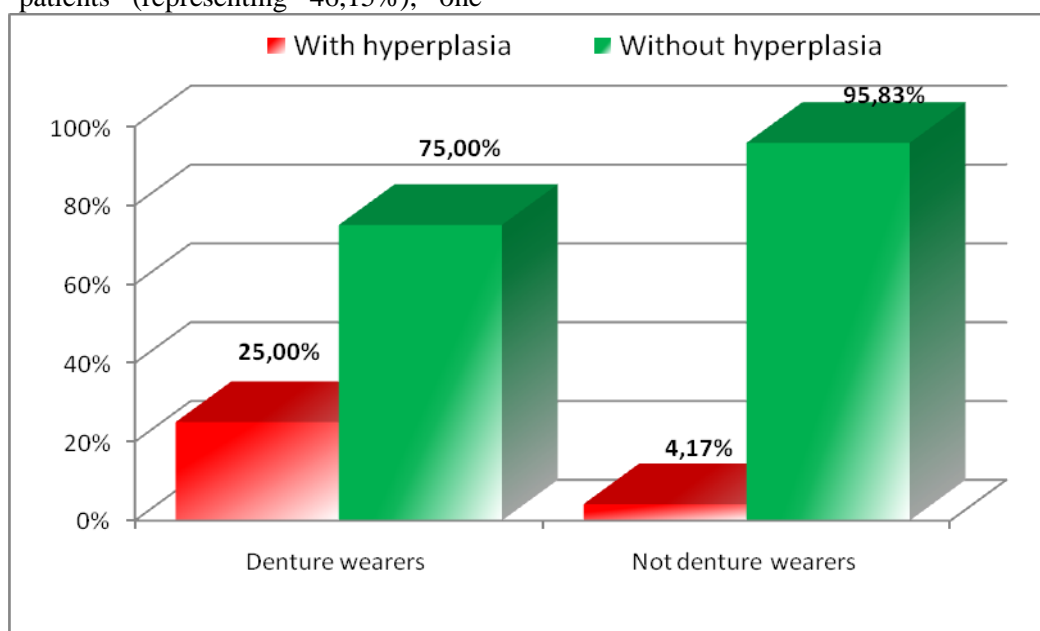


Fig.4. Oral mucosal hyperplasia incidence among denture wearers and not denture wearers patients

We surgically removed the oral mucosal hyperplasia and restricted the patients from wearing their old dentures.

In the cases of 6 not-denture wearers patients (25%) and 3 denture wearers patients (10,71%), angular cheilitis was present. (Fig. 5). In these cases, the vertical occlusal dimension was reduced, favourising salivary leakage. The mycological examination showed the presence

of *Candida albicans* in 5 out of these 9 cases. We initiated local and general antifungal treatment for these patients, as well as the restriction of wearing the old dentures. Despite the fact that previous denture wearers have angular cheilitis in smaller percentage than not denture wearers (10.71% vs. 25%), this difference could not be proven significant for our data, as Fisher's test result was  $p=0.161 > 0.05$ .

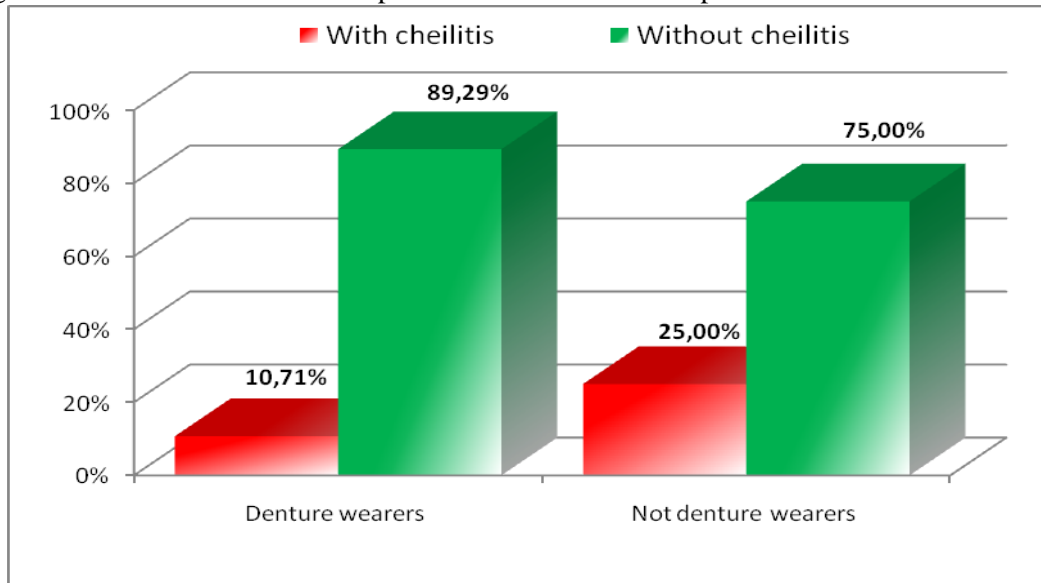


Fig.5. Angular cheilitis incidence among denture wearers and not denture wearers patients

Another particularity that we encountered was the existence of flabby maxillary tuberosity. It was unilateral in 4 cases of denture-wearers patients, and bilateral in 4 cases. 2 not denture wearers patients had unilateral flabby maxillary tuberosity. In our study, patients that were not denture-wearers did

not have bilateral flabby maxillary tuberosity (Fig. 6). The presence of flabby maxillary tuberosity shows differences for denture and not denture wearers, but these are not statistically significant, at least not for our data ( $p=0.1211 > 0.05$ ).

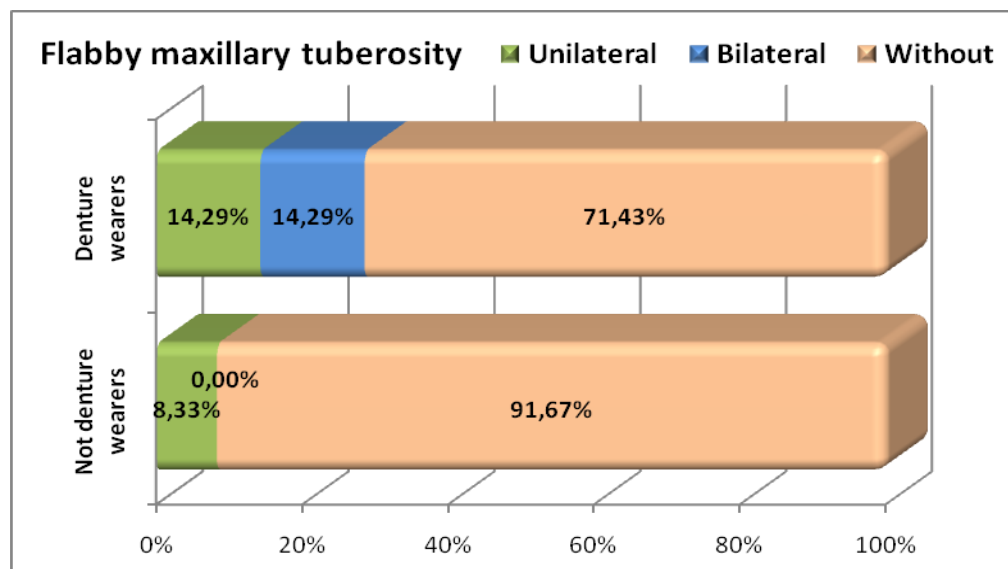


Fig.6. Flabby maxillary tuberosity incidence among denture wearers and not denture wearers patients

We encountered the presence of unilateral flabby retromolar pad in the case of 1 denture wearer patient (3,57%) and bilateral flabby retromolar pad in another case (3,57%). 3 not denture wearers patients presented unilateral flabby retromolar pad (12,50%) and 1 patient presented blateral flabby retromolar pad (4,17%)

(Fig. 7). The differences between previous denture wearers and not denture wearers are even smaller for flabby retromolar pad, so it comes as natural that the result of Fisher's exact test is much greater than the maximum limit for statistical significance -  $p=0.545 > 0.05$ .

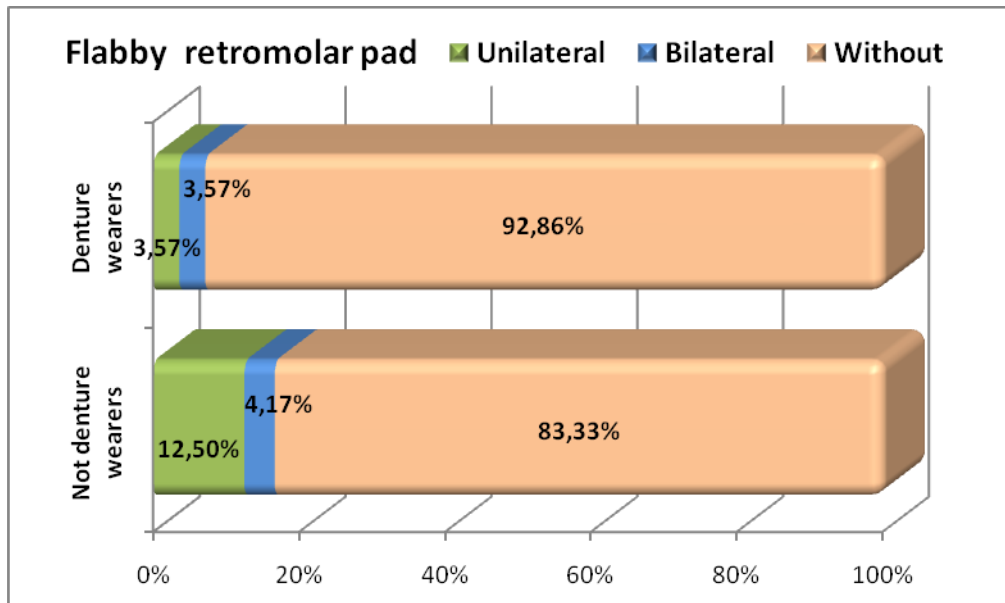


Fig.7. Flabby retromolar pad incidence among denture wearers and not denture wearers patients

The number of completely edentulous patients that presented maxillary anterior flabby ridge was 5 and 3 of them were cases of Combination Syndrome, as they were maxillary completely edentulous and presented Kennedy Class I mandibular edentation. We also encountered 2 cases of anterior flabby mandibular ridge (Fig. 8a).

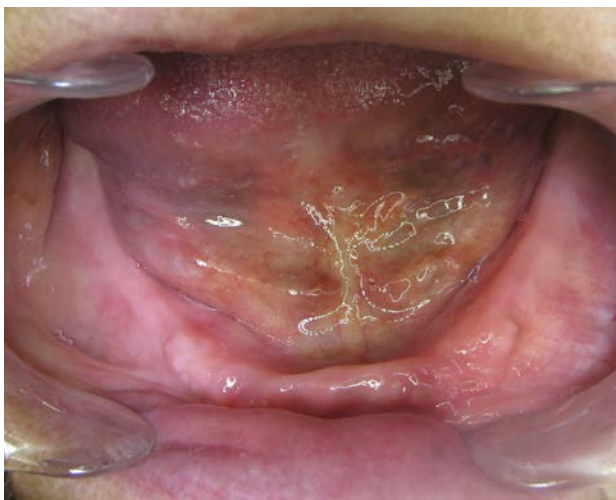

Fig.8.a. Mandibular complete edentation

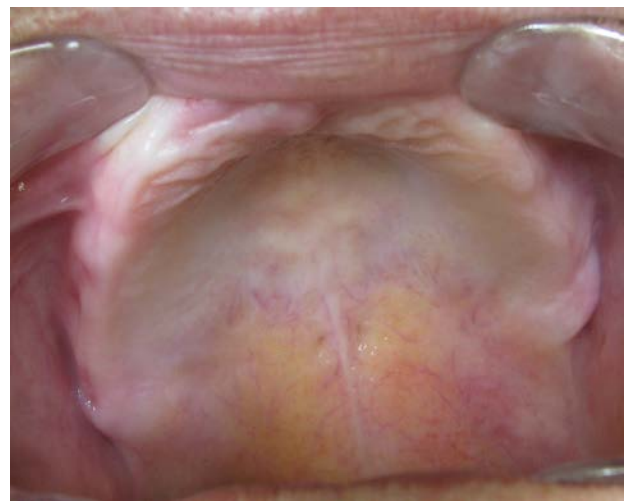


Fig.8.b. Maxillary complete edentation

Another important parameter that we examined was the degree of mucosal resilience. It was different from one patient to another and from one sector of the denture support area to another. From the total number of 20 completely edentulous patients, 4 had soft denture support area, characterized by an overlaying oral mucosa

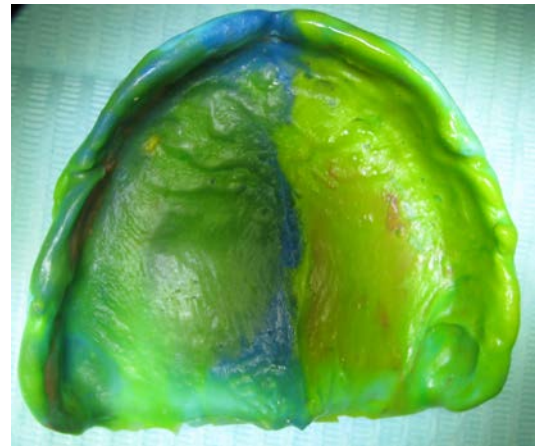
with a high degree of resilience, 5 had oral mucosa adherent to the periosteum with underrepresented submucosal tissue and a lower degree of mucosal resilience and in 11 cases the degree of oral mucosal resilience was variable from one area to another. The remaining 8 patients had denture support area characterized by a mucosal resilience degree that was variable from one area to another and anatomical formations, such as the incisive papilla (**Fig. 8b**), palatal rugae and the median raphe, that needed protection during the impression taking procedure and also protection from the direct contact with the denture's base.

In such cases we opted for the use of a selective pressure final impression technique, that takes into consideration the support area's anatomy and that tries to functionally distribute the pressures to the areas that are most capable of supporting them. The utilised material for the final impression was polyvinyl-syloxane of different consistencies. The custom tray was perforated in areas corresponding to the regions that needed protection from excessive pressure.

Border molding was done using Sta-Seal f, a medium consistency polyvinyl-syloxane. First we placed adhesive on the custom tray's border, then, along the tray's same border, a polyvinyl-syloxane (Sta-Seal f) roll. The roll's thickness in the posterior palatal area was according to the mucosa's resilience degree. The patient was instructed to execute specific moves that mobilized the peripheral structures.

After examining if the border molding is adequate, we placed the final impression materials with different consistencies corresponding to the mucosal substrate's characteristics: we placed the medium body polyvinyl-syloxane along the area of the custom tray that corresponds with the residual ridge that is usually covered by thin and adherent fixed mucosa and the light body material in the area covered by more resilient mucosa. After the final impression material set, we removed the impression from the mouth and inspected its precision.

We obtained a muco-dynamic final impression with 4 different consistency polyvinyl-syloxane: heavy-medium, medium, light and extra-light (**Fig. 9**). This impression technique allows the obtaining of a denture capable of correctly transmitting the occlusal forces to the different areas of the supporting structure.



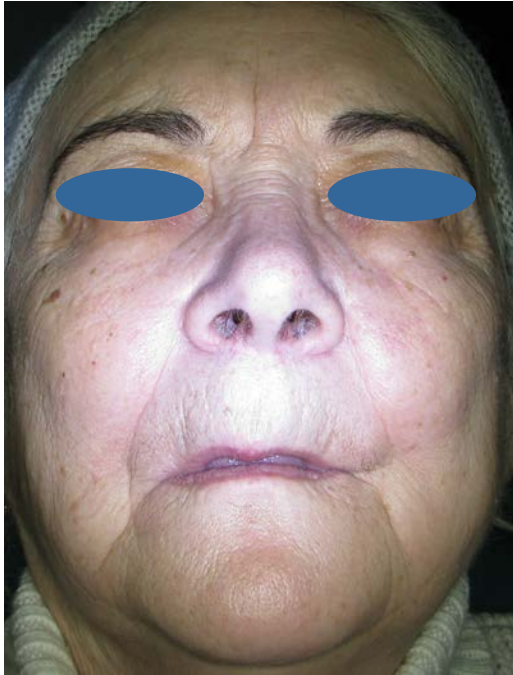**Fig.9. Final maxillary impression**

For the mandibular completely edentulous cases, with reduced mucosal resilience, for the final impression phase we used an acrylic custom tray. We adapted its borders and first we made the impression of the supporting structure with zinc oxide eugenol paste and then we made the border molding. The advantages of making the supporting area's impression before border molding consist of: stabilizing the custom tray on the future denture bearing area during border molding, offering the possibility of correctly repositioning the custom tray in the mouth and of avoiding the border alterations caused by the marginal overflow of the material used for making the denture bearing area's impression and also ensuring the custom tray a high maintenance and thus the capacity to record the retromylohyoid fossa. After making the supporting structure's impression. The border molding material that we utilised was Ex-3-N Gold (Johannes Meist Dentalfabrikation) and we used the one-step technique (**Fig. 10**). Border molding movements were carried out by the doctor and by the patient.

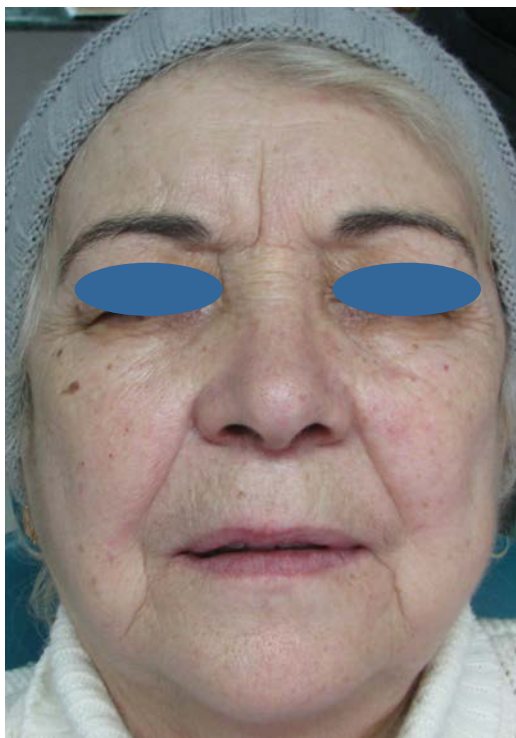

**Fig.10. Final mandibular impression**

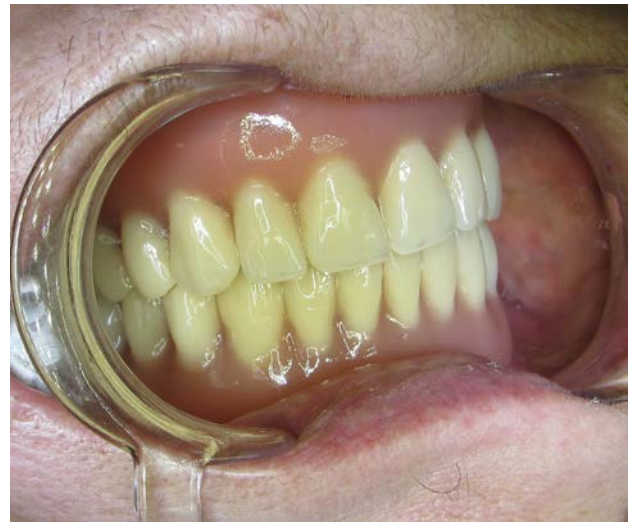The dentures restored the affected functions: mastication, phonetics, physiognomic appearance. (Fig. 11, Fig. 12, Fig. 13).



**Fig.11. Completely edentulous patient's facial aspect before prosthetic rehabilitation**



**Fig.12. Completely edentulous patient's facial aspect after prosthetic rehabilitation**



**Fig.13. Maxillary and mandibular dentures - intraoral aspect**

### Discussions

In general, older patients have significant mucosal resorptions, the attached mucosa becoming thinner and pressure-sensitive, all because of the senescence process that reduces the body's water quantity and alters the connective tissue [8]. Because of the aging process, there are trophic disorders of the oral mucosa, caused by the poor vascularization and by the qualitative and quantitative changes affecting its epithelial and connective components. The visco-elastic quality of the tissues is thus diminished. Fixed mucosal areas become mobile, losing their connection with the periosteum and thus mucosal folds appear [9]. In our study, the patients suffering from cardio-vascular diseases and those with diabetes, had a reduced salivary secretion probably because of their medication, which resulted in a thin and dry mucosal substrate.

Fixed mucosa overlaying the hard palate, the maxillary tuberosity and the retromolar pad undergoes, with time, especially in the cases of completely edentulous patients, more or less significant morphological alterations.

The use of a denture creates a special situation, because these structures are required to perform functions they are not structured for [10]. The supporting structure's mucosal component comes into direct contact with the denture's base and receives the masticatory pressures. These two interfaces define a space and their relationship takes place inside this space, which has a certain spread, a minimum thickness, is sealed and is occupied by the salivary film. The supporting structures



should include, in the cases of complete dentures prosthetic rehabilitation, the entire fixed mucosa and, in the partial removable dentures cases, only a part of the fixed mucosa. The larger the supporting area is, the better the functional pressures are dispersed and are also less demanding for the mucosal substrate.

In order to correctly disperse the pressures to the osteo-mucosal substrate, several final impressions have been devised. Massad believes that the type of material utilised for final impression plays an essential part in exerting pressure during this impression phase. He also believes that it is important to apply, simultaneously or one at a time, different viscosity impression materials, resistant to dissociation, aiming to obtain a final impression with harmonious overlapping layers that correctly records all the morphological details [11]. We used his impression method for the completely edentulous cases with variable degrees of mucosal resilience and with mucosal structures that needed to be protected. The polyvinyl-siloxane's viscosity we utilised was heavy-medium for the border molding procedure and medium, light and extra-light for the supporting area impression procedure. This composite final impression technique, performed according to the morphological characteristics of each area, provides appropriate denture support, both at the time of its insertion and during its daily wear, thus also following the prosthetic therapy's prophylactic component.

The denture moves on the supporting area, the movement depending on the residual ridge's mucosal displacement [12]. This displacement depends on the mucosal degree of resilience but is also, inherently, encountered during some of the stomatognathic system's functions. The denture movements have great traumatic potential for the mucosal substrate and represent causes of osteo-mucosal resorption that alters the supporting area's morphology and increases denture instability.

The mucosa that covers the residual ridges of edentulous patients may present some distortion or displacement when occlusal loading is applied on complete dentures. This distortion and movement of the denture can result in acceleration of residual ridge resorption and loss of retention and stability of the denture. A good impression holds the key to a successful

treatment in cases of resorbed mandibular ridges where we have minimum tissue to fulfil the fundamental requirement of retention, stability and support [13].

The flabby ridge or movable tissues are frequently seen in maxillary anterior ridge when the edentulous maxilla is opposed by natural teeth in the mandibular anterior region [13]. Kelly in 1972 reported that mandibular anterior teeth cause trauma on maxillary anterior ridge as all occlusal forces are directed on to this area. This results in loss of bone from the anterior maxilla with subsequent fibrous tissue hyperplasia. Impression methods utilised in these cases had the purpose of recording the flabby mucosa in an undisplaced manner [13, 14]. Ill-fitting dentures are a cause of abuse for the oral mucosal support [15]. The new dentures are made only after solving the existing problems, which are identified through detailed clinical examination.

## Conclusions

The clinical implications of the research we carried out revealed the importance of morphological variation encountered in denture bearing area's mucosal substrate for optimal prosthetic treatment choice. These variations are caused by local and general factors and they influence the denture treatment phases. Surgical preprosthetic treatment creates a removable prosthetic – favourable supporting structure that is able to withstand pressures exerted on it.

## Acknowledgment

This paper was published under the frame of European Social Fund, Human Resources Development Operational Programme 2007–2013, Project No POSDRU/159/1.5/S/136893.

## References

1. Monica Mihaela Crăițoiu, Mihaela Păuna, Veronica Mercuț, Ștefania Crăițoiu, Elena Annabel Nițulescu. Clinical, histological and therapeutic study regarding the variations of the edentulous ridge's mucosa, Rom J Morphol and Embriol 2009; 50(3):441-445.
2. Zarb G, Bolender CH, Carlsson G. Boucher's Prosthodontic Treatment for Edentulous Patients. Mosby Year Book St. Louis, Missouri 1997:13-45;141-181.
3. Preoteasa E. Aspecte clinice și terapeutice în edentația totală cu modificări ale statusului oral, Ed. Universitară Carol Davila, București 2005: 1-7.
4. Hüe O, Berteretche MV. Prothèse Complète. Réalité Clinique. Solutions thérapeutiques, Ed. Quintessence International Paris 2004: 10-12.

5. Grant AA, Heath JR, McCord JF. Complete prosthodontics problems, diagnosis and management, Wolfe 1994:90-92.
6. Ivanhoe JR, Cibirka RM, Parr GR. Treating the modern complete denture patient: a review of the literature, J Prosthet Dent. 2002 Dec; 88(6):631-5 Review. PMID: 12488857.
7. Louis JP, Archien C, Ludwigs H. An original rehabilitation method for the totally edentulous. 1. Primary impressions. Article in French, Cah Prothese. 1990 Jun; (70):88-97.
8. Fleishman R, Peles DB, Pisanti S. Oral mucosal lesions among elderly in Israel. J Dent Res 1985;64(5):831-836.
9. Xie Q, Narhi TO, Nevalainen JM, Wolf J, Ainamo A. Oral status and prosthetic factors related to residual ridge resorption in elderly subjects. Acta Odontol Scand 1997;55:306.
10. Taïeb F, Carpentier P. Anatomie des zones rétromolaire maxillaire et mandibulaire: incidence en prothèse totale II. La région retromolaire mandibulaire. Cah Prothese 1989;67:113-119.
11. Massad J. Building the edentulous impression: a layering technique using multiple viscosities of impression material. Compendium 2006;27(8):446-451
12. Compagnoni MA, De Souza RF, Leles CR. Kinesiographic study of complete denture movement related to mucosa displacement in edentulous patients. Pesqui Odontol Bras 2003;17(4):356-61.
13. Krishna Prasad D, Divya Mehra & Anupama Prasad D. Prosthodontic management of compromised ridges and situations, NUJHS 2014; 4(1):141-148.
14. Kelly E. Changes caused by a mandibular removable partial denture opposing a maxillary complete denture. J Prosthet Dent 1972; 27:140-50.
15. Le Bars P, Amouriq Y, Bodic F, Giumelli B. Reactions tissulaires au port des appareils de prothese dentaire amovible partielle ou totale. Odontologie, P-10, 23325 Paris: Encycl Med Chir, 2002.

---

**Correspondence Address: Monica Mihaela Crăițoiu, MD, PhD, Department of Prosthetic Dentistry, Faculty of Dental Medicine, University of Medicine and Pharmacy of Craiova, 2 Petru Rareș Street, Craiova, Romania; e-mail: mcraitoiu@yahoo.com**