




# Accuracy of computer-assisted, template-guided implant placement compared with conventional implant placement by hand—An in vitro study

David Schneider  | Caroline Sax | Manuel Sancho-Puchades |  
Christoph H.F. Hämmerle  | Ronald Ernst Jung 

Clinic of Reconstructive Dentistry, Center of Dental Medicine, University of Zurich, Zurich, Switzerland

## Correspondence

David Schneider, Clinic of Reconstructive Dentistry, Center of Dental Medicine, University of Zurich, Plattenstrasse 11, CH-8032 Zurich, Switzerland.  
Email: david.schneider@zsm.uzh.ch

## Funding information

Swissmeda; Dentsply Sirona

## Abstract

**Objectives:** To compare free-hand to computer-assisted implant planning and placement (CAIPP) regarding planned to achieved implant position.

**Material and methods:** Forty-eight cast/bone models were mounted in mannequin heads. On each side, a tooth gap of different sizes was created. In the test group (T), study implants were placed using a CAD-CAM guide based on virtual planning. In the control (C), free-hand implant placement was performed. After CBCT scanning, the implant position was compared with the planned position. Descriptive statistics were applied, and ANOVA was used to identify differences between groups and gaps. ( $p < .05$ ).

**Results:** In C, mean lateral deviations at the implant base amounted to 0.7 mm (max. 1.8) (large gap) and 0.49 mm (1.22) (small gap). In T, 0.18 mm (0.49) and 0.24 mm (0.52) were recorded. At the apex, 0.77 mm (2.04) (large gap) and 0.51 mm (1.24) (small gap) were measured in C, and 0.31 mm (0.83)/0.34 mm (0.93) in T. Mean vertical deviations in C measured 0.46 mm (1.26) (large gap) and 0.45 mm (1.7) (small gap). In T, 0.14 mm (0.44) and 0.28 mm (0.78) were recorded. Mean angular deviations of 1.7° (3.2°) were observed in C (large gap) and 1.36° (2.1°) (small gap). In T, mean values were 1.57° (3.3°) and 1.32° (3.4°). Lateral and vertical deviations were significantly different between groups (not gaps), angular between gaps (not groups).

**Conclusions:** CAIPP protocols showed smaller deviations irrespective of the size of the tooth gap. In C, the gap size had an influence on the error in angulation only.

## KEYWORDS

computer-assisted implantology, digital dentistry, guided surgery

## 1 | INTRODUCTION

The use of dental implants to prosthetically restore (partially) edentulous patients is a routine procedure with high long-term success rates (Hjalmarsson et al., 2016; Jung et al., 2008). In the recent past, computer-based technologies including 3D-analysis of radiographic data and the use of CAD-CAM procedures were able to produce surgical guides, which have been implemented in the clinical treatment workflow. Several systems are commercially available and are advertised by the manufacturers as easier, more accurate, and safer compared with conventional protocols using two-dimensional x-rays and free-hand implant placement, even allowing flapless implant installation and prefabrication of prostheses for immediate loading.

Numerous studies have investigated the accuracy of transferring the virtual implant position into the patients' bone showing mean lateral deviations of approximately 1 to 2 millimeters (Skjerven et al., 2019; Valente et al., 2009; Van Assche et al., 2012; Van de Wiele et al., 2015). However, analysis of the scientific literature reveals a considerable deviation of drill holes or implants from the planned position in some cases (Jung et al., 2009; Schneider et al., 2009). As a result of these deviations, potential injury of adjacent anatomic structures such as adjacent roots, nerves, and blood vessels may occur. Up to now, limited data are available to confirm the superiority of computer-assisted planning and template-guided implant placement (CAIPP) in direct comparison to free-hand implant placement.

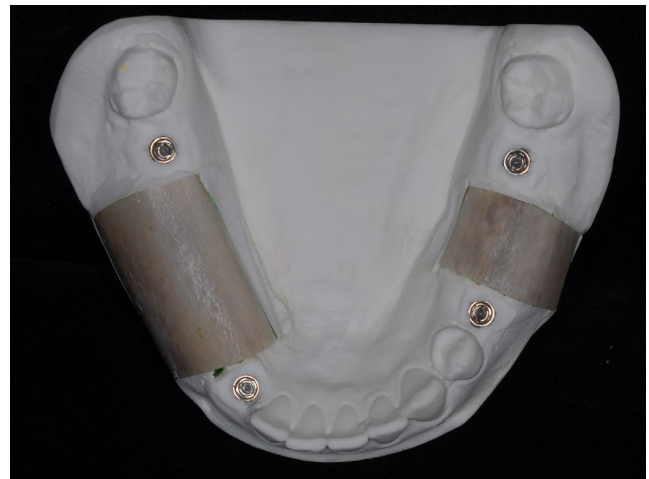The aim of this *in vitro* study was to investigate whether or not the use of computer-generated surgical templates improves the positioning of implants in a clinically based setup compared with free-hand implant placement.

The hypothesis was that a more accurate implant position would be achieved by using the CAIPP protocol.

## 2 | MATERIAL AND METHODS

The present study was performed at the clinic of reconstructive dentistry at the center of dental medicine of the University of Zurich, Switzerland.

Forty-eight identical cast models (Fuji Rock) representing the lower jaw of a male human were fabricated from a reference model which was reproduced using a silicone form. A triple tooth gap (missing teeth number 34, 35, and 36) and a single tooth gap (missing tooth number 46) were spared out in the cast model. Four reference implants (Astra Tech, Mölndal, Sweden; type 4.0s, length 8 mm) bordering the actually investigated implant site were placed parallel and at the same vertical level as the bone crest using a surveyor and impression copings for transfer of the implants. These implants served as a reference regarding the position of the test implants and for the later superimposition of the CBCT data (Figure 1). Two customized, degreased, and deproteinized pork rib segments were embedded at the level of



**FIGURE 1** Cast models with embedded bone segments and bordering reference implants. On one side, representing the 3rd quadrant, a small tooth gap is present, on the other one, representing the 4th quadrant, a large tooth gap is present (reference implants further away from each other)

the reference implant shoulder (Kalt and Gehrke, 2008) leading to 96 implant sites.

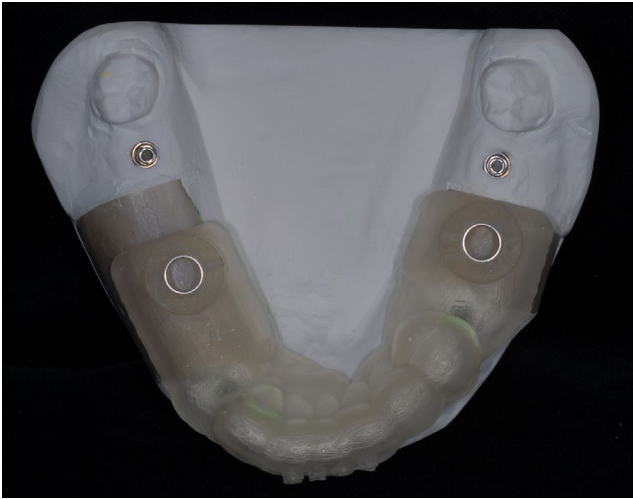The implant sites were equally divided into two investigational groups (test group and control group):

### 2.1 | Test (T): Computer-assisted implant placement planning and template-guided implant placement

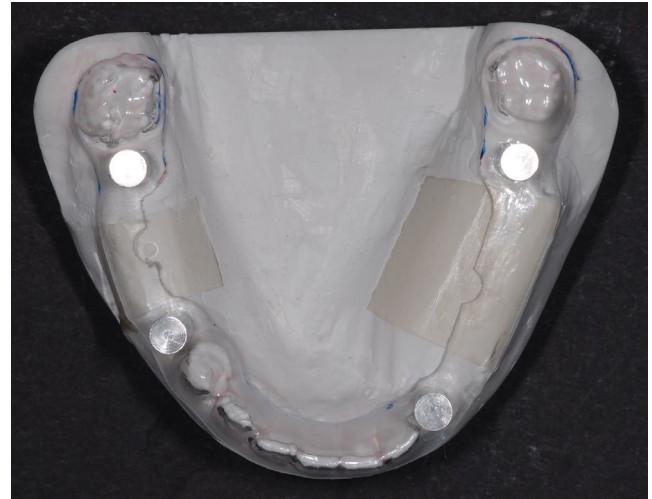The cast models with scan abutments mounted on the reference implants were captured by a first cone-beam CT (3D exam, KaVo; 120 kV acceleration voltage, 5 mA beam current, FOV diameter of 16 cm, FOV height of 6 cm, 600 projections, 360° rotation, voxel size of 0.25 mm, and scan time of 26 s). The obtained radiographic data were imported into a planning software (SimPlant/Facilitate, Materialise). In the software, the test implant was virtually placed at half distance between the reference implants and at the same level as a line connecting the base of the reference implants, parallel to the mesial reference implant. Subsequently, the data including the test implant position were sent to the manufacturing center (Materialise) and a surgical guide was fabricated by means of stereolithography (Figure 2). This guide was used for template-guided drilling and implant placement using the facilitated surgical system according to the manufacturer's protocol. The type of implants placed was Astra 4.0S, 8 mm.

### 2.2 | Control (C): Conventional non-guided implant placement using a conventional surgical template

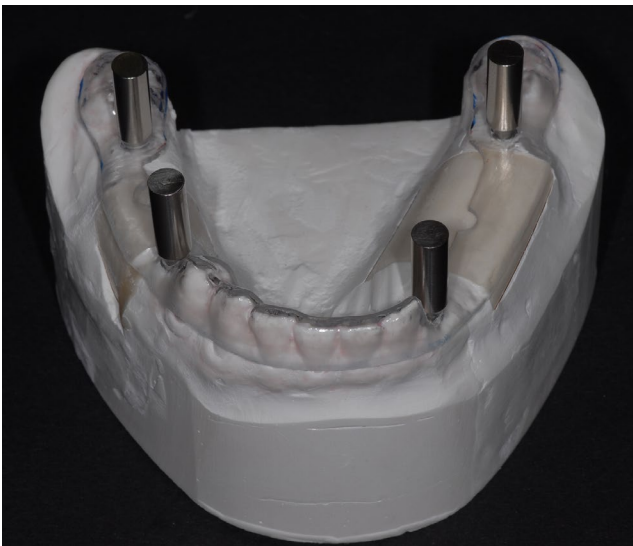The implant was placed manually with a conventional lab-fabricated surgical guide made of acrylic serving as a "prosthetic reference." As



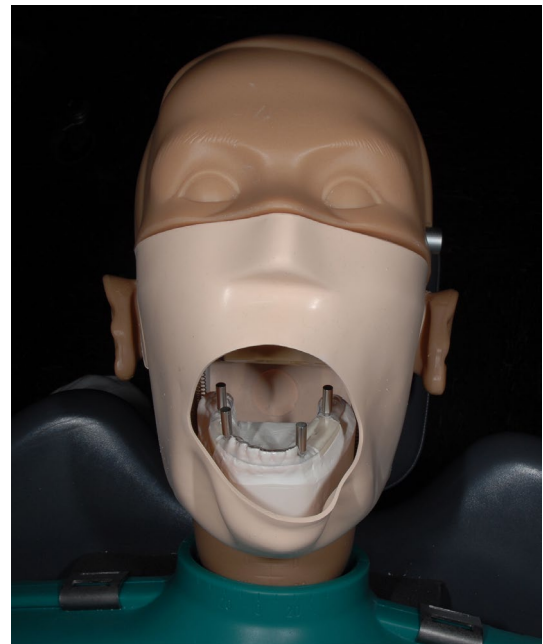
**FIGURE 2** Surgical guide made by stereolithography with incorporated metal sleeves mounted on the cast model for the implant placement in the test group



**FIGURE 4** Occlusal view of the cast model prepared for implant placement of the test group (see description of Figure 2)



**FIGURE 3** Cast model for implant placement in the free-hand control group. Metal posts are mounted on the reference implants for identification of the implant axis. A primitive transparent acrylic lab-fabricated orientation template is also mounted (corresponding with a clinically used lab-fabricated prosthetic template)



**FIGURE 5** Cast models mounted in a mannequin head

in the test group, the aim was to place the implant at half the distance on a line connecting the bordering reference implants (Figures 3 and 4). The axis should be parallel to the axis of the abutments/indicators on the mesial implant. It was intended to place the implant with its shoulder at the same level as the mesial and distal bone crest which corresponds with the level of the shoulder of the reference implants.

Prior to the implant placement, in both groups, the cast models were mounted in a mannequin head (Figures 5 and 6).

Both procedures, the placement by hand and the guided placement, were being performed by four clinicians (senior research and

teaching assistants) with several years of experience in implant dentistry including surgical and prosthetic procedures. The order of implant placement in the different groups was randomly allocated to the four clinicians.

After positioning of the test implant, radio-opaque scan abutments were placed and a second CBCT scan was performed using the same device and the same parameters as previously described.

These radiographic data were imported into a software program (SMOP, Swissmeda) for determination of the difference between the actual implant position compared with the initially planned and intended implant position (Figure 7).

Deviation from the planned position was evaluated as (Figure 8):

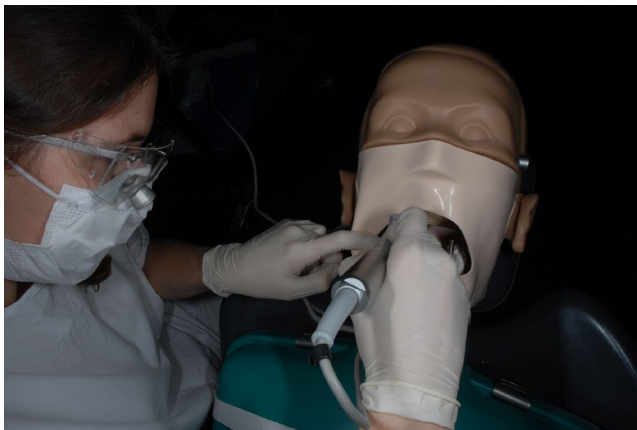1. Horizontal lateral deviation at base of the implant
2. Horizontal lateral deviation at apex of the implant
3. Vertical deviation at apex of the implant
4. Angular deviation

depending on:

1. the method of planning and placement: conventional (C) versus computer-assisted (T1/T2)
2. the size of the tooth gap or distance between reference implants (1 tooth versus 3 tooth gap), respectively

### 2.3 | Statistical analysis

Sample size calculation was performed assuming 80% power at a critical level of means difference between groups in deviation of the implant position of 0.6 mm. Deviation in horizontal direction was chosen due to its high clinical impact. A value of more than 0.5 mm



**FIGURE 6** Implant placement performed in the mannequin head mounted on a clinical treatment unit

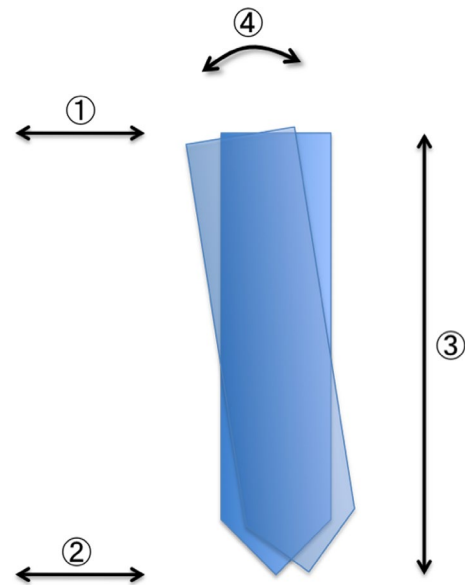
was considered clinically relevant, based on available data from other studies a standard deviation of 1 mm was used. This led the sample size of 94 implant sites. The level of significance was set at  $p < .05$ .

Statistical analysis was performed using the software program R (R core team (2016)).

Descriptive statistics were applied for the parameters analyzed (horizontal deviation at implant base and implant apex [mm], vertical deviation at apex [mm], and angular deviation [°]). Mean values, standard deviation (SD), min. (0%), lower quartile (25%) median (50%), upper quartile (75%), and max. (100%) were calculated.

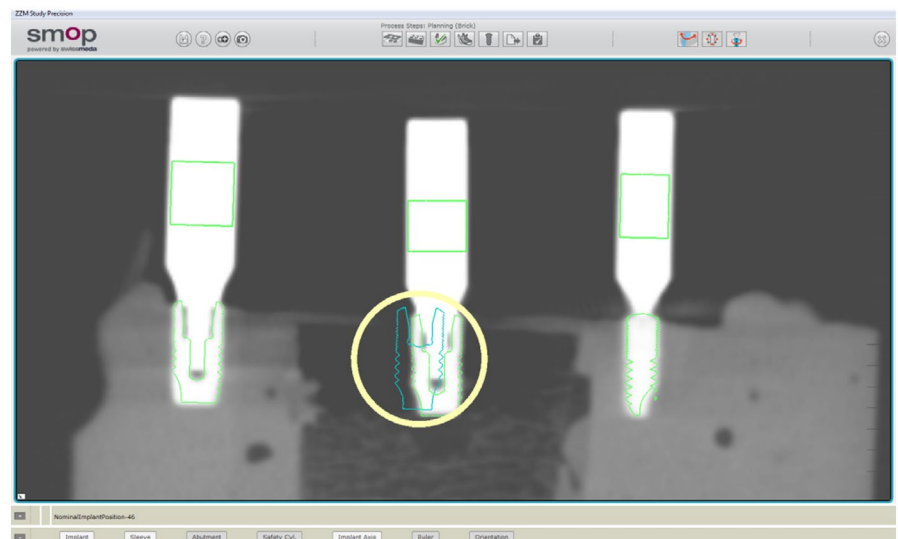Boxplots showing the results in the groups were plotted.

Two-way ANOVA was fitted to identify significant differences between groups (test versus control) and size of the gap (small versus large). In order not to violate the ANOVA assumptions, the



**FIGURE 8** Direction of deviations: 1. Lateral horizontal deviation at the base of the implant, 2. Lateral horizontal deviation at the apex of the implant, 3. Vertical deviation, and 4. Angular deviation

**FIGURE 7** Software analysis comparing the planned and actually reached implant position using CBCT data. Indicator abutments are mounted on the implants for a more precise implant position determination. The calculated, planned implant position is encircled (blue implant outline)



target values were log-transformed. For the two zero values encountered (one for deviation in height and one for angular deviation), a small constant of 0.01 was added to the entire data set to enable the calculation of *p*-values. In the case of vertical deviation, absolute values were used. The level of significance was set a  $p < .05$ .

### 3 | RESULTS

The results are displayed in Tables 1–4 and Figures 9–12.

At the base of the implant (Table 1), the lateral deviations amounted to 0.7 mm at the large gap site and to 0.49 mm at the

small gap site in the free-hand control group. The maximum deviations were 1.8 mm and 1.22 mm, respectively.

In the guided test group, the lateral deviations at the base amounted to 0.18 mm at the large gap and 0.24 mm at the small size gap. The maximum deviations amounted to 0.49 mm and 0.52 mm, respectively. Differences between groups were statistically significant ( $p < .001$ ) for small and large gaps, but no significant differences were found between small and large gap sites in either group ( $p = .71$ ).

Similar results were observed for lateral deviations at the apex of the implant (Table 2). In the free-hand control group, mean deviations of 0.77 mm at the large gap and 0.51 mm at the small gap were recorded with a maximum of 2.04 mm and 1.24 mm.

	min.	25%	50%	75%	max.	mean	SD
Control—large gap	0.14	0.32	0.56	0.93	1.80	0.70	0.48
Test—large gap	0.02	0.13	0.15	0.19	0.49	0.18	0.11
Control—small gap	0.06	0.22	0.43	0.72	1.22	0.49	0.33
Test—small gap	0.03	0.16	0.21	0.30	0.52	0.24	0.13

Note: Control=Free hand, Test=Guided.

**TABLE 1** Horizontal deviation at implant base [mm]

	min.	25%	50%	75%	max.	mean	SD
Control—large gap	0.16	0.40	0.64	1.17	2.04	0.77	0.53
Test—large gap	0.09	0.18	0.27	0.41	0.83	0.31	0.17
Control—small gap	0.06	0.25	0.53	0.66	1.24	0.51	0.33
Test—small gap	0.07	0.22	0.30	0.42	0.93	0.34	0.20

Note: Control=Free hand, Test=Guided.

**TABLE 2** Horizontal deviation at implant apex [mm]

	min.	25%	50%	75%	max.	mean	SD
Control—large gap	0	0.25	0.36	0.62	1.26	0.46	0.33
Test—large gap	0.01	0.09	0.17	0.29	0.44	0.19	0.13
Control—small gap	0.04	0.14	0.24	0.59	1.70	0.45	0.46
Test—small gap	0.02	0.09	0.29	0.39	0.78	0.28	0.19

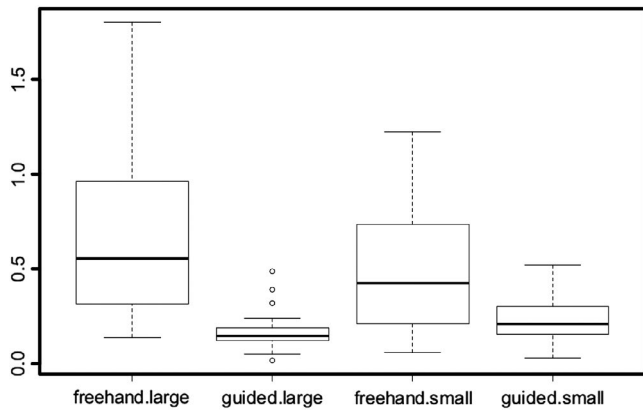
Note: Control=Free hand, Test=Guided

**TABLE 3** Vertical deviation [mm]

	min.	25%	50%	75%	max.	mean	SD
Control—large gap	0.80	1.20	1.65	2.20	3.20	1.70	0.67
Test—large gap	0.20	0.20	1.40	2.35	3.30	1.57	0.84
Control—small gap	0.00	0.00	1.20	2.10	2.80	1.36	0.78
Test—small gap	0.30	0.30	1.05	1.78	3.40	1.32	0.88

Note: Control=Free hand, Test=Guided

**TABLE 4** Angular deviation [°]



**FIGURE 9** Lateral deviations [mm] at the base of the implant depending on the size of the tooth gap

In the guided test group, the same values measured 0.31 mm and 0.34 mm in mean, 0.83 mm and 0.93 mm in maximum. Again, differences were only statistically significant between groups irrespective of the gap size ( $p < .001$ ), not between small and large gaps ( $p = .25$ ).

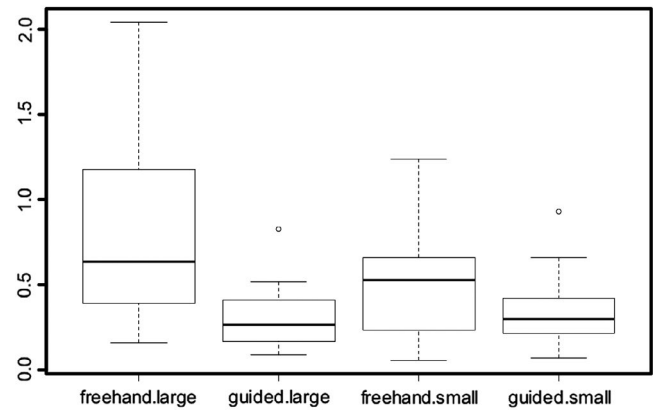
Mean vertical deviations (Table 3) in the control group amounted to 0.46 mm at the large gap site and 0.45 mm at the small gap site, reaching maximum values of 1.26 mm and 1.7 mm, respectively.

In the test group, the mean values were 0.19 and 0.28 mm, with maximum values of 0.44 mm and 0.78 mm. The differences between groups were statistically significant ( $p = .006$ ), not between sites of different gap sizes ( $p = .95$ ).

Angular deviations (Table 4) of a mean of  $1.7^\circ$  were recorded in the control for the large gap and  $1.36^\circ$  for the small gap, in maximum  $3.2^\circ$  and  $2.1^\circ$ . In the test group, mean values of  $1.57^\circ$  and  $1.32^\circ$  were recorded with maximum values of  $3.3^\circ$  and  $3.4^\circ$ . In contrast to the measurements above, the differences were statistically significant regarding the size of the gap ( $p = .04$ ) but not in respect to the group ( $p = .67$ ).

## 4 | DISCUSSION

In the present study, it was shown that the computer-assisted, template-guided approach resulted in a more accurate (defined as closer to target) and precise (defined as closer in terms of distribution) implant positioning when compared to free-hand implant placement. This was especially true for lateral deviation from the planned position as well as the vertical deviation, however, not for angular deviation. As expected, the size of the gap had no influence on accuracy and precision in the test group, since the position was calculated by the software and transferred to the surgical guide. In contrast, in the free-hand control group the difference between the large and small size gap did not reach statistical significance but a trend was observed toward less deviation in the small size group. This was somehow expected since the visual references, that is, posts on the adjacent reference implants, were closer together in the small size gap.

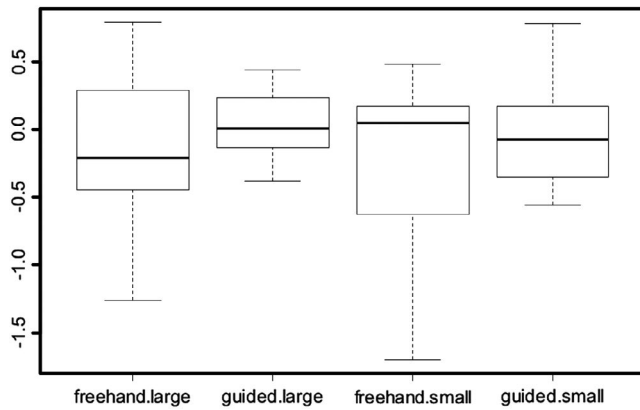


**FIGURE 10** Lateral deviations [mm] at apex of the implant depending on the size of the tooth gap

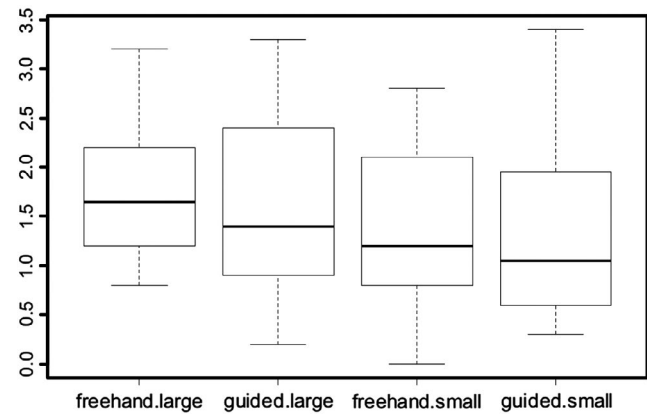
For angular deviation, the differences between groups were not significant. A possible explanation could be the tolerance of instruments within the guiding sleeves of the surgical guides. A certain degree of tolerance between components is mandatory for insertion of the instruments and for rotation of the drills. While the lateral and vertical tolerance is very limited, the angular tolerance of the instruments can be quite significant, as shown by previous in vitro studies (Schneider et al., 2015; Van Assche & Quirynen, 2010).

Nevertheless, it is quite surprising that the surgeons managed to keep the lateral, vertical, and angular deviation in a relatively low range. Recent systematic reviews on the accuracy of computer-guided implant planning and template-guided implant placement reported lateral deviations of approximately 0.5 to 1.5 mm at the base of the implant, 0.5 to 2 mm at the apex, around 1 mm in vertical direction, and 2 to 5 degrees angular deviation, however, with significant standard deviations for all values and maximum values of more than 6 mm lateral and  $24^\circ$  angular deviations (Bover-Ramos et al., 2018; Van Assche et al., 2012). In the present study, the deviations in the test group were smaller and amounted to a mean of around 0.2 mm (max. 0.5 mm) in lateral direction at the base of the implant and 0.3 mm (max. 0.9 mm) at the apex. Vertical deviation was below 0.3 mm in mean (max. 0.8 mm) and angular deviations reached means around  $1.6^\circ$  (max. just above  $3^\circ$ ). Even in the large gap control group, the lateral deviations amounted to a mean of just 0.7 mm and a maximum of 1.8 mm at the base and a mean of 0.8 mm at the apex, not exceeding 2 mm. In the free-hand group, the maximum deviations in the vertical measured 1.7 mm and angular deviations in maximum  $3.4^\circ$ .

A recent in vitro study was comparing conventional free-hand with computer-assisted template-guided implantation in a similar study setup as the present study. The authors also reported less deviation of the placed implant from the planned implant position in the CAIPP group compared with the free-hand approach when placing an implant in the maxillary anterior (Vermeulen, 2017). The deviations, however, were higher in both groups in comparison to the present study. In the free-hand group, the mean lateral deviation amounted to 1.27 mm at the base, 1.28 mm at the apex,



**FIGURE 11** Vertical deviations [mm] depending on the size of the tooth gap. Negative values mean a too shallow implant position



**FIGURE 12** Angular deviations [degrees] depending on the size of the tooth gap

0.78 mm in vertical, and 7.63° in angulation. In the CAIPP group, the respective numbers were 0.42 mm lateral the base, 0.52 mm at the apex, 0.54 mm in depth, and 2.19° in angulation. The maximum values, extracted from the charts as well as possible, seemed to be by far higher with angular deviations of up to 18° in the test group. Although the title of the study implies to compare experienced with non-experienced surgeons, the data do not allow any comparison based on experience. Nevertheless, the authors conclude that the CAIPP protocols increase the accuracy of implant placement irrespective of the experience of the surgeon.

In a combined clinical and in vitro study, free-hand implant placement was compared with CAIPP in a setup which was different to the present in vitro study (Nickenig et al., 2010). After virtual implant position planning, an implant was placed in unilateral free-end situations using a laboratory-fabricated template for instrument guidance. In the other group, conventional free-hand implant placement was performed by another surgeon (either maxillofacial surgeon or prosthodontist) on a cast model, in a position he found to be prosthetically and anatomically suitable. Postoperative CBCT scans were performed to compare the achieved implant position with the planned position in the CAIPP group. In the free-hand group, a CBCT scan was performed of the cast model with the implant in place and was compared with the preoperative virtual implant position. At the implant shoulder, the difference between the virtually planned to the actually achieved position amounted to a mean of 0.9 mm (0–4.5 mm) in the CAIPP group and 2.4–3.5 mm (0–7 mm) in the free-hand group. At the apex of the implant, a mean deviation of 0.6–0.9 mm (0–3.4 mm) was recorded in the CAIPP group, 2–2.5 mm (0–7.7 mm) in the free-hand group. Angular deviations of 4.2° in mean (0–10°) were observed in the CAIPP group, 9.8–10.9° (2–20°) in the free-hand group. The authors concluded that the CAIPP group was more accurate than the free-hand group. However, these numbers, especially the maximum values, are quite alarming and much less accurate than the ones achieved in the present study.

Another clinical study compared different modalities of surgical guide support and free-hand implant placement in fully edentulous patients (Vercreyssen et al., 2015). Computer-assisted implant

position planning was performed using a specific software program. In the CAIPP groups, surgical guides with mucosal or bone support were applied, while in the free-hand “mental guidance” group, the surgeons tried to transfer the virtually planned implant position according to their perception without the use of a surgical guide. Postoperative scans were used for comparison of the planned to the actually reached implant position. As in other studies, the free-hand group showed higher lateral and vertical deviations in comparison with the guided protocols. The overall mean deviations for the guided surgery groups were 0.9 mm (0 to 3.7 mm) in depth and 0.9 mm (range: 0.0 to 2.9) in lateral direction. Based on the charts in the publication, the free-hand group showed a mean lateral deviation of around 2 mm with maximum values of over 8 mm. In the vertical, the mean amounted to around 1 mm with a maximum value of 4.4 mm. Again, the results showed higher deviations than in the present in vitro study for the CAIPP and even more for the free-hand protocols.

One possible explanation for the relatively small deviations in both groups of the present investigation may be the study setup, namely the in vitro nature of the experiment. Although it was attempted to create a clinically realistic setup using a mannequin head in a clinical treatment unit and real bone for implant placement, several aspects differed from an in vivo setup. These include access to the surgical site depending on the patients’ mouth opening, movement of the patient, elevation of a muco-periosteal flap, fluids such as blood, saliva, and water reducing visual orientation. Many of these restrictions have been reported to be clinically relevant and problematic for implant placement (Block & Chandler, 2009; Cassetta et al., 2011; Hultin et al., 2012). Also, the study design included only the use of splints resting on a “dentition” and therefore being supported in the best way possible. It is likely that missing dentition to support the splints (missing posterior dentition or complete edentulism), mucosa-supported splints would result in higher degrees of deviation, as described in other publications (Arisan et al., 2010). Also, a near to ideal morphology of the bone crest was simulated for drilling and implant placement perpendicular to the bone surface and with a more than sufficient bone width. In clinical environment,

the amount of alveolar bone is often limited due to atrophy and the drilling as well as the implant placement are much more demanding. This fact, again, limits the interpretation of the results in relation to clinical application.

The orientation regarding implant position was facilitated by the use of posts mounted on the reference implants. In a clinical environment, such clear direction indicators are rarely found except for the placement of multiple implants. Usually, a prosthetic splint or the axis of adjacent teeth or crowns is used as direction reference structures. The setup in the study had to involve standardized models with clearly identifiable reference objects. Posts mimicking direction indicators were chosen, since the axis of a tooth or its crown is difficult to be determined in an objective and reproducible way. This may be a limitation of this study in transferring the results into a real clinical environment but on the other hand leads to a more precise measurement of implant positions.

Last but not least the stress level of the surgeon must be considered as influencing parameter on the implant positioning. The placement of implants in an in vitro environment occurs with significantly less tension and stress than an in vivo placement in patients. Reduced stress levels allow the clinician to focus on essential tasks and can improve the outcomes (Arora et al., 2010; Wetzel et al., 2010).

Despite the higher accuracy and precision of the CAIPP group when comparing the planned and final implant position, it remains uncertain, if this creates a benefit for the surgeon or patient regarding the outcome of the treatment. A recent study investigated the clinical outcome of the computer-assisted, template-guided approach in comparison to a free-hand implant placement based on two-dimensional radiographs and intrasurgical judgment of the surgeon (Sancho-Puchades et al., 2019; Schneider et al., 2018; Schneider, Sancho-Puchades, Mir-Mari, et al., 2019; Schneider, Sancho-Puchades, Schober, et al., 2019). The authors found no differences regarding prosthetic nor biological outcome between these two treatment protocols. In all cases of the free-hand group and in all but one case of the CAIPP group, a screw-retained supra-structure could be mounted on well-integrated implants without biological complications at the time of delivery and the subsequent follow-up appointment. Interestingly, they recorded a considerable percentage of intrasurgical deviations from the planned surgical protocol based on intrasurgical, clinical reevaluation of the actual clinical situation as compared to the perception during the planning in the software program based on cone-beam computer tomography data.

Another clinical study comparing free-hand with template-guided protocols found a significantly higher rate of complications in the free-hand group, especially regarding positioning errors (Arisan et al., 2013). An implant malposition was observed in 88% of the free-hand cases but also in 15%–29% of the guided cases and led to improper design of the emergence profile of the reconstructions, inadequate inter-implant distance, improper parallelism of implants, excessive subcrestal placement, implant shoulder exposure etc.

These findings underline the importance of a thorough radiographic and prothetic planning and imperative intrasurgical

verification and reevaluation of the surgical plan and implant position irrespective of the planning and surgical protocol. The use of CAIPP does not per se guarantee a proper implant position.

## 5 | CONCLUSION

In the present in vitro study, CAIPP protocols showed a smaller deviation of the implant position from the planned implant position compared with free-hand implant placement, irrespective of the size of the tooth gap. In the free-hand group, the size of the gap had an influence on the error of the angulation only, not on the lateral or vertical deviation. In both groups, the deviations were small compared with other studies. The clinical impact of the findings remains to be investigated by clinical studies.

## ACKNOWLEDGEMENTS

The present study was self-funded by the Clinic of Reconstructive Dentistry at the Center of Dental Medicine of the University of Zurich, Switzerland. Partial support including software and study material was provided by Dentsply Sirona Implants and Swissmeda.

## CONFLICT OF INTEREST

The investigators do not have any conflicts of interest.

## AUTHOR CONTRIBUTION

**David Schneider:** Conceptualization (equal); Formal analysis (equal); Investigation (equal); Methodology (equal); Writing-original draft (equal). **Caroline Sax:** Investigation (equal); Methodology (equal); Project administration (equal). **Manuel Sancho-Puchades:** Investigation (equal). **Christoph H.F. Hämmerle:** Supervision (equal). **Ronald Ernst Jung:** Supervision (equal); Writing-review & editing (equal).

## DATA AVAILABILITY STATEMENT

Data available on request from the authors.

## ORCID

David Schneider  <https://orcid.org/0000-0003-1622-073X>

Christoph H.F. Hämmerle  <https://orcid.org/0000-0002-8280-7347>

Ronald Ernst Jung  <https://orcid.org/0000-0003-2055-1320>

## REFERENCES

- Arisan, V., Karabuda, C. Z., Mumcu, E., & Ozdemir, T. (2013). Implant positioning errors in freehand and computer-aided placement methods: A single-blind clinical comparative study. *International Journal of Oral and Maxillofacial Implants*, 28, 190–204. <https://doi.org/10.11607/jomi.2691>
- Arisan, V., Karabuda, Z. C., & Ozdemir, T. (2010). Accuracy of two stereolithographic guide systems for computer-aided implant placement: A computed tomography-based clinical comparative study. *Journal of Periodontology*, 81, 43–51. <https://doi.org/10.1902/jop.2009.090348>
- Arora, S., Sevdalis, N., Nestel, D., Woloshynowych, M., Darzi, A., & Kneebone, R. (2010). The impact of stress on surgical performance: A systematic review of the literature. *Surgery*, 147(3), 318–330.e6. <https://doi.org/10.1016/j.surg.2009.10.007>



- Block, M. S., & Chandler, C. (2009). Computed tomography-guided surgery: Complications associated with scanning, processing, surgery, and prosthetics. *Journal of Oral and Maxillofacial Surgery*, *67*, 13–22. <https://doi.org/10.1016/j.joms.2009.04.082>
- Bover-Ramos, F., Vina-Almunia, J., Cervera-Ballester, J., Penarrocha-Diago, M., & Garcia-Mira, B. (2018). Accuracy of Implant placement with computer-guided surgery: A systematic review and meta-analysis comparing cadaver, clinical, and in vitro studies. *International Journal of Oral and Maxillofacial Implants*, *33*, 101–115. <https://doi.org/10.11607/jomi.5556>
- Cassetta, M., Stefanelli, L. V., Giansanti, M., Di Mambro, A., & Calasso, S. (2011). Depth deviation and occurrence of early surgical complications or unexpected events using a single stereolithographic surgical guide. *International Journal of Oral and Maxillofacial Surgery*, *40*, 1377–1387. <https://doi.org/10.1016/j.ijom.2011.09.009>
- Kalt, G., & Gehrke, P. (2008). Transfer precision of three-dimensional implant planning with CT assisted offline navigation. *Int J Comput Dent*, *11*(3–4), 213–225.
- Hjalmarsson, L., Gheisarifar, M., & Jemt, T. (2016). A systematic review of survival of single implants as presented in longitudinal studies with a follow-up of at least 10 years. *European Journal of Oral Implantology*, *9*(Suppl 1), S155–S162.
- Hultin, M., Svensson, K. G., & Trulsson, M. (2012). Clinical advantages of computer-guided implant placement: A systematic review. *Clinical Oral Implants Research*, *23*(Suppl 6), 124–135. <https://doi.org/10.1111/j.1600-0501.2012.02545.x>
- Jung, R. E., Pjetursson, B. E., Glauser, R., Zembic, A., Zwahlen, M., & Lang, N. P. (2008). A systematic review of the 5-year survival and complication rates of implant-supported single crowns. *Clinical Oral Implants Research*, *19*, 119–130. <https://doi.org/10.1111/j.1600-0501.2007.01453.x>
- Jung, R. E., Schneider, D., Ganeles, J., Wismeijer, D., Zwahlen, M., Hammerle, C. H., & Tahmaseb, A. (2009). Computer technology applications in surgical implant dentistry: A systematic review. *International Journal of Oral and Maxillofacial Implants*, *24*(Suppl), 92–109.
- Nickenig, H. J., Wichmann, M., Hamel, J., Schlegel, K. A., & Eitner, S. (2010). Evaluation of the difference in accuracy between implant placement by virtual planning data and surgical guide templates versus the conventional free-hand method - a combined in vivo - in vitro technique using cone-beam CT (Part II). *Journal of Cranio-Maxillo-Facial Surgery*, *38*, 488–493. <https://doi.org/10.1016/j.jcms.2009.10.023>
- Sancho-Puchades, M., Alfaro, F. H., Naenni, N., Jung, R., Hammerle, C., & Schneider, D. (2019). A randomized controlled clinical trial comparing conventional and computer-assisted implant planning and placement in partially edentulous patients. Part 2: Patient related outcome measures. *International Journal of Periodontics and Restorative Dentistry*, *39*, e99–e110. <https://doi.org/10.11607/prd.4145>
- Schneider, D., Marquardt, P., Zwahlen, M., & Jung, R. E. (2009). A systematic review on the accuracy and the clinical outcome of computer-guided template-based implant dentistry. *Clinical Oral Implants Research*, *20*(Suppl 4), 73–86. <https://doi.org/10.1111/j.1600-0501.2009.01788.x>
- Schneider, D., Sancho-Puchades, M., Benic, G. I., Hammerle, C. H., & Jung, R. E. (2018). A randomized controlled clinical trial comparing conventional and computer-assisted implant planning and placement in partially edentulous patients. Part 1: Clinician-related outcome measures. *International Journal of Periodontics and Restorative Dentistry*, *38*, s49–s57. <https://doi.org/10.11607/ds2018s>
- Schneider, D., Sancho-Puchades, M., Mir-Mari, J., Muhlemann, S., Jung, R., & Hammerle, C. (2019). A randomized controlled clinical trial comparing conventional and computer-assisted implant planning and placement in partially edentulous patients. Part 4: Accuracy of implant placement. *International Journal of Periodontics and Restorative Dentistry*, *39*, e111–e122. <https://doi.org/10.11607/prd.4147>
- Schneider, D., Sancho-Puchades, M., Schober, F., Thoma, D., Hammerle, C., & Jung, R. (2019). A randomized controlled clinical trial comparing conventional and computer-assisted implant planning and placement in partially edentulous patients. Part 3: Time and cost analyses. *International Journal of Periodontics and Restorative Dentistry*, *39*, e71–e82. <https://doi.org/10.11607/prd.4146>
- Schneider, D., Schober, F., Grohmann, P., Hammerle, C. H., & Jung, R. E. (2015). In-vitro evaluation of the tolerance of surgical instruments in templates for computer-assisted guided implantology produced by 3-D printing. *Clinical Oral Implants Research*, *26*, 320–325. <https://doi.org/10.1111/clr.12327>
- Skjerven, H., Riis, U. H., Herlofsson, B. B., & Ellingsen, J. E. (2019). In vivo accuracy of implant placement using a full digital planning modality and stereolithographic guides. *International Journal of Oral and Maxillofacial Implants*, *34*, 124–132. <https://doi.org/10.11607/jomi.6939>
- Valente, F., Schirolli, G., & Sbrenna, A. (2009). Accuracy of computer-aided oral implant surgery: A clinical and radiographic study. *International Journal of Oral and Maxillofacial Implants*, *24*, 234–242.
- Van Assche, N., & Quirynen, M. (2010). Tolerance within a surgical guide. *Clinical Oral Implants Research*, *21*, 455–458. <https://doi.org/10.1111/j.1600-0501.2009.01836.x>
- Van Assche, N., Vercruyssen, M., Coucke, W., Teughels, W., Jacobs, R., & Quirynen, M. (2012). Accuracy of computer-aided implant placement. *Clinical Oral Implants Research*, *23*(Suppl 6), 112–123. <https://doi.org/10.1111/j.1600-0501.2012.02552.x>
- Van de Wiele, G., Teughels, W., Vercruyssen, M., Coucke, W., Temmerman, A., & Quirynen, M. (2015). The accuracy of guided surgery via mucosa-supported stereolithographic surgical templates in the hands of surgeons with little experience. *Clinical Oral Implants Research*, *26*, 1489–1494. <https://doi.org/10.1111/clr.12494>
- Vercruyssen, M., Coucke, W., Naert, I., Jacobs, R., Teughels, W., & Quirynen, M. (2015). Depth and lateral deviations in guided implant surgery: An RCT comparing guided surgery with mental navigation or the use of a pilot-drill template. *Clinical Oral Implants Research*, *26*, 1315–1320. <https://doi.org/10.1111/clr.12460>
- Vermeulen, J. (2017). The accuracy of implant placement by experienced surgeons: Guided vs freehand approach in a simulated plastic model. *International Journal of Oral and Maxillofacial Implants*, *32*, 617–624. <https://doi.org/10.11607/jomi.5065>
- Wetzel, C. M., Black, S. A., Hanna, G. B., Athanasiou, T., Kneebone, R. L., Nestel, D., Wolfe, J. H., & Woloshynowych, M. (2010). The effects of stress and coping on surgical performance during simulations. *Annals of Surgery*, *251*, 171–176. <https://doi.org/10.1097/SLA.0b013e3181b3b2be>

**How to cite this article:** Schneider, D., Sax, C., Sancho-Puchades, M., Hämmerle, C. H. F., & Jung, R. E. (2021). Accuracy of computer-assisted, template-guided implant placement compared with conventional implant placement by hand—An in vitro study. *Clinical Oral Implants Research*, *32*, 1052–1060. <https://doi.org/10.1111/clr.13799>