

# Review

---

## LEBER CONGENITAL AMAUROSIS DUE TO *CEP290* MUTATIONS—SEVERE VISION IMPAIRMENT WITH A HIGH UNMET MEDICAL NEED

### A Review

BART P. LEROY, MD, PhD,\*†‡§ DAVID G. BIRCH, PhD,§¶ JACQUE L. DUNCAN, MD,\*\*  
 BYRON L. LAM, MD,†† ROBERT K. KOENENKOP, MD, PhD,‡‡ FERNANDA B. O. PORTO, MD,§§  
 STEPHEN R. RUSSELL, MD,¶¶ ANIZ GIRACH, MD\*\*\*

**Purpose:** Leber congenital amaurosis due to *CEP290* mutations (LCA10) is an inherited retinal disease that often results in severe visual impairment or blindness in early childhood. Currently, there are no approved treatments, highlighting the considerable unmet medical need associated with LCA10. We aimed to review the clinical characteristics of LCA10, its impact on patients and society, and the investigational treatment strategies currently in development.

**Methods:** Review of the current literature.

**Results:** LCA10 is an autosomal recessive ciliopathy, for which the *CEP290* intronic variant c.2991+1655A>G (p.Cys998X) is the most common mutation. Usually diagnosed in early childhood, most patients with LCA10 have severe visual impairment during their first decade of life, which significantly affects the quality of life and development. LCA10 also has a significant societal burden (direct and indirect costs). RNA editing using anti-sense oligonucleotides or *Staphylococcus aureus* CRISPR-associated protein-9 nuclease is currently under investigation for treatment of p.Cys998X LCA10. Specifically, the anti-sense oligonucleotide therapy QR-110 (sepofarsen) has demonstrated encouraging safety and efficacy data in a first-in-human trial; a phase 3 clinical trial is ongoing.

**Conclusion:** Interventions that can preserve or improve vision in patients with LCA10 have considerable potential to improve the patient quality of life and reduce burden of disease.

RETINA 41:898–907, 2021

Inherited retinal diseases (IRDs), a highly heterogeneous group of diseases, are caused by mutations in one of several hundred genes and are characterized by photoreceptor dysfunction, followed by retinal cell death.<sup>1</sup> Leber congenital amaurosis (LCA), first described by Theodore Leber in 1869,<sup>2</sup> is considered one of the most severe IRDs.<sup>3</sup> Leber congenital amaurosis represents more than 5% of all IRDs and is one of the most common IRDs.<sup>4</sup> Leber congenital amaurosis is a monogenic autosomal recessive disease<sup>5</sup>

affecting approximately 1 in 30,000 newborns,<sup>6</sup> with a population frequency of approximately 1 in 50,000 in Europe and North America.<sup>7</sup> The prevalence of LCA seems to be increasing in some reports, more than doubling in children in Denmark between 1988 and 2011.<sup>8</sup> The latter is probably an artifact of greater awareness and increased diagnosis. However, funding for IRD research and innovation has historically been limited, which has led to delays in diagnosis and clinical care for patients with IRD.<sup>9</sup>

## Observations

### Pathophysiology

To date, mutations in 25 genes have been identified, representing at least 80% of LCA cases.<sup>2</sup> Leber congenital amaurosis is mostly a nonsyndromic retinopathy although some causative mutations have systemic involvement.<sup>3</sup> Mutations in the gene encoding centrosomal protein 290 (*CEP290*) can cause LCA, RP and early-onset severe retinal dystrophy, and aberrant *CEP290* expression in other tissues is associated with Bardet–Biedl syndrome, Joubert syndrome, Meckel–Gruber syndrome, and Senior–Løken syndrome.<sup>2</sup> Biallelic loss-of-function mutations in *CEP290* cause the LCA-ciliopathy known as LCA10, which is the most frequent cause of LCA, responsible for up to 30% of cases.<sup>4,10–12</sup> *CEP290* is a large protein located in the ciliary transition zone of cone and rod photoreceptors that is essential for the formation and stability of primary cilia<sup>13</sup> and acts as a molecular gatekeeper, regulating ciliary protein traffic between the photoreceptor inner and outer segments (see **Figure S1, Supplemental Digital Content 1**, <http://links.lww.com/IAE/B413>).<sup>1,13</sup> As the maintenance of the outer segment of the photoreceptor relies on proteins and lipids trafficked from the inner segment, a reduction of functional

*CEP290* is believed to lead to retinal degeneration.<sup>1,13</sup> The intronic c.2991+1655A>G mutation is the most prevalent LCA-associated *CEP290* mutant allele,<sup>3,6,14</sup> reported in 20% to 57% of patients of European descent,<sup>5,6</sup> and up to 77% of one patient cohort in the United States.<sup>14</sup> This mutation creates a strong splice-donor site that competes with the normal splice-donor site resulting in the insertion of a cryptic exon (exon X) in *CEP290* messenger RNA (mRNA; p.Cys998X), leading to a premature stop codon and termination of protein synthesis in 50% of *CEP290* transcripts.<sup>3,7,15</sup> p.Cys998X LCA10 has a retinal-specific phenotype, as aberrant splicing is more pronounced in human photoreceptors than other cells.<sup>11</sup> Other LCA-associated *CEP290* mutations include c.4723A>T, which shows a frequency of 4% to 11% in patients of European descent, and studies have reported c.4393C>T, c.4661\_4663delAAG, c.3310-1\_3310delinsAA, and c.5777G>C mutant alleles at frequencies of 13%, 8%, 6%, and 5%, respectively.<sup>6,12</sup>

### Clinical Presentation

The phenotype of LCA is relatively heterogeneous.<sup>2</sup> Leber congenital amaurosis is usually diagnosed in early childhood in patients presenting with congenital

From the \*Department of Ophthalmology, Ghent University and Ghent University Hospital, Ghent, Belgium; †Center for Medical Genetics, Ghent University and Ghent University Hospital, Ghent, Belgium; ‡Division of Ophthalmology, The Children's Hospital of Philadelphia, Philadelphia, Pennsylvania; §Center for Cellular and Molecular Therapeutics, The Children's Hospital of Philadelphia, Philadelphia, Pennsylvania; ¶Retina Foundation of the Southwest, Dallas, Texas; \*\*Department of Ophthalmology, University of California, San Francisco, San Francisco, California; ††Bascom Palmer Eye Institute, University of Miami Miller School of Medicine, Miami, Florida; ‡‡Departments of Paediatric Surgery, Human Genetics, and Adult Ophthalmology, McGill University Health Center, Montreal, Quebec, Canada; §§INRET Clínica e Centro de Pesquisa, Belo Horizonte, Brazil; ¶¶The University of Iowa Institute for Vision Research, University of Iowa, Iowa City, Iowa; and \*\*\*ProQR Therapeutics, Leiden, the Netherlands.

Editorial support was provided by Rebecca Lawson from Fishawack Health and Agathe Plichta from ProQR Therapeutics, funded by ProQR Therapeutics. B. P. Leroy is a senior clinical investigator of the Research Foundation—Flanders, Belgium (grant no.: 1803821N).

Financial support for the *CEP290* and other IRD work is as follows. B. P. Leroy reports trial support from Second Sight Medical Products, consultancy fees from Bayer, Biogen, REGENXBIO, and Vedere Bio, and trial support and/or consultancy fees and travel support from GenSight Therapeutics, IVERIC Bio, Novartis Pharma, Spark Therapeutics, and ProQR Therapeutics. He reports no personal financial gain, with all consultancy fees paid into Ghent University Hospital research accounts to support research. D. G. Birch reports support from the National Eye Institute EY09076 and Foundation Fighting Blindness. He has served as a consultant for ProQR, AGTC, Nacuity, Editas, and Biogen and has received clinical trial support from AGTC, ProQR Therapeutics, NightstaRx, and 4D Therapeutics. J. L. Duncan is a consultant for 4D Therapeutics, AGTC, Biogen/NightstaRx Therapeutics, California Institute for Regenerative Medicine, Editas Medicine, Eloxx, Foundation Fighting Blindness, ProQR Therapeutics, SparingVision, Spark Therapeutics, and Vedere Bio. She has received material support for research from Neurotech USA, Inc, and clinical trial support from Allergan, Acucela, Second Sight Medical Products, Inc, and Biogen/NightstaRx Therapeutics; she receives grant support from the Foundation Fighting Blindness, Research to Prevent Blindness, the National Eye Institute, and the Food and Drug Administration Office of Orphan Product Development. B. L. Lam reports grant funding from ProQR Therapeutics, Biogen, AGTC, Allergan, and Spark Therapeutics. He has served as a consultant for ProQR, Biogen, and Allergan. R. K. Koenekoop is receiving support from the Fighting Blindness Canada Foundation (FBC), the Canadian Institutes for Health Research (CIHR), Réseau du Québec, The Montreal Children's Hospital Foundation (MCHF), and NIH (NEI IRO1 EY 030499-01). He is a consultant for ProQR Therapeutics, Biogen, Novartis Canada, and Santen. He was on the Data Monitoring Committee for sepfarsen and continues to work as a PI. F. B. O. Porto has received clinical trial support from ProQR, Acucela, and Apellis. S. R. Russell reports grant funding from Spark Therapeutics and ProQR Therapeutics and is a consultant for Novartis and cofounded an artificial intelligence-based retinal imaging company, IDx Technologies. A. Girach is an employee of ProQR.

Supplemental digital content is available for this article. Direct URL citations appear in the printed text and are provided in the HTML and PDF versions of this article on the journal's Web site ([www.retinajournal.com](http://www.retinajournal.com)).

This is an open-access article distributed under the terms of the Creative Commons Attribution-Non Commercial-No Derivatives License 4.0 (CCBY-NC-ND), where it is permissible to download and share the work provided it is properly cited. The work cannot be changed in any way or used commercially without permission from the journal.

Reprint requests: Bart P. Leroy, MD, PhD, Department of Ophthalmology, Ghent University Hospital, Corneel Heymanslaan 10, 9000 Ghent, Belgium; e-mail: [bart.leroy@ugent.be](mailto:bart.leroy@ugent.be)

nystagmus, sluggish pupillary light reflex, the oculodigital sign (eye poking), and an inability to follow light or objects.<sup>3,4</sup> Initially, the retina may appear relatively normal.<sup>3,4,15</sup> From the second year of life, two clinical forms of LCA can be recognized—a severe, fairly stationary cone-rod dystrophy, and a progressive rod-cone dystrophy.<sup>3</sup> Patients with LCA10 typically have the severe cone-rod form of LCA, characterized by severe photophobia, high hyperopia, and visual acuity reduced to hand movements or perception of light.<sup>3</sup>

In patients with LCA10, rod photoreceptors develop but then rapidly degenerate postnatally, with some patients retaining midperipheral rods in their first decade of life, but most patients having central cones but no rods by their second decade.<sup>1</sup> An evolution in the retinal phenotype from normal to pigmentary retinopathy was suggested in a retrospective case series of 40 patients with LCA10 (23 with p.Cys998X LCA10), indicating progressive peripheral photoreceptor cell death.<sup>6</sup> Patients generally present with a normal fundus at diagnosis (mean age of 1.9 years),<sup>6</sup> with white flecks or a marbleized fundus aspect appearing in the first to second decade (mean age of 5.9 years) (Figures 1 and 2 and see **Supplemental Digital Content 2**, <http://links.lww.com/IAE/B417>),<sup>6,12</sup> followed by pigmentary retinopathy (mean age of 19.7 years).<sup>6</sup>

Many patients with LCA10 report a very low level of vision from as early as they can remember, implying either a congenital, or at least very early-onset loss of vision.<sup>1</sup> Severe vision loss, defined as the visual acuity of counting fingers or worse in the better-seeing eye, has been reported in 62% to 89% of patients with LCA10.<sup>1</sup> A retrospective analysis showed that patients with LCA10 (N = 43) had a wide spectrum of the visual acuity that was unrelated to age or length of follow-up, but severe visual acuity loss was observed in most patients in their first decade of life, with no significant further loss over ~10 years' follow-up (range 2–47 years).<sup>14</sup> A similar wide spectrum of the visual acuity has been shown in another cohort of patients with LCA10,<sup>6</sup> and specifically in patients with p.Cys998X LCA10.<sup>16</sup> LCA10 is associated with relatively preserved foveal architecture,<sup>4</sup> suggesting vision loss in LCA10 is disproportionate to the remaining foveal outer nuclear layer.<sup>15</sup> In a retrospective case series, relatively preserved foveal architecture was found in 11/12 patients with LCA10 with available optical coherence tomography data.<sup>6</sup> In another study in patients with p.Cys998X LCA10, there was no significant change in foveal outer nuclear layer thickness over a 10-year period; however, the nasal and temporal optical coherence tomography scans indicated loss of the outer nuclear layer with macular preservation that constricted slowly over time.<sup>15</sup> Indeed, 11/12 European patients

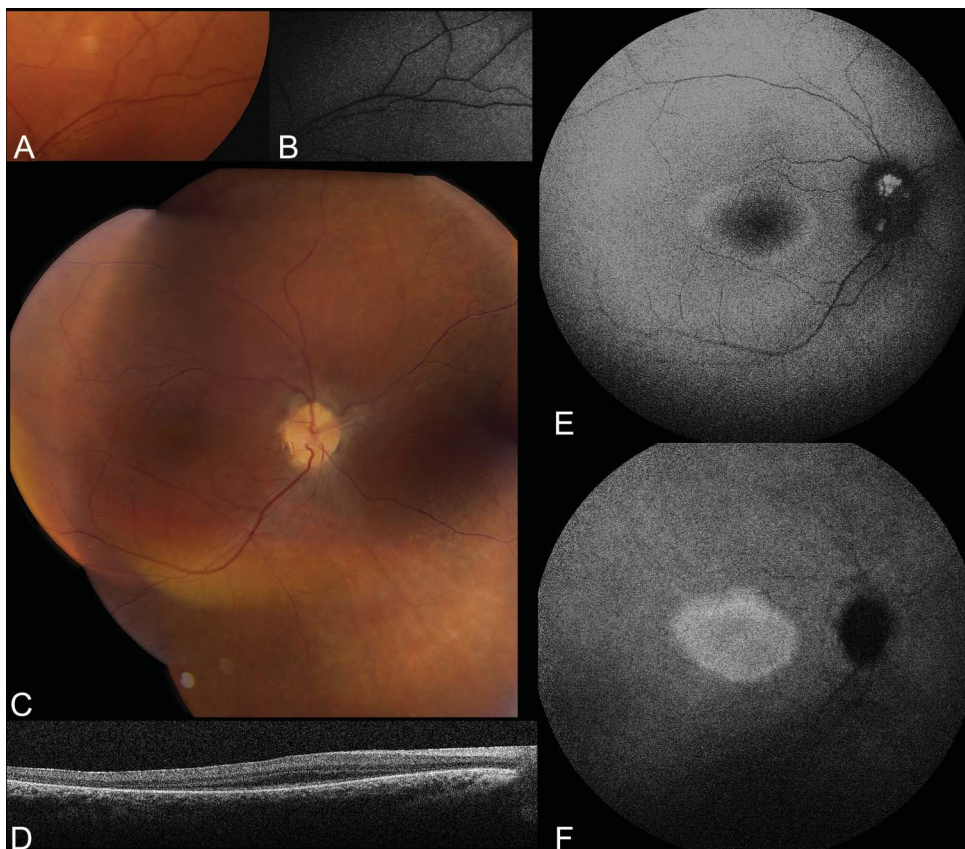
with p.Cys998X LCA10 retained foveal outer nuclear layer and ellipsoid zone integrity until a median age of 23 years (range 5–48).<sup>16</sup> The exact mechanisms by which central visual function is often very low or even absent in LCA10 patients, despite the relatively preserved retinal architecture in the fovea is unknown. *CEP290* apparently does not play an essential role in development of the photoreceptors, albeit that it seems crucial for proper functioning and maintenance.<sup>1</sup> However, this represents an opportunity for treatment.

### Assessment and Diagnosis

An early diagnosis of LCA10 is critical to allow better-informed advice regarding prognosis.<sup>6</sup>

Indeed, guidelines are available for the assessment of patients with IRDs.<sup>17</sup> Careful examination and detailed investigations, including full-field flash electroretinography, optical coherence tomography, fundus autofluorescence imaging and other means, should facilitate an accurate diagnosis of LCA, which generally affects otherwise normal infants.<sup>6,10</sup> However, the differential diagnosis for severe visual impairment and nystagmus is broad, and includes complete and incomplete achromatopsia, S-cone monochromatism, complete and incomplete congenital stationary night blindness, and albinism.<sup>10</sup> Leber congenital amaurosis should also be distinguished from several syndromic conditions that show comparable ocular phenotypes in early infancy, including Joubert syndrome and Senior-Løken syndrome.<sup>10</sup> Patients with LCA have either severely reduced or extinct retinal responses on electroretinogram.<sup>3</sup> Molecular testing can provide a more specific diagnosis<sup>10</sup>; thus, genetic testing and counseling can be offered effectively to patients and their families.<sup>5</sup> Multigene panel testing, including for *CEP290* mutations, has been shown to provide a molecular diagnosis in 84.7% of children with IRD when correlated with detailed ophthalmic examination, electrodiagnostic testing, and dysmorphic assessment.<sup>18</sup> A molecular diagnosis also enables tailored dietary decisions; for example, a high intake of vitamin A is a risk factor for progression of Stargardt's, whereas vitamin A supplementation may be protective for RP progression. In addition, obtaining a molecular diagnosis informs suitability for clinical trial participation.<sup>9</sup> However, genetic testing rates remain relatively low (approximately 62% of patients with an IRD in the United Kingdom have received a genetic test),<sup>19</sup> and there is a lack of specialist training programs on IRDs for medical professionals.<sup>9</sup>



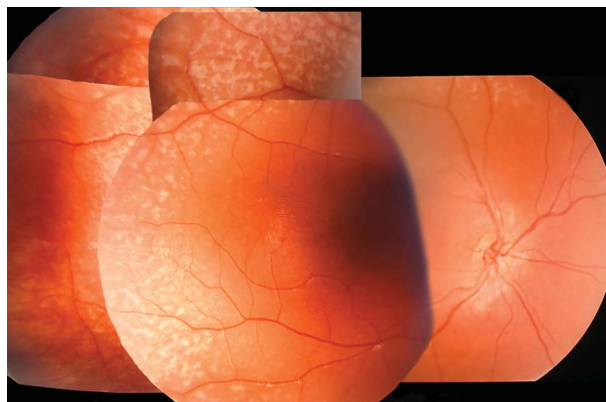


**Fig. 1.** Fundus, blue-light and near-infrared light autofluorescence, and optical coherence tomography images of male patient homozygous for the c.2991+1665A>C mutation in *CEP290*. **A.** Image of detail of superior midperiphery of the left eye illustrating a mild marbled aspect of the retina, taken at age 14 years when the best-corrected visual acuity (BCVA) was counting fingers in both eyes. **(B)** Blue-light autofluorescence image of the same area at same visit illustrating irregular hyperautofluorescence of marbled lesions. **(C–F)** Fundus, spectral-domain optical coherence tomography, blue-light autofluorescence, and near-infrared light autofluorescence images of the right eye of the same patient at age 24. Blue-light autofluorescence shows hyperautofluorescent ring around the central macula and optic disc, whereas near-infrared light autofluorescence shows more homogenous hyperautofluorescence of the central macula, coincident with area of preserved foveal ellipsoid zone and retinal pigment epithelium on foveal OCT. The best-corrected visual acuity at that time

was light perception in both eyes. OCT, optical coherence tomography.

### The Burden of Early Vision Loss Associated With LCA10

Visual impairment has a significant effect on the quality of life (QoL) of children; the total QoL (Low Vision Quality of Life Questionnaire) was 36% lower in



**Fig. 2.** Composite fundus image of the right eye of a *CEP290*-related LCA patient at Age 3; the patient is compound heterozygous for two *CEP290* mutations. Note white, polymorphous flecks with jagged borders in the retinal midperiphery; flecks absent in a cuff-like area around the retinal arterioles, as opposed to flecks present in immediate proximity of venules; normal macula. LCA, Leber congenital amaurosis.

children 3 to 16 years of age with visual impairment than for age-matched children with no known visual disability.<sup>20</sup> In children  $\leq 16$  years of age with childhood-onset IRD, the severity of visual impairment is negatively correlated with health-related QoL and results in a greater impact on the family and family functioning.<sup>21</sup> Despite the lifelong implications of visual impairment associated with IRDs on all aspects of children's lives and for their families, to the best of our knowledge, only a single study reports the effects of an IRD, specifically LCA2 (*RPE65*), on the QoL of children.<sup>22</sup> Retina specialists with expertise in IRDs scored clinical vignettes depicting different levels of vision loss in patients with LCA2, from moderate loss to no light perception, using the 5-level EQ-5D (EQ-5D-5L; a measure of health based on self-assessment of mobility, self-care, usual activities, pain or discomfort, and anxiety or depression),<sup>22,23</sup> and the Health Utility Index 3 (HUI3; a measure of health based on hearing, vision, speech, ambulation, dexterity, emotion, cognition, and pain).<sup>22,24</sup> Progressive vision loss had a substantial effect on the QoL, with identical declines in both instruments.<sup>22</sup> These data are supported by outputs from a cross-sectional community survey of the parents of children 3 to 8 years of age with visual impairment or blindness, in whom their ophthalmic

condition significantly affected their QoL.<sup>25</sup> These children also had high levels of functional limitation for vision, cognition, ambulation, and dexterity according to HUI3.<sup>25</sup> Indeed, visual impairment has complex and far-reaching effects on early development. For example, in a recent systematic review, the overall prevalence of autism spectrum disorder in children with visual impairment was 19% (relative risk: 31.0).<sup>26</sup> The early involvement of a pediatrician experienced in the developmental needs of children with visual impairment can mitigate or delay the impact of visual impairment on other areas of development.<sup>10</sup>

Early vision impairment also has significant psychological impact on both the child and their caregivers,<sup>21,27</sup> with 75% of parents of visually impaired children reporting moderate, severe, or very severe anxiety.<sup>28</sup> Psychological effects continue into teenage and adult years, whereby patients report psychological complications and limitations in daily activities and opportunities.<sup>22,29,30</sup> In an observational descriptive cross-sectional study of visually impaired students 10 to 22 years of age, students frequently reported depression (55%), suicidal thoughts (40%), and worthlessness (42.5%).<sup>30</sup> These results are mirrored in adulthood, during which patients with IRD often experience anxiety and depression about disease progression and worry about coping alone. Indeed, these patients report strains on personal relationships and frustrations surrounding an inability to pursue careers of their choice, and reliance on friends and family members for transport.<sup>29</sup> Unsurprisingly, most patients living with an IRD (73.2%) and parents of children living with an IRD (75%) are frustrated by the lack of awareness and support for IRDs.<sup>19</sup>

There are no studies reporting the medicoeconomic burden of LCA10, specifically. The total costs attributable to IRDs in the United Kingdom were estimated at £523.3 million in 2019, encompassing £327.2 million in economic costs and £196.1 million in well-being costs (including costs for anxiety, depression, social isolation, and financial stress).<sup>9,19</sup> Furthermore, the indirect costs of LCA2-associated visual impairment in the United States over a patient's lifetime were estimated at \$1,915,590 (95% confidence interval \$1,431,142–\$2,490,304).<sup>31</sup> These indirect costs of visual impairment comprised \$43,073 in education, \$68,255 in government programs, \$407,562 in productivity loss, \$70,978 in tax loss, and \$1,325,722 in informal caregiver costs. Yearly indirect costs were 3-fold higher for children than for adults (US\$43,593 vs. \$13,770), with the caregiver costs comprising 74% of the yearly cost for children compared with 66% for adults.<sup>31</sup> Given

that LCA10 is associated with more profound visual impairment at an earlier age than LCA2,<sup>6</sup> one would expect the indirect costs for children with LCA10 to be even higher, at least in terms of education and informal caregiver costs.

## Treatment

### *Leber Congenital Amaurosis*

Since their discovery (i.e., by Donders in 1857 [RP]<sup>32</sup> and Leber in 1869 [LCA]<sup>2</sup>), IRDs have been considered incurable.<sup>7</sup> However, recent data regarding molecular and retinal biology, animal models, human phenotyping, and therapeutic tools have led to the proof of concept for a gene-based treatment.<sup>1</sup> The adeno-associated virus (AAV) therapy voretigene neparvovec (Luxturna; Spark Therapeutics, Philadelphia, PA & Novartis, Basel, Switzerland) was approved for the treatment of patients with LCA2, in the United States in 2017<sup>33</sup> and in Europe in 2019.<sup>34</sup> The wealth of data that led to the development and approval of voretigene neparvovec for LCA2 also prompted the development of other genetic therapies for LCA (Table 1).

### *LCA10*

LCA10 occurs at a much higher frequency than LCA2.<sup>10</sup> However, LCA10 is associated with profound visual impairment at an earlier age than LCA2 and is recognized as a more severe subtype.<sup>6</sup> Therefore, LCA10 may be more difficult to treat than LCA2, as the potential therapeutic window for restoring function is likely more limited.<sup>6</sup> The onset of severe visual impairment at an early age is also an added complication in clinical trial design in terms of selecting suitable patients and outcome measures,<sup>6</sup> as children, especially visually impaired children, may have difficulty performing the tests chosen as endpoints.<sup>35</sup> Furthermore, the large size of full-length *CEP290* cDNA (coding region ~7.5 kb; which is much larger than *RPE65* cDNA) precludes the use of a conventional AAV vector for delivery of genetic material, requiring alternative approaches.<sup>7</sup>

Currently, there are no treatments approved for patients with LCA10. Despite the potential challenges associated with treating LCA10 noted above, the severity of visual impairment combined with the potential for improvement based on a structure–function dissociation (i.e., preserved foveal photoreceptors despite severe vision loss), make LCA10 an attractive target for therapy.<sup>1</sup> The intronic c.2991+1655A>G mutation in LCA10 is an ideal target for genetic therapies, as preventing the insertion

Table 1. Clinical Trials Investigating Gene Therapy for LCA Where the Drug is Still Currently in Development\*

	Drug/Vector Name-Target Gene (Target Gene)	Sponsor	Phase	Clinicaltrials.gov Identifier	Target n	Start Date End†/ Completion Date‡	Status (May 2020)	
Leber congenital amaurosis	LCA1	SAR439483	Sanofi	1/2	NCT03920007	15	September 2019	Active (not recruiting)
	LCA2	AAV <sub>2/5</sub> -OPTIRPE65	MeiraGTx UK II Ltd.	1/2	NCT02781480	15	February 2021/ February 2022	Completed
		rAAVR-CB-hRPE65	Applied Genetic Technologies Corp.	1/2	NCT00749957	12	December 2018 June 2009	Completed§
LCA10	AGN-151587/ EDIT-1010 (CEP290)	Allergan & Editas Medicine Inc.	1/2	NCT03872479	18	September 2019	Recruiting	
	QR-110 (CEP290)	ProQR Therapeutics	1/2	NCT03140969	12	March 2024 October 2017	Completed	
		ProQR Therapeutics	1/2	NCT03913130	11	December 2019 May 2019	Active (not recruiting) (long term follow-up of above studies)	
		ProQR Therapeutics	2/3	NCT03913143	30	March 2021 April 2019	Recruiting	
						December 2020/ December 2021		

\*Excluding ongoing studies in indications for which the therapy is licensed, that is, voretigene neparovec for LCA2.

†Estimated primary completion date.

‡If different from estimated end/primary completion date.

§Weleber RG, Pennesi ME, Wilson DJ, et al. Results at 2 years after gene therapy for RPE65-deficient Leber congenital amaurosis and severe early-childhood-onset retinal dystrophy. *Ophthalmology*. 2016;123(7):1606–1620.

of exon X in *CEP290* mRNA would fully restore normal *CEP290* splicing and wild-type *CEP290* levels. RNA editing, using antisense oligonucleotides (AONs) or *Staphylococcus aureus* CRISPR-associated protein-9 nuclease (Cas9), is under investigation in p.Cys998X LCA10 (Table 1).

RNA editing by AONs has several advantages. The intervention occurs at the pre-mRNA level and, therefore, does not interfere with endogenous expression of the target gene, which may exert irreversible toxic effects.<sup>36</sup> Because of their relatively small size, AONs can easily be delivered as naked molecules or as AAV-packaged AONs.<sup>37</sup> Indeed, naked AONs can

be delivered by a simple intravitreal injection into the eye as an in-office procedure<sup>38</sup> and have the ability to target the entire retina,<sup>39</sup> which allows for treatment in early degenerative diseases, potentially halting their progression at a much earlier stage. However, there is a need for frequent (currently 6-monthly) dosing to achieve adequate efficacy,<sup>40</sup> with recent data showing a common adverse event of cataract formation.<sup>41</sup> Some studies suggest that intravitreal injection is associated with a low rate of intraocular inflammation (around 2%).<sup>42,43</sup>

By contrast, RNA editing using Cas9 uses a simple design to induce robust genome editing. The Cas9



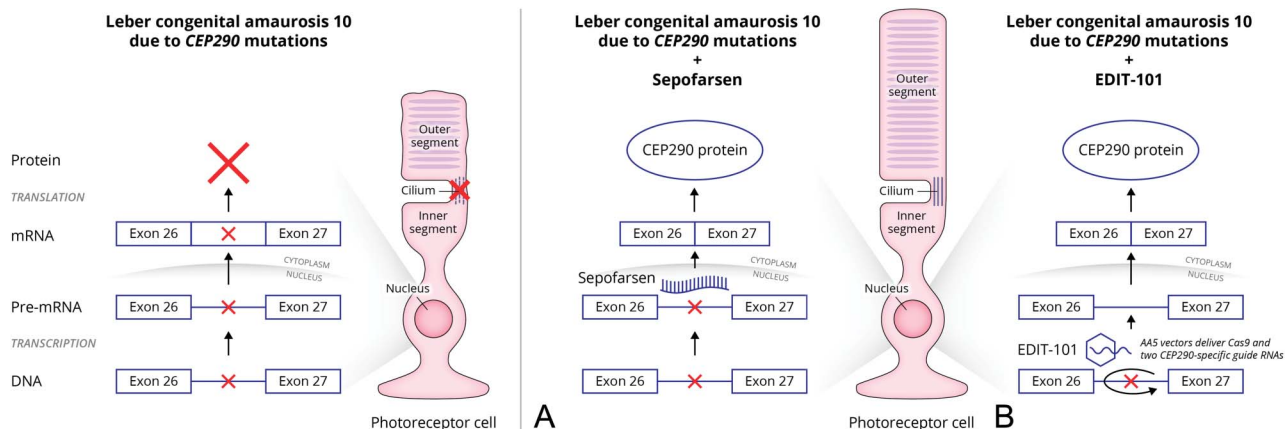
system can be used to both induce double-strand breaks at specific genomic loci to edit out mutation gain-of-function alleles or induce precise correction of mutations using donor DNA templates.<sup>44</sup> Cas9-based therapies are limited by a relatively low efficacy of genome correction because photoreceptors are generally postmitotic, therefore largely lack homology-directed repair mechanisms.<sup>37</sup> In postmitotic cells, AAV-mediated Cas9 expression may persist for a long time, thereby increasing the risk of off-target effects.<sup>44</sup> In addition, exogenous Cas9 protein may induce host immune responses.<sup>45</sup> Typically, gene editing technologies are delivered through an invasive subretinal injection, requiring general anesthesia.<sup>46,47</sup> In addition, only a small part of the retina can be effectively transduced,<sup>46</sup> and therefore, it is usually reserved for end-stage disease, or centrally focused diseases, in the hope of preserving the central macular area.<sup>48,49</sup> Because gene editing technology is new, only one case has been treated at the time of writing this article,<sup>50</sup> and therefore very little is known about the side effect profile, other than the potential complications of subretinal surgery, including cataract formation because of vitrectomy.<sup>26</sup> In addition, adverse events of subretinal injection include ocular inflammation (around 8%),<sup>33,51</sup>

In fibroblast cells from patients with homozygous p.Cys998X LCA10, naked AONs, and AAV-packaged AONs (using *CEP290* minigene constructs containing ~6.4 kb of human *CEP290*) both fully restored pre-mRNA *CEP290* splicing, significantly increased *CEP290* protein levels and rescued a ciliary phenotype.<sup>7</sup> In a transgenic, humanized mouse model of homozygous p.Cys998X LCA10, intraocular injection of naked, and AAV-packaged AONs significantly reduced exon X-containing transcripts without compromising the retinal structure, effects that persisted for at least 30 days after injection.<sup>7</sup> Correction of a single allele in cell lines from patients with compound heterozygous p.Cys998X LCA10 also minimized the effects of pathology, but the severity of the second variant or presence of other variants in the ciliary process should be considered.<sup>52</sup>

These results led to the development of a clinical drug candidate, seprofarsen (QR-110, ProQR Therapeutics), a single-stranded, 17-mer 2'-O-methyl-modified phosphorothioate RNA AON<sup>13</sup> (Figure 3A). Sepofarsen modulates RNA splicing, blocking access to the active cryptic splicing site, and restoring preference for the wild-type splicing site.<sup>53</sup> Consequently, seprofarsen restored wild-type *CEP290* mRNA and *CEP290* protein expression in c.2991+1655A>G homozygous and compound heterozygous fibroblasts and homozygous retinal organoids, and increased cilogenesis in the latter.<sup>13</sup> An open-label, multiple-dose,

dose escalation phase 1b/2 study was initiated to assess the safety and tolerability of seprofarsen administered by intravitreal injection to patients ≥6 years of age with homozygous or compound heterozygous p.Cys998X LCA10 (NCT03140969). Inclusion criteria included the best-corrected visual acuity (BCVA) equal to or better than light perception in both eyes, and equal to or worse than +0.6 logMAR in the worse eye and equal to or worse than +0.4 logMAR in the contralateral eye. Patients received unilateral intravitreal injection of seprofarsen to the worse eye up to every 3 months. Results after 12 months' treatment are available.<sup>41,53</sup> Sepofarsen was well tolerated with manageable safety findings.<sup>41</sup>

Patients (N = 11) who received up to four doses of seprofarsen (2 dose groups with loading/maintenance doses of 160 μg/80 μg or 320 μg/160 μg every 6 months) had a clinically meaningful improvement in the BCVA for treated eyes from baseline to Month 12 compared with contralateral eyes, that was sustained through Month 12 for all patients (mean, -0.55 logMAR at Month 12 vs. -0.12 logMAR at baseline,  $P < 0.05$ ) (Figure 4).<sup>41</sup> Improvement in full-field sensitivity threshold testing with red (mean, -0.91 log cd/m<sup>2</sup> at Month 12 vs. -0.16 log cd/m<sup>2</sup> at baseline,  $P < 0.01$ ) and blue (mean, -0.79 log cd/m<sup>2</sup> at Week 12 vs. 0.02 log cd/m<sup>2</sup> at baseline,  $P < 0.02$ ) stimuli was also observed for all patients in both dose groups (Figure 4). In addition, there was improvement in composite mobility course score for both treated eyes (+4.0 levels) and contralateral eyes (+2.7 levels) at Month 12 versus baseline.<sup>41</sup> Cataracts, the cause of which is unknown, but which may be due to an accumulation of the AON either on the lens surface or in the lens itself, were observed in eight patients. Three of the 6 patients (50%) were in the 160 μg/80 μg group and the rest in the 320 μg/160 μg group, with the cataracts leading to a worsening in the mean BCVA around Month 9.<sup>41</sup> All six patients who required lens replacement surgery (two did not) had their vision restored to the same level as before the cataract.<sup>41</sup> Cataracts and lens opacities are frequently reported with other licensed intravitreal products. For example, cataracts are reported in 68% of patients receiving dexamethasone intravitreal implants<sup>54</sup> and 82% of patients receiving fluocinolone acetonide intravitreal implants.<sup>55</sup> In the 320 μg/160 μg group, there were 2 cases of mild cystoid macular edema and 2 cases of subclinical retinal thinning that resolved after treatment or stabilized without treatment,<sup>41</sup> both of these side effects sometimes being associated with improved visual function. However, no adverse events lead to patient withdrawal, and there were no additional safety events of interest.<sup>41</sup> Long-term data are expected at the beginning of 2021 from



**Fig. 3.** Mechanism of action of two genetic therapies. **A.** Splice correction of p.Cys998X *CEP290* mRNA in patients with p.Cys998X LCA10 using QR-110 (seprofarsen). In p.Cys998X LCA10 cells, protein transport is hampered and the outer segment degenerates. Exclusion of the cryptic exon from the mutated mRNA leads to wild-type CEP290 protein expression.<sup>13</sup> **B.** Correction of intronic c.2991+1655A>G mutation in patients with p.Cys998X LCA10 with EDIT-101. AAV5 vectors deliver Cas9 and two CEP290-specific guide RNAs, which remove the intronic c.2991+1655A>G mutation.<sup>11</sup>

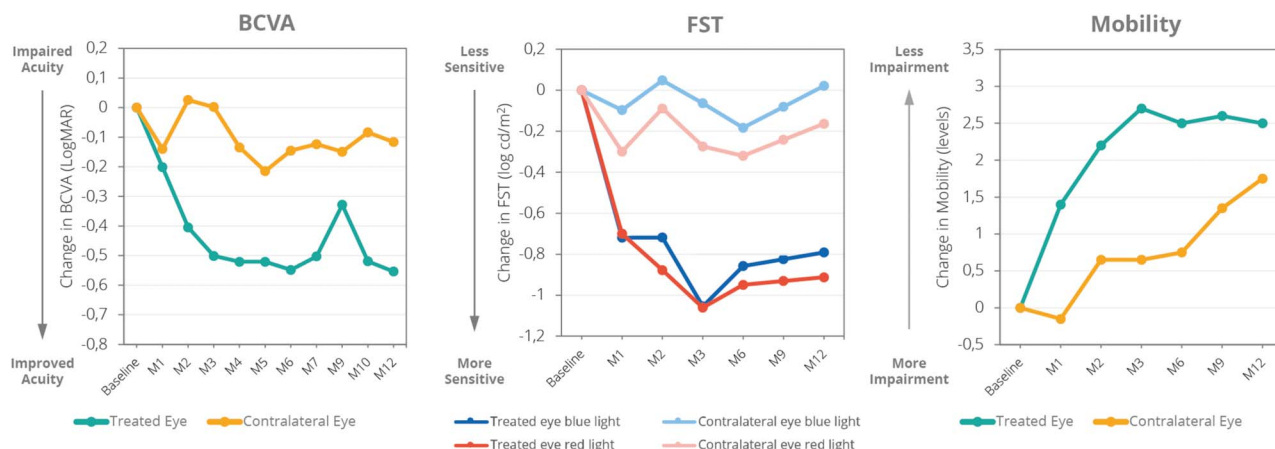
the INSIGHT study (NCT03913130), an extension study enrolling eligible patients who participated in the phase 1/2 study.<sup>56</sup> The 160 μg/80 μg regimen is under further investigation in a phase 2/3 trial (ILLUMINATE, NCT03913143); a 24-month, phase 2/3 double-blind, randomized, sham-controlled, multiple-dose trial of seprofarsen in patients ≥8 years of age, for which topline data are expected in 2021.<sup>57</sup>

AGN-151587/EDIT-101 (Allergan & Editas Medicine, Inc.) is another gene-based strategy designed to overcome the restricted cargo size of AAVs (Figure 3B).<sup>11</sup> It uses an AAV5 vector to deliver Cas9 and two *CEP290*-specific guide RNAs to photoreceptor cells through subretinal injection, with the aim of removing the intronic c.2991+1655A>G mutation.<sup>11</sup> AGN-151587 corrected *CEP290* splicing defects and expression of CEP290 in patient fibroblasts, demon-

strated rapid, sustained gene editing in a human *CEP290* c.2991+1655A>G mutation knock-in mouse model and showed gene editing in primate photoreceptors.<sup>11</sup> A first-in-human, phase 1/2 study was initiated investigating subretinal injection of AGN-151587 in patients ≥3 years of age with homozygous or compound heterozygous p.Cys998X LCA10 (NCT03872479), with results anticipated in 2024.<sup>58</sup>

**Conclusions**

Currently, there are no treatments approved for patients with LCA10. There is a high unmet medical need in LCA10, and particularly p.Cys998X LCA10, because of its population frequency, severity, and onset at an early age. Two genetic therapies are



**Fig. 4.** Change in BCVA, FST, and mobility in patients with LCA10 because of at least one p.Cys998X mutation in a clinical proof-of-concept trial of seprofarsen (N = 11).<sup>41</sup> \*Visual acuity and FST peaks are associated with cataract occurrence. These subjects regained their precataract visual acuity after surgery. BCVA, best-corrected visual acuity; FST, full-field sensitivity threshold; M, month. Data are the mean of all patients who received each respective treatment.



currently being investigated in clinical trials in patients with p.Cys998X LCA10, the results of which are eagerly awaited (see **Figures 1–3, Supplemental Digital Contents 1–3**, <http://links.lww.com/IAE/B413>, <http://links.lww.com/IAE/B414>, <http://links.lww.com/IAE/B415>, and <http://links.lww.com/IAE/B416>).

**Key words:** c2991+1655A>G, CEP290, childhood blindness, ciliopathy, cone-rod dystrophy, inherited retinal disease, LCA10, Leber congenital amaurosis.

### Acknowledgments

The authors thank all the patients and families who participated in the first-in-human and subsequent clinical trials, without whom this work would not be possible.

### References

- Cideciyan AV, Jacobson SG. Leber congenital amaurosis (LCA): potential for improvement of vision. *Invest Ophthalmol Vis Sci* 2019;60:1680–1695.
- Feldhaus B, Weisschuh N, Nasser F, et al. CEP290 mutation spectrum and delineation of the associated phenotype in a large German cohort: a monocentric study. *Am J Ophthalmol* 2020; 211:142–150.
- Perrault I, Delphin N, Hanein S, et al. Spectrum of NPHP6/ CEP290 mutations in Leber congenital amaurosis and delineation of the associated phenotype. *Hum Mutat* 2007;28:416.
- Coussa RG, Lopez Solache I, Koenekoop RK. Leber congenital amaurosis, from darkness to light: an ode to Irene Maumenee. *Ophthalmic Genet* 2017;38:7–15.
- den Hollander AI. Omics in ophthalmology: advances in genomics and precision medicine for Leber congenital amaurosis and age-related macular degeneration. *Invest Ophthalmol Vis Sci* 2016;57:1378–1387.
- Sheck L, Davies WIL, Moradi P, et al. Leber congenital amaurosis associated with mutations in CEP290, clinical phenotype, and natural history in preparation for trials of novel therapies. *Ophthalmology* 2018;125:894–903.
- Garanto A, Chung DC, Duijkers L, et al. In vitro and in vivo rescue of aberrant splicing in CEP290-associated LCA by antisense oligonucleotide delivery. *Hum Mol Genet* 2016;25: 2552–2563.
- Bertelsen M, Jensen H, Larsen M, et al. Prevalence and diagnostic spectrum of generalized retinal dystrophy in Danish children. *Ophthalmic Epidemiol* 2013;20:164–169.
- Galvin O, Chi G, Brady L, et al. The impact of inherited retinal diseases in the Republic of Ireland (ROI) and the United Kingdom (UK) from a cost-of-illness perspective. *Clin Ophthalmol* 2020;14:707–719.
- Kumaran N, Moore AT, Weleber RG, Michaelides M. Leber congenital amaurosis/early-onset severe retinal dystrophy: clinical features, molecular genetics and therapeutic interventions. *Br J Ophthalmol* 2017;101:1147–1154.
- Maeder ML, Stefanidakis M, Wilson CJ, et al. Development of a gene-editing approach to restore vision loss in Leber congenital amaurosis type 10. *Nat Med* 2019;25:229–233.
- Coppieters F, Casteels I, Meire F, et al. Genetic screening of LCA in Belgium: predominance of CEP290 and identification of potential modifier alleles in AH11 of CEP290-related phenotypes. *Hum Mutat* 2010;31:E1709–E1766.
- Dulla K, Aguila M, Lane A, et al. Splice-modulating oligonucleotide QR-110 restores CEP290 mRNA and function in human c.2991+1655A>G LCA10 models. *Mol Ther Nucleic Acids* 2018;12:730–740.
- McAnany JJ, Genead MA, Walia S, et al. Visual acuity changes in patients with Leber congenital amaurosis and mutations in CEP290. *JAMA Ophthalmol* 2013;131:178–182.
- Jacobson SG, Cideciyan AV, Sumaroka A, et al. Outcome measures for clinical trials of Leber congenital amaurosis caused by the intronic mutation in the CEP290 gene. *Invest Ophthalmol Vis Sci* 2017;58:2609–2622.
- Valkenburg D, van Cauwenbergh C, Lorenz B, et al. Clinical characterization of 66 patients with congenital retinal disease due to the deep-intronic c.2991+1655A>G mutation in CEP290. *Invest Ophthalmol Vis Sci* 2018;59:4384–4391.
- American Academy of Ophthalmology Quality of Care Secretariat. Recommendations on Clinical Assessment of Patients with Inherited Retinal Degenerations; 2016. Available at: <https://www.aaof.org/clinical-statement/recommendations-on-clinical-assessment-of-patients>. Accessed November 1, 2019.
- Taylor RL, Parry NRA, Barton SJ, et al. Panel-based clinical genetic testing in 85 children with inherited retinal disease. *Ophthalmology* 2017;124:985–991.
- Deloitte Access Economics. The Socioeconomic Impact of Inherited Retinal Dystrophies (IRDs) in the United Kingdom. 2019. Available at: <https://www2.deloitte.com/content/dam/Deloitte/au/Documents/Economics/deloitte-au-economics-cost-illness-irds-uk-030919.pdf>. Accessed March 1, 2020.
- Chadha RK, Subramanian A. The effect of visual impairment on quality of life of children aged 3–16 years. *Br J Ophthalmol* 2011;95:642–645.
- Hamblyon EL, Moore AT, Rahi JS. The health-related quality of life of children with hereditary retinal disorders and the psychosocial impact on their families. *Invest Ophthalmol Vis Sci* 2011;52:7981–7986.
- Lloyd A, Piglowska N, Ciulla T, et al. Estimation of impact of RPE65-mediated inherited retinal disease on quality of life and the potential benefits of gene therapy. *Br J Ophthalmol* 2019; 103:1610–1614.
- Herdman M, Gudex C, Lloyd A, et al. Development and preliminary testing of the new five-level version of EQ-5D (EQ-5D-5L). *Qual Life Res* 2011;20:1727–1736.
- Hatoum HT, Brazier JE, Akhras KS. Comparison of the HUI3 with the SF-36 preference based SF-6D in a clinical trial setting. *Value Health* 2004;7:602–609.
- Boulton M, Haines L, Smyth D, Fielder A. Health-related quality of life of children with vision impairment or blindness. *Dev Med Child Neurol* 2006;48:656–661.
- Do B, Lynch P, Macris EM, et al. Systematic review and meta-analysis of the association of Autism Spectrum Disorder in visually or hearing impaired children. *Ophthalmic Physiol Opt* 2017;37:212–224.
- de Verdier K, Ulla E, Lofgren S, Fernell E. Children with blindness - major causes, developmental outcomes and implications for habilitation and educational support: a two-decade, Swedish population-based study. *Acta Ophthalmol* 2018;96: 295–300.
- Tavakol K, Dehi M, Naji H, Nasiri M. Parental anxiety and quality of life in children with blindness in Abasire institution. *Iran J Nurs Midwifery Res* 2008;13:141–144.

29. Prem Senthil M, Khadka J, Gilhotra JS, et al. Exploring the quality of life issues in people with retinal diseases: a qualitative study. *J Patient Rep Outcomes* 2017;1:15.
30. Ishtiaq R, Chaudhary MH, Rana MA, Jamil AR. Psychosocial implications of blindness and low vision in students of a school for children with blindness. *Pak J Med Sci* 2016;32:431–434.
31. Jensen IS, Kay CN. Estimating the Life-Time Indirect Costs of Vision Impairment in Inherited Retinal Degeneration: Economic Impact on Education, Government Benefit Programs, Productivity, and Tax Loss for Patients and Caregiver Burden (PO075-2018). Chicago, IL: American Academy of Ophthalmology; 2018.
32. Verbakel SK, van Huet RAC, Boon CJF, et al. Non-syndromic retinitis pigmentosa. *Prog Retin Eye Res* 2018;66:157–186.
33. Spark Therapeutics Inc. Luxturna (Voretigene Nepravovec-Rzyl) Prescribing Information. 2017. Available at: [https://sparktx.com/LUXTURNA\\_US\\_Prescribing\\_Information.pdf](https://sparktx.com/LUXTURNA_US_Prescribing_Information.pdf). Accessed November 1, 2019.
34. Novartis. Luxturna (Voretigene Nepravovec) Summary of Product Characteristics. 2019. Available at: [https://www.ema.europa.eu/en/documents/product-information/luxturna-epar-product-information\\_en.pdf](https://www.ema.europa.eu/en/documents/product-information/luxturna-epar-product-information_en.pdf). Accessed November 13, 2019.
35. Hyvärinen L. Considerations in evaluation and treatment of the child with low vision. *Am J Occup Ther* 1995;49:891–897.
36. Collin RW, den Hollander AI, van der Velde-Visser SD, et al. Antisense oligonucleotide (AON)-based therapy for Leber congenital amaurosis caused by a frequent mutation in CEP290. *Mol Ther Nucleic Acids* 2012;1:e14.
37. Vázquez-Domínguez I, Garanto A, Collin RWJ. Molecular therapies for inherited retinal diseases—current standing, opportunities and challenges. *Genes (Basel)* 2019;10:654.
38. Rasul A, Subhi Y, Sorensen TL, Munch IC. Non-physician delivered intravitreal injection service is feasible and safe—a systematic review. *Dan Med J* 2016;63:A5229.
39. Ziccardi L, Cordeddu V, Gaddini L, et al. Gene therapy in retinal dystrophies. *Int J Mol Sci* 2019;20:5722.
40. Yin W, Rogge M. Targeting RNA: a transformative therapeutic strategy. *Clin Transl Sci* 2019;12:98–112.
41. Russell SR, Drack AV, Cideciyan AV, et al. Results of a phase 1b/2 trial of intravitreal (IVT) sepfarsen (QR-110) antisense oligonucleotide in Leber congenital amaurosis 10 (LCA10) due to p.Cys998X mutation in the CEP290 gene. *Invest Ophthalmol Vis Sci* 2020;61:866.
42. Falavarjani KG, Nguyen QD. Adverse events and complications associated with intravitreal injection of anti-VEGF agents: a review of literature. *Eye (Lond)* 2013;27:787–794.
43. Kitchens JW, Do DV, Boyer DS, et al. Comprehensive review of ocular and systemic safety events with intravitreal aflibercept injection in randomized controlled trials. *Ophthalmology* 2016;123:1511–1520.
44. Trapani I, Auricchio A. Has retinal gene therapy come of age? From bench to bedside and back to bench. *Hum Mol Genet* 2019;28:R108–R118.
45. Ruan GX, Barry E, Yu D, et al. CRISPR/Cas9-Mediated genome editing as a therapeutic approach for Leber congenital amaurosis 10. *Mol Ther* 2017;25:331–341.
46. Peng Y, Tang L, Zhou Y. Subretinal injection: a review on the novel route of therapeutic delivery for vitreoretinal diseases. *Ophthalmic Res* 2017;58:217–226.
47. Ochakovski GA, Bartz-Schmidt KU, Fischer MD. Retinal gene therapy: surgical vector delivery in the translation to clinical trials. *Front Neurosci* 2017;11:174.
48. Edwards TL, Jolly JK, Groppe M, et al. Visual acuity after retinal gene therapy for choroideremia. *N Engl J Med* 2016;374:1996–1998.
49. MacLaren RE, Groppe M, Barnard AR, et al. Retinal gene therapy in patients with choroideremia: initial findings from a phase 1/2 clinical trial. *Lancet* 2014;383:1129–1137.
50. Ledford H. CRISPR treatment inserted directly into the body for first time. *Nature* 2020;579:185.
51. Maguire AM, Russell S, Wellman JA, et al. Efficacy, safety, and durability of voretigene neparvovec-rzyl in RPE65 mutation-associated inherited retinal dystrophy: results of phase 1 and 3 trials. *Ophthalmology* 2019;126:1273–1285.
52. Duijkers L, van den Born LI, Neidhardt J, et al. Antisense oligonucleotide-based splicing correction in individuals with Leber congenital amaurosis due to compound heterozygosity for the c.2991+1655A>G mutation in CEP290. *Int J Mol Sci* 2018;19:753.
53. Cideciyan AV, Jacobson SG, Drack AV, et al. Effect of an intravitreal antisense oligonucleotide on vision in Leber congenital amaurosis due to a photoreceptor cilium defect. *Nat Med* 2019;25:225–228.
54. Allergan. Ozurdex® Prescribing Information. 2018. Available at: [https://www.accessdata.fda.gov/drugsatfda\\_docs/label/2018/022315s012lbl.pdf](https://www.accessdata.fda.gov/drugsatfda_docs/label/2018/022315s012lbl.pdf). Accessed November 2, 2020.
55. Alimera Sciences I. ILUVIEN® Prescribing Information. 2016. Available at: [https://www.accessdata.fda.gov/drugsatfda\\_docs/label/2017/201923s002lbl.pdf](https://www.accessdata.fda.gov/drugsatfda_docs/label/2017/201923s002lbl.pdf). Accessed November 2, 2020.
56. ClinicalTrials.gov. Extension Study to Study PQ-110-001 (NCT03140969) (INSIGHT). 2019. Available at: <https://clinicaltrials.gov/ct2/show/NCT03913130>. Accessed May 21, 2020.
57. ClinicalTrials.gov. A Study to Evaluate Efficacy, Safety, Tolerability and Exposure After a Repeat-Dose of Sepofarsen (QR-110) in LCA10 (ILLUMINATE). 2019. Available at: <https://clinicaltrials.gov/ct2/show/NCT03913143>. Accessed May 21, 2020.
58. ClinicalTrials.gov. Single Ascending Dose Study in Participants With LCA10; 2019. Available at: <https://clinicaltrials.gov/ct2/show/study/NCT03872479>. Accessed November 1, 2019.