


CASE REPORT

Absence of ^{18}F -fluorodeoxyglucose uptake using Positron Emission Tomography/Computed Tomography in Madelung's disease: A case report

Michiel P.B. Moonen¹  | Emmani B.M. Nascimento¹ | Marinus J.P.G. van Kroonenburgh² | Dees Brandjes³ | Wouter D. van Marken Lichtenbelt¹

¹Department of Nutrition and Movement Sciences, NUTRIM School of Nutrition and Translation Research in Metabolism, Maastricht University, Maastricht, Netherlands

²Department of Nuclear Medicine, Maastricht University Medical Center, Maastricht, Netherlands

³Department of Internal Medicine, Slotervaart Medical Centre, Amsterdam, Netherlands

Correspondence

Michiel P. B. Moonen, Department of Nutrition and Movement Sciences, NUTRIM School of Nutrition and Translation Research in Metabolism, Maastricht University, Maastricht, Netherlands.
Email: m.moonen@maastrichtuniversity.nl

Madelung's disease is characterized by the manifestation of multiple ectopic lipomas, usually found in the cervical-thoracic region, however, clinical manifestation may vary among patients. It has been postulated that lipomas associated with Madelung's disease are linked to brown adipose tissue (BAT) due to the presence of uncoupling protein 1 (UCP1). Therefore, we here investigated whether BAT activity is present in a patient with Madelung's disease. ^{18}F -fluorodeoxyglucose (^{18}F -FDG) uptake using PET/CT after a cooling procedure was measured together with body temperature and energy expenditure. Finally, adipose tissue biopsies were taken from the lipomas for gene expression analysis and histology. ^{18}F -FDG uptake was not detected after the cooling procedure in the lipomas. Furthermore, adipose tissue biopsies derived from the lipomas did not express UCP1. We thus conclude that cold-stimulated BAT activity was not detected in lipomas associated with Madelung's disease. Additional research in other patients is needed to unravel the role of dysfunctional BAT in Madelung's disease.

KEYWORDS

brown adipose tissue, Madelung's disease

Multiple symmetric lipomatosis or Madelung's disease is characterized by symmetric development of lipomas in the cervical-thoracic region.¹ Madelung's disease mainly affects males and is associated with alcohol abuse early in life.²⁻⁴ Clinically, patients can be divided in two subgroups: Type 1, with symmetrical gross masses in the upper part of the body and Type 2, with more general obesity.⁵

Uncoupling protein 1 (UCP1) has been detected in biopsies taken from lipomas in patients suffering from Madelung's disease.⁶ Normally, mitochondria build up a proton gradient across the membrane by oxidation of substrates which is used to produce ATP. Adrenergic activation of UCP1 uncouples this process resulting in heat

production instead of ATP production.⁷ UCP1 is normally specific for brown adipose tissue (BAT), which could mean that BAT is present in the lipomas. However, cells derived from these lipomas do not respond to adrenergic receptor stimulated lipolysis,⁶ and this may indicate reduced fatty acid availability and related disturbed BAT metabolism. This would impair mitochondrial uncoupling and BAT thermogenesis, potentially reducing the body's protection against cold together with an elevated sympathetic nervous system activity. This could in turn lead to proliferation of adipocytes.⁶ In other samples taken from lipomas there was also evidence for mitochondrial dysfunction due to mutations in the mitochondrial DNA.⁸

This is an open access article under the terms of the Creative Commons Attribution-NonCommercial-NoDerivs License, which permits use and distribution in any medium, provided the original work is properly cited, the use is non-commercial and no modifications or adaptations are made.

© 2019 The Authors. *Clinical Obesity* published by John Wiley & Sons Ltd on behalf of World Obesity Federation

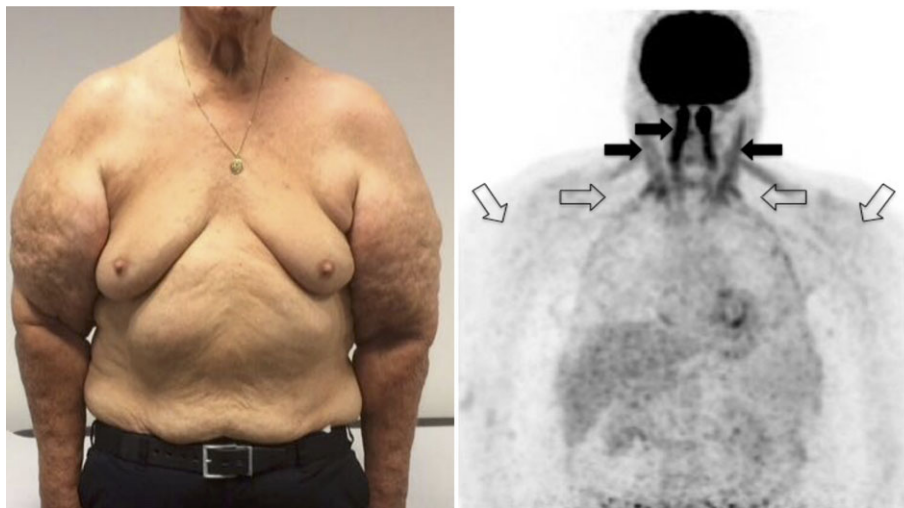


FIGURE 1 (A) Clinical view of the patient. Noticeable is the subcutaneous lipomatosis in both upper arms and abdomen, with relative sparing of the cervical region. (B) PET image using ^{18}F -FDG following the cooling procedure. The ^{18}F -fluorodeoxyglucose (FDG) uptake in the cervical region is caused by active muscle tissue due to shivering (filled arrows). Note the absence of ^{18}F -FDG uptake in the deep cervical adipose tissue and lipomas in both upper arms (clear arrows)

Expression of UCP1 in lipomas associated with Madelung's disease suggests the presence of BAT. However, since this BAT could be dysfunctional, we hypothesize no BAT activity will be measured via uptake of ^{18}F -fluorodeoxyglucose (FDG) following cold exposure. Furthermore, we expect to detect UCP1 mRNA in adipose tissue biopsies derived from the lipomas.

A 68-year-old male patient (body mass index, BMI: 36.2 kg/m²), with clinical diagnosis of Madelung's disease (Type 1) was referred to Maastricht University Medical Centre for detection of active BAT. The patient extensively used alcohol from the age of 16. He suffered from symmetric lipomatosis mainly around the upper arms and abdomen, with relative sparing of the cervical region (Figure 1A). Recent laboratory results showed a near-to-normal thyroid function (TSH: 4.8 mIU/L [ref 0.3–4.6 mIU/L]; FT4: 15.3 pmol/L [ref 10–23 pmol/L]). The patient had not used beta-blockers in the last year.

BAT presence and activity was determined in the patient using an individualized cooling procedure and ^{18}F -FDG-Positron Emission Tomography/Computed Tomography (PET/CT) (Gemini TF PET/CT; Philips, Amsterdam, Netherlands) as described before.⁹ The patient arrived at the research institute at 8:30 AM, after consuming a light breakfast at 6:00 AM. At 8:45 AM, the patient ingested a telemetric pill (CorTemp HT150002; HQ Inc., Palmetto, Florida). At the same time wireless temperature sensors (iButton; Maxim Integrated Products, San Jose, California) were attached at the 15 International Organization for Standardization (ISO) defined sites to measure skin temperature. An intravenous cannula was placed in the right antecubital vein. The patient was wrapped in a water-perfused suit (ThermoWrap Universal 3166; MTR Advanced Technologies Ltd., Yavne, Israel), which was connected to two cooling installations (Blanketrol III; Cincinnati Sub-Zero, Sharonville, Ohio).

The water-perfused suit was heated to 36°C to create thermoneutral conditions. Indirect calorimetry was measured using a ventilated hood system (EZCAL; Maastricht Instruments, Maastricht, Netherlands). After this thermoneutral period, the cooling procedure was started. The water temperature was lowered to 4°C each

15 minutes, until shivering. Following this, the temperature was raised to 34°C for 5 minutes to stop the shivering. Then temperature was maintained at 27°C, which was followed by a second indirect calorimetry measurement. At 12:45 PM, a bolus of 77 MBq of ^{18}F -FDG was injected intravenously after which the patient was instructed to lie down still for 1 hour.

After 1 hour, at 13:45 PM, the PET/CT protocol was performed with a low-dose CT scan (120 kV, 30 mAs), immediately followed by a static PET scan (6 bed positions, 4 minutes per position) covering the area from the skull to the iliac crest. After the ^{18}F -FDG-PET/CT scan, two adipose tissue biopsies were taken under local anaesthesia. One biopsy was taken at the lateral side of the right upper arm from the lipoma. The second biopsy was taken from the abdominal subcutaneous fat deposit, just right of the umbilical. The adipose tissue samples were either paraffin-embedded or frozen in melting isopentane prior to further analysis. RNA was extracted using Trizol reagent followed by protocol described in the RNeasy kit from Qiagen (Hildenberg,

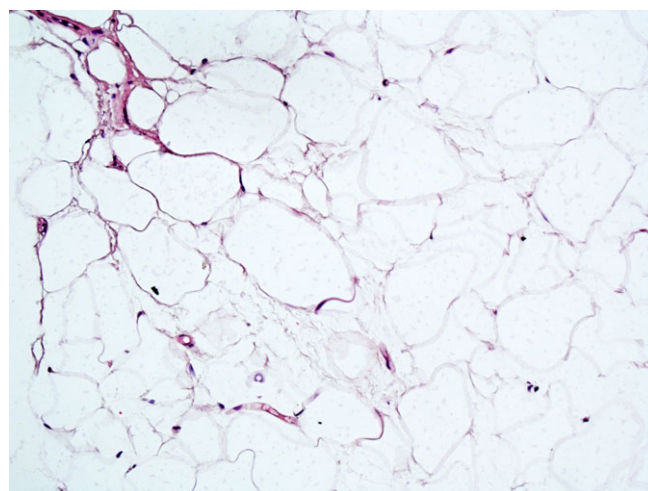


FIGURE 2 Adipose tissue from lipoma of right upper arm (magnification: $\times 200$)

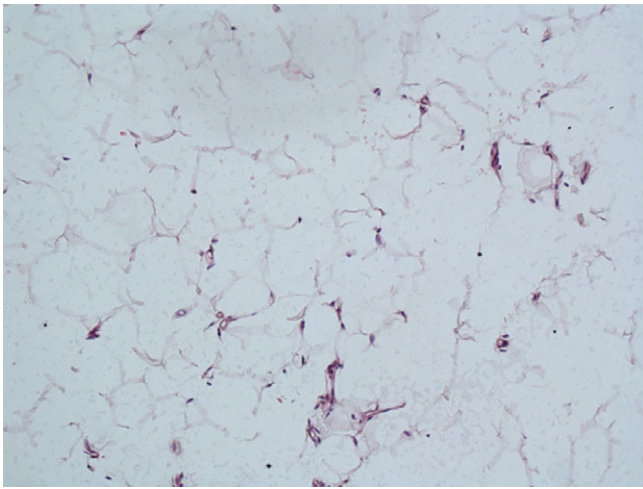


FIGURE 3 Subcutaneous white adipose tissue from abdomen (magnification: $\times 200$)

Germany). UCP1 mRNA expression was determined using a CFX384 Touch Real-Time PCR Detection System from BioRad Laboratories (Hercules, California) with a Taqman gene expression assay (Hs00222453_m1) as described before.¹⁰

Cold exposure increased resting energy expenditure from 5.2 to 9.7 kJ/min. Although the protocol was designed to induce non-shivering thermogenesis, the patient did shiver occasionally in the final stages of the cooling procedures. Non-shivering thermogenesis plus some shivering thermogenesis (as the per cent increase in energy expenditure during cold exposure above the resting energy expenditure) was 53.6%. The respiratory quotient remained 0.83. Core temperature was 37.3°C during the thermoneutral period and dropped to 36.5°C during cold exposure, while the mean skin temperature dropped from 34.0°C to 32.1°C.

The ¹⁸F-FDG-PET/CT scan showed no uptake of ¹⁸F-FDG in the adipose tissue depots in the cervical-thoracic region or in both upper arms (Figure 1B). Adipose tissue biopsies from the arm (Figure 2) and the abdomen (Figure 3) were stained with haematoxylin-eosin (HE), and both showed the microscopic structure of white adipose tissue (WAT). Next, we examined UCP1 mRNA expression in biopsies taken from the arm and the abdomen. Cq values for the samples derived from the lipoma and subcutaneous WAT were 32.9 and 33.7, respectively. As a reference, we included a human hibernoma, which had a Cq value of 19.4.

Our patient showed normal physical responses to cooling, as seen in the sustained core temperature and the temperature gradient in the lower arm. Energy expenditure increased upon cold exposure as expected for normal thermoregulation including both non-shivering and mild shivering.

As hypothesized, the ¹⁸F-FDG-PET/CT scan showed no uptake of the ¹⁸F-FDG tracer in neither the cervical-thoracic region nor the upper arms, where the lipomas were situated in our patient. Based on the hypothesis that a dysfunctional adrenergic pathway leads to less UCP1 expression and reduced or absent thermogenesis, this could explain the lack of tracer uptake in the normal BAT regions in our patient.

In line with the ¹⁸F-FDG-PET/CT results, both adipose tissue biopsies showed a typical morphology of WAT (Figures 2 and 3), which was negative for UCP1 mRNA. However, it is possible that our patient has another causal mechanism, explaining the lack of UCP1.^{5,6,8} This could potentially explain why we were unable to find any sign of BAT presence in the biopsy material.

The use of an ¹⁸F-FDG-PET/CT scan combined with the cooling procedure is an established method to detect the presence of active BAT.⁹ Generally, the prevalence is highest in young healthy (lean) adults, although BAT is not always detected in all lean subjects.¹⁰ The prevalence of BAT decreases with obesity and age.⁹ In view of the age and BMI of our patient, this may also explain the absence of active BAT.

The defective adrenergic pathway in Madelung's disease could also explain the absence of tracer uptake in both upper arms. In the adipose tissue biopsies, we only found cells resembling white adipocytes without any expression of UCP1 mRNA. An in vitro model with primary cultured adipocytes derived from patient adipose tissue could be used to examine UCP1 expression after adrenergic stimulation. However, these experiments would require freshly isolated adipose tissue biopsies.

Concluding, in a patient with clinical Madelung's disease we found no active BAT, neither in the lipomas nor in the cervical-thoracic region. However, since this was a single case, the results in patients may differ, and this may not exclude BAT activity in other patients. Further research could focus on the causal mechanism for Madelung's disease and the possible relationship with BAT.

ACKNOWLEDGEMENTS

The authors would also like to thank Nicole Bouvy and Karin Sanders, Paul van Dijk and Gert Schaart for obtaining and processing of the biopsy material.

CONFLICTS OF INTEREST

No conflict of interest was declared.

Author contributions

M.P.B.M., M.J.P.G.K. and E.B.M.N. performed experiments. M.P.B.M., E.B.M.N., M.J.P.G.K., D.B. and W.D.V.M.L. designed the study and wrote the manuscript.

ORCID

Michiel P.B. Moonen  <https://orcid.org/0000-0002-8207-3953>

REFERENCES

1. Busetto L, Strater D, Enzi G, et al. Differential clinical expression of multiple symmetric lipomatosis in men and women. *Int J Obes Relat Metab Disord*. 2003;27(11):1419-1422.
2. Enzi G, Busetto L, Ceschin E, Coin A, Digo M, Pigozzo S. Multiple symmetric lipomatosis: clinical aspects and outcome in a long-term

- longitudinal study. *Int J Obes Relat Metab Disord*. 2002;26(2):253-261.
3. Leffell DJ, Braverman IM. Familial multiple lipomatosis. Report of a case and a review of the literature. *J Am Acad Dermatol*. 1986;15(2, pt 1):275-279.
 4. Lee HW, Kim TH, Cho JW, Ryu BY, Kim HK, Choi CS. Multiple symmetric lipomatosis: Korean experience. *Dermatol Surg*. 2003;29(3):235-240.
 5. Enzi G. Multiple symmetric lipomatosis: an updated clinical report. *Medicine*. 1984;63(1):56-64.
 6. Enzi G, Busetto L, Sergi G, et al. Multiple symmetric lipomatosis: a rare disease and its possible links to brown adipose tissue. *Nutr Metab Cardiovasc Dis*. 2015;25(4):347-353.
 7. Cannon B, Nedergaard J. Brown adipose tissue: function and physiological significance. *Physiol Rev*. 2004;84(1):277-359.
 8. Plummer C, Spring PJ, Marotta R, et al. Multiple symmetrical lipomatosis—a mitochondrial disorder of brown fat. *Mitochondrion*. 2013;13(4):269-276.
 9. Vijgen GH, Bouvy ND, Teule GJ, Brans B, Schrauwen P, van Marken Lichtenbelt WD. Brown adipose tissue in morbidly obese subjects. *PLoS One*. 2011;6(2):e17247.
 10. Vosselman MJ, Hoeks J, Brans B, et al. Low brown adipose tissue activity in endurance-trained compared with lean sedentary men. *Int J Obes (Lond)*. 2015;39(12):1696-1702.

How to cite this article: Moonen MPB, Nascimento EBM, van Kroonenburgh MJ, Brandjes D, van Marken Lichtenbelt WD. Absence of ¹⁸F-fluorodeoxyglucose uptake using Positron Emission Tomography/Computed Tomography in Madelung's disease: A case report. *Clin Obes*. 2019;9:e12302. <https://doi.org/10.1111/cob.12302>