

First two cases of literature: Caustic sclerosing cholangitis due to percutaneous treatment of hydatid liver disease causing liver transplantation

 Gokalp Okut,  Kutay Saglam,  Huseyin Kocaaslan,  Cuneyt Kayaalp

Department of Gastrointestinal Surgery, Inonu University School of Medicine, Malatya, Turkiye

Abstract

Echinococcus granulosus is predominantly found in the liver and can be effectively managed through antihelminthic therapy, surgical intervention, or interventional radiology. Percutaneous treatment (PT) has gained widespread popularity due to its minimally invasive nature. An integral step in surgical and PT procedures involves the utilization of protoscolicidal agents to eliminate the parasites. However, the administration of protoscolicidal agents carries the risk of inducing caustic sclerosing cholangitis (SC) if there is a communication between the cyst and the biliary tract. In this pioneering study, we present two cases of caustic SC that occurred subsequent to PT for hydatid liver, necessitating further progression of the disease and ultimately leading to liver transplantation.

Keywords: Cholangitis; hydatid cyst; hydatid disease; liver transplantation; PAIR.

Introduction

Hydatid disease, attributed to the parasite *Echinococcus granulosus*, primarily affects the liver and lungs, although it can manifest in various tissues and organ systems. Treatment options for liver hydatid cysts include medical, surgical, or percutaneous interventions. Percutaneous interventions involve using ultrasound or computed tomography guidance to insert a catheter into the cyst cavity, through which a scolicidal agent is injected and then aspirated. Recommended scolicidal agents include 20–30% hypertonic saline, 95% ethanol, or 0.5% cetrimide.^[1] However, the use of these agents carries the risk of severe toxicity to the biliary tract if there is a cystobiliary connection. This study presents two cases of secondary sclerosing cholangitis (SC) that arose following the administration of scolicidal agents during percutaneous therapy

(PT) and necessitated liver transplantation. To the best of our knowledge, this is the first report of liver transplantation required due to SC subsequent to PT for hepatic hydatid cysts.

Case Reports

Case 1

A 50-year-old male patient was initially admitted to another medical center with complaints of right upper quadrant pain. Upon evaluation, a type 1 hydatid cyst located in segments 6–7 of the liver was detected. The patient underwent medical therapy and subsequently the puncture-aspiration-injection-reaspiration (PAIR) procedure using a 20% saline solution. Following the procedure, the patient was discharged on the first day and reported no symptoms except for intermittent pain, which persisted for eight months. During outpatient follow-up visits, the attending physician confirmed the eradication of the cyst.

After eight months, the patient was readmitted to the hospital due to jaundice and right upper quadrant pain. Clinical, laboratory, radiological, and endoscopic retrograde cholangiopancreatography (ERCP) findings confirmed the diagnosis of SC (Fig. 1). The patient underwent regular follow-up, receiving endoscopic biliary stenting for five years to manage recurrent cholangitis attacks. Eventually, the patient was referred to our clinic for evaluation of secondary biliary cirrhosis. Considering the patient's moderately impaired liver function (Model for End-Stage Liver Disease score [MELD Na]: 13, Child Class B), liver transplantation was not initially considered. However, due to recurring episodes of cholangitis and the development of liver abscesses, multiple percutaneous drainage procedures were required.

In the sixth year following the PAIR procedure, the patient was admitted to our institute with advanced cirrhosis (MELD Na: 26, Child Class C), leading to the decision to perform a living donor right lobe liver transplantation. Intraoperative findings showed cholestasis and fibrosis in the liver, with the common bile duct exhibiting sclerotic changes and thickened walls due to recurrent ERCP procedures and SC episodes. The postoperative period was complicated by a biliary fistula and hepatic artery thrombosis, necessitating relaparotomy. Fortunately, the patient's clinical course following relaparotomy was uneventful, and he was successfully discharged.

Pathological evaluation of the explanted liver confirmed cirrhosis and obliteration of the biliary tree. Tragically, the patient succumbed to sepsis caused by a secondary infection of a bilioma resulting from a biliary leak attributed to late hepatic artery thrombosis in the fourth month following liver transplantation.

How to cite this article: Okut G, Saglam K, Kocaaslan H, Kayaalp C. First two cases of literature: Caustic sclerosing cholangitis due to percutaneous treatment of hydatid liver disease causing liver transplantation. *Hepatology Forum* 2024; 5(2):90–92.

Received: July 10, 2023; **Revised:** August 28, 2023; **Accepted:** September 28, 2023; **Available online:** February 12, 2024

Corresponding author: Gokalp Okut; Inonu Universitesi Tip Fakultesi, Gastrointestinal Cerrahi Anabilim Dalı, Malatya, Turkiye
Phone: +90 545 624 37 83; **e-mail:** gokalp.okut@gmail.com



OPEN ACCESS
This work is licensed under a Creative Commons Attribution-NonCommercial 4.0 International License.

Hepatology Forum - Available online at www.hepatologyforum.org

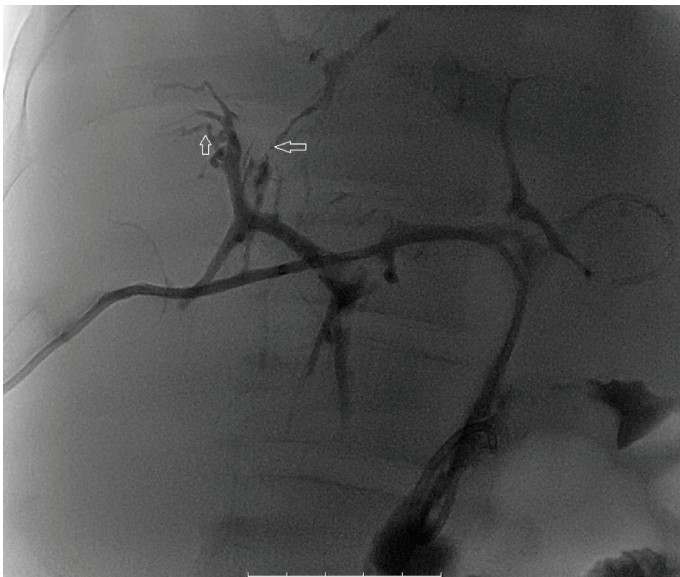


Figure 1. Strictural biliary areas.

Case 2

A 26-year-old female patient underwent a PAIR procedure at another medical center for the management of a type 1 hydatid cyst located in segment 7 of the liver, using ethanol as the scolicedal agent. Immediately after the procedure, the patient developed persistent abdominal pain, fever, and hyperbilirubinemia. Subsequent imaging with computerized tomography and ERCP (Fig. 2) confirmed the diagnosis. After 26 days of hospitalization, she was referred to our institute with a secondary diagnosis of SC accompanied by liver failure.

Upon evaluation, the patient was found to have end-stage liver failure, with a MELD Na of 31.5 and Child Class C. A living donor liver transplantation was performed to address her condition. The patient's postoperative course was uneventful, and she was discharged on the 21st day after surgery. Pathological examination of the explanted liver revealed a segmental hydatid cyst that had partially ruptured into the major bile ducts, with mucosal ulceration observed in the extrahepatic biliary tract and increased connective tissue thickening of the duct. During the 31st-month follow-up after transplantation, the patient's condition remained stable and favorable.

Discussion

While vague abdominal pain is a common symptom associated with hydatid liver cysts, these cysts often remain asymptomatic and are typically discovered incidentally during patient examinations. Over time, the cysts gradually grow and become symptomatic when they rupture into the biliary tract, leading to obstructive jaundice. In some cases, the cysts may rupture spontaneously into the peritoneal cavity.^[2] Laboratory tests in patients with uncomplicated cysts often yield normal results. However, when there is communication between the cyst and the biliary system, liver function tests and cholestasis enzymes may show elevated levels. Due to the non-specific nature of the symptoms and the limited information from history and physical examination, radiological imaging, such as ultrasound and computed tomography, is essential for accurate diagnosis. The radiological classification of hepatic hydatid cysts is based on the World Health Organization Informal Working Group on Echinococcosis and the Gharbi classification system.^[3]

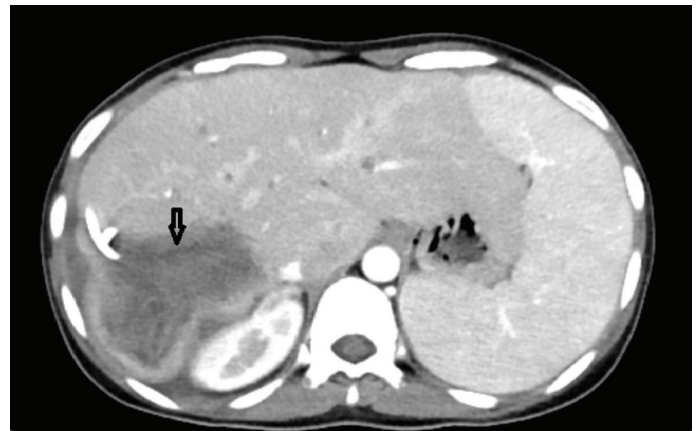

Figure 2. Hydatid cyst with PAIR catheter.

The choice of treatment for hydatid cysts depends on the cyst type. Percutaneous treatment (PT) is commonly employed for patients who are not suitable candidates for surgery, those who prefer non-surgical options, cases of recurrence, and individuals who do not respond to benzimidazole treatment. PT modalities are also indicated for World Health Organization cyst types CE1 and CE3a, as well as for cysts smaller than 5 cm, pregnant women, and children under 3 years old.^[4] However, PT is generally not recommended for WHO cyst types CE2, CE3b, CE4, and CE5, as well as for cysts located in the lungs and those that communicate with the biliary tree.^[4] For cysts larger than 10 cm, the preferred approach is often the placement of a drainage catheter into the cystic cavity, which is then removed when the drainage volume falls below 10 ml.^[5]

Although percutaneous intervention has relatively low reported rates of mortality and morbidity, it is not without specific and serious complications. In a study, the overall rate of various complications associated with PT, including anaphylaxis, allergic skin rash, pneumothorax, cavity infection, and cystobiliary fistula, was reported to be approximately 9%.^[6] The most concerning complications are the risk of anaphylactic shock (0.38%) and secondary intra-abdominal hydatidosis (1.3%) resulting from the dissemination of cyst content into the abdomen during the intervention. Additionally, there is a risk of scolicedal agents causing cholangitis in cases where there is communication between the cyst and the biliary tract. However, such a complication has not been reported thus far.^[7]

Caustic SC is a term coined by Belghiti et al.^[8] in 1986 to describe SC caused by scolicedal agents. It is believed to arise from a combination of four key factors: injection of scolicedal agents into the cyst cavity, presence of cystobiliary communication, prolonged exposure of the biliary tree to the scolicedal solution, and individual sensitivity to the scolicedal agent.^[9] In our presented cases, caustic SC was diagnosed, which distinguishes them from primary SC based on two distinctive characteristics.

Firstly, the disease in both patients exhibited rapid progression compared to the natural course of primary SC. In patients with primary SC, the time interval between the initial diagnosis and liver transplantation typically spans between 10 to 14 years. However, in our cases, the disease progressed rapidly over a period ranging from months to several years.

Secondly, unlike primary SC where fibrotic and stenotic biliary lesions affect the entire biliary tree, caustic SC observed in our cases was localized only to the portion exposed to the scolicedal agent. This finding aligns with the observations made in our presented patients.

Bakdik et al.^[9] reported a cystobiliary communication rate of 5.4% in patients who underwent PAIR treatment. Determining whether there is a cystobiliary connection before PAIR is crucial in preventing caustic SC formation. For this purpose, it is necessary to clarify the relationship between the cyst and the biliary tree before using the scolicedal agent during PAIR. However, it is important to note that cystobiliary connection alone is insufficient for the development of cholangitis. The presence of a certain degree of biliary obstruction, which can occur in hydatid cysts that rupture into the biliary tract, as well as individual sensitivity to the agent, are additional contributing factors.^[10]

Conclusion

While there have been reports in the literature regarding caustic cholangitis resulting from the use of scolicedal agents during surgery, there have been no documented cases of caustic cholangitis following PAIR. Our presented cases demonstrate that percutaneous treatment of liver hydatid cysts has the potential to induce caustic SC in patients with abnormal cystobiliary communication. This highlights the importance of considering this potential complication in patients undergoing percutaneous interventions for hydatid cysts, particularly those with cystobiliary communication.

Author Contributions: Concept – CK, GO; Design – CK, GO; Supervision – CK; Fundings – KS; Materials – HK; Data Collection and/or Processing – HS, HK; Analysis and/or Interpretation – CK, GO; Literature Search – GO, HK; Writing – GO, KS; Critical Reviews – CK.

Conflict of Interest: The authors have no conflict of interest to declare.

Informed Consent: Written informed consent was obtained from the patient for the publication of the case report and the accompanying images.

Use of AI for Writing Assistance: Not declared.

Financial Disclosure: The authors declared that this study has received no financial support.

Peer-review: Externally peer-reviewed.

References

1. Yagci G, Ustunsoz B, Kaymakcioglu N, Bozlar U, Gorgulu S, Simsek A, et al. Re-sults of surgical, laparoscopic, and percutaneous treatment for hydatid disease of the liver: 10 years experience with 355 patients. *World J Surg* 2005;29(12):1670-1679.
2. Mandal S, Mandal MD. Human cystic echinococcosis: epidemiologic, zoonotic, clinical, diagnostic and therapeutic aspects. *Asian Pac J Trop Med* 2012;5(4):253-260.
3. WHO Informal Working Group. International classification of ultrasound images in cystic echinococcosis for application in clinical and field epidemiological settings. *Acta Trop* 2003;85(2):253-261.
4. Kabaalioglu A, Ceken K, Alimoglu E, Apaydin A. Percutaneous imaging-guided treatment of hydatid liver cysts: do long-term results make it a first choice? *Eur J Radiol* 2006;59(1):65-73.
5. Men S, Yücesoy C, Edgüer TR, Hekimoğlu B. Percutaneous treatment of giant abdominal hydatid cysts: long-term results. *Surg Endosc* 2006;20(10):1600-1606.
6. Kahriman G, Ozcan N, Donmez H. Hydatid cysts of the liver in children: percutaneous treatment with ultrasound follow-up. *Pediatr Radiol* 2011;41(7):890-894.
7. Yaghan R, Heis H, Bani-Hani K, Matalka I, Shatanawi N, Gharaibeh K, et al. Is fear of anaphylactic shock discouraging surgeons from more widely adopting percutaneous and laparoscopic techniques in the treatment of liver hydatid cyst?. *Am J Surg* 2004;187(4):533-537.
8. Belghiti J, Benhamou JP, Houry S, Grenier P, Huguier M, Fékété F. Caustic sclerosing cholangitis. A complication of the surgical treatment of hydatid disease of the liver. *Arch Surg* 1986;121(10):1162-1165.
9. Bakdik S, Arslan S, Oncu F, Tolu I, Eryilmaz MA. Percutaneous treatment of hepatic cystic echinococcosis: the success of alcohol as a single endocavitary agent in PAIR, catheterization, and modified catheterization techniques. *Radiol Med* 2018;123(2):153-160.
10. Kumar R, Reddy SN, Thulkar S. Intra-biliary rupture of hydatid cyst: diagnosis with MRI and hepatobiliary isotope study. *Br J Radiol* 2002;75(891):271-274.