

Different Techniques for the Management of Meniscal Ramp Lesions Using Standard Anterior Portals



Begad Hesham Mostafa Zaky Abdelrazek, M.Sc., M.D., F.R.C.S.,
Mohammed Refaat Waly, M.Sc., M.D., Mahmoud Ahmed Abdel Aziz, M.Sc., M.D., and
Ahmed Abdel Aziz, M.Sc., M.D.

Abstract: There is strong association between meniscal lesions and anterior cruciate ligament injuries. Recently, light was shown on a new entity: ramp lesions. The incidence of these lesions and their management is still unclear. Although some believe that some lesions, when stable, can be managed conservatively, most surgeons repair ramp tears. Accessibility of these tears is challenging; they are best accessed through posterior portals, which is time-consuming and poses potential risk to vital structures. Our technique allows access to and management of ramp lesions through safe standard anterior portals. Ramp lesions are searched for as a routine step during anterior cruciate ligament reconstruction by advancing the scope through the intercondylar notch just beside the medial femoral condyle. If a lesion is found, it is repaired; only very stable small tears are treated with needling to refresh the edges and induce a healing response. A simple suture, horizontal mattress suture, or a circumferential stitch is used.

Introduction (With Video Illustration)

Meniscal lesions are found in association with anterior cruciate ligament (ACL) injuries in up to 43% of the cases. Lateral meniscal injuries are more common in the acute setting, whereas in chronic ACL-deficient knees, medial meniscal lesions prevail.¹ Despite the fact that most medial meniscal tears are visible on routine knee arthroscopy, many other lesions remain occult and are evident only on posteromedial viewing. From its name, ramp lesions occur in the meniscotibial attachment of the posterior horn of the medial meniscus. This type of lesion is repairable, as it

involves peripheral attachment of meniscus. The aim of this work is to illustrate easy, different methods for the management of ramp lesions in ACL-deficient knees through standard anterior portals using the FAST-FIX 360 Meniscal Repair System (Smith & Nephew, Andover, MA) (Video 1).

Surgical Technique

Informed consent was obtained from all patients. The procedure is performed under tourniquet control with the patient in the supine position under general or spinal anesthesia, and a selective nerve block is used in all cases for postoperative pain control. Bilateral knee examination under anesthesia is performed to assess range of motion and evaluate for concurrent ligamentous instability. The anterolateral portal is created first using an 11-mm blade to create the arthrotomy, and the scope is then introduced through this portal for visualization. A spinal needle is used to check the trajectory of the anteromedial portal before it is created. Medial and lateral compartments are examined, and the menisci are probed for any visible lesions.

Before beginning the steps of ACL reconstruction, we inspect for a ramp lesion by posteromedial visualization of the meniscocapsular attachment of posterior horn medial meniscus. This is performed by diving deep in

From Trauma and Orthopaedics Faculty of Medicine (B.H.M.Z.A., M.R.W., M.A.A.A., A.A.A.) and Student Hospital (M.A.A.A.), Cairo University, Cairo, Egypt; and Trauma and Orthopaedics, Royal London Hospital, Barts Health NHS Trust, London, United Kingdom (B.H.M.Z.A.).

The authors report that they have no conflicts of interest in the authorship and publication of this article. Full ICMJE author disclosure forms are available for this article online, as [supplementary material](#).

Received March 31, 2019; accepted August 27, 2019.

Address correspondence to Begad Hesham Mostafa Zaky Abdelrazek, M.Sc., M.D., F.R.C.S., Trauma and Orthopaedics Faculty of Medicine, Kasr-Alainy, Mathaf El-Manial St., Cairo 11553, Egypt. E-mail: begadhesham@gmail.com

© 2019 by the Arthroscopy Association of North America. Published by Elsevier. This is an open access article under the CC BY-NC-ND license (<http://creativecommons.org/licenses/by-nc-nd/4.0/>).

2212-6287/19417

<https://doi.org/10.1016/j.eats.2019.08.020>

the notch between the posterior cruciate ligament and the medial femoral condyle. In some knees with narrow medial compartments, medial release is performed through the pie crusting technique (needling of superficial medial collateral ligament in the maximum valgus position) to facilitate visualization. A meniscal rasps or shaver is used to refresh the edges, which is followed by all-inside repair, performed through different techniques.

General Steps in All Techniques of Repair

The FAST-FIX 360 Meniscal Repair needle is adjusted to the desired depth of 20 mm. It is then introduced through the anteromedial portal through intercondylar notch over a slotted cannula to avoid lodging soft tissues.

Mattress Suture Technique

Horizontal mattress bites are pursued where the first implant is fired at a posterior location, whereas the second implant is introduced in a more anterior position on the meniscus. The delivery needle is adjusted to be perpendicular to the tear and a minimum of 5 mm from the tear site on the inner meniscal fragment. In general, a minimum width of 8 mm between the 2 entry points should be maintained (Fig 1, Video 1).

Simple Suture (Vertical Mattress) Technique

In this technique, the first implant is delivered superior to the meniscus and in the capsule. The second implant is inserted in the inner fragment of the meniscus. After tightening the stitch, the gap at the tear closes, but the meniscus will be lifted up. Another simple suture is taken, this time on the undersurface of the meniscus in similar method to secure the repair and reverse the upward lifted position of meniscus (Fig 2, Video 1).

Circumferential Technique

In some cases with degenerated menisci, where the material and integrity of the meniscal tissue is questionable, circumferential sutures are performed. The first implant is delivered superior to the meniscus into the knee capsule and the second one is delivered below the meniscus into the capsule with no sutures passing through the meniscal tissue. The suture is then tightened, encircling the meniscus, hence approximating the tear gap. Severe tightening of the stitch is not advisable to avoid kinking of the meniscus (Fig 3, Video 1).

Needling of Stable Lesions

In some cases with scarred stable ramp lesion, a 16-gauge cannula needle is inserted through the

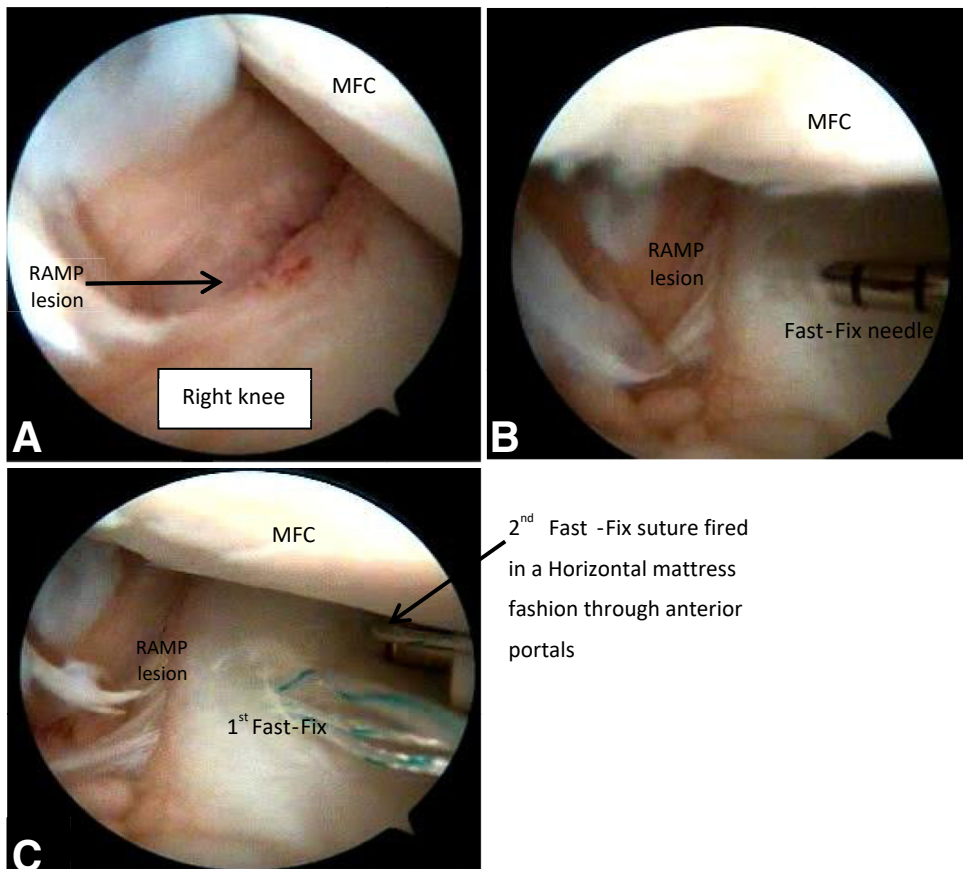
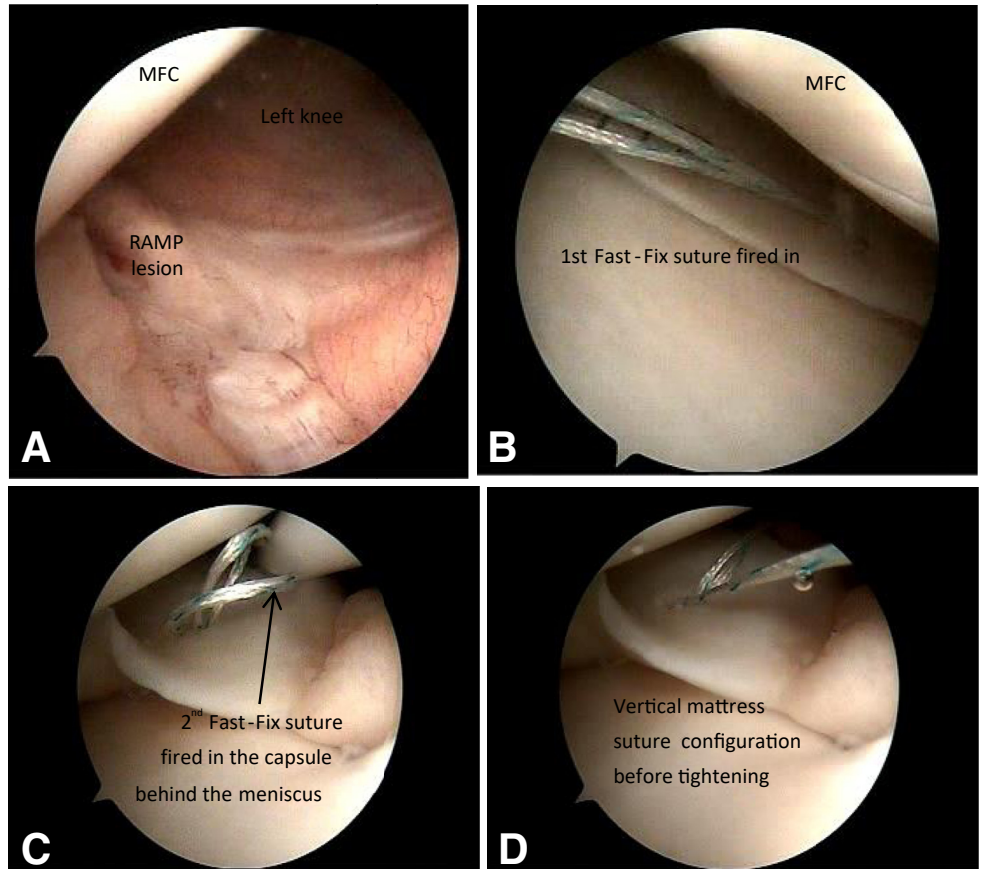


Fig 1. (A) Arthroscopic view of the right knee with posteromedial visualization through standard anterior portals. (B) Needle of FAST-FIX 360 Meniscal Repair introduced to deliver the first anchor. (C) Delivery of the second anchor of FAST-FIX 360 Meniscal Repair needle in a horizontal mattress fashion. (MFC, medial femoral condyle.)

Fig 2. (A) Arthroscopic view of the posteromedial aspect of left knee with a ramp lesion. (B) Arthroscopic view after delivery of the first anchor. (C) Delivery of the second anchor in a vertical mattress manner. (D) Tightening of the stitch and approximation of the tear. (MFC, medial femoral condyle.)



posteromedial capsule guide by transillumination. Then, multiple punctures around the tear are performed to induce a healing response (Fig 4, Video 1).

Discussion

Papastergiou et al.² reported a significant increase in the incidence of meniscal tears in patients undergoing ACL reconstruction after 3 months from the date of injury, and they recommended that ACL reconstruction should be carried out within 3 months to minimize the risk of developing secondary meniscus tears. They also highlighted the importance of posteromedial examination of the ramp area in chronic ACL-deficient knees. Similarly, Zoller et al.³ claimed greater rates of meniscal injuries if ACL reconstruction surgery is delayed 6 months. Ramp lesions occurring either at the time of initial injury or following the progressive stretching due repeated giving way episodes with ACL deficiency are believed to contribute to anteroposterior and/or rotary instability. This is explained by the loss of the wedge block effect of the meniscus against the back of the femoral condyles during femoral roll-back. If neglected, it could be a cause of failure of ACL reconstruction.⁴

The post-ACL reconstruction mild AP knee joint laxity may jeopardize the normal biomechanical

environment for stable ramp lesions to heal.⁵ Thus, it is necessary according to some authors to repair ramp lesions whether stable or not. Ramp lesions are peripheral tears of the meniscotibial attachments, occurring in the red-red zone with a good healing power.⁶ Furthermore, bone marrow and stem cells released during reaming the tunnels of ACL graft promote healing of the lesion. Hence, its repair in conjunction with ACL reconstruction yields good functional outcomes.⁶

According to many authors, the anatomic location of the ramp lesion, being in a vascular area, and biological factors with ACL reconstruction favor its healing without the need for repair. In their view, ramp lesions can be treated conservatively without repair.^{7,8} Ahn et al.⁹ support repair of those lesions, claiming that hypermobility of the meniscocapsular attachment occurring with flexion and extension will hinder healing.

Different techniques have been described for repair of ramp lesions, including all-inside repair, inside-out, and outside-in repair. The pearls and pitfalls of the different techniques described in this study are outlined in Table 1. Repair of ramp lesions is challenging for surgeons.⁶ Good visualization, identifying the extent of the

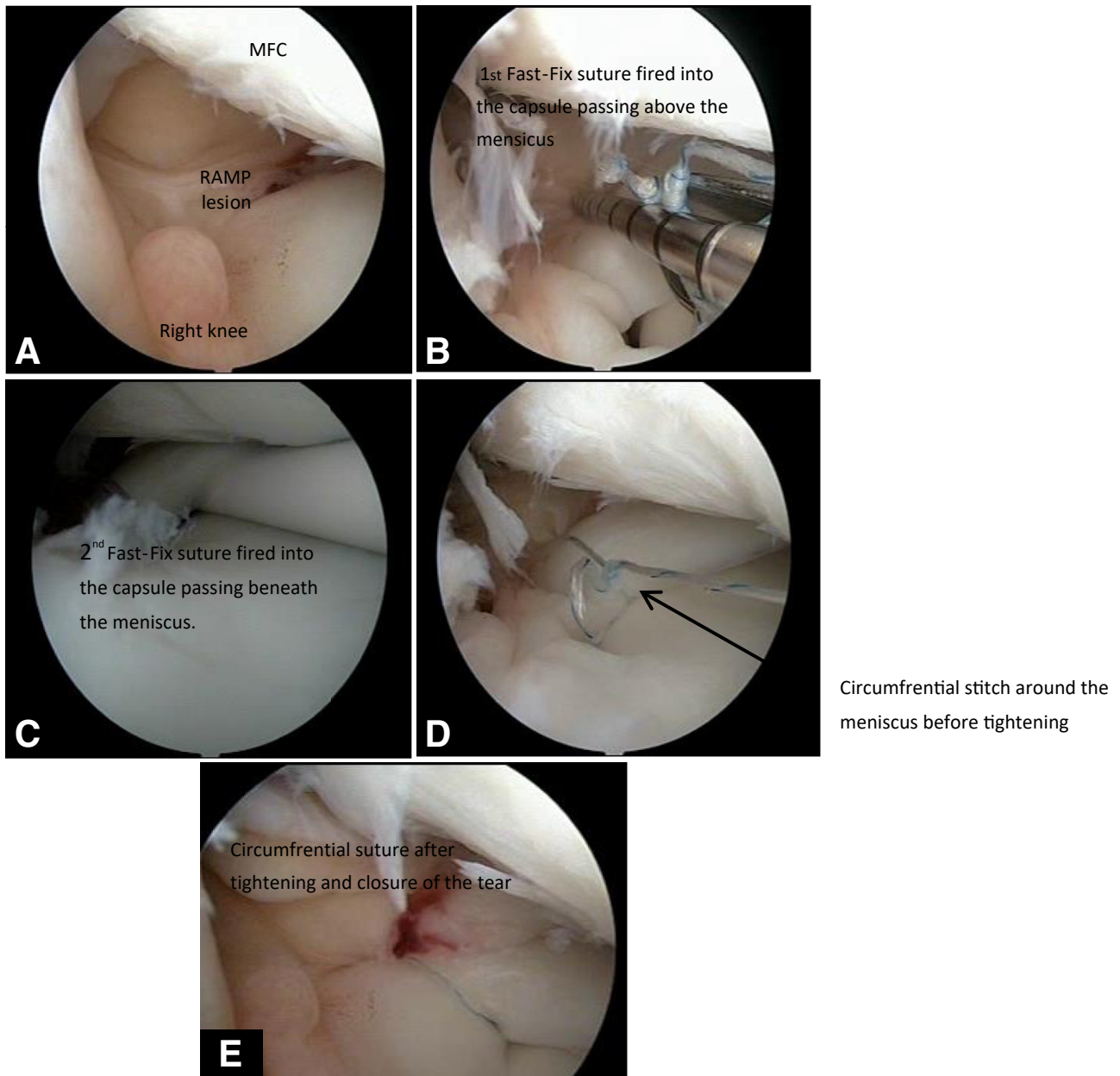


Fig 3. (A) Posteromedial arthroscopic view of the right knee through standard anterior portals showing the ramp lesion. (B) FAST-FIX 360 Meniscal Repair needle introduced into the capsule above the meniscus to fire the first anchor. (C) FAST-FIX 360 Meniscal Repair needle passed beneath the meniscus to deploy the second anchor. (D) Circumferential stitch around the meniscus before tightening of the knot. (E) Tightened circumferential stitch around the meniscus with closure of the gap at the site of the lesion. (MFC, medial femoral condyle.)

tear, and accessibility are important factors for successful repair. Other factors to consider include the surgeon's experience, operative time, stability of the tear, and availability of implants. Advantages and disadvantages of using standard anterior portals are outlined in [Table 2](#).

Some surgeons described 2 posteromedial portals for outside-in repair, where one portal is used for visualization and the other for instrumentation. A suture passer could be used to perform the repair. Others used a

transeptal technique, relying on a posterolateral visualizing portal and a posteromedial portal for instrumentation.¹⁰ Morgan¹¹ described the first all-inside suture technique from the posteromedial portal through a cannula, with technical challenges in manipulating a suture hook through the cannula and a greater risk of articular cartilage damage.

Surgeons using posteromedial portals argue that they allow better visualization of the extent of the tear, more adequate preparation of the edges, and easier

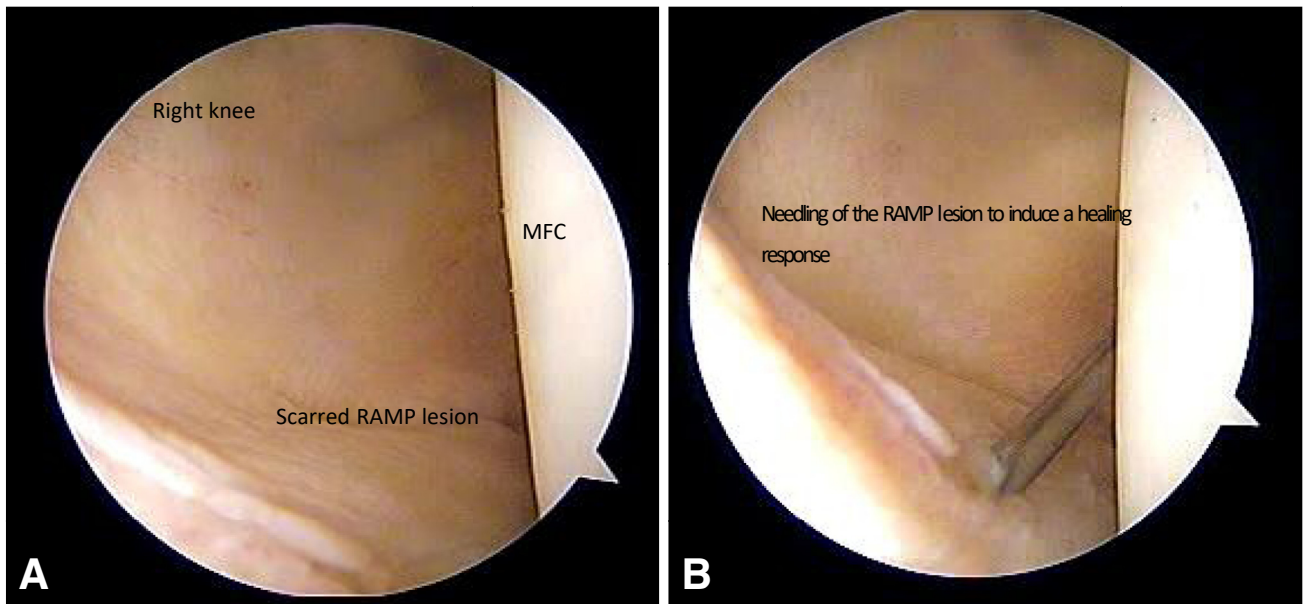


Fig 4. (A) Arthroscopic posteromedial view of the right knee showing a stable, scarred ramp lesion. (B) Arthroscopic posteromedial view showing needling of ramp lesion. (MFC, medial femoral condyle.)

maneuvering and repair in a vertical fashion at right angles to the circumferentially oriented deep meniscal fibers and, hence, a more biomechanically robust repair.¹² Furthermore, some hidden lesions are only seen and appreciated when inspecting the ramp area from posteromedial portals.¹³

Thaunat et al.¹⁴ and Ahn et al.⁷ demonstrated that ramp lesion repair using posteromedial portals during ACL reconstruction yields high healing rates. Furthermore, Ahn et al.¹⁵ stress the importance of an acute repair, because the inferior displacement of the peripheral fragment renders it difficult to heal.

In contrast, posterior portals risk injuring cartilage of the posterior aspect of femoral condyles; however,

many believe this to be a non-weight-bearing area and do not give much weight to this concern. Posterior portals demand more experience, skills, instruments, and time, and they also carry risk of neurovascular injury, unjustified by the benefits they offer.⁴

The techniques described herein allow easy, convenient, and reliable repair of ramp lesions through standard anterior portals using the FAST-FIX 360 Meniscal Repair System without the need for posteromedial portals, avoiding risk of articular cartilage damage and time loss. Light is currently shed on meniscal ramp lesions. Awareness of inspecting for such lesions and attempting an acute repair with ACL reconstruction provides the best healing rates. There are many different ways to repair ramp lesions. Surgeons must be mindful of the versatility, pros, and risks of each. All-inside repair of ramp lesions through standard anterior portals could be done using different techniques. It avoids the hazards of posterior knee portals yet allows for adequate and precise repair.

Table 1. Pearls and Pitfalls of the Techniques Described

Pearls	Pitfalls
Visualization of the tear is improved with internal and external rotation maneuver of the tibia.	Looking for a ramp lesion at the end of the procedure.
The use of a 70° lens improves defining the extent of the tear and suture placement.	Keeping the needle of the Fast-Fix at 25 mm risks penetration of posterior vessels.
The choice of suture configuration to use relies on the tear pattern, size, and quality of meniscal tissue.	Using inadequate number of sutures to hold the repair which eventually fails.
Repair is best performed at the same time of ACL reconstruction, before drilling the ACL tunnels.	

ACL, anterior cruciate ligament.

Table 2. Advantages and Disadvantages of Ramp Lesion Repair Using Standard Anterior Portals

Advantages	Disadvantages
Easy technique, fewer instruments required	Less accurate in determining the extent of the tear (inferior visualization)
Quick, less time-consuming	Risk of cartilage injury in tight medial compartment
Reproducible	May require medial release
Less associated morbidity	Damage to the light source with inexperience and tight knees with narrow notch

References

1. Chahla J, Dean CS, Moatshe G, et al. Meniscal ramp lesions. *Orthop J Sport Med* 2016;4. 232596711665781.
2. Papastergiou SG, Koukoulis NE, Mikalef P, Ziogas E, Voulgaropoulos H. Meniscal tears in the ACL-deficient knee: Correlation between meniscal tears and the timing of ACL reconstruction. *Knee Surg Sport Traumatol Arthrosc* 2007;15:1438-1444.
3. Zoller SD, Toy KA, Wang P, Ebrahimzadeh E, Bowen RE. Temporal relation of meniscal tear incidence, severity, and outcome scores in adolescents undergoing anterior cruciate ligament reconstruction. *Knee Surg Sport Traumatol Arthrosc* 2017;25:215-221.
4. Stephen JM, Halewood C, Kittl C, Bollen SR, Williams A, Amis AA. Posteromedial meniscocapsular lesions increase tibiofemoral joint laxity with anterior cruciate ligament deficiency, and their repair reduces laxity. *Am J Sports Med* 2016;44:400-408.
5. Liu X, Zhang H, Feng H, Hong L, Wang X, Song G. Is it necessary to repair stable ramp lesions of the medial meniscus during anterior cruciate ligament reconstruction? A prospective randomized controlled trial. *Am J Sports Med* 2017;45:1004-1011.
6. Li W-P, Chen Z, Song B, Yang R, Tan W. The FasT-Fix repair technique for ramp lesion of the medial meniscus. *Knee Surg Relat Res* 2015;27:56-60.
7. Shelbourne KD, Rask BP. The sequelae of salvaged non-degenerative peripheral vertical medial meniscus tears with anterior cruciate ligament reconstruction. *Arthroscopy* 2001;17:270-274.
8. Liu X, Feng H, Zhang H, Hong L, Wang XS, Zhang J. Arthroscopic prevalence of ramp lesion in 868 patients with anterior cruciate ligament injury. *Am J Sports Med* 2011;39:832-837.
9. Ahn JH, Kim SH, Yoo JCWJ. All-inside suture technique using two posteromedial portals in a medial meniscus posterior horn tear. *Arthroscopy* 2004;20:101-108.
10. Buyukdogan K, Laidlaw MS, Miller MD. Meniscal ramp lesion repair by a trans-septal portal technique. *Arthrosc Tech* 2017;6:e1379-e1386.
11. Morgan CD. The "all-inside" meniscus repair. *Arthroscopy* 1991;7:120-125.
12. Buckland M, Sadoghi D, Wimmer P, et al. Meta-analysis on biomechanical properties of meniscus repairs: Are devices better than sutures? *Knee Surg Sports Traumatol Arthrosc* 2015;23:83-89.
13. Rodeo SA. Arthroscopic meniscal repair with use of the outside-in technique. *Instr Course Lect* 2000;49:195-206.
14. Thaunat M, Jan N, Fayard JM, et al. Repair of meniscal ramp lesions through a posteromedial portal during anterior cruciate ligament reconstruction: Outcome study with a minimum 2-year follow-up. *Arthroscopy* 2016;32:2269-2277.
15. Ahn JH, Wang JH, Yoo JC. Arthroscopic all-inside suture repair of medial meniscus lesion in anterior cruciate ligament-deficient knees: Results of second-look arthroscopies in 39 cases. *Arthroscopy* 2004;20:936-945.