

## Positional change of the condyle after orthodontic-orthognathic surgical treatment: is there a relationship to skeletal relapse?

Husanov Zafar<sup>1</sup>, Dong-Soon Choi<sup>1,2</sup>, Insan Jang<sup>1,2</sup>, Bong-Kuen Cha<sup>1,2</sup>, Young-Wook Park<sup>3</sup>

<sup>1</sup>Department of Orthodontics, College of Dentistry, Gangneung-Wonju National University,

<sup>2</sup>Research Institute for Dental Engineering, Gangneung-Wonju National University,

<sup>3</sup>Department of Oral and Maxillofacial Surgery, College of Dentistry, Gangneung-Wonju National University, Gangneung, Korea

**Abstract** (J Korean Assoc Oral Maxillofac Surg 2014;40:160-168)

**Objectives:** The purpose of this study was to evaluate the condylar position in relation to the glenoid fossa before and after orthodontic-orthognathic surgical treatment and to investigate the relationship with skeletal relapse.

**Materials and Methods:** Lateral cephalograms and temporomandibular joint tomograms from 19 patients with mandibular prognathism who received orthodontic-orthognathic surgery were included in this study. Samples were divided into two groups based on skeletal change during the retention period. The relapse group consisted of 7 patients (3 females and 4 males; mean age, 21.9 years) whose pogonion or menton displaced more than 1 mm during the retention period and the stable group consisted of 12 patients (5 females and 7 males; mean age, 21.7 years). Anterior joint space, posterior joint space, superior joint space, and anteroposterior index were measured on tomograms at pretreatment and posttreatment timepoints. Condyle position and frequency of the positional change were compared between both groups.

**Results:** In the relapse group and stable group, 42.9% and 45.8% of the condyles, respectively, showed forward or backward displacement at post-treatment. However, the changes were small and the mean anterior, posterior, superior joint spaces and frequencies of the positional changes did not differ statistically between both groups.

**Conclusion:** Our results suggest that small positional changes of the condyle, which may occur after orthodontic-orthognathic surgery treatment, may not be related to skeletal relapse after removal of the orthodontic appliances.

**Key words:** Mandibular condyle, Malocclusion, Orthognathic surgery, Temporomandibular joint

[paper submitted 2014. 4. 2 / revised 1st 2014. 5. 13, 2nd 2014. 6. 3 / accepted 2014. 6. 4]

### I. Introduction

Orthodontic treatment alone is not sufficient to resolve severe skeletal malocclusion. Orthopedic treatment in children and orthognathic surgery in adults are needed to overcome the skeletal discrepancy and improve facial esthetics. Orthognathic surgery for Class III malocclusion with mandibular prognathism is not recommended for growing children for

posttreatment stability. However, relapse occurs occasionally even if surgery is performed in adulthood. Relapse after orthognathic surgery can be multifactorial<sup>1-3</sup> including factors such as preoperative age of the patient<sup>4</sup>, amount of mandibular setback<sup>5,6</sup>, direction of bony fragment movement<sup>7</sup>, skill of the surgeon<sup>8,9</sup>, soft tissue and muscular tension<sup>10-12</sup>, quality of orthodontic treatment<sup>5,6</sup>, and postoperative orthodontic retention<sup>4</sup>.

Early relapse or short-term relapse, which occurs at 6-8 postoperative weeks, is mostly caused by movements at the osteotomy site or sagging of the temporomandibular joint (TMJ)<sup>2</sup>. It has been reported that proximal segment rotation during surgery was associated with instability after mandibular setback<sup>6,13</sup>. Kawamata et al.<sup>14</sup> who evaluated the postsurgical condylar displacement at 3 to 6 months after mandibular osteotomy in Class III patients reported that changes in the inclination of the condylar axis were distinctly seen, although

#### *Dong-Soon Choi*

Department of Orthodontics, Gangneung-Wonju National University Dental Hospital, 7 Jukheon-gil, Gangneung 210-702, Korea  
TEL: +82-33-640-2759 FAX: +82-33-640-3057  
E-mail: dschoi@gwnu.ac.kr

© This is an open-access article distributed under the terms of the Creative Commons Attribution Non-Commercial License (<http://creativecommons.org/licenses/by-nc/3.0/>), which permits unrestricted non-commercial use, distribution, and reproduction in any medium, provided the original work is properly cited.

Copyright © 2014 The Korean Association of Oral and Maxillofacial Surgeons. All rights reserved.

This study was supported by the 2012 research fund of Gangneung-Wonju National University Dental Hospital (2012-0142).

changes in the position of the condyles within the joints were minimal. Lee and Park<sup>15</sup> investigated 30 Class III malocclusion patients who received sagittal split ramus osteotomy (SSRO) and reported that the condyle tends to move inferiorly and rotate inward on the axial view and backward on the sagittal view at 1 month after surgery. Ueki et al.<sup>16</sup> also reported condylar rotation seen on horizontal axial images after surgery for mandibular prognathism.

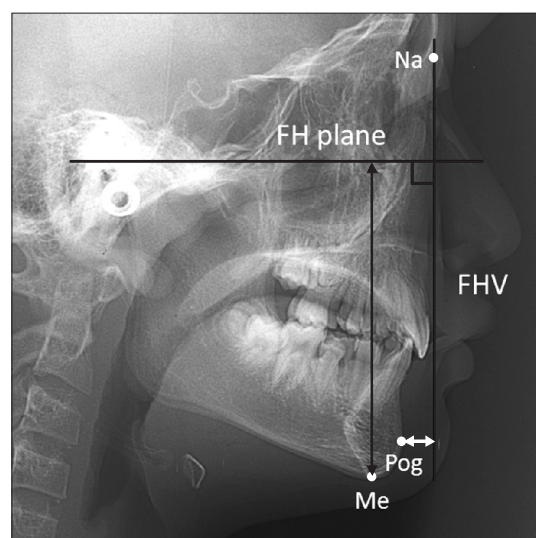
Positional and angular change of the condyle could occur immediately after orthognathic surgery. The goals of post-surgical orthodontic treatment are to settle the occlusion on the new skeletal position and to cope with immediate skeletal relapse. However, if the condyle position is not stable at the time of bracket debonding, late relapse can be expected to occur. Jakobson et al.<sup>17</sup> reported that most of the relapse after the mandibular setback occurred during the first 6 months, but some relapse was also observed between 1 and 3 years postoperatively. According to a recent study by Ueki et al.<sup>18</sup>, the postoperative anterior joint space (AJS) was significantly larger than the preoperative value after assessment at 1 year after surgery in the 87 mandibular prognathism patients.

However, there is little evidence to determine whether the condyle position is stable or displaced at the time of debonding, and if there is a relation to late skeletal relapse. Most previous studies that investigated the change of condyle position focused on the surgical method and/or fixation type<sup>14,16,19,20</sup>, asymmetry<sup>18,21</sup>, one-jaw or two-jaw surgery<sup>6,20,22</sup>, and improvement of TMJ disorder<sup>16,22</sup>. However, these studies lacked a cephalometric analysis, and therefore could not provide information regarding skeletal relapse after removal of orthodontic appliances. Recently, in a study using a cone-beam computed tomography, Kim et al.<sup>23,24</sup> reported that the condyle moved from the anterior to the concentric position after surgery and tended to return slightly toward the original position at 17 months after surgery. They also concluded that these changes did not negatively affect the skeletal stability. However, in their studies, the relationship between the condy-

lar position at debonding time and skeletal relapse during the postretention period could not be clearly explained. This is due to the fact that the statistical mean applied in their studies is highly misleading as an expectation of treatment response. The best way to represent the data is in terms of percentage of the patients who showed a stable result or relapse<sup>25</sup>. The purpose of this study was to investigate the positional change of the condyle after orthodontic-orthognathic surgery treatment and the relationship with skeletal relapse.

## II. Materials and Methods

Samples were selected from patient records who received orthodontic-orthognathic surgery treatment at Gangneung-Wonju National University Dental Hospital from 2004 to 2009. Samples used in this retrospective study were TMJ tomograms taken before treatment (T1) and immediately



**Fig. 1.** Cephalometric measurements. Me to FH plane and Pog to FHV. Refer to Table 1 for the definitions of landmarks.

Husanov Zafar et al: Positional change of the condyle after orthodontic-orthognathic surgical treatment: is there a relationship to skeletal relapse? *J Korean Assoc Oral Maxillofac Surg* 2014

**Table 1.** Lateral cephalometric landmarks (points) and reference plane

Landmark	Original term	Definition
Na	Nasion	The most anterior point of the nasofrontal suture
Me	Menton	The most inferior point on the symphysis of the mandible
Pog	Pogonion	The most anterior point on the symphysis of the mandible
Po	Porion	The highest point on the superior surface of the external auditory meatus
Or	Orbitale	The lowest point on the averaged outline of the orbital rims
FH plane	Frankfort horizontal plane	The plane constructed by Po and Or
FHV		The line drawn from nasion and perpendicular to Frankfort horizontal plane

Husanov Zafar et al: Positional change of the condyle after orthodontic-orthognathic surgical treatment: is there a relationship to skeletal relapse? *J Korean Assoc Oral Maxillofac Surg* 2014

after the removal of the orthodontic appliances (T2), and lateral cephalograms at T1, T2, and at the retention period (T3). Inclusion criteria were as follows: (1) patients who had mandibular prognathism and received mandibular set-back surgery with SSRO, (2) patients with no TMJ disorders before treatment, (3) patients successfully treated with normal overjet and occlusion, and (4) patients with good quality of TMJ tomograms at T1 and T2, and cephalograms at T1, T2, and T3.

Finally, tomograms and cephalograms of 19 patients were selected for the present study. Seven patients received only mandibular set-back surgery and 12 patients received bimaxillary orthognathic surgery. The protocols of this study were approved by the Ethics Committee of the Gangneung-Wonju National University Dental Hospital (IRB 2010-1-3).

### 1. Cephalogram analysis

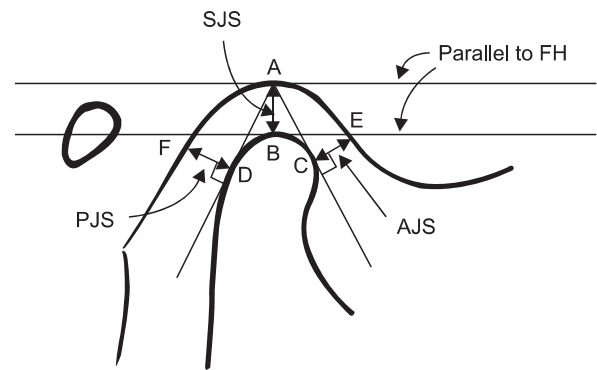
Lateral cephalograms taken in the habitual occlusion with the CX-90SP (Asahi Roentgen Industries Co., Kyoto, Japan) were traced on acetate paper to obtain measurements. Cephalograms at T2 and T3 were superimposed on sella-nasion line at sella. The distance from the menton (Me) to Frankfort horizontal (FH) plane, and the distance from pogonion (Pog) to the vertical reference line passing nasion and perpendicular to FH plane (FHV) were measured. (Table 1, Fig. 1) All measurements were read to a 0.01 mm scale and the radiographic magnifications (110%) were corrected to 100%.

Patients were divided into stable and relapse groups. The patients who showed skeletal changes more than 1 mm in the distance of Me to FH and/or Pog to FHV between T2 and T3 were classified in the relapse group. The relapse group consisted of 7 patients (3 females and 4 males; mean age, 21.9 years). The stable group consisted of 12 patients (5 females and 7 males; mean age, 21.7 years). Sample description and

mean duration of the record is summarized in Table 2.

### 2. TMJ tomogram analysis

Individualized corrected TMJ tomogram was taken using CommCAT IS-2000 (Imaging Sciences International, Hatfield, PA, USA) while maintaining the FH plane of the patient parallel to the horizontal plane. To determine the long axis of the mandibular condyle, submentovortex radiography was used. The selected sections of the tomogram were traced using acetate paper and pencil. The distance of the condyle to the temporal fossa was measured in the AJS, posterior joint space (PJS), and superior joint space (SJS) as described in Fig. 2.



**Fig. 2.** Tracing of temporomandibular joint tomogram to evaluate superior joint space (SJS), anterior joint space (AJS), and posterior joint space (PJS). (FH: Frankfort horizontal, A: the most superior point of the glenoid fossa, B: the most superior point of the condyle, C: tangent to the anterior surface of condyle from point A, D: tangent to the posterior surface of condyle from point A, E: intersection point perpendicular to A-C line from point C and anterior slope of the glenoid fossa, F: intersection point between the point perpendicular to A-D line from point D and the posterior slope of glenoid fossa)

Husanov Zafar et al: Positional change of the condyle after orthodontic-orthognathic surgical treatment: is there a relationship to skeletal relapse? J Korean Assoc Oral Maxillofac Surg 2014

**Table 2.** Sample description

Variable	Stable group (n=12)	Relapse group (n=7)	P-value <sup>1</sup>	Significance
Age at T1 (yr)	21.7±5.9	21.9±3.2	0.902	NS
ANB at T1 (°)	-2.6±2.5	-0.9±4.3	0.650	NS
Amount of mandibular set-back (mm)	7.0±2.7	7.4±2.9	1.000	NS
Duration of postsurgical orthodontic treatment (mo)	7.3±3.0	10.5±3.9	0.045	*
Duration of total treatment (T1-T2) (mo)	22.7±6.7	30.0±7.7	0.068	NS
Duration of retention period (T2-T3) (mo)	12.8±4.1	18.6±10.8	0.196	NS

(T1: pretreatment, T2: posttreatment, T3: postretention, ANB: A point-nasion-B point angle, NS: not significant)

\*P<0.05.

<sup>1</sup>P-values by Mann-Whitney U test.

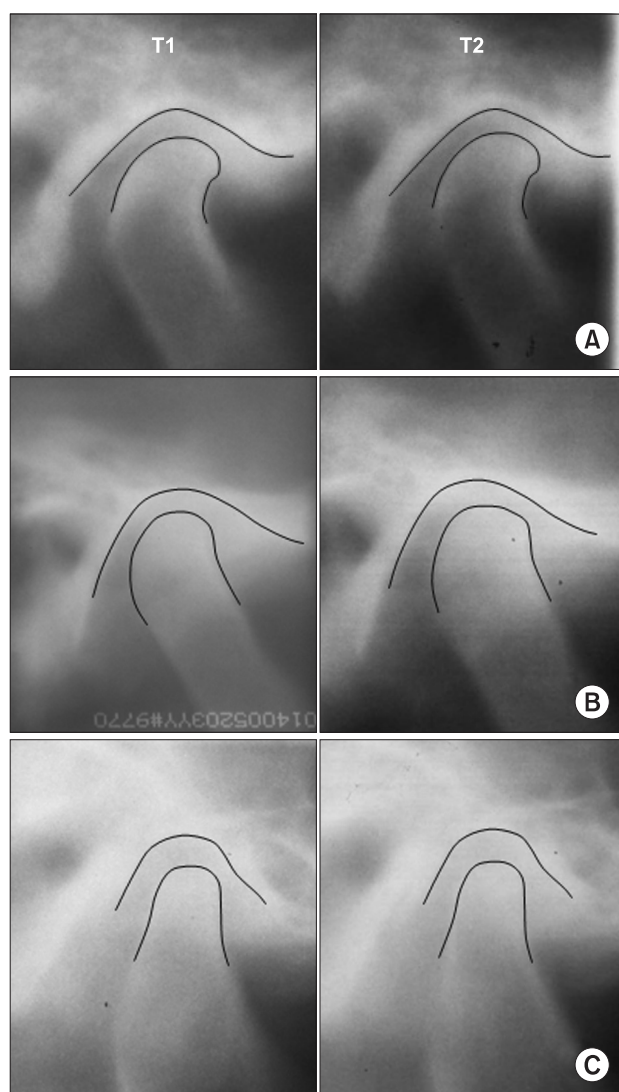
Values are presented as mean±standard deviation.

Husanov Zafar et al: Positional change of the condyle after orthodontic-orthognathic surgical treatment: is there a relationship to skeletal relapse? J Korean Assoc Oral Maxillofac Surg 2014

**Table 3.** The pattern of positional change of the condyle

Positional change	Pattern	Definition
Unchanged	A-A	No change of the condylar position from its original anterior position
	C-C	No change of the condylar position from its original concentric position
	P-P	No change of the condylar position from its original posterior position
Backward movement	A-C	Change of the condylar position from the anterior position to the concentric position
	C-P	Change of the condylar position from the concentric position to the posterior position
	A-P	Change of the condylar position from the anterior position to the posterior position
Forward movement	C-A	Change of the condylar position from the concentric position to the anterior position
	P-C	Change of the condylar position from the posterior position to the concentric position
	P-A	Change of the condylar position from the posterior position to the anterior position

Husanov Zafar et al: Positional change of the condyle after orthodontic-orthognathic surgical treatment: is there a relationship to skeletal relapse? J Korean Assoc Oral Maxillofac Surg 2014



**Fig. 3.** Temporomandibular joint tomograms at pretreatment (T1) and posttreatment (T2) showing three patterns of positional changes of the condyle. A. C-C pattern (unchanged). B. C-A pattern (forward movement). C. A-C pattern (backward movement). Refer to Table 3 for the definitions of patterns.

Husanov Zafar et al: Positional change of the condyle after orthodontic-orthognathic surgical treatment: is there a relationship to skeletal relapse? J Korean Assoc Oral Maxillofac Surg 2014

Measurements were read at the 0.01 mm scale and the radiographic magnification (126%) was corrected. Anteroposterior index (API) was calculated to define the position of the condyle to the temporal fossa as reported by Pullinger and Hollender<sup>26</sup>.

$$API = (PJS - AJS) / (PJS + AJS) \times 100$$

API between -12 and +12 was defined as concentric position, more than +12 as anterior position, and less than -12 as posterior position. Positional change of the condyle between T1 and T2 was classified as unchanged, backward displacement, and forward displacement as described in Table 3. Three different patterns of condyle change are shown in Fig. 3.

### 3. Statistical analysis

Normal distribution of the measurements was confirmed by the Shapiro-Wilk test. Because the measurements did not show normal distribution, nonparametric tests were used. The Mann-Whitney U test was used to verify the difference between the two groups. Spearman correlation analysis was used to determine the relationship between skeletal relapse and condylar changes. Additionally, the chi-square test was used to determine differences in the frequency of the pattern of condylar positional change between the groups. The statistical significance was determined at the 5% level of confidence. All statistical analyses were performed with IBM SPSS Statistics 20.0 (IBM Co., Armonk, NY, USA).

## III. Results

Table 4 shows the group differences in the skeletal changes during the retention period (T3-T2). The Pog to FHV and Me to FH was not significantly different at posttreatment (T2) between the groups. However, the mean absolute value of the difference of Pog to FHV (T3-T2) was 0.6 mm in the stable

**Table 4.** Comparison of chin position between the groups (mm)

Chin position	Posttreatment (T2)			Postretention (T3)			Difference (T3-T2) <sup>1</sup>		
	Stable	Relapse	P-value	Stable	Relapse	P-value	Stable	Relapse	P-value
Pog to FHV	2.0±6.8	1.2±8.7	0.902	1.9±6.7	2.1±8.2	0.837	0.6±0.3	1.2±0.2	0.001*
Me to FH	92.3±5.5	97.3±9.1	0.142	92.5±5.4	97.3±9.8	0.167	0.5±0.3	1.2±0.8	0.017*

<sup>1</sup>Absolute value.

\*P<0.05.

Values are presented as mean±standard deviation.

Refer to Table 1 for the definitions of landmarks.

Husanov Zafar et al: Positional change of the condyle after orthodontic-orthognathic surgical treatment: is there a relationship to skeletal relapse? J Korean Assoc Oral Maxillofac Surg 2014

**Table 5.** Comparison of joint space at pretreatment (T1), posttreatment (T2), and joint space change (T2-T1)

Joint space		Stable group (n=12)	Relapse group (n=7)	P-value <sup>1</sup>	Significance
Right	T1				
	AJS (mm)	1.8±0.7	1.7±0.6	0.902	NS
	PJS (mm)	2.2±0.7	2.0±0.3	0.536	NS
	SJS (mm)	2.3±0.6	2.4±0.7	0.773	NS
	API <sup>2</sup>	11.4±17.0	8.7±16.4	0.902	NS
	T2				
	AJS (mm)	2.1±1.0	1.8±0.9	0.432	NS
	PJS (mm)	2.4±0.6	2.2±0.7	0.482	NS
	SJS (mm)	2.5±0.4	2.8±1.5	0.536	NS
	API <sup>2</sup>	9.4±23.0	13.5±19.9	0.650	NS
	T2-T1				
	ΔAJS (mm)	0.2±0.7	0.0±0.6	0.536	NS
	ΔPJS (mm)	0.1±0.7	0.2±0.6	0.711	NS
	ΔSJS (mm)	0.2±0.5	0.4±0.9	1.000	NS
ΔAPI <sup>2</sup>	-2.0±21.3	4.9±20.7	0.592	NS	
Left	T1				
	AJS (mm)	2.3±1.2	1.7±0.6	0.536	NS
	PJS (mm)	2.2±1.1	2.4±0.8	0.432	NS
	SJS (mm)	2.9±1.5	2.3±0.5	0.592	NS
	API <sup>2</sup>	-0.1±19.9	15.7±16.3	0.142	NS
	T2				
	AJS (mm)	2.6±1.3	1.8±0.7	0.120	NS
	PJS (mm)	1.8±0.7	2.1±0.7	0.384	NS
	SJS (mm)	2.7±0.9	2.3±0.6	0.299	NS
	API <sup>2</sup>	-13.4±24.0	7.1±18.7	0.120	NS
	T2-T1				
	ΔAJS (mm)	0.3±0.7	0.1±0.2	0.299	NS
	ΔPJS (mm)	-0.4±1.1	-0.3±0.3	0.967	NS
	ΔSJS (mm)	-0.2±1.1	-0.1±0.6	0.837	NS
ΔAPI <sup>2</sup>	-13.3±17.6	-8.6±10.3	0.299	NS	

(AJS: anterior joint space, PJS: posterior joint space, SJS: superior joint space, API: anteroposterior index, NS: not significant)

<sup>1</sup>P-values by Mann-Whitney U test.

<sup>2</sup>API=(PJS-AJS)/(PJS+AJS)×100.

Values are presented as mean±standard deviation.

Husanov Zafar et al: Positional change of the condyle after orthodontic-orthognathic surgical treatment: is there a relationship to skeletal relapse? J Korean Assoc Oral Maxillofac Surg 2014

group and 1.2 mm in the relapse group. The Me to FH (T3-T2) was 0.5 mm in the stable group and 1.2 mm in the relapse group.

Table 5 shows the distance of the joint space (AJS, PJS, SJS) and API of the stable group and the relapse group at T1 and T2. The position of the condyle was generally concentric to the glenoid fossa. Although the API of the left condyle indicated a slight anterior position at T1 in the relapse group

(API=15.7) and slight posterior position at T2 in the stable group (API=-13.4), the difference was not statistically significant between the groups (P>0.05).

Table 5 also shows a change of the joint space from T1 to T2. Negative values of API mean backward displacement of the condyle to the glenoid fossa. The condyles of the left side showed slight backward movement from T1 to T2 in both groups. However, the change of the condyle position was not

**Table 6.** Spearman correlation analysis of the change in chin position and position of the condyle

Joint space		$\Delta$ Pog to FHV (T3-T2)		$\Delta$ Me to FH (T3-T2)	
		r	P-value	r	P-value
Right	T1				
	AJS	-0.054	0.825	0.352	0.140
	PJS	0.349	0.143	0.011	0.966
	SJS	0.216	0.375	0.158	0.519
	API <sup>1</sup>	0.130	0.596	-0.179	0.464
	T2				
	AJS	0.128	0.601	0.174	0.477
	PJS	0.104	0.673	0.284	0.238
	SJS	0.012	0.960	0.233	0.336
	API <sup>1</sup>	-0.047	0.847	-0.007	0.977
	T2-T1				
	$\Delta$ AJS	0.284	0.238	0.119	0.627
	$\Delta$ PJS	-0.160	0.514	0.089	0.716
	$\Delta$ SJS	0.016	0.949	0.296	0.218
Left	T1				
	AJS	0.028	0.909	-0.025	0.920
	PJS	0.293	0.223	-0.016	0.949
	SJS	0.046	0.853	-0.049	0.842
	API <sup>1</sup>	0.232	0.340	0.018	0.943
	T2				
	AJS	-0.091	0.710	-0.149	0.542
	PJS	0.245	0.312	0.041	0.867
	SJS	-0.051	0.836	0.018	0.943
	API <sup>1</sup>	0.068	0.783	0.064	0.794
	T2-T1				
	$\Delta$ AJS	-0.007	0.977	-0.088	0.721
	$\Delta$ PJS	-0.049	0.842	0.061	0.803
	$\Delta$ SJS	0.040	0.870	0.177	0.468

(T1: pretreatment, T2: posttreatment, T3: postretention, AJS: anterior joint space, PJS: posterior joint space, SJS: superior joint space, API: anteroposterior index)

<sup>1</sup>API=(PJS-AJS)/(PJS+AJS)×100.

Refer to Table 1 for the definitions of landmarks.

Husanov Zafar et al: Positional change of the condyle after orthodontic-orthognathic surgical treatment: is there a relationship to skeletal relapse? J Korean Assoc Oral Maxillofac Surg 2014

significantly different between the groups ( $P>0.05$ ).

In the Spearman correlation analysis, no correlation was found between the change of chin position during the retention period and the position of the condyle at T1 and T2 ( $P>0.05$ ). (Table 6)

The frequencies of the positional change of the condyle from T1 to T2 are shown in Table 7. The positions of 13 out of 24 condyles (54.2%) in the stable group and 8 out of 14 condyles (57.1%) in the relapse group were not changed from their original position after treatment. Backward movement occurred in 8 condyles (33.3%) in the stable group and 3 condyles (21.4%) in the relapse group, and patterns were A-C and C-P. There was no A-P pattern with backward changes. Forward movement occurred on 3 condyles (12.5%) in the stable group and 3 condyles (21.4%) in the relapse group.

**Table 7.** Chi-square test of the patterns of positional change of the condyle between the groups

Positional change	Pattern	Stable group (n=24)	Relapse group (n=14)
Unchanged	A-A	5 (20.8)	3 (21.4)
	C-C	4 (16.7)	5 (35.7)
	P-P	4 (16.7)	0
Backward movement	A-C	5 (20.8)	2 (14.3)
	C-P	3 (12.5)	1 (7.1)
	A-P	0	0
Forward movement	C-A	3 (12.5)	2 (14.3)
	P-C	0	0
	P-A	0	1 (7.1)

Refer to Table 3 for the definitions of patterns.

Values are presented as number (%).

$P=0.438$

Husanov Zafar et al: Positional change of the condyle after orthodontic-orthognathic surgical treatment: is there a relationship to skeletal relapse? J Korean Assoc Oral Maxillofac Surg 2014

One P-A pattern of condyle movement was observed in the relapse group. No P-C patterns of condyle movement were found. The chi-square test, however, showed that frequencies of the pattern of positional change of the condyle were not statistically different between the groups ( $P=0.438$ ).

#### IV. Discussion

Among the many factors affecting relapses after orthognathic surgery, we focused on the condyle position after bilateral SSRO for the mandibular set-back and evaluated the relation between condyle position and skeletal relapse. The preoperative age of the patients, A point-nasion-B point (ANB) angle, chin position at T1, and amount of mandibular set-back did not significantly differ between the stable group and the relapse group (Tables 2, 3), which means sample homogeneity between both groups. However, a different duration of the records (T1-T2 and T2-T3) between both groups and large standard deviation can be considered a weak point of this study, although the statistical evaluation showed no significance. It is interesting that the relapse group showed longer post-surgical orthodontic treatment than the stable group.

Some statistic measurements can be misleading, as true relapse can occur only in some cases and significant results can be distributed among groups. Proffit et al.<sup>7</sup> reported that in both the postsurgical and posttreatment periods, almost all changes occur in a minority of patients, so it is better to consider the percentage of patients with clinically significant changes than to compare the mean value of the differences. Using ANOVA to analyze means, it can be concluded that

not grouping according the treatment response is a potential weak point of previous studies<sup>23,24</sup> on the long-term evaluation of the condyle change and skeletal stability. In the present study, we divided the samples based on treatment response, such as stable group and relapse group, and therefore a change of the condyle could be evaluated in both groups respectively. However, the mean positional change of the condyle was not different between the groups. In the chi-square test, the frequencies of the changing pattern did not differ between the groups.

In the present study, we could not find any relationship between the positional change of the condyle after orthodontic-orthognathic surgery treatment (T2-T1) and skeletal relapse during the retention period (T3-T2). One reason for a failure to identify a relationship may be the small sample size in the relapse group and severe criteria to define an episode of relapse. Only 1 out of 7 patients showed more than 2 mm at the distance of the Me to FH plane, while the other 6 patients included in the relapse group showed a small change of the chin area (range: 1 to 2 mm). Other classifications based on larger skeletal relapse may indicate significant differences between the stable and relapse groups. In the present study, however, it was difficult to collect relapse samples showing skeletal relapse more than 2 or 3 mm during the retention period that satisfied the inclusion criteria. Therefore, our results should be interpreted cautiously only in patients showing small skeletal relapse during retention periods.

In the relapse group, the number of patients with forward, backward, downward, and upward movement of the chin between T2 and T3 was 5, 1, 2, and 2 patients, respectively. In the present study, we could not investigate the results according to the subdivision based on the direction of skeletal relapse due to the small sample size. In future research, detailed classification based on the direction of skeletal change and a less strict definition of skeletal relapse may be needed to clarify the association between the positional change of the condyle and skeletal relapse.

It is interesting that approximately half of the condyles still showed forward or backward displacement at the posttreatment timepoint in both groups (45.8% for stable group and 42.8% for relapse group), even though 7 to 10 months on average of postsurgical orthodontic treatment was applied. (Table 7) Moreover, diverse patterns of positional change were observed. Many researchers also reported that condyle position changes on occasion after orthognathic surgery<sup>27-29</sup> and maintaining the condylar position in its own position

after orthognathic surgery is very important to reduce relapse and the risk of TMJ disorders<sup>30-33</sup>. To prevent positional changes of the condyle after surgery, several condylar positioning devices have been proposed, but use of condylar positioning devices did not provide better functional and long-term outcomes<sup>8,34</sup>. By this reasoning, most surgeons still rely on empirical methods to reposition the mandibular proximal segment during SSRO to obtain the most favorable condylar position<sup>8,9,35</sup>.

Ueki et al.<sup>9</sup> concluded that the most favorable postoperative condylar position may not match the preoperative one, but would not be dramatically different except for cases of temporomandibular disorder (TMD) or asymmetry. In the ideal postoperative position of the condyle, remodeling of the TMJ induced by postoperative biomechanical stress would be small<sup>9,36,37</sup>. Kim et al.<sup>23</sup> concluded that physiologic adaptation can accommodate small changes in the condylar position and this would be followed either by later skeletal relapse or condylar remodeling. Regarding specific manifestations of TMD signs and symptoms, this depends on the individual physiologic adaptation capacity of the patient. All patients in the present study did not show any TMD signs or symptoms after orthognathic surgery and during follow-up periods.

In the present study, we could not evaluate the condyle position immediately following orthognathic surgery and postretention period because TMJ tomograms were not taken at that time due to exposure to radiation and high cost. Therefore, it is unclear whether the condylar position changed during the postretention period in the relapse group. Additionally, mixed samples, including 2-jaw and 1-jaw surgery and possible residual mandibular growth after orthognathic surgery, might affect the results of this study. The possibility of rotation of the proximal segment, which can occur after orthognathic surgery, and its relation to late skeletal relapse after removal of orthodontic appliances remains to be investigated.

## V. Conclusion

The present study investigated the condyle position of the patients who received orthodontic-orthognathic surgery for mandibular prognathism and compared it between stable and relapse groups.

- More than 40% of the condyles showed positional change at posttreatment (T2) in both stable and relapse groups.
- However, the changes of the condyle position (T2-T1)

were small and did not statistically differ between stable group and relapse group.

- Our results suggest that small positional changes of the condyle, which may occur after orthodontic-orthognathic surgery, are not related to skeletal relapse after removal of orthodontic appliances.

### Conflict of Interest

No potential conflict of interest relevant to this article was reported.

### References

1. Wolford LM. The sagittal split ramus osteotomy as the preferred treatment for mandibular prognathism. *J Oral Maxillofac Surg* 2000;58:310-2.
2. Hoffmannová J, Foltán R, Vlk M, Klíma K, Pavlíková G, Bulik O. Factors affecting the stability of bilateral sagittal split osteotomy of a mandible. *Prague Med Rep* 2008;109:286-97.
3. Costa F, Robiony M, Politi M. Stability of sagittal split ramus osteotomy used to correct Class III malocclusion: review of the literature. *Int J Adult Orthodon Orthognath Surg* 2001;16:121-9.
4. Villegas C, Oberti G, Jimenez I, Franchi L, Baccetti T. Early orthognathic surgery in growing Class III patients. *J Clin Orthod* 2010;44:651-64.
5. Kobayashi T, Watanabe I, Ueda K, Nakajima T. Stability of the mandible after sagittal ramus osteotomy for correction of prognathism. *J Oral Maxillofac Surg* 1986;44:693-7.
6. Franco JE, Van Sickels JE, Thrash WJ. Factors contributing to relapse in rigidly fixed mandibular setbacks. *J Oral Maxillofac Surg* 1989;47:451-6.
7. Proffit WR, Turvey TA, Phillips C. The hierarchy of stability and predictability in orthognathic surgery with rigid fixation: an update and extension. *Head Face Med* 2007;3:21.
8. Costa F, Robiony M, Toro C, Sembronio S, Polini F, Politi M. Condylar positioning devices for orthognathic surgery: a literature review. *Oral Surg Oral Med Oral Pathol Oral Radiol Endod* 2008;106:179-90.
9. Ueki K, Moroi A, Sotobori M, Ishihara Y, Marukawa K, Takatsuka S, et al. A hypothesis on the desired postoperative position of the condyle in orthognathic surgery: a review. *Oral Surg Oral Med Oral Pathol Oral Radiol* 2012;114:567-76.
10. Epker BN, Wessberg GA. Mechanisms of early skeletal release following surgical advancement of the mandible. *Br J Oral Surg* 1982;20:175-82.
11. Bailey LJ, Collie FM, White RP Jr. Long-term soft tissue changes after orthognathic surgery. *Int J Adult Orthodon Orthognath Surg* 1996;11:7-18.
12. Mihalik CA, Proffit WR, Phillips C. Long-term follow-up of Class II adults treated with orthodontic camouflage: a comparison with orthognathic surgery outcomes. *Am J Orthod Dentofacial Orthop* 2003;123:266-78.
13. Komori E, Aigase K, Sugisaki M, Tanabe H. Cause of early skeletal relapse after mandibular setback. *Am J Orthod Dentofacial Orthop* 1989;95:29-36.
14. Kawamata A, Fujishita M, Nagahara K, Kanematu N, Niwa K, Langlais RP. Three-dimensional computed tomography evaluation of postsurgical condylar displacement after mandibular osteotomy. *Oral Surg Oral Med Oral Pathol Oral Radiol Endod* 1998;85:371-6.
15. Lee W, Park JU. Three-dimensional evaluation of positional change of the condyle after mandibular setback by means of bilateral sagittal split ramus osteotomy. *Oral Surg Oral Med Oral Pathol Oral Radiol Endod* 2002;94:305-9.
16. Ueki K, Marukawa K, Nakagawa K, Yamamoto E. Condylar and temporomandibular joint disc positions after mandibular osteotomy for prognathism. *J Oral Maxillofac Surg* 2002;60:1424-32.
17. Jakobsone G, Stenvik A, Sandvik L, Espeland L. Three-year follow-up of bimaxillary surgery to correct skeletal Class III malocclusion: stability and risk factors for relapse. *Am J Orthod Dentofacial Orthop* 2011;139:80-9.
18. Ueki K, Moroi A, Sotobori M, Ishihara Y, Marukawa K, Yoshizawa K, et al. Changes in temporomandibular joint and ramus after sagittal split ramus osteotomy in mandibular prognathism patients with and without asymmetry. *J Craniomaxillofac Surg* 2012;40:821-7.
19. Ueki K, Degerliyurt K, Hashiba Y, Marukawa K, Nakagawa K, Yamamoto E. Horizontal changes in the condylar head after sagittal split ramus osteotomy with bent plate fixation. *Oral Surg Oral Med Oral Pathol Oral Radiol Endod* 2008;106:656-61.
20. Kim JW, Lee DH, Lee SY, Kim JH, Lee SH. 3-D CT evaluation of condyle head position, mandibular width, and mandibular angle after mandibular setback surgery. *J Korean Assoc Oral Maxillofac Surg* 2009;35:229-39.
21. Lee SK, Kim KW, Kim CH. Postoperative positional change of condyle after bilateral sagittal split ramus osteotomy associated with mandibular asymmetry. *J Korean Assoc Oral Maxillofac Surg* 2004;30:359-67.
22. Ueki K, Marukawa K, Shimada M, Hashiba Y, Nakagawa K, Yamamoto E. Condylar and disc positions after sagittal split ramus osteotomy with and without Le Fort I osteotomy. *Oral Surg Oral Med Oral Pathol Oral Radiol Endod* 2007;103:342-8.
23. Kim YI, Cho BH, Jung YH, Son WS, Park SB. Cone-beam computerized tomography evaluation of condylar changes and stability following two-jaw surgery: Le Fort I osteotomy and mandibular setback surgery with rigid fixation. *Oral Surg Oral Med Oral Pathol Oral Radiol Endod* 2011;111:681-7.
24. Kim YI, Jung YH, Cho BH, Kim JR, Kim SS, Son WS, et al. The assessment of the short- and long-term changes in the condylar position following sagittal split ramus osteotomy (SSRO) with rigid fixation. *J Oral Rehabil* 2010;37:262-70.
25. Bailey L, Cevidanes LH, Proffit WR. Stability and predictability of orthognathic surgery. *Am J Orthod Dentofacial Orthop* 2004;126:273-7.
26. Pullinger A, Hollender L. Variation in condyle-fossa relationships according to different methods of evaluation in tomograms. *Oral Surg Oral Med Oral Pathol* 1986;62:719-27.
27. Alder ME, Deahl ST, Matteson SR, Van Sickels JE, Tiner BD, Rugh JD. Short-term changes of condylar position after sagittal split osteotomy for mandibular advancement. *Oral Surg Oral Med Oral Pathol Oral Radiol Endod* 1999;87:159-65.
28. Hackney FL, Van Sickels JE, Nummikoski PV. Condylar displacement and temporomandibular joint dysfunction following bilateral sagittal split osteotomy and rigid fixation. *J Oral Maxillofac Surg* 1989;47:223-7.
29. Will LA, Joondeph DR, Hohl TH, West RA. Condylar position following mandibular advancement: its relationship to relapse. *J Oral Maxillofac Surg* 1984;42:578-88.
30. Ellis E 3rd, Hinton RJ. Histologic examination of the temporomandibular joint after mandibular advancement with and without rigid fixation: an experimental investigation in adult *Macaca mulatta*. *J Oral Maxillofac Surg* 1991;49:1316-27.
31. Hoppenreijts TJ, Stoelinga PJ, Grace KL, Robben CM. Long-term evaluation of patients with progressive condylar resorption following orthognathic surgery. *Int J Oral Maxillofac Surg* 1999;28:411-8.
32. Hwang SJ, Haers PE, Seifert B, Sailer HF. Non-surgical risk factors for condylar resorption after orthognathic surgery. *J Craniomaxillofac Surg* 2004;32:103-11.
33. Rotskoff KS, Herbosa EG, Villa P. Maintenance of condyle-prox-



- imal segment position in orthognathic surgery. *J Oral Maxillofac Surg* 1991;49:2-7.
34. Gerressen M, Zadeh MD, Stockbrink G, Riediger D, Ghassemi A. The functional long-term results after bilateral sagittal split osteotomy (BSSO) with and without a condylar positioning device. *J Oral Maxillofac Surg* 2006;64:1624-30.
  35. Ingervall B, Thüer U, Vuillemin T. Stability and effect on the soft tissue profile of mandibular setback with sagittal split osteotomy and rigid internal fixation. *Int J Adult Orthodon Orthognath Surg* 1995;10:15-25.
  36. Ueki K, Nakagawa K, Marukawa K, Takatsuka S, Yamamoto E. The relationship between temporomandibular joint disc morphology and stress angulation in skeletal Class III patients. *Eur J Orthod* 2005;27:501-6.
  37. Ueki K, Nakagawa K, Takatsuka S, Yamamoto E. The change of stress distribution on the condyle after mandibular setback surgery. *Eur J Orthod* 2006;28:433-9.