

Received: 2020.05.26

Accepted: 2020.07.28

Available online: 2020.08.05

Published: 2020.09.08

Concomitant Gallbladder Agenesis with Methimazole Embryopathy

Authors' Contribution:

Study Design A
Data Collection B
Statistical Analysis C
Data Interpretation D
Manuscript Preparation E
Literature Search F
Funds Collection G

ABCDEF **Hirota**
Kato
EF **Yasuyuki**
Mitani
E **Taro**
Goda
A **Hiroki**
Yamaue

Second Department of Surgery, Wakayama Medical University, Wakayama City,
Wakayama, Japan

Corresponding Author: Hiroki Yamaue, e-mail: yamaue-h@wakayama-med.ac.jp

Conflict of interest: None declared

Patient: Female, Newborn
Final Diagnosis: Gallbladder agenesis
Symptoms: Asymptomatic
Medication: —
Clinical Procedure: —
Specialty: Pediatrics and Neonatology

Objective: Rare co-existence of disease or pathology

Background: Methimazole embryopathy is caused by maternal methimazole intake during early pregnancy. It causes fetal malformations such as choanal atresia, esophageal atresia, aplasia cutis, omphalomesenteric duct remnants, urachal remnants, and omphalocele. Gallbladder agenesis is sometimes complicated with other malformations, but there have been no reports of gallbladder agenesis due to methimazole or concomitant methimazole embryopathy with gallbladder agenesis.


Case Report: The mother of a male neonate had taken methimazole for hyperthyroidism until pregnancy was recognized at 7 weeks of gestation. Ultrasonography at 12 weeks and 4 days of gestation showed the fetus had a cystic lesion in the umbilical region. The child was born at the gestational age of 38 weeks and 5 days. At birth there was omphalocele, omphalomesenteric fistula, and a scalp defect, and the child was diagnosed with methimazole embryopathy. Ultrasonography could not identify the gallbladder. Emergency surgery was performed for omphalocele with omphalomesenteric fistula on day 0. The intestine, including the omphalomesenteric fistula, was resected. Postoperative blood testing revealed hypothyroidism, so the patient was administered levothyroxine. Although MRI did not detect the gallbladder, it showed dilatation of the biliary duct. Hypothyroidism was well controlled by levothyroxine, so the patient was discharged with outpatient follow-up for the gallbladder agenesis. Six months later, the patient is asymptomatic.

Conclusions: Concomitant gallbladder agenesis with methimazole embryopathy has not been previously reported. In the case of a dilated common bile duct, even when asymptomatic in the neonatal period, gallbladder agenesis demands long-term follow-up because of possible manifestation of choledocholithiasis or biliary malignant tumors.

MeSH Keywords: Fetal Diseases • Gallbladder • Hernia, Umbilical • Methimazole • Vitelline Duct

Abbreviations: MMI – methimazole; GA – gallbladder agenesis; MRCP – magnetic resonance cholangiopancreatography

Full-text PDF: <https://www.amjcaserep.com/abstract/index/idArt/926310>



1252



—



3



22



Background

Methimazole (MMI), a thyroperoxidase inhibitor prescribed for hyperthyroidism, can be teratogenic [1,2]. MMI embryopathy is caused by maternal methimazole intake during early pregnancy. It can cause the fetus to have choanal atresia, esophageal atresia, aplasia cutis, omphalomesenteric duct remnants, urachal remnants, and omphalocele [3]. Gallbladder agenesis (GA) is the absence of the gallbladder and cystic duct due to embryological abnormality. GA has high mortality because of complications with other critical malformations, especially when diagnosed in children under 1 year of age [4]. It sometimes causes the common bile duct to become dilated due to cholestasis and repeated chronic inflammation, which can cause choledocholithiasis or biliary malignant tumors [5,6]. Gallbladder agenesis has not been included in the category of methimazole embryopathy. This is the first reported case of gallbladder agenesis due to methimazole, or concomitant methimazole embryopathy with gallbladder agenesis.

Case Report

The patient's mother had taken methimazole for hyperthyroidism until she was diagnosed as being in the seventh week of pregnancy. Methimazole was discontinued and she was switched to hyperthyroid treatment using potassium iodide and was referred to our center for perinatal management. At referral, ultrasonography did not reveal any significant abnormal findings. At 12 weeks and 4 days gestational age, a cystic lesion at the child's umbilical portion was shown, and the mother and baby were observed carefully thereafter (Figure 1). The child was born at 38 weeks and 5 days gestational age by vaginal delivery. The child's birth weight was 2729 g and the Apgar score was 6/9 points. A physical examination at birth revealed omphalocele, omphalomesenteric fistula, and a scalp defect. Methimazole embryopathy

was diagnosed, and the child was admitted to the Neonatal Intensive Care Unit (NICU).

Physical findings at birth showed pulse rate 120 bpm, SpO₂ 95% (room air), blood pressure 65/35 mmHg, and body temperature 36°C. There was a 4-cm diameter omphalocele with omphalomesenteric fistula at the umbilicus. There was also a scalp defect on the head (Figure 2). Blood and urinary examination at birth showed no significant findings in the neonatal period, but ultrasonography could not identify the gallbladder.

Emergency surgery was performed for omphalocele with omphalomesenteric fistula on the day of birth. In operative findings, when the peritoneum on the omphalocele was incised and the small intestine was observed, an omphalomesenteric fistula was located 17 cm from the Bauhin valve. The intestine, including the omphalomesenteric fistula, was resected. Extracted specimen findings showed the small intestine, including the omphalocele and omphalomesenteric fistula. Pathological findings showed that the intestinal structure was maintained, and did not show significant changes in either cell density or distribution of the gland and columnar morphology, which was consistent with an omphalomesenteric remnant.

Blood tests on postoperative day 4 showed hypothyroidism, so levothyroxine was administered. On postoperative day 5, the patient had abdominal distention, and abdominal X-ray images showed accumulation of small-intestinal gas. He was diagnosed with postoperative paralytic ileus, and an ileus tube was inserted. On postoperative day 8, the patient took oral feeding while decompressing with the ileus tube. The ileus tube was removed on postoperative day 30. After alleviation of the ileus symptoms, magnetic resonance cholangiopancreatography (MRCP) did not show the gall bladder clearly, but it did show dilatation of the biliary duct (Figure 3). The postoperative course was then uneventful, and hypothyroidism was well controlled with levothyroxine. The patient was discharged

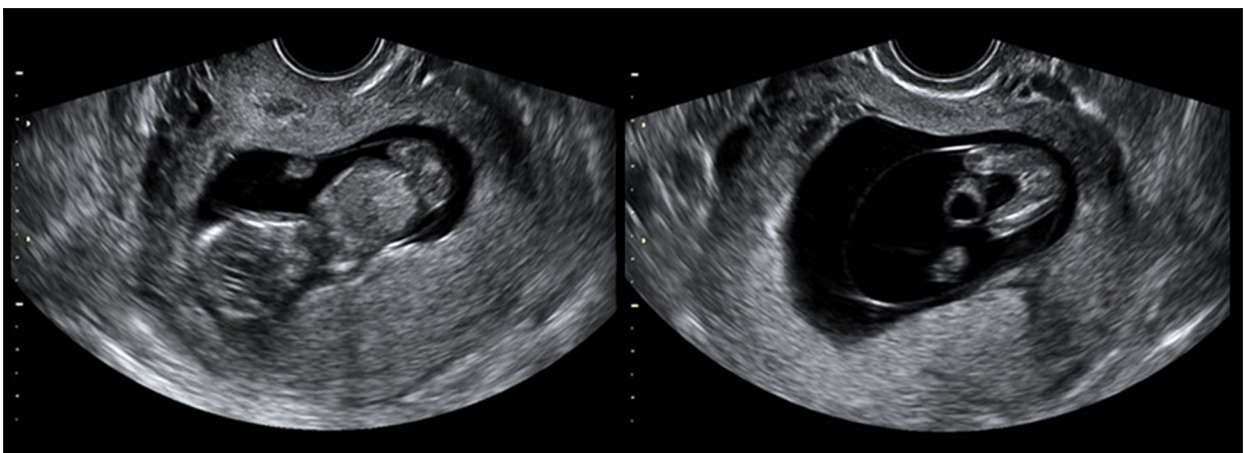

Figure 1. Fetal ultrasonography at 12 weeks and 4 days of gestation age. There was a cystic lesion at the fetal umbilical region.

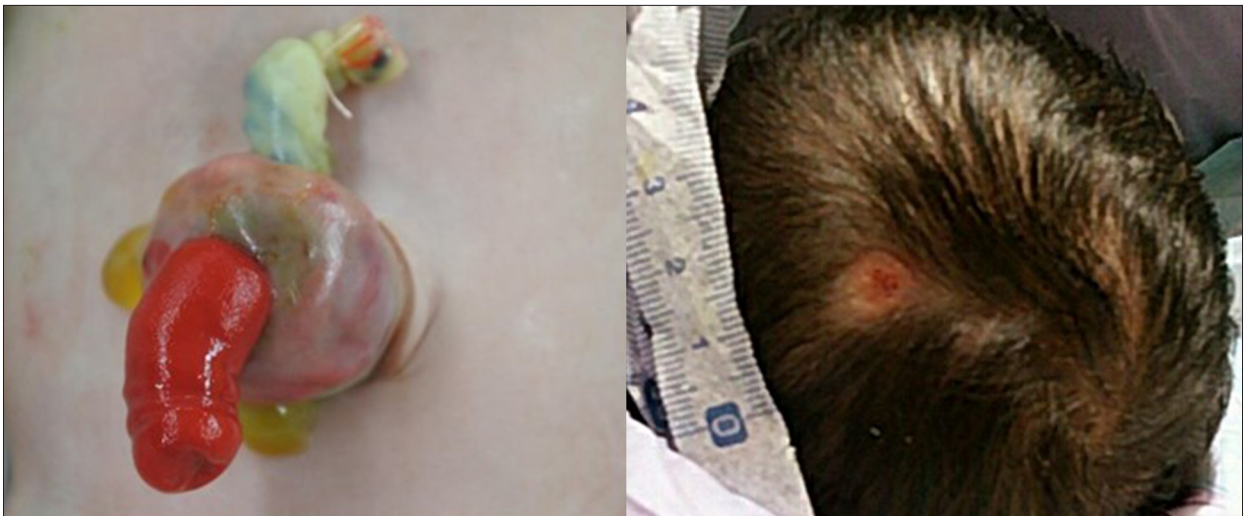

Figure 2. Physical findings at birth. Omphalocele with omphalomesenteric fistula protruded from the umbilicus, and there was a scalp defect on the head.

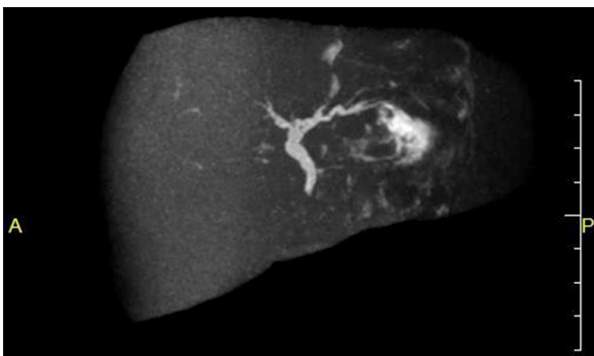


Figure 3. MRCP examination. MRCP showed absence of the cystic duct and gallbladder and dilation of the biliary duct.

on postoperative day 53 with follow-up for gallbladder agenesis. At present, the patient has a dilated common bile duct, but here are no significant findings of choledocholithiasis or biliary malignant tumors.

Discussion

MMI is a thyroperoxidase inhibitor prescribed for hyperthyroidism, with possible teratogenicity, and maternal intake of MMI, especially in early pregnancy, increases the risk [1,2]. Clementi et al. [3] proposed that maternal intake of MMI can lead to embryopathic choanal atresia, esophageal atresia, aplasia cutis, omphalomesenteric duct remnants, urachal remnants, or/and omphalocele. Regarding MMI embryopathy, in the United States and Europe, there have been many reports on choanal atresia or esophageal atresia. In Japan, omphalomesenteric duct remnants or omphalocele have more often been reported, with an estimated frequency of 1% to 14%. The incidence of

omphalomesenteric duct remnants or omphalocele due to the mother taking MMI is significantly higher than spontaneous omphalomesenteric duct remnants or omphalocele [1,2]. In the present case, the mother had a history of taking MMI for hyperthyroidism during early pregnancy, and the patient had omphalomesenteric duct remnants, omphalocele, and aplasia cutis, which was diagnosed as MMI embryopathy. The highest risk of MMI embryopathy may be due to exposure to the drug at 6 to 10 weeks of gestational age [7,8]. The mother in this case had been taking MMI until 7 weeks of gestational age, which appears to have caused the embryopathy.

GA is a rare congenital anomaly characterized by the absence of a gallbladder and cystic duct in conjunction with a normal bile duct system [9]. GA was first reported in 1701 by Lemery et al. [10], with a frequency of 13–65 per 100 000 births [11]. GA has been occasionally associated with other congenital malformations, such as genitourinary, gastrointestinal, cardiovascular, or skeletal anomalies [12]. In the case of diagnosis, especially in children under 1 year of age, other critical malformations have been highly involved, often causing death [4,13]. Regarding the development of the biliary tract system, the hepatic diverticulum, which is the base of the duodenum, is formed at about the gestational age of 3 weeks, the liver and biliary ducts form from the cranial part of the hepatic diverticulum, and the gallbladder and cystic duct form from the caudal part at a gestational age of 4 to 7 weeks [14]. The cause of gallbladder agenesis is that the caudal hepatic diverticulum, which forms the gallbladder and cystic duct, does not differentiate [15,16]. Genetic and drug-related factors have been reported for GA, but drug reports associated with GA include only thalidomide [12,17]. In the present neonatal case, there was no significant family history from the paternal or maternal pedigree. There have been no reports of MMI presenting with GA or MMI embryopathy concomitant with GA.

Although the causal relationship is unknown, we suggest that the GA was concomitant with congenital malformation of omphalomesenteric duct remnants or/and omphalocele due to MMI embryopathy. MRCP is useful for diagnosis of GA because it is necessary to rule out ectopic gallbladder [18,19]. In this case, MRCP at birth showed absence of the gallbladder and it did not show ectopic gallbladder or pancreaticobiliary malfunction. The common bile duct presented 5.0 mm diameter dilation [20]. GA often cause cholestasis due to compensated dilation of the common bile duct, which sometimes presents as choledocholithiasis or cholangitis [5,21]. There are also reports that repeated chronic inflammation due to cholestasis results in cholangiocarcinoma and intrahepatic biliary intraductal papillary neoplasm in adulthood [6,22]. Some patients with GA present symptoms such as abdominal pain, nausea, vomiting, or jaundice, which indicate choledocholithiasis or biliary malignant tumors [13]. Both MMI and GA develop at a gestational age of 6 to 9 weeks, so GA could be concomitant with not only MMI embryopathy, but also the other malformations.

References:

1. Andersen SL, Olsen J, Wu CS, Laurberg P: Birth defects after early pregnancy use of antithyroid drugs: A Danish nationwide study. *J Clin Endocrinol Metab*, 2013; 98(11): 4373–81
2. Yoshihara A, Noh J, Yamaguchi T et al: Treatment of Graves' disease with antithyroid drug in the first trimester of pregnancy and the prevalence of congenital malformation. *J Clin Endocrinol Metab*, 2012; 97(7): 2396–403
3. Clementi M, Di Gianantonio E, Pelo E et al: Methimazole embryopathy: Delineation of the phenotype. *Am J Med Genet*, 1999; 83(1): 43–46
4. Martinovici D, Ransy V, Vanden Eijnden S et al: Neonatal hemochromatosis and Martinez-Frias syndrome of intestinal atresia and diabetes mellitus in a consanguineous newborn. *Eur J Med Genet*, 2010; 53(1): 25–28
5. Alzahrani HA, Yamani NM: Gallbladder agenesis with a primary choledochal stone in patient with situs inversus totalis. *Am J Case Rep*, 2014; 15: 185–88
6. Yoldas O, Yazici P, Ozsan I et al: Coexistence of gallbladder agenesis and cholangiocarcinoma: Report of a case. *J Gastrointest Surg*, 2014; 18(7): 1373–76
7. Laurberg P, Andersen SL: Therapy of endocrine disease: antithyroid drug use in early pregnancy and birth defects: Time windows of relative safety and high risk? *Eur J Endocrinol*, 2014; 171(1): 13–20
8. Arata N: Pregnancy outcomes of exposure to methimazole (POEM) study: Final report. *Thyroid*, 2016; 26: 12
9. Kwon AH, Yanagimoto H, Matsui Y, Imamura A: Agenesis of the gallbladder with hypoplastic cystic duct diagnosed at laparoscopy. *Surg Laparosc Endosc Percutan Tech*, 2006; 16(4): 251–54
10. Chowbey PK, Dey A, Khullar R et al: Agenesis of gallbladder – our experience and review of literature. *Indian J Surg*, 2009; 71(4): 188–92
11. Rajkumar A, Piya A: Gall bladder agenesis: A rare embryonic cause of recurrent biliary colic. *Am J Case Rep*, 2017; 18: 334–38
12. Turkel SB, Swanson V, Chandrasoma P: Malformations associated with congenital absence of the gall bladder. *J Med Genet*, 1983; 20(6): 445–49
13. Bennion RS, Thompson JE Jr., Tompkins RK: Agenesis of the gallbladder without extrahepatic biliary atresia. *Arch Surg*, 1988; 123(10): 1257–60
14. Ando H: Embryology of the biliary tract. *Dig Surg*, 2010; 27(2): 87–89
15. Rabinovitch J, Rabinovitch P, Rosenblatt P, Pines B: Congenital anomalies of the gallbladder. *Ann Surg*, 1958; 148(2): 161–68
16. Gotohda N, Itano S, Horiki S et al: Gallbladder agenesis with no other biliary tract abnormality: Report of a case and review of the literature. *J Hepatobiliary Pancreat Surg*, 2000; 7(3): 327–30
17. Yamashita R, Takegawa Y, Sakamoto M et al: Defective development of the gall bladder and cystic duct in Lgr4 hypomorphic mice. *Dev Dyn*, 2009; 238(4): 993–1000
18. Sherson ND: The absent adult gallbladder. *Aust NZJ Surg*, 1970; 39(3): 225–28
19. Pierro A, Martucci M, Maselli G, Farchione A: Agenesis of the gallbladder with the presence of a small dysmorphic cyst: Role of magnetic resonance cholangiopancreatography. *J Clin Imaging Sci*, 2012; 2: 17
20. Hernanz-Schulman M, Ambrosino MM, Freeman PC, Quinn CB: Common bile duct in children: Sonographic dimensions. *Radiology*, 1995; 195(1): 193–95
21. Peloponissios N, Gillet M, Cavin R, Halkic N: Agenesis of the gallbladder: A dangerously misdiagnosed malformation. *World J Gastroenterol*, 2005; 11(39): 6228–31
22. Kim BS, Joo SH, Lim SJ, Joo KR: Intrahepatic biliary intraductal papillary mucinous neoplasm with gallbladder agenesis: Case report. *Surg Laparosc Endosc Percutan Tech*, 2013; 23(2): 61–64

Conclusions

We report a rare case of concomitant GA with MMI embryopathy. GA can sometimes be concomitant with the other malformations; therefore, it is necessary to be mindful of GA in the neonatal and infantile period. Careful long-term follow-up is necessary due to the possibility of adult manifestation of choledocholithiasis or biliary malignant tumors caused by cholestasis.

Acknowledgements

We acknowledge proofreading and editing by Benjamin Phillis at the Clinical Study Support Center, Wakayama Medical University.