

# The influence of age, sex, and tooth type on the anatomical relationship between tooth roots and the mandibular canal

Michał Puciło<sup>1</sup>, Aleksandra Puciło<sup>2</sup>, Krzysztof Safranow<sup>3</sup>, Alicja Nowicka<sup>4,\*</sup>

<sup>1</sup>*Stomatologia Puciło, Zielona Góra, Poland*

<sup>2</sup>*Faculty of Medicine and Dentistry, Pomeranian Medical University, Szczecin, Poland*

<sup>3</sup>*Department of Biochemistry and Medical Chemistry, Pomeranian Medical University, Szczecin, Poland*

<sup>4</sup>*Department of Conservative Dentistry and Endodontics, Pomeranian Medical University, Szczecin, Poland*

## ABSTRACT

**Purpose:** Cone-beam computed tomography (CBCT) reconstructions were analysed to elucidate factors affecting the anatomical relationship between tooth roots and the mandibular canal (MC).

**Materials and Methods:** Images of 300 volumetric tomography scans of patients aged between 20 and 79 years old (167 women and 133 men) were analysed. The mean distances between 2,053 dental root apices and the internal border of the MC were obtained by measuring the horizontal and vertical distances on coronal CBCT images. The actual distance was then calculated mathematically with the Pythagorean formula. The statistical significance of differences between men and women was assessed using the Mann-Whitney test. Correlations with patient age were evaluated with the Spearman rank correlation coefficient.

**Results:** The mean distances ranged from 2.17 mm, for single right third molar roots in women, to 8.02 mm for single left third molar mesiolingual roots in men. The mean distances measured for the mandibular right second molar mesial roots and the right second premolar roots were larger in men than in women. Age showed a significant positive correlation with the measured distances for mesial and distal roots of the first and second molar on both sides and the right third molar, mesiolingual roots of the left third molar, and single roots of the right third molar.

**Conclusion:** The root-to-mandibular canal distance depended on age and the type of tooth. In 2 root types, this distance was impacted by sex. (*Imaging Sci Dent 2021; 51: 373-82*)

**KEY WORDS:** Cone-Beam Computed Tomography, Endodontics, Mandibular Nerve

## Introduction

The mandibular canal (MC) is located on both sides of the mandible, starting at the mandibular foramen, running below the root apices of the mandibular molars, and ending at the mental foramen. It contains the inferior alveolar nerve (IAN), which innervates the molar and premolar regions, including the teeth and gingiva; then, branches of the IAN leave the mental foramen and innervate the mental region and skin of the lower lip and mucous membrane.<sup>1</sup>

All dental procedures performed near the roots of the mandibular teeth, including extractions, endodontic micro-

surgery, and implants in the mandible, are associated with the risk of temporarily or permanently damaging the IAN. Complications after root canal treatment may lead to paraesthesia or anaesthesia in the areas of the lower lip, gums, or mental nerve.<sup>2</sup> IAN damage may be caused by physical (e.g., pressure from overfilled material), chemical (e.g., neurotoxic effects of sealers), or thermal (e.g., overheating the periapical region when filing root channels in a thermal procedure) mechanisms.<sup>3</sup>

To reduce the risk of complications, clinicians should have a precise anatomical knowledge of the MC and the neighbouring structures. Previously, clinicians have relied on panoramic radiographs to examine the mandibular canal and its relationship with the roots. Cone-beam computed tomography (CBCT), which became available in 1996, enables 3-dimensional imaging, which provides more informa-

Received February 6, 2021; Revised May 20, 2021; Accepted May 28, 2021

Published online Aug 11, 2021

\*Correspondence to : Prof. Alicja Nowicka

Department of Conservative Dentistry and Endodontics, Pomeranian Medical University, Al. Powstańców Wlkp. 72, 70-111 Szczecin, Poland  
Tel) 48-91-466-16-48, E-mail) nowicka6@gmail.com

Copyright © 2021 by Korean Academy of Oral and Maxillofacial Radiology

This is an Open Access article distributed under the terms of the Creative Commons Attribution Non-Commercial License (<http://creativecommons.org/licenses/by-nc/3.0>) which permits unrestricted non-commercial use, distribution, and reproduction in any medium, provided the original work is properly cited.

Imaging Science in Dentistry · pISSN 2233-7822 eISSN 2233-7830

tion than panoramic radiographs.<sup>4,5</sup>

Previous studies have used CBCT to explore structures around the MC.<sup>6,7</sup> However, those studies were limited by the few types of teeth investigated and the wide variety of measurement methods.<sup>8</sup> Therefore, the present study aimed to analyse CBCT images to explore the anatomical relationship between the MC and the root apices of the neighbouring erupted permanent teeth and to identify factors that might affect that relationship.

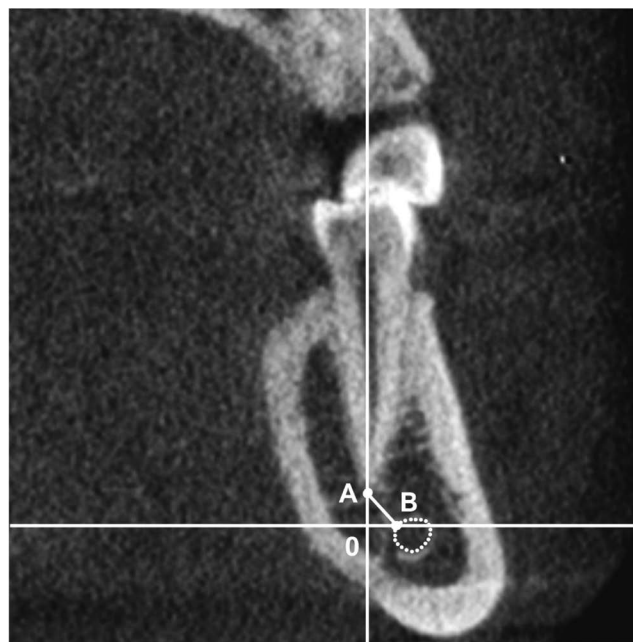
## Materials and Methods

This study was approved by the Bioethical Commission of Pomeranian Medical University (no. KB-0012/159/05/17). Anthropometric measurements were made on volumetric tomography images that were acquired between 2009 and 2018 during the planning stages of implant treatments. The confidentiality of patient personal data was strictly respected.

Images were included in the study according to the following inclusion criteria: CBCT showed the presence of at least 1 mandibular canine, premolar, or molar; the root was fully formed; the apical foramen was closed; there were no periapical changes or signs of root resorption; and the MC lumen was visible. The exclusion criteria were images with a resolution  $>0.25$  mm and images with visible post-traumatic lesions of the mandible or artefacts that prevented a correct measurement.

In a database containing 1612 CBCT scans of patients belonging to the Caucasian race, 300 scans acquired with a Gendex GXCB-500 tomograph (KaVo Kerr, Brea, CA, USA) met the inclusion criteria. The selected images were analysed randomly by 2 researchers. The scanning parameters were 120 kV, 5 mA, and an exposure time of 3 to 7 s. The voxel sizes were 0.25 to 0.125 mm. The field of view (FOV) volume was 85 mm  $\times$  60-133 mm. Patient information included sex and age. To determine the position of the root apex in each tooth relative to the MC, the 3D multiplanar reconstruction of the CBCT scans was employed and measurements on the axial, coronal, and sagittal planes were performed using the RadiAnt DICOM Viewer 5.5.0 (Medixant, Poznań, Poland). Images were viewed on a personal computer equipped with a 3.69-MP monitor and Windows 10 operating system (Microsoft, Redmond, WA, USA). All authors were certified in maxillo-facial radiology.

The measurement method was standardized as follows; the MC was located on the coronal plane, starting at the mental foramen, and followed on subsequent distal cross-sections up to the mandibular foramen. The morphology of



**Fig. 1.** Point A is set at the root apex in the coronal plane, point B is the closest point to point A on the oval formed by the mandibular canal (dashed circle), and the distance between points A and B (i.e., AB) is calculated with the Pythagorean formula.

each tooth root was analysed and assigned to 1 of the following groups: single root, mesial root, distal root, mesiolingual root, mesiobuccal root, distolingual root, or distobuccal root. Grid lines were positioned in coronal and sagittal reconstructions to align the image along the long axis of each root. The shortest distance (mm) between the apex of the root and the internal border of the MC in the coronal plane was measured. In the coronal plane, point A was designated as the root apex. Point B was the closest point to point A on the oval formed by the MC in the coronal CBCT section of the mandible. Next, a horizontal line,  $x$ , which passed through point B, and a vertical line,  $y$ , which passed through point A was drawn. The lines intersected at a right angle at point O. The vertical distance from the root apex to the MC was designated A0, and the horizontal distance was designated B0. Then, the distance between points A and B (i.e., the distance from the root apex to the MC) was determined from the Pythagorean formula for the hypotenuse of a right triangle (Fig. 1).

To reduce selection bias, all CBCT scans were selected using the same inclusion and exclusion criteria. To diminish bias during the measurement procedure, 2 independent researchers measured each root according to standardized procedure. Each researcher measured the distance once, and the mean value of their results was then calculated. All measurements were done on the same device, using the same

software. One month later, measurements on randomly selected 60 CBCT scans were repeated to improve the accuracy.

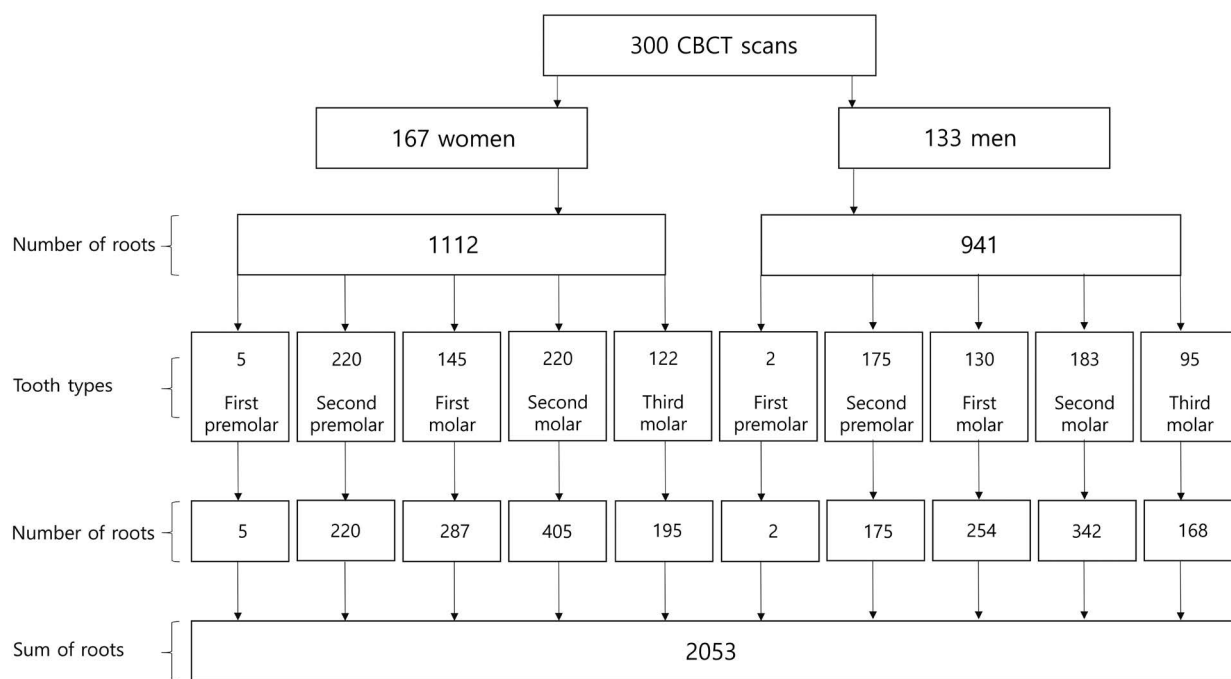
The root apices-to-MC distances are presented as the mean ± standard deviation (SD) for each root in all subjects. Since the number of roots counted was different in each category, the statistical precision for the estimation of population parameters greatly differed between categories. To achieve precision in the estimation of the mean, calculated as the standard error of the mean corresponding to one-tenth of the SD of distances from the RA to the MC, the number of roots in a category should be 100 (10<sup>2</sup>). With 300 CBCT scans, it was possible to achieve such a goal (n ≥ 100) for 10 root categories: second premolar single roots, first molar mesial roots, first molar distal roots, second molar mesial roots, and second molar distal roots on the left side and second premolar single roots, first molar mesial roots, first molar distal roots, second molar mesial roots, and second molar distal roots on the right side. The statistical significance of differences according to sex was evaluated with the Mann-Whitney test. Correlations between the measured distances and patient age were analysed with the Spearman rank correlation coefficient. To analyse inter- and intra-observer agreement between measurements, the intraclass correlation coefficient (ICC [3,1]) was calculated between the measurements performed by 2 researchers and

between 2 measurements performed by the same researcher at a 1-month interval for each root type. The mean of the ICC values for all root types was calculated subsequently. *P*-values < 0.05 were considered to indicate statistical significance. Statistica version 13 (Dell, Round Rock, TX, USA) was used for all calculations.

### Results

Among the 300 CBCT scans included, 56% (n = 167) were from women and 44% (n = 133) were from men. The teeth suitable for measuring included 7 first premolars, 395 second premolars, 541 first molars, 747 second molars, 363 third molars, and their corresponding roots (Fig. 2). The number of each root type and the mean distances from the root apices to the MC on each side of the mandible for each sex are shown in Tables 1 and 2. An example of the CBCT images of the right and left jaws with mean distances from the root apices to the MC is shown in Figure 3.

Among the mean distances, the shortest (2.17 mm) was found for single roots of the right third molar in women, and the longest (8.02 mm) was found for mesiolingual roots of the left third molar in men. The only significant differences between men and women were found in the measurements of mesial roots of the right second molar and single roots of the right second premolar.



**Fig. 2.** The flow diagram shows the number of roots counted in each category, based on 300 cone-beam computed tomography (CBCT) images.

**Table 1.** The mean distances from the right root apices to the mandibular canal

| Root             |                   |        | Number | Mean ± SD (mm) | Minimum (mm) | Maximum (mm) |
|------------------|-------------------|--------|--------|----------------|--------------|--------------|
| Second premolars | Single root       | Total  | 189    | 4.40 ± 2.73    | 0            | 15.37        |
|                  |                   | Male   | 85     | 5.14 ± 2.93    | 0.95         | 15.37        |
|                  |                   | Female | 104    | 3.79 ± 2.39    | 0            | 10.35        |
| First molars     | Mesial root       | Total  | 133    | 5.26 ± 2.14    | 1.11         | 12.18        |
|                  |                   | Male   | 60     | 5.37 ± 2.14    | 1.41         | 12.18        |
|                  |                   | Female | 73     | 5.17 ± 2.14    | 1.11         | 10.65        |
|                  | Distal root       | Total  | 140    | 5.06 ± 2.29    | 0            | 11.25        |
|                  |                   | Male   | 64     | 5.19 ± 2.18    | 0            | 11.08        |
|                  |                   | Female | 76     | 4.95 ± 2.38    | 0.82         | 11.25        |
| Second molars    | Single root       | Total  | 22     | 3.80 ± 2.18    | 0            | 8.29         |
|                  |                   | Male   | 6      | 3.08 ± 2.08    | 0            | 5.1          |
|                  |                   | Female | 16     | 4.08 ± 2.21    | 0            | 8.29         |
|                  | Mesial root       | Total  | 163    | 3.69 ± 2.22    | 0            | 11.64        |
|                  |                   | Male   | 79     | 4.10 ± 2.46    | 0            | 11.64        |
|                  |                   | Female | 84     | 3.31 ± 1.90    | 0            | 8.51         |
|                  | Distal root       | Total  | 158    | 3.37 ± 2.26    | 0            | 12.24        |
|                  |                   | Male   | 73     | 3.60 ± 2.66    | 0            | 12.24        |
|                  |                   | Female | 85     | 3.17 ± 1.84    | 0            | 8.52         |
|                  | Mesiolingual root | Total  | 7      | 4.30 ± 2.74    | 0            | 8.65         |
|                  |                   | Male   | 2      | 6.48 ± 3.28    | 4.3          | 8.65         |
|                  |                   | Female | 5      | 3.43 ± 2.36    | 0            | 5.64         |
|                  | Mesiobuccal root  | Total  | 7      | 3.47 ± 2.75    | 0.3          | 8.37         |
|                  |                   | Male   | 2      | 6.48 ± 3.28    | 4.3          | 8.65         |
|                  |                   | Female | 5      | 2.63 ± 2.08    | 0.3          | 4.72         |
| Third molars     | Single root       | Total  | 23     | 2.39 ± 1.89    | 0            | 5.56         |
|                  |                   | Male   | 5      | 3.19 ± 2.16    | 0            | 5.48         |
|                  |                   | Female | 18     | 2.17 ± 1.81    | 0            | 5.56         |
|                  | Mesial root       | Total  | 61     | 3.76 ± 2.37    | 0            | 11.03        |
|                  |                   | Male   | 34     | 3.66 ± 2.56    | 0            | 11.03        |
|                  |                   | Female | 27     | 3.88 ± 2.15    | 0            | 9.48         |
|                  | Distal root       | Total  | 51     | 3.61 ± 2.19    | 0            | 9.13         |
|                  |                   | Male   | 27     | 3.55 ± 2.19    | 0            | 8.14         |
|                  |                   | Female | 24     | 3.68 ± 2.24    | 0            | 9.13         |
|                  | Mesiolingual root | Total  | 4      | 4.88 ± 1.99    | 3.18         | 7.52         |
|                  |                   | Male   | 0      | –              | –            | –            |
|                  |                   | Female | 4      | 4.88 ± 1.99    | 3.18         | 7.52         |
|                  | Mesiobuccal root  | Total  | 4      | 2.95 ± 1.23    | 1.66         | 4.62         |
|                  |                   | Male   | 0      | –              | –            | –            |
|                  |                   | Female | 4      | 2.95 ± 1.23    | 1.66         | 4.62         |

The measured distance was significantly correlated with age in 13 types of roots (mesial roots of the left first molar, left second molar, right first molar, right second molar, and right third molar; distal roots of the left first molar, left second molar, left third molar, right first molar, right second

molar, right third molar; mesiolingual roots of the left third molar; single roots of the right third molar). For each type of root, the distance increased with age (Fig. 4).

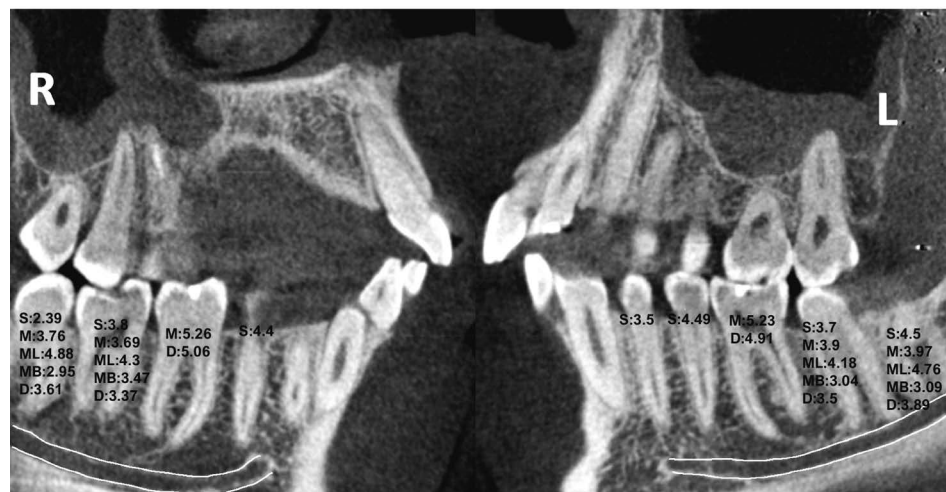The repeatability of the measurements calculated as the ICC (3,1) was excellent both between the 2 researchers

**Table 2.** The mean distances from the left root apices to the mandibular canal

|                  | Root              |        | Number | Mean $\pm$ SD<br>(mm) | Minimum<br>(mm) | Maximum<br>(mm) |
|------------------|-------------------|--------|--------|-----------------------|-----------------|-----------------|
| First premolars  | Single root       | Total  | 7      | 3.50 $\pm$ 1.31       | 2.24            | 5.78            |
|                  |                   | Male   | 2      | 2.45 $\pm$ 0.31       | 2.24            | 2.67            |
|                  |                   | Female | 5      | 3.91 $\pm$ 1.33       | 2.63            | 5.78            |
| Second premolars | Single root       | Total  | 206    | 4.49 $\pm$ 2.39       | 0               | 12.38           |
|                  |                   | Male   | 90     | 4.69 $\pm$ 2.51       | 0               | 11.45           |
|                  |                   | Female | 116    | 4.34 $\pm$ 2.30       | 0               | 12.38           |
| First molars     | Mesial root       | Total  | 133    | 5.23 $\pm$ 2.29       | 0               | 12.61           |
|                  |                   | Male   | 64     | 5.65 $\pm$ 2.51       | 1.47            | 12.61           |
|                  |                   | Female | 69     | 4.85 $\pm$ 1.99       | 0               | 9.85            |
|                  | Distal root       | Total  | 135    | 4.91 $\pm$ 2.19       | 0               | 11.5            |
|                  |                   | Male   | 66     | 5.30 $\pm$ 2.36       | 0.2             | 11.5            |
|                  |                   | Female | 69     | 4.54 $\pm$ 1.96       | 0               | 10.19           |
| Second molars    | Single root       | Total  | 28     | 3.70 $\pm$ 2.63       | 0               | 8.77            |
|                  |                   | Male   | 11     | 4.11 $\pm$ 2.99       | 0               | 8.69            |
|                  |                   | Female | 17     | 3.43 $\pm$ 2.42       | 0               | 8.77            |
|                  | Mesial root       | Total  | 178    | 3.90 $\pm$ 2.15       | 0               | 11.65           |
|                  |                   | Male   | 82     | 4.27 $\pm$ 2.48       | 0               | 11.65           |
|                  |                   | Female | 96     | 3.58 $\pm$ 1.78       | 0               | 7.96            |
|                  | Distal root       | Total  | 178    | 3.50 $\pm$ 2.20       | 0               | 14.4            |
|                  |                   | Male   | 83     | 3.84 $\pm$ 2.62       | 0               | 14.4            |
|                  |                   | Female | 95     | 3.20 $\pm$ 1.72       | 0               | 7.16            |
|                  | Mesiolingual root | Total  | 3      | 4.18 $\pm$ 1.40       | 2.99            | 5.73            |
|                  |                   | Male   | 2      | 4.77 $\pm$ 1.35       | 3.81            | 5.73            |
|                  |                   | Female | 1      | 2.99                  | 2.99            | 2.99            |
|                  | Mesiobuccal root  | Total  | 3      | 3.04 $\pm$ 1.68       | 1.34            | 4.69            |
|                  |                   | Male   | 2      | 3.01 $\pm$ 2.37       | 1.34            | 4.69            |
|                  |                   | Female | 1      | 3.09                  | 3.09            | 3.09            |
| Third molars     | Single root       | Total  | 31     | 4.5 $\pm$ 2.53        | 0               | 7.68            |
|                  |                   | Male   | 9      | 4.38 $\pm$ 2.59       | 0               | 7.68            |
|                  |                   | Female | 22     | 3.14 $\pm$ 2.48       | 0               | 7.33            |
|                  | Mesial root       | Total  | 83     | 3.97 $\pm$ 2.56       | 0               | 11.02           |
|                  |                   | Male   | 44     | 4.32 $\pm$ 2.72       | 0               | 11.02           |
|                  |                   | Female | 39     | 3.56 $\pm$ 2.33       | 0               | 9.04            |
|                  | Distal root       | Total  | 90     | 3.89 $\pm$ 2.57       | 0               | 10.46           |
|                  |                   | Male   | 45     | 3.94 $\pm$ 2.87       | 0               | 10.46           |
|                  |                   | Female | 45     | 2.84 $\pm$ 2.11       | 0               | 7.34            |
|                  | Mesiolingual root | Total  | 8      | 4.76 $\pm$ 3.82       | 0               | 9.33            |
|                  |                   | Male   | 2      | 8.02 $\pm$ 1.85       | 6.72            | 9.33            |
|                  |                   | Female | 6      | 3.68 $\pm$ 3.75       | 0               | 8.84            |
|                  | Mesiobuccal root  | Total  | 8      | 3.09 $\pm$ 2.77       | 0               | 6.33            |
|                  |                   | Male   | 2      | 4.61 $\pm$ 0.62       | 4.17            | 5.05            |
|                  |                   | Female | 6      | 2.58 $\pm$ 3.07       | 0               | 6.33            |

(inter-observer agreement: ICC = 0.9947) and between the 2 measurements performed by the same researcher at a

1-month interval (intra-observer agreement: ICC = 0.9981 for researcher MP and ICC = 0.9977 for researcher AP).



**Fig. 3.** Two cone-beam computed tomographic images of the right (R) and left (L) mandible show the tooth roots and the mandibular canal (red lines), the mean distances (in mm) between the roots of each tooth and the mandibular canal are superimposed on the corresponding tooth image; the roots are labelled as follows: S: single root, M: mesial root, D: distal root, ML: mesiolingual root, MB: mesiobuccal root.

## Discussion

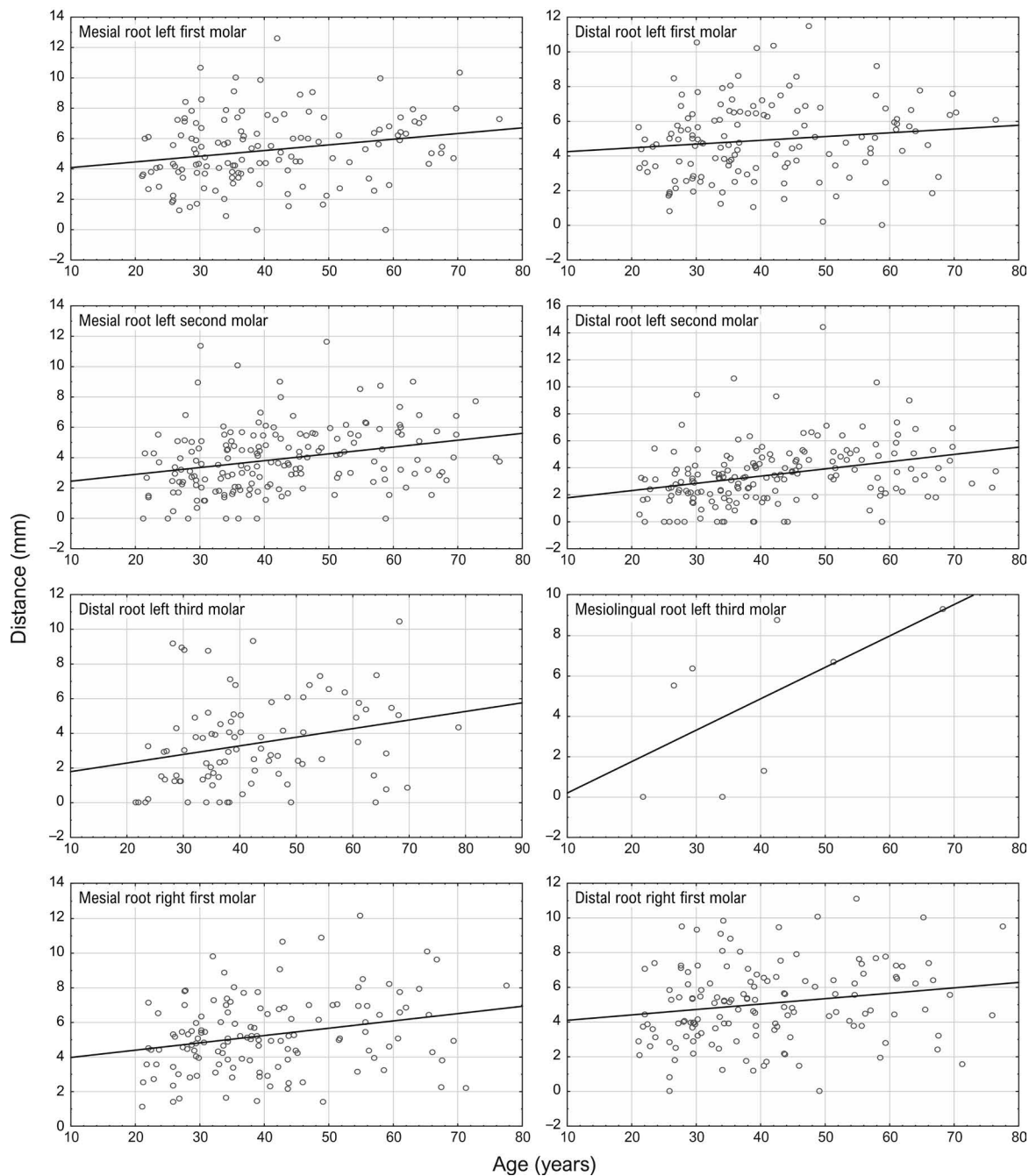
The relationship between the root apices of mandibular teeth and the MC was investigated based on CBCT reconstructions. Although other authors have previously explored this topic, they used different methods to define the relationship between the root apices and MC. Before digital X-ray imaging became widely available, only cadaveric studies were possible. Those studies were limited by the small sample sizes.<sup>9</sup> Later, conventional periapical radiographs and panoramic radiographs, which are the current preoperative standard for endodontic treatment, were used in radiology-based studies that investigated the positions of the MC and neighbouring structures.<sup>10</sup> The disadvantages of those X-ray examinations were the lack of buccolingual information, interference from the buccal plate, and the magnification and distortion derived from the changing distance between the radiation source and the examined structures, which is an inherent limitation of panoramic radiographs.

The advantages of CBCT are that more information is available than on 2-dimensional orthopantomography,<sup>4,5</sup> and the radiation dose is lower than that associated with multi-slice computed tomography.<sup>11</sup> The European Society of Endodontology released a position statement about the use of CBCT in endodontics;<sup>12</sup> the main guidelines were to ensure that the radiation exposure was as low as reasonably possible and to consider the risks and benefits before performing a CBCT scan. Because a smaller FOV leads to lower radiation exposure, the American Association of Endodontics and American Academy of Oral and Maxillofacial Radiology recommend a limited FOV for patients with contraindications or non-specific clinical signs and

symptoms associated with untreated or previously endodontically treated teeth.<sup>13</sup>

Knowledge about the position of the MC is important during treatment planning to reduce the risk of complications associated with IAN damage.<sup>3</sup> The use of CBCT for investigating anatomical relationships is justified by its high accuracy in linear measurements.<sup>14</sup>

Previous studies that used CBCT reconstructions employed different anatomical structures as the points of measurement, including bone margins,<sup>15</sup> the mental foramen,<sup>16</sup> or the root apices.<sup>6,7,17-29</sup> The relationship between the root apices and the bone margin or mental foramen is important for surgery, endodontic microsurgery, and implant procedures. Knowledge of the relationship between the root apices and the MC is important for endodontic treatments. When the root apices were used as a reference point, some studies reported the position of the MC in millimetres,<sup>6,7,17-21,23,24,26-29</sup> while another described the contact or lack of contact between the MC and the root tips<sup>25</sup> and yet others described the position of the MC relative to the roots (i.e., lingual; buccal; interradicular; lingual and interradicular; apical/inferior/in-line with the apex/middle; lingual and inferior; buccal and inferior; or interradicular and inferior).<sup>22</sup> Studies that used root apices as the reference points and made measurements in millimetres used different definitions of the reference point on the MC. Some authors measured the shortest distance between the root apices and the MC,<sup>7,17-21,27,28</sup> while others measured the distance from the superior border of the MC cortical bone.<sup>6,23,24,29</sup> The present study used an innovative method, based on the measurement method proposed by Chong et al.,<sup>6</sup> with some modifications. The reference point was the root apex aspect closest to the internal border of the MC. In contrast, Chong et al.<sup>6</sup>



**Fig. 4.** Mandibular root types showed significant correlations between the root apex-to-mandibular canal distance and patient age.

measured the distance from root apices to the most superior aspect of the IAN. This method was chosen because, when the root apex lies below the MC, the distance between the outer structures would not reflect the risk of IAN involvement (Fig. 5).

In general, no significant influence of sex on the measured distances was found. However, the right second molar mesial root and the right second premolar root measurements were associated with sex; these distances were smaller

in women than in men. This finding was consistent with other studies, but other studies found that, in general, all the distances between the MC and the root apices were smaller in women than in men.<sup>7,17,18,21,23,24,28</sup> This difference between women and men may be attributed to the fact that men generally have a larger body size and demonstrate greater distances between the MC and the root apices; as a consequence, women may have a higher risk of IAN damage during surgical or endodontic procedures.<sup>21</sup>

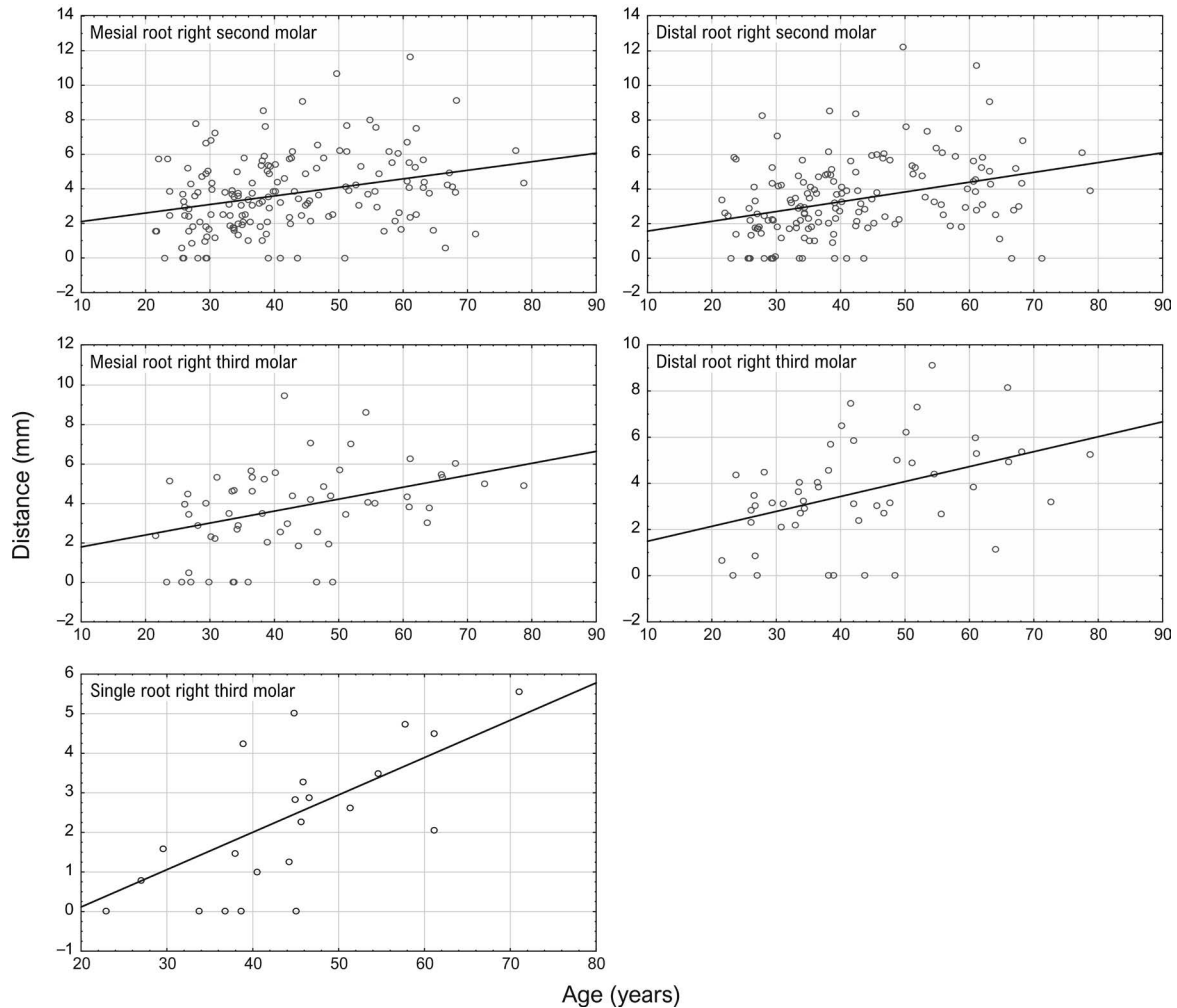


Fig. 4. Continued.

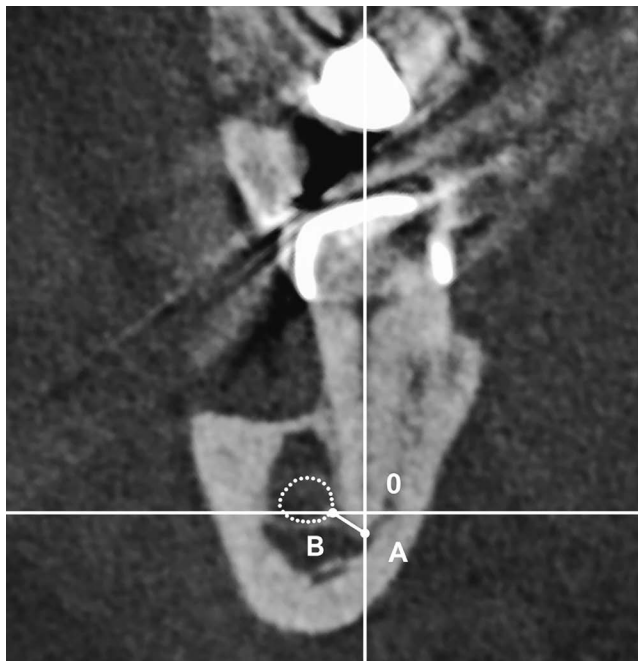
Some studies evaluated different age categories and found that the root apex-to-MC distances were smaller in younger than in older patients.<sup>7,17,18,23,24,28</sup> Two studies reported smaller distances in older individuals.<sup>7,18</sup> This difference may be related to the variety of age categories used in particular studies; for instance, Bürklein et al.<sup>21</sup> divided their research sample into 6 age groups, whereas Simonton et al.<sup>7</sup> used 3 categories. Discrepancies in this relationship across studies may also be attributed to racial differences.

The present study confirmed that age was significantly correlated with the MC-to-root apex distance in the mesial roots of the left first molar, left second molar, right first molar, right second molar, and right third molar; distal roots of the left first molar, left second molar, left third molar, right first molar, right second molar, right third molar; mesio-lingual roots of the left third molar; and single roots of the right third molar. The findings of this study showed that the measured distances increased with age, but did not confirm

decreasing measurements in patients over 50 years old (Fig. 4). This is in line with studies that have claimed that the craniofacial complex continues to change over the entire lifetime.<sup>30</sup>

Other studies found that the MC-to-root apex distance depended on which teeth were measured.<sup>17,19-21,23,26,28,29</sup> Those studies investigated a range of different teeth types, including second premolars and first and second molars;<sup>17,23</sup> first and second molars;<sup>19,26,29</sup> canines and first and second premolars, first and second molars;<sup>20</sup> second premolars and first, second, and third molars;<sup>21</sup> and first and second premolars and first, second, and third molars.<sup>28</sup> In the current study, canines, first and second premolars, and first, second, and third molars were investigated. The relationship between the MC and root apices of the first premolars was observed in 7 cases, according to definition of the MC as a structure that ended at the mental foramen. The discrepancy between the results of this study and previous research





**Fig. 5.** An example of a case where the root apex lies below the mandibular canal (MC). In this coronal cone-beam computed tomography (CBCT) image of the mandible, point A is on the root apex, and point B is the point on the oval formed by the internal boundary of the mandibular canal closest to point A. A mark on the internal boundary of the MC closest to the root apex gives better information about the risk of inferior alveolar nerve involvement than a mark on the superior border of the MC cortical bone.

involving canines, reported by Nair et al.,<sup>20</sup> may be due to the characteristic anatomy of their research sample or because they treated the incisive canal as a continuation of the MC.

When considering the issue of the shortest distance to the MC depending on the tooth type, the following mean distances were found (in ascending order): third molars (2.39 mm), second molars (3.04 mm), first premolars (3.5 mm), second premolars (4.4 mm), and first molars (4.91 mm). Two other studies included third molars in their measurements.<sup>21,28</sup> One found that third molar roots were frequently (31.3%) in direct communication with the MC.<sup>21</sup> The other study found that the third molar roots were significantly closer to the MC than the roots of the first and second molars and the premolars.<sup>28</sup>

The limitations of this study are the relatively small sample size resulting from the restricted indications for performing CBCT and the fact that the population of our CBCT database was limited to representatives of the Caucasian race.

This study confirmed that both age and tooth type influenced the distance between the root apices and the MC, but did not confirm that, in general, sex had an impact on the

distance. The findings of this study might help clinicians gain a better understanding of anatomical diversity. Additionally, the findings might improve the planning and performance of surgical and endodontic procedures that involve the mandible, thereby helping to avoid IAN injuries.

**Conflicts of Interest:** None

## References

1. Kim ST, Hu KS, Song WC, Kang MK, Park HD, Kim HJ. Location of the mandibular canal and the topography of its neurovascular structures. *J Craniofac Surg* 2009; 20: 936-9.
2. Alves FR, Coutinho MS, Gonçalves LS. Endodontic-related facial paresthesia: systematic review. *J Can Dent Assoc* 2014; 80: e13.
3. Renton T. Prevention of iatrogenic inferior alveolar nerve injuries in relation to dental procedures. *Dent Update* 2010; 37: 350-60.
4. Kapila R, Harada N, Araki K, Sano T, Goto TK. Relationships between third-molar juxta-apical radiolucencies and mandibular canals in panoramic and cone beam computed tomography images. *Oral Surg Oral Med, Oral Pathol Oral Radiol* 2014; 117: 640-4.
5. Peker I, Sarikir C, Alkurt MT, Zor ZF. Panoramic radiography and cone-beam computed tomography findings in preoperative examination of impacted mandibular third molars. *BMC Oral Health* 2014; 14: 71.
6. Chong BS, Quinn A, Pawar RR, Makdissi J, Sidhu SK. The anatomical relationship between the roots of mandibular second molars and the inferior alveolar nerve. *Int Endod J* 2015; 48: 549-55.
7. Simonton JD, Azevedo B, Schindler WG, Hargreaves KM. Age- and gender-related differences in the position of the inferior alveolar nerve by using cone beam computed tomography. *J Endod* 2009; 35: 944-9.
8. Puciło M, Lipski M, Sroczyk-Jaszczyńska M, Puciło A, Nowicka A. The anatomical relationship between the roots of erupted permanent teeth and the mandibular canal: a systematic review. *Surg Radiol Anat* 2020; 42: 529-42.
9. Denio D, Torabinejad M, Bakland LK. Anatomical relationship of the mandibular canal to its surrounding structures in mature mandibles. *J Endod* 1992; 18: 161-5.
10. Sato I, Ueno R, Kawai T, Yosue T. Rare courses of the mandibular canal in the molar regions of the human mandible: a cadaveric study. *Okajimas Folia Anat Jpn* 2005; 82: 95-101.
11. Loubele M, Bogaerts R, Van Dijck E, Pauwels R, Vanheudtsden S, Suetens P, et al. Comparison between effective radiation dose of CBCT and MSCT scanners for dentomaxillofacial applications. *Eur J Radiol* 2009; 71: 461-8.
12. Patel S, Brown J, Semper M, Abella F, Mannocci F. European Society of Endodontology position statement: use of cone beam computed tomography in Endodontics. *European Society of Endodontology (ESE) developed by. Int Endod J* 2019; 52: 1675-8.
13. Special Committee to Revise the Joint AAE/AAOMR Position

- Statement on use of CBCT in Endodontics. AAE and AAOMR joint position statement: use of cone beam computed tomography in endodontics 2015 update. *Oral Surg Oral Med Oral Pathol Oral Radiol* 2015; 120: 508-12.
14. Ganguly R, Ramesh A, Pagni S. The accuracy of linear measurements of maxillary and mandibular edentulous sites in cone-beam computed tomography images with different fields of view and voxel sizes under simulated clinical conditions. *Imaging Sci Dent* 2016; 46: 93-101.
  15. Koivisto T, Chiona D, Milroy LL, McClanahan SB, Ahmad M, Bowles WR. Mandibular canal location: cone-beam computed tomography examination. *J Endod* 2016; 42: 1018-21.
  16. Chong BS, Gohil K, Pawar R, Makdissi J. Anatomical relationship between mental foramen, mandibular teeth and risk of nerve injury with endodontic treatment. *Clin Oral Investig* 2017; 21: 381-7.
  17. Kovisto T, Ahmad M, Bowles WR. Proximity of the mandibular canal to the tooth apex. *J Endod* 2011; 37: 311-5.
  18. Adigüzel Ö, Yiğit-Özer S, Kaya S, Akkuş Z. Patient-specific factors in the proximity of the inferior alveolar nerve to the tooth apex. *Med Oral Patol Oral Cir Bucal* 2012; 17: 1103-8.
  19. Balaji SM, Krishnaswamy NR, Kumar SM, Rooban T. Inferior alveolar nerve canal position among South Indians: a cone beam computed tomographic pilot study. *Ann Maxillofac Surg* 2012; 2: 51-5.
  20. Nair UP, Yazdi MH, Nayar GM, Parry H, Katkar RA, Nair MK. Configuration of the inferior alveolar canal as detected by cone beam computed tomography. *J Conserv Dent* 2013; 16: 518-21.
  21. Bürklein S, Grund C, Schäfer E. Relationship between root apices and the mandibular canal: a cone-beam computed tomographic analysis in a German population. *J Endod* 2015; 41: 1696-700.
  22. Harada N, Beloor Vasudeva S, Matsuda Y, Seki K, Kapila R, Ishikawa N, et al. Characteristic findings on panoramic radiography and cone-beam CT to predict paresthesia after extraction of impacted third molar. *Bull Tokyo Dent Coll* 2015; 56: 1-8.
  23. Hiremath H, Agarwal R, Hiremath V, Phulambrikar T. Evaluation of proximity of mandibular molars and second premolar to inferior alveolar nerve canal among central Indians: a cone-beam computed tomographic retrospective study. *Indian J Dent Res* 2016; 27: 312-6.
  24. Kawashima Y, Sakai O, Shosho D, Kaneda T, Gohel A. Proximity of the mandibular canal to teeth and cortical bone. *J Endod* 2016; 42: 221-4.
  25. Pippi R, Santoro M, D'Ambrosio F. Accuracy of cone-beam computed tomography in defining spatial relationships between third molar roots and inferior alveolar nerve. *Eur J Dent* 2016; 10: 454-8.
  26. Kosumar W, Patanaporn V, Jotikasthira D, Janhom A. Distances from the root apices of posterior teeth to the maxillary sinus and mandibular canal in patients with skeletal open bite: a cone-beam computed tomography study. *Imaging Sci Dent* 2017; 47: 157-64.
  27. Muñoz G, Dias FJ, Weber B, Betancourt P, Borie E. Anatomic relationships of mandibular canal. A cone beam CT study. *Int J Morphol* 2017; 35: 1243-8.
  28. Aksoy U, Aksoy S, Orhan K. A cone-beam computed tomography study of the anatomical relationships between mandibular teeth and the mandibular canal, with a review of the current literature. *Microsc Res Tech* 2018; 81: 308-14.
  29. Vidya KC, Pathi J, Rout S, Sethi A, Sangamesh NC. Inferior alveolar nerve canal position in relation to mandibular molars: a cone-beam computed tomography study. *Natl J Maxillofac Surg* 2019; 10: 168-74.
  30. Dager MM, McNamara JA, Baccetti T, Franchi L. Aging in the craniofacial complex. *Angle Orthod* 2008; 73: 440-4.