



Rare case of a male breast tumour secondary to poorly differentiated rectal adenocarcinoma

Xia Cheng^{1#}, Tong Zhao^{2#}, Jia-Ning Jiang², Ying Liu², Heming Li³, Ruo-Yu Wang²

¹Graduate School, Dalian Medical University, Dalian, China; ²Department of Oncology, Affiliated Zhongshan Hospital of Dalian University, Dalian, China; ³The Key Laboratory of Biomarker High Throughput Screening and Target Translation of Breast and Gastrointestinal Tumor, Dalian, China

[#]These authors contributed equally to this work.

Correspondence to: Ruo-Yu Wang. Department of Oncology, Affiliated Zhongshan Hospital of Dalian University, 6 Jiefang Road, Dalian 116000, China. Email: chengxia3096@163.com.

Abstract: Rectal cancer metastasis to the breast is rare. A case history is presented of a 57-year-old man with breast metastases from rectal carcinoma. However, this patient did not have metastasis in common metastatic sites, such as the liver, lung, and other organs. The patient had undergone chemotherapy for advanced rectal carcinoma 6 months earlier and presented with a mammary mass. An ultrasound-directed core needle biopsy of the breast mass was performed. Cytology indicated an adenocarcinoma with poor to moderate differentiation in the breast mass. Immunohistochemistry (IHC) showed cytokeratin (CK) expression with a pattern that is characteristic of colorectal tumours: CK7(-), CK20(+), CDX2(-), Villin(+), TOPOII(-), and a Ki-67 index of 30%. The 3 main breast tumour markers were negative. Based on these histopathological and immunohistochemical findings, the patient was diagnosed with breast metastases from rectal carcinoma. Distant metastasis should be taken into account when a patient has a medical history of rectal adenocarcinoma, even when a rare metastasis site is involved. We should be vigilant when patients have some features that are favorable for metastasis. Histopathological characteristics and immunohistochemical tests are helpful for diagnosis. Regardless of surgical treatment after neoadjuvant chemotherapy, standard chemotherapy regimens for intestinal tumors, and EGFR molecular-targeted drugs, there is no obvious effect and the prognosis is poor. The treatment method needs further study.

Keywords: Male breast metastases; rectal carcinoma; transfer method; prognosis; case report

Submitted Apr 27, 2020. Accepted for publication Oct 21, 2020.

doi: 10.21037/tcr-20-1936

View this article at: <http://dx.doi.org/10.21037/tcr-20-1936>

Introduction

More than 1.2 million patients are diagnosed with colorectal cancer every year, and more than 600,000 patients die from this disease (1). When breast metastasis occurs in most rectal cancer, it is often accompanied by multiple organ metastasis, such as the liver, lung and so on.

Metastasis accounts for between 0.5% and 6% of all malignant breast tumours (2). Metastatic spread from a contralateral breast malignancy is the most common cause of metastasis to the breast (3). In the past 30 years, less than 20 such cases have been reported in the literature (4). Only

3 male patients were described in the existing reports, and the ratio of males to females was 1:6–1:5 (5).

Male primary breast cancer (PBC) is a rare malignant tumor, accounting for less than 1% of all breast cancers worldwide (6). Male PBC often exhibits more advanced disease features than in female BC, such as a larger tumor size, lymph node involvement, and distant metastases at the time of diagnosis (7). Estimates of *in situ* carcinoma in men accounts for 10%; the remaining 90% can be attributed to infiltrating ductal carcinoma. The treatment of early male BC includes 4 main treatment methods: surgery, radiation therapy, chemotherapy, and endocrine therapy. Male BCs

Table 1 Organization of the case into a timeline

Time	Treatment [T]/symptoms [S]/examination [E]
Nov. 2015	[S] Scrotal swelling, repeated haematochezia and rapid weight loss
Dec. 2015	[E] Colonoscopy showed bulging lesions [E] Cauliflower-like masses could be seen in the perianal area [E] A biopsy of the rectal mass revealed poorly differentiated adenocarcinoma [E] A scan of the chest, abdomen and pelvis showed bilateral groin, right axilla, and right clavicle multiple lymphadenopathy; there was no liver or lung metastasis, and the mammary ultrasound was normal
Jan. 2016	[T] Chemotherapy with FOLFOX6 for maintenance therapy
Jun. 2016	[E] The tumour markers were slowly and continuously increasing [E] Abdominal CT showed progressive disease [T] Chemotherapy with FOLFIRI
Aug. 2016	[S] The right breast mass had been gradually growing [E] A physical examination identified a hard, fixed mass [E] An ultrasound-directed core needle biopsy of the breast mass was performed [E] Cytology indicated an adenocarcinoma with poor to moderate differentiation [E] Immunohistological analysis indicated metastasis
Sep. 2016	[T] Chemotherapy with FOLFIRI and bevacizumab
Oct. 2016	[S] Bone pain [E] CT examination revealed bone metastasis
Nov. 2016	[S] The patient died

FOLFOX6, oxaliplatin, 5-fluorouracil and leucovorin; FOLFIRI, irinotecan, fluorouracil, leucovorin; CT, computed tomography.

usually express the estrogen receptor (ER), Progesterone receptor (PR), and androgen receptor (AR) are hormonally responsive. The use of endocrine therapy such as tamoxifen is routine for the management of male BC (8).

As the management differs and because of its rarity the importance of the diagnosis between primary and metastatic breast cancer is imperative. The present study reports the case of a 57-year-old man. This case mimicked rectal carcinoma metastasizing to breast during needle biopsy examination and immunohistochemistry. We present the following article in accordance with the CARE reporting checklist (available at <http://dx.doi.org/10.21037/tcr-20-1936>).

Case presentation

A 57-year-old man visited the hospital with complaints of scrotal swelling, repeated haematochezia and rapid weight loss for 1 month. The patient's diagnosis and

treatment process were briefly outlined in the timeline (*Table 1*). A physical exam revealed perianal masses. With palpation, the mass was hard, the boundary was unclear, and the glove was stained with blood. The mass extended to the scrotum. Colonoscopy showed approximately 4.0 cm × 1.2 cm bulging lesions at 5 cm from the anus and anal canal. Cauliflower-like masses could be observed in the perianal area. A biopsy of the rectal mass revealed poorly differentiated adenocarcinoma (*Figure 1*). A scan of the chest, abdomen and pelvis showed bilateral groin, right axilla, and right clavicle multiple lymphadenopathy; there was no liver or lung metastasis, and the mammary ultrasound was normal (*Figure 2*). The clinical stage was T4N2M0. A tumour at this stage is inoperable, so the patient was started on chemotherapy with oxaliplatin, 5-fluorouracil and leucovorin (FOLFOX6). After three cycles of chemotherapy, patient complaints that scrotal swelling and haematochezia resolved. An evaluation of total abdominal augmentation with computed tomography (CT)

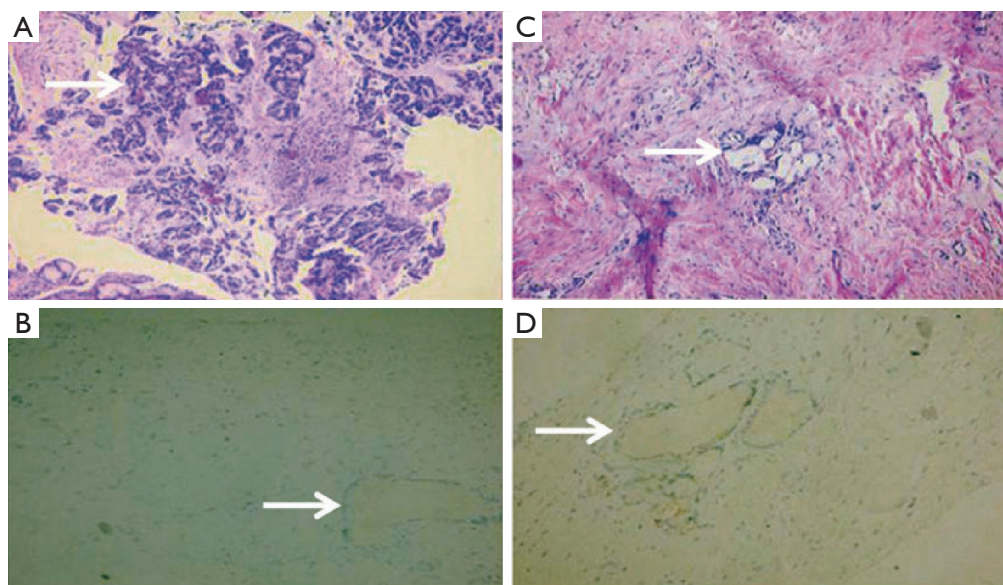


Figure 1 Representative pathological and immunohistochemistry. (A) The histopathological examination of the rectal mass shows low-grade adenocarcinoma (HE, $\times 200$). (B) Negative cytokeratin 7 staining in the tumour (cytokeratin 7, $\times 200$). (C) Breast core biopsy showing features similar to the primary rectal cancer (HE, $\times 200$). (D) Cytokeratin 20 was positive (cytokeratin 20, $\times 200$).

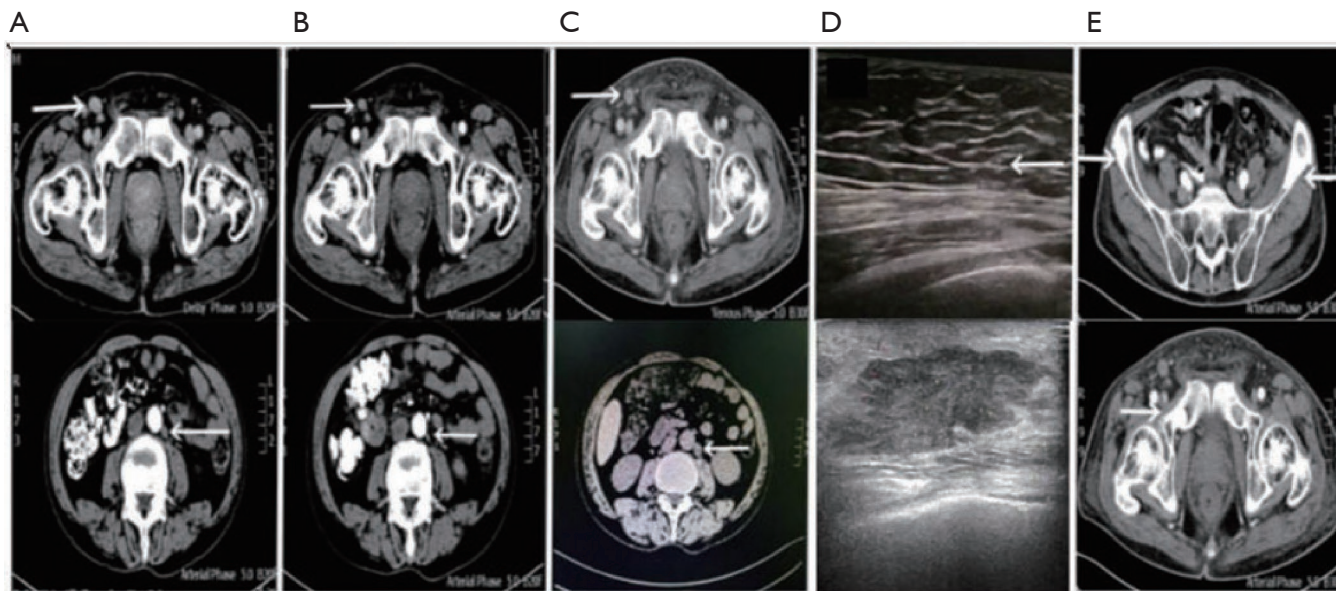


Figure 2 Representative images at different stages of disease development. (A) At the first visit (inguinal and retroperitoneal lymph nodes); (B) after 3 weeks of FOLFOX chemotherapy; (C) progression after FOLFIRI chemotherapy; (D) without metastasis vs. breast metastasis; (E) pelvic metastasis.

showed a partial response (*Figure 2*). CEA, CA125, CA724, and CA199 significantly decreased after treatment. After continuing chemotherapy for 5 months, the tumour markers

were slowly and continuously increasing. Abdominal CT showed progressive disease according to the Response Evaluation Criteria in Solid Tumors (RECIST) criteria.

Table 2 Comparison of histologic finding findings between PCB and CRC metastasizing to breast

Immunohistochemical	PCB	CRC	Characteristics
CK7(-)	+	-	PCB
CK20	-	+	CRC metastasizing to breast
CDX2	-	+	-
ER	+	-	PCB
PR	+/-	-	-
HER	+	-	PCB

PCB, primary carcinoma of the breast; CRC, colorectal carcinoma; ER, estrogen receptor; PR, progesterone receptor.

The chemotherapy protocol was changed to irinotecan, fluorouracil, leucovorin (FOLFIRI).

After 3 cycles of chemotherapy, the patient reported that the right breast mass had been gradually growing. He had no other breast symptoms, and his past medical history showed no risk factors for breast cancer, either hormonal or familial. A physical examination identified a hard, round, fixed mass that was approximately 3.0 cm × 3.9 cm × 1.3 cm behind the right nipple, with surrounding oedema and tenderness. Four non-tender lymph nodes (0.5–1.9 cm in diameter) were palpated in the ipsilateral axilla. An ultrasound-directed core needle biopsy of the breast mass was performed (*Figure 2*). Cytology indicated an adenocarcinoma with poor to moderate differentiation in the breast mass (*Figure 1*). Immunohistochemistry (IHC) showed cytokeratin (CK) expression with a pattern that is characteristic of colorectal tumours: CK7(-), CK20(+), CDX2(-), Villin(+), TOPOII(-), and a Ki-67 index of 30% (*Figure 1*). The 3 main breast tumour markers were negative. As the management differs the importance of the diagnosis between primary and metastatic breast cancer is imperative. The Cytokeratin pattern of CK7-negative, CK20-positive is considered to be the most useful, so we considered the possibility of metastatic rectal carcinoma. These results were consistent with breast metastasis secondary to rectal carcinoma. The initial clinical stage of the patient was T4N2M0. Now it is confirmed that the patient has breast metastasis. The intervention adherence is well, and the body's tolerance gradually decreases. The patient was then started on chemotherapy with FOLFIRI and bevacizumab. After one cycle of treatment, the patient failed to respond and developed bone pain from disease progression (*Figure 2*). The patient died 2 months later.

All procedures performed in studies involving human participants were in accordance with the ethical standards of the institutional and/or national research committee(s) and with the Helsinki Declaration (as revised in 2013). Written informed consent was obtained from the next of kin of the patient.

Discussion

Diagnosis of a breast mass after rectal cancer

Breast secondaries from colorectal neoplasm are rare till date. In the past 30 years, the ratio of males to females was 1:6–1:5, and only 3 male patients were described in the existing reports (9). Obtaining the correct diagnosis is crucial for these patients. It has been reported that radiologically these lesions are usually imaged by mammography and/or ultrasound and appear as single, round, discrete lesions usually lacking the irregularities and microcalcifications of primary breast malignancies (10). Fine needle aspiration biopsy (FNAB) is the best approach to the diagnosis of tumors that either clinically or radiographically are not typical of breast tumors (11). Currently, our diagnosis depends on pathological biopsy and IHC guidance. Male breast carcinomas are typically ER(+), CK7(+), and CK20(-) and show variable PR positive. The expected immunophenotype is ER(-), PR(-), HER2(-), CK7(-), and CK20(+). Testing for the expression of CK7 and CK20 is considered to be the most important. This patient had a history of rectal cancer, and the pathological tissue type and IHC results were consistent with metastatic rectal cancer (*Table 2*).

The routes of breast metastases secondary to rectal cancer

Colorectal cancers most typically metastasize to regional lymph nodes. Previously reported patients that at the same time there was a non-breast metastasis. In our case, non-breast metastasis was not detected. Axillary lymph and Inguinal lymph node involvement is known. Isolated metastasis to sites other than the liver and lung are uncommon. At present, the mechanism of rectal cancer metastasis to the breast has not been elucidated. In this patient, the tumour was 5 cm from the anus, and there was a perianal mass (below the dentate line). He had an unusual site of metastasis, the right breast, without any liver or lung metastasis. Blood-borne metastasis was not considered. The progressive appearance began in the groin and then involved the retroperitoneum, abdominal aorta,

Table 3 Few reported cases of rectal cancer metastasis to breast

Reported cases	Age (years)	Gender	Distance from mass to anus	Inguinal lymph nodes	Axillary lymph nodes
My patient	57	Male	5 cm	+	+
Wang <i>et al.</i> (12)	38	Male	<7 cm	NM	+
David <i>et al.</i> (11)	42	Female	Undifferentiated carcinoma	NM	+
Sanchez <i>et al.</i> (3)	36	Female	Infiltrate the vaginal wall	+	+
Ahmad <i>et al.</i> (4)	43	Female	5 cm	NM	+
Hisham <i>et al.</i> (15)	32	Female	2–10 cm	NM	NM
Li <i>et al.</i> (14)	54	Female	3–4 cm	With ascites	+
Mihai <i>et al.</i> (16)	53	Female	Uterine adnexal metastasis	+	+
Makhdoomi <i>et al.</i> (17)	28	Female	4 cm	Liver involvement	–
Singh <i>et al.</i> (18)	42	Female	–	Pleural effusion	–
Gur <i>et al.</i> (13)	47	Male	Low position	–	–

NM, not mentioned.

mediastinum, ipsilateral armpit, and supraclavicular lymph nodes. This pattern is also consistent with the metastatic route of breast metastasis from other primary tumours. Thus, it is speculated that this may be the route for breast metastasis. Further studies might shed more light on this unorthodox hypothesis (3,4,11-17) (*Table 3*).

Features favoring metastases are the following:

- (I) Low rectal tumor (distance from anus <5–7 cm);
- (II) The pathological type is poorly differentiated carcinoma;
- (III) Colorectal carcinoma (CRC) is positive for cytokeratin 20, CDX2 and negative for breast markers cytokeratin-7, mammaglobin and ER and PR in greater than 90% of cases;
- (IV) Pelvic metastasis or inguinal or axillary lymph node positive;
- (V) Gender (sex hormone level).

Wang *et al.* reported a case. The patient received 2 cycles of intravenous NAC (docetaxel; epirubicin; cyclophosphamide). The response to this regimen was poor, so the NAC was changed to vinorelbine. Following the last round of vinorelbine, modified radical mastectomy and dermoplasty were performed (12). Gur *et al.* presented a similar case. After a definitive diagnosis, the patient was started on chemotherapy containing calcium folinate, 5-fluorouracil, and oxaliplatin (13). After determined to be a metastasis, our patient was started on chemotherapy with FOLFIRI and bevacizumab. Comparing these three patients, it is not difficult to find that no significant

effect was seen regardless of surgical treatment after neoadjuvant chemotherapy, standard chemotherapy regimens for intestinal tumors, and EGFR molecular-targeted drugs. Taking into account the way such patients metastasize, we look forward to lymphatic targeting drugs or immunotherapy. Effective treatment methods and whether there are related gene mutations to require further exploration. The prognosis of the 3 cases was poor. We found that there are some common points: age <60 years, low rectal cancer, and triple-negative metastases (all negative for ER PR HER-2), so these are related factors for poor prognosis.

Metastases to the breast are rare in themselves, and such metastases occurring secondary to a previous rectal carcinoma makes this case very unusual, which may cause misdiagnosis. We should be vigilant when patients have some features that are favorable for metastasis. Metastasis should be considered in patients with breast mass and previously diagnosed cancer even if the patient is male. Metastatic disease of the breast is a marker for disseminated metastatic spread. The disease is under a poor prognosis. Most patients die within 1 year of breast metastasis (14). Our case is unusual because there was no non-breast metastasis of rectal carcinoma and metastasis occurred in an unexpected location, the breast of a male patient.

Acknowledgments

The authors would like to thank affiliated Zhongshan

Hospital of Dalian University for their kindness assistance and technical support.

Funding: None.

Footnote

Reporting Checklist: The authors have completed the CARE reporting checklist. Available at <http://dx.doi.org/10.21037/tcr-20-1936>

Conflicts of Interest: All authors have completed the ICMJE uniform disclosure form (available at <http://dx.doi.org/10.21037/tcr-20-1936>). The authors have no conflicts of interest to declare.

Ethical Statement: The authors are accountable for all aspects of the work in ensuring that questions related to the accuracy or integrity of any part of the work are appropriately investigated and resolved. All procedures performed in studies involving human participants were in accordance with the ethical standards of the institutional and/or national research committee(s) and with the Helsinki Declaration (as revised in 2013). Written informed consent was obtained from the next of kin of the patient.

Open Access Statement: This is an Open Access article distributed in accordance with the Creative Commons Attribution-NonCommercial-NoDerivs 4.0 International License (CC BY-NC-ND 4.0), which permits the non-commercial replication and distribution of the article with the strict proviso that no changes or edits are made and the original work is properly cited (including links to both the formal publication through the relevant DOI and the license). See: <https://creativecommons.org/licenses/by-nc-nd/4.0/>.

References

- Brenner H, Kloor M, Pox CP. Colorectal cancer. *Lancet* 2014;383:1490-502.
- Georgiannos SN, Chin J, Goode AW, et al. Secondary neoplasms of the breast: a survey of the 20th Century. *Cancer* 2001;92:2259-66.
- Sanchez LD, Chelliah T, Meisher I, et al. Rare case of breast tumor secondary to rectal adenocarcinoma. *South Med J* 2008;101:1062-4.
- Ahmad SS, Khalilullah K, McGowan K, et al. Unexpected destination! Rectal carcinoma metastasis to the breast. *J Surg Case Rep* 2019;2019:rjz036.
- Shackelford RE, Allam-Nandyala P, Bui MM, et al. Primary colorectal adenocarcinoma metastatic to the breast: case report and review of nineteen cases. *Case Rep Med* 2011;2011:738413.
- Korde LA, Zujewski JA, Kamin L, et al. Multidisciplinary meeting on male breast cancer: a summary and research recommendations. *J Clin Oncol* 2010;28:2114-22.
- Gucalp A, Traina TA, Eisner JR, et al. Male breast cancer: a disease distinct from female breast cancer. *Breast Cancer Res Treat* 2019;173:37-48.
- Darkeh MHSE, Azavedo E. Male breast cancer clinical features, risk factors, and current diagnostic and therapeutic approaches. *Int J Clin Med* 2014;5:1068-86.
- Yeh CN, Lin CH, Chen MF. Clinical and ultrasonographic characteristics of breast metastases from extramammary malignancies. *Am Surg* 2004;70:287-90.
- Vergier B, Trojani M, de Mascarel I, et al. Metastases to the breast: Differential diagnosis from primary breast carcinoma. *J Surg Oncol* 1991;48:112-6.
- David O, Gattuso P, Razan W, et al. Unusual cases of metastases to the breast. A report of 17 cases diagnosed by fine needle aspiration. *Acta Cytol* 2002;46:377-85.
- Wang T, Lv YG, Yan QG, et al. Rectal carcinoma metastatic to the male breast after 7 years: case report. *Onkologie* 2011;34:544-6.
- Gur EO, Onak C, Bayar EE, et al. Rectum mucinous adenocarcinoma metastasis to bilateral breast in a male patient: A case report. *Breast J* 2020;26:517-9.
- Li HC, Patel P, Kapur P, et al. Metastatic rectal cancer to the breast. *Rare Tumors* 2009;1:e22.
- Hisham RB, Thuaibah H, Gul YA. Mucinous adenocarcinoma of the rectum with breast and ocular metastases. *Asian J Surg* 2006;29:95-7.
- Mihai R, Christie-Brown J, Bristol J. Breast metastases from colorectal carcinoma. *Breast* 2004;13:155-8.
- Makhdooni R, Mustafa F, Ahmad R, et al. Bilateral breast metastasis from mucinous adenocarcinoma of the rectum: a case report and review of the literature. *Turk Patoloji Derg* 2013;29:231-4.
- Singh T, Premalatha CS, Satheesh CT, et al. Rectal carcinoma metastasizing to the breast: a case report and review of literature. *J Cancer Res Ther* 2009;5:321-3.

Cite this article as: Cheng X, Zhao T, Jiang JN, Liu Y, Li H, Wang RY. Rare case of a male breast tumour secondary to poorly differentiated rectal adenocarcinoma. *Transl Cancer Res* 2020;9(12):7676-7681. doi: 10.21037/tcr-20-1936