

Case Report

Renal biopsy in a patient with haemophilia A and cryoglobulinaemic membranoproliferative glomerulonephritis associated with hepatitis C virus infection

Ikue Kobayashi, Eiji Ishimura, Kaname Hirowatari, Takao Tsuchida, Ayako Nishihira, Hideaki Shima, Kaori Shidara, Katsuhito Mori, Masaaki Inaba, Ken-ichi Wakasa and Yoshiki Nishizawa

Departments of Nephrology, Pathology, Endocrinology, Metabolism and Molecular Medicine, Osaka City University Graduate School of Medicine, Osaka, Japan

Correspondence and offprint requests to: Eiji Ishimura; E-mail: ish@med.osaka-cu.ac.jp

Abstract

A renal biopsy was performed in a 47-year-old man with haemophilia A. Thirty minutes after administration of an intravenous bolus of 4000 units of recombinant factor VIII, which increased the activity to 74–91%, a needle renal biopsy was successfully performed, followed by administration of 3000 units of factor VIII in the evening, and then the subsequent morning and evening. The patient was diagnosed with hepatitis C virus-associated membranoproliferative glomerulonephritis. Treatment with interferon, ribavirin, prednisolone and cyclosporine A improved the nephrotic syndrome. This is the first report of a successful renal biopsy in a patient with haemophilia A after factor VIII injection.

Keywords: haemophilia A; hepatitis C virus; membranoproliferative glomerulonephritis; renal biopsy

Introduction

In the treatment of nephrotic syndrome, histological diagnosis with a renal biopsy is essential. A renal biopsy is generally contraindicated in patients with bleeding tendency. In haemophiliacs, there have been several reports of a needle biopsy of the liver [1–3], although a liver biopsy was once considered to be unsuitable and not recommended for haemophiliacs [4]. To our knowledge, there have been no reports of a renal biopsy for haemophiliacs. At present, the methods for preoperative administration of factor VIII in a renal biopsy are unknown. Herein, we report a patient with haemophilia A and nephrotic syndrome, in whom a renal biopsy was successfully performed with preoperative administration of recombinant factor VIII. The renal biopsy was useful in determining a definitive diagnosis and the treatment strategy for cryoglobulinaemic membranoprolif-

erative glomerulonephritis (MPGN) associated with hepatitis C virus (HCV).

Case report

A 47-year-old man was admitted to our hospital for evaluation of proteinuria in June 2004. He had a history of blood transfusion in 1977, due to unexpected bleeding after tooth extraction. In 1996, he was diagnosed with haemophilia A and chronic hepatitis associated with HCV infection. In November 2002, he complained of swelling and pain of the lower limbs. After the diagnosis of neuropathy caused by cryoglobulinaemia, prednisolone (20 mg/day) was administered, and improvement was observed. Prednisolone was stopped after 6 months. In June 2004, the patient noticed oedema and purpura on both lower extremities, and was admitted.

He was 164 cm in height and weighed 62.6 kg. The blood pressure was 170/90 mmHg. Urinalysis revealed proteinuria (2.6 g/day) and microscopic haematuria. The serum protein, albumin and creatinine levels were 6.9 g/dL, 3.1 g/dL and 1.30 mg/dL, respectively. Serologic workup included positive cryoglobulin and rheumatoid factor (430 IU/mL). Liver function tests were normal. The test for HCV antibody was positive, and serum HCV RNA was detected at a high level (392 KIU/mL) by a PCR assay. The HCV genotype was group 1. The plasma factor VIII activity was 6%. A renal biopsy was not considered because of the risk of bleeding. Based on the presumption of proteinuria caused by HCV-associated nephritis with cryoglobulinaemia, treatment was commenced with antiviral agents, consisting of injections of interferon- α of 6 million units six times/week combined with oral administration of ribavirin 400 mg/day. After discharge, serum HCV RNA disappeared, and proteinuria was reduced to 0.8 g/day. However, there were sustained episodes of leukocytopenia (800/ μ L) and anaemia (haemoglobin as low as

Table 1. Prothrombin time (PT), activated partial thrombin time (APTT) and plasma factor VIII activity after intravenous continuous administration of 3000 units for 30 min (panel A) and bolus intravenous administration of 4000 units (panel B) of recombinant factor VIII

Panel A	Before	30 min	1 h	4 h	8 h	24 h
PT%		79	79	81	84	85
APTT (s)		40.1	40.1	41.8	47.7	47.1
Factor VIII (%)	8	34	31	24	20	15

Panel B	Before	30 min	1 h	4 h	24 h
PT%	82	79	85	81	82
APTT (s)	48.6	36.6	37.4	40.7	45.0
Factor VIII (%)	10	74	69	58	20

8.8 g/dL), and side effects of interferon- α and ribavirin, and treatment was ceased 2 months later. Serum HCV RNA levels rose, again, to 307 KIU/mL, proteinuria increased to 7.7 g/day and serum albumin was decreased to 2.6 g/dL.

In order to treat the patient, based on a definite diagnosis, the patient was advised to receive a renal biopsy, despite possible bleeding risk due to haemophilia A. This was because presumption of a diagnosis without a renal biopsy, as in the first admission, could not allow us an expensive and risky treatment with a combination of pegylated interferon and ribavirin in conjunction with lenograstim and epoetin α injection. The patient was re-admitted for a renal biopsy in January 2005. Before undergoing this, an increase of serum factor VIII by intravenous administration of recombinant factor VIII (octocog alfa, Kogenate[®] FS; Bayer Health Care Pharmaceuticals, Berkley, CA, USA) was noted, as shown in Table 1. Based on these findings, a biopsy was performed in the morning, 30 min after a bolus injection of 4000 units of recombinant factor VIII, and with two passes of an automatic 16-gauge core biopsy needle (ACECUT for Nephro-Biopsy, CREATE MEDIC CO., LTD, Yokohama, Japan). The plasma factor VIII activity 30 min after the administration was 91%. In the evening of

the day of biopsy, and the following morning and evening, three bolus administrations of 3000 units of factor VIII were added. After the renal biopsy, ultrasonography of the kidney did not detect haematoma, and the blood count did not show a decrease in haemoglobin.

Light microscopic examination of the renal biopsy specimen revealed MPGN (Figure 1). Immunofluorescent microscopy revealed positive staining of C3, Ig M and Ig G (Figure 1). Electron microscopy revealed subendothelial deposits. Based on this definite diagnosis obtained from the renal biopsy, we determined to perform antiviral therapy with agents to overcome side effects, even though the therapy may be expensive. Anti-viral treatment was initiated, consisting of injection of pegylated interferon 80 μ g/week and oral administration of ribavirin 400 mg/day, combined with lenograstim and epoetin α injections to avoid leukocytopenia and anaemia, respectively. The patient was then discharged. Serum HCV RNA disappeared and proteinuria was reduced to 2.6 g/day. However, there was sustained leukocytopenia and anaemia despite the lenograstim and epoetin α injections, and so anti-viral treatment was stopped, 3 months later. After two more months, serum HCV RNA levels rose to 309 KIU/mL, and proteinuria was increased to 6.0 g/day. The patient was admitted to our hospital for the third time in June 2005. According to the next therapy of cryoglobulinaemic MPGN associated with HCV infection [5], daily oral prednisolone (40 mg/day) was started. Prednisolone was tapered, and cyclosporine A (150 mg/day) was added. One month after the treatment, proteinuria decreased to 0.2 g/day, and serum albumin increased to 3.4 g/dL.

Discussion

In the present case, in order to treat the patient with a definitive diagnosis, we determined to perform a renal biopsy, despite the possible bleeding risk due to the presence of haemophilia A. In the needle biopsy of the liver

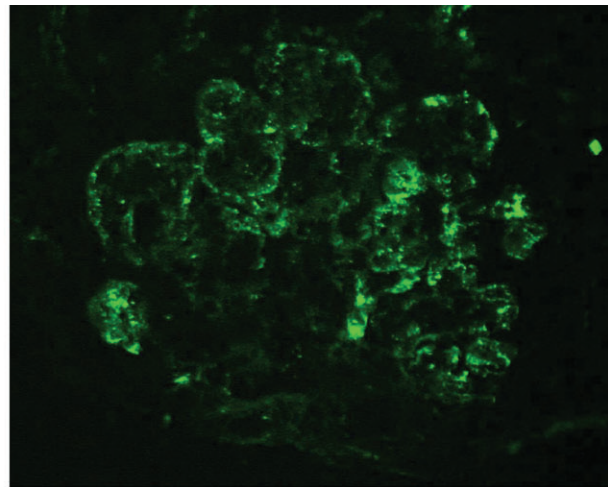
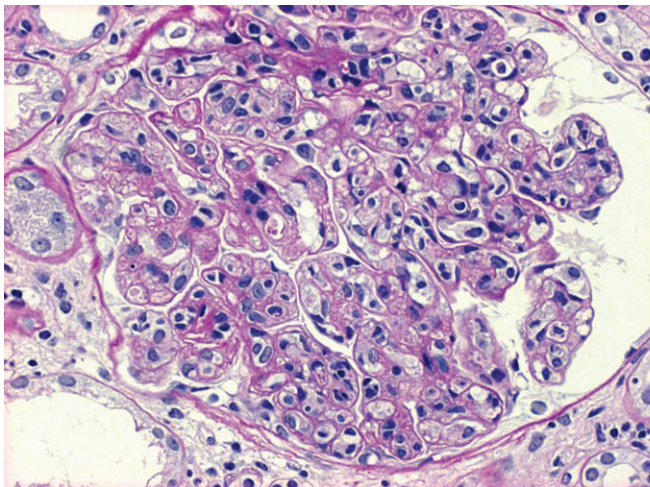


Fig. 1. PAS staining and IgG immunofluorescence of the renal biopsy specimen. Light microscopic examination of the renal biopsy specimen revealed membranoproliferative glomerulonephritis ($\times 420$). Immunofluorescence microscopy revealed positive staining for C3, Ig M and Ig G ($\times 380$).

in haemophiliacs, intravenous bolus or continuous injection of factor VIII was recommended. We examined the factor VIII activity after intravenous administration of recombinant factor VIII, at a dose of 50–60 units/body weight, as previously reported in the liver biopsy [3,6]. After confirming the increase in factor VIII, a renal biopsy was performed. As with previous reports [3,6], factor VIII was administered in the evening, and in the morning and evening the day after.

In the first admission, we performed antiviral therapy based on the presumption of HCV-associated cryoglobulinaemic glomerulonephritis, without an exact histopathological diagnosis of nephrotic syndrome. However, antiviral therapy caused serious side effects of leucopaenia and anaemia. To further perform a risky antiviral therapy with additional expensive supportive therapies with lenograstim and epoetin α injection, we needed a definite diagnosis based on the renal biopsy in this patient. Histopathological diagnosis of MPGN definitely allowed us to perform the therapy. In the treatment of HCV-associated cryoglobulinaemic MPGN, anti-viral therapy has been performed successfully since the 1990s [7]. Since then, anti-viral therapy including pegylated interferon and ribavirin has been performed [5,8]. Anti-viral therapy has been recommended for at least 48 weeks, but some patients do not respond to the therapy [5]. Although the therapy had effectiveness in reducing proteinuria and transient elimination of serum HCV in the present patient, both interferon α and pegylated interferon caused a serious side effect of leucopaenia despite the use of lenograstim and epoetin α injection, for which we abandoned treatment with anti-viral therapy. Immunosuppressive treatment is recommended in patients who are refractory to the anti-viral treatment or experience relapse after discontinuation of the anti-viral treatment [5]. In the present case, based on the definite diagnosis of HCV-associated cryoglobulinaemic MPGN, we could switch to immunosuppressive regimens. Prednisolone, with the subsequent addition of cyclosporine A, successfully led to improvement of nephrotic syndrome. Through our experience of a renal biopsy in a patient with haemophilia A, it was found that a renal biopsy should be considered to be

performed on patients in whom renal diseases are unresponsive to risky, expensive therapies and in whom some of several therapies should be chosen based on definite histopathological diagnosis, in spite of any tendency towards risk of bleeding. Our case showed that, even in patients with haemophilia A, a renal biopsy could be performed under appropriate supplementation of recombinant factor VIII.

In summary, we successfully performed a renal biopsy in a patient with haemophilia A, 30 min after intravenous bolus administration of recombinant factor VIII. The precise histological diagnosis of renal biopsy led us to definitely and successfully treat the patient with anti-viral therapy and immunosuppressive agents. To the best of our knowledge, this is the first case of a renal biopsy in haemophiliacs.

Conflict of interest statement. None declared.

References

1. Venkataramani A, Behling C, Rond R *et al.* Liver biopsies in adult haemophiliacs with hepatitis C: a United States center's experience. *Am J Gastroenterol* 2000; 95: 2374–2376
2. Schwarz KB, Zellos A, Stamato L *et al.* Percutaneous liver biopsy in haemophilic children with chronic hepatitis C virus infection. *J Pediatr Gastroenterol Nutr* 2008; 46: 423–428
3. Theodore D, Fried MW, Kleiner DE *et al.* Liver biopsy in patients with inherited disorders of coagulation and chronic hepatitis C. *Haemophilia* 2004; 10: 413–421
4. Perrillo R. Diagnosis of hepatitis C. Role of liver biopsy. *NIH Consensus Development Conference on Management of Hepatitis C, National Institute of Health: Bethesda, MD* 1997: 61–65
5. Kamar N, Rostaing L, Alric L. Treatment of hepatitis C-virus-related glomerulonephritis. *Kidney Int* 2006; 69: 436–439
6. Fukuda Y, Nakano I, Katano Y *et al.* Assessment and treatment of liver disease in Japanese haemophilia patients. *Haemophilia* 1998; 4: 595–600
7. Johnson RJ, Gretch DR, Couser WG *et al.* Hepatitis C virus-associated glomerulonephritis. Effect of alpha-interferon therapy. *Kidney Int* 1994; 46: 1700–1704
8. Alric L, Plaisier E, Thebault S *et al.* Influence of antiviral therapy in hepatitis C virus-associated cryoglobulinemic MPGN. *Am J Kidney Dis* 2004; 43: 617–623

Received for publication: 8.5.09; Accepted in revised form: 28.5.09