

Evaluation of cerebral blood flow in older patients with status epilepticus using arterial spin labeling



Tatsuya Ueno^{a,*}, Tamaki Kimura^b, Yukihisa Funamizu^a, Tomoya Kon^a, Rie Haga^a, Haruo Nishijima^a, Akira Arai^a, Chieko Suzuki^a, Jin-ichi Nunomura^a, Masayuki Baba^a, Masahiko Tomiyama^a

^a Department of Neurology, Aomori Prefectural Central Hospital, Aomori, Japan

^b Department of Neurology, National Hospital Organization Aomori Hospital, Aomori, Japan

ARTICLE INFO

Keywords:

Status epilepticus
Arterial spin labeling
Older patient
Non-convulsive status epilepticus
Magnetic resonance imaging

ABSTRACT

Introduction: Although older patients with status epilepticus (SE) have a high mortality rate and poor outcome, it is difficult to perform emergent electroencephalography (EEG) to diagnose SE in community hospitals. Arterial spin labeling (ASL) is a non-invasive magnetic resonance imaging (MRI) technique that can rapidly assess cerebral blood flow (CBF). Further, ASL can detect increased CBF in the ictal period. Therefore, ASL may be a useful tool for diagnosing SE in older patients. However, its effectiveness in this population is unknown.

Methods: We retrospectively investigated differences in CBF abnormalities between older patients (≥ 70 years) and non-older patients (< 70 years) with SE using ASL. Participants were diagnosed with convulsive status epilepticus (CSE) or non-convulsive status epilepticus (NCSE) based on symptoms, brain MRI, and EEG.

Results: ASL detected CBF abnormalities in 40% of older patients with CSE or NCSE. Rates of CBF abnormalities in older patients were not significantly different compared with that in non-older patients.

Conclusions: ASL did not detect a higher rate of CBF abnormalities in older patients, but may help physicians diagnose SE in older patients in a community hospital setting if emergent EEG cannot be immediately performed.

1. Introduction

Diagnosis of convulsive status epilepticus (CSE) is based on clinical presentation [1], whereas that of non-convulsive SE (NCSE) requires ictal electroencephalography (EEG) confirmation [2]. Few facilities can perform emergent EEG, which limits its use in clinics. In a previous study assessing its use, emergent EEG was used for diagnosis of SE in only 10.7% patients, where it was performed to rule out SE [3]. Therefore, physicians need an alternative approach for diagnosis of SE.

Arterial spin labeling (ASL) is a non-invasive magnetic resonance imaging (MRI) technique. ASL can rapidly assess cerebral blood flow (CBF) using magnetically-labeled water in blood as an endogenous tracer. A seizure increases metabolic demand in the involved cerebral cortex, accompanied by temporarily increased regional CBF [4–7]. Therefore, ASL can be used to detect increased CBF in affected regions during the ictal period of NCSE [8], and localize the seizure focus in patients with clinical seizure activity [9,10]. Furthermore, ASL in the

interictal period detects decreasing CBF [11].

SE in older people is associated with a high mortality rate and poor outcome [12]. Consequently, physicians must diagnose and treat SE as soon as possible in older patients. However, whether ASL is useful in older patients with SE remains unknown. This study aimed to identify differences in CBF abnormalities in ASL between older patients with SE and non-older patients with SE.

2. Materials and methods

Thirty-seven SE events from 35 Japanese patients (23 male) with CSE or NCSE, who were consecutively admitted to Aomori Prefectural Central Hospital for tonic-clonic SE or altered consciousness were retrospectively investigated. The patients were enrolled between January 2014 and September 2016. Seven patients who did not complete the study were excluded, including patients suspected of having NCSE with positive ASL findings and negative EEG findings. Older patients were

* Corresponding author at: Department of Neurology, Aomori Prefectural Central Hospital, 2-1-1 Higashi-Tsukurimichi, Aomori 030-8551, Japan.

E-mail addresses: tatsuya_ueno@med.pref.aomori.jp (T. Ueno), tamakik@aurora.ocn.ne.jp (T. Kimura), y_funamizu@med.pref.aomori.jp (Y. Funamizu), tk10608pc@nifty.com (T. Kon), rie_haga@med.pref.aomori.jp (R. Haga), hnishijima-tyk@umin.ac.jp (H. Nishijima), akira_arai@med.pref.aomori.jp (A. Arai), chieko_murakami@med.pref.aomori.jp (C. Suzuki), Jin-ichi_Nunomura@med.pref.aomori.jp (J.-i. Nunomura), masa_baba@med.pref.aomori.jp (M. Baba), masahiko_tomiyama@med.pref.aomori.jp (M. Tomiyama).

<https://doi.org/10.1016/j.ensci.2018.12.005>

Received 23 December 2017; Received in revised form 6 September 2018; Accepted 16 December 2018

Available online 17 December 2018

2405-6502/ © 2018 The Authors. Published by Elsevier B.V. This is an open access article under the CC BY-NC-ND license (<http://creativecommons.org/licenses/by-nc-nd/4.0/>).

Table 1
Patients' profiles.

Variables	Total (n = 30)	≥ 70 years (n = 15)	< 70 years (n = 15)	P value
Age (years)	68.5 (61.8–80)	83 (75–84)	62 (55.5–65)	< 0.001
Sex (male/female)	19/9	8/5	11/4	1
Seizure type				1
CSE, n (%)	27 (90)	13 (86.7)	14 (93.3)	
NCSE, n (%)	3 (10)	2 (13.3)	1 (6.7)	
ASL abnormality, n (%)	15 (50)	6 (40)	9 (60)	0.47
ASL abnormality with CSE, n (%)	12 (44.4)	4 (30.8)	8 (57.1)	0.26
ASL abnormality with NCSE, n (%)	3(100)	2 (100)	1 (100)	1
Time from seizure onset to MRI (hours)	8.8 (4.6–25.9)	9 (6–21)	8.5 (4–76.25)	0.84
Time from seizure onset to EEG (hours)	73 (44–118.8)	75.5 (40.8–120.5)	72 (5.5–115.5)	0.87
Etiology, n (%)				
Cerebrovascular disease	10 (33.3)	8 (53.3)	2 (13.3)	
Intracranial tumors	2 (6.7)	1 (6.7)	1 (6.7)	
Neurodegenerative disease	4 (13.3)	4 (26.7)	0	
Head trauma	2 (6.7)	1 (6.7)	1 (6.7)	
Alcohol related	3 (10)	0	3 (20)	
Metabolic disturbances	2 (6.7)	0	2 (13.3)	
Post-acute disseminated encephalomyelitis	1 (3.3)	0	1 (6.7)	
Neurosyphilis	1 (3.3)	0	1 (6.7)	
Unkown	5 (16.7)	1 (6.7)	4 (26.7)	
Change in mRS, n (%)				0.65
No change	21 (70)	10 (66.7)	11 (73.3)	
1–2	7 (23.3)	4 (26.7)	3 (20)	
4–5	2 (6.7)	1 (6.7)	1 (6.7)	

Data are median (interquartile range). We reviewed 30 clinical seizures from 28 patients.

P values were calculated using Fisher's exact test for categorical variables and the Mann–Whitney U test for continuous variables.

P values show the difference between ≥70 years and < 70 years.

Change in mRS shows the difference between the preadmission mRS and that at discharge.

Abbreviations: CSE, convulsive status epilepticus; NCSE, non-convulsive status epilepticus; ASL, arterial spin labeling; MRI, magnetic resonance imaging; EEG, electroencephalogram; mRS, modified Rankin Scale.

defined as those aged 70 years or older, and non-older patients as younger than 70 years. Participants were diagnosed with CSE or NCSE based on initial symptoms, brain MRI, and subsequent EEG [1,2]. Diagnosis of CSE was made clinically in cases of tonic-clonic SE lasting longer than 5 min [1]. NCSE was diagnosed using electro-clinical criteria for NCSE [2]. The following variables were evaluated: seizure type, CBF abnormality on ASL, time from seizure onset to MRI and EEG, etiology of SE, and difference between modified Rankin Scale (mRS) at preadmission and discharge [13]. Infection and stroke were excluded by clinical findings, images, and laboratory data.

An 18-channel digital EEG machine (Neurofax; Nihon-Kohden, Tokyo, Japan) and the International 10–20 system for electrode placement were used. EEG recordings were performed for at least 30 min. An experienced neurologist (T. K.) evaluated the EEG data. Brain MRI was obtained using a 1.5 T MR scanner (Optima MR450w; GE Healthcare, Milwaukee, WI, USA) or 3.0 T MR scanner (Discovery MR750w; GE Healthcare) at various time points depending on the patient's visit time.

ASL (pulsed continuous ASL) was prepared using a three-dimensional spiral fast spin-echo sequence. The following ASL protocol was used: repeat time, 4800 ms; echo time, 10.7 ms; slice thickness, 4.0 mm; number of excitations, 3 (3.0 T) or 4 (1.5 T); number of slices, 36; arms, 6; points, 512; field of view, 24 × 24 cm²; effective resolution, 4.44 mm; post-labeling delay, 2025 ms; and acquisition time, 3 min 34 s. All MRI data were evaluated by a neurologist (T. U.).

This study was approved by the ethics committee of Aomori Prefectural Central Hospital, Japan. Written informed consent for participation in the study was not obtained from the patients because the study was retrospective in nature and the data were analyzed anonymously.

Statistical analyses were performed with the freely available EZR software version 1.32 (Saitama Medical Center, Jichi Medical University, Saitama, Japan) [14]. P-values were calculated using Fisher's exact test for categorical variables and the Mann–Whitney U test for continuous variables. A P-value < .05 was considered statistically

significant.

3. Results

After the exclusion of seven patients, we reviewed a total of 30 clinical seizures in 28 patients with CSE or NCSE (Table 1). Two patients were hospitalized for seizure recurrence. We obtained 16 ASL images from 1.5 T MRI and 14 ASL images from 3 T MRI.

The median age was 68.5 years (interquartile range [IQR]: 61.8–80 years). The SE etiologies were: cerebrovascular disease (n = 10), intracranial tumors (n = 2), neurodegenerative disease (n = 4), head trauma (n = 2), alcohol-related (n = 3), metabolic disturbances (n = 2), post-acute disseminated encephalomyelitis (n = 1), neurosyphilis (n = 1), and unknown (n = 5). Use of anti-epileptic drugs before MRI evaluation in CSE and NCSE patients was 81.5% and 33.3%, respectively. The anti-epileptic drugs used before ASL were: diazepam (n = 17), midazolam (n = 5), levetiracetam (n = 6), phenytoin (n = 5), phenobarbital (n = 5), valproate (n = 2), and carbamazepine (n = 2), including combination therapy.

ASL was performed for each clinical seizure. Of the 30 seizures, 27 were diagnosed as CSE and 3 as NCSE. Further, CBF abnormalities were detected by ASL in 15 (50%) cases. Of the CSE seizures, five were generalized convulsive SE, 16 were focal onset evolving into bilateral convulsive SE, and 6 were unknown (whether focal or generalized SE). Median time (IQR) from seizure onset to MRI and EEG was 8.8 (4.6–25.9) h and 73 (44–118.8) h, respectively. The difference between mRS at preadmission and discharge was: unchanged in 21 patients (70%), 1 to 2 points of deterioration in seven patients (23.3%), and 4 to 5 points of deterioration in two patients (6.7%).

The frequency of CSE and NCSE was not significantly different between older and non-older patients (CSE: 86.7% vs. 93.3%; NCSE: 13.3% vs. 6.7%; older vs. non-older for both comparisons). The rates of CBF abnormality in older patients with CSE and NCSE were 30.8% and 100%, respectively. Abnormalities in CBF were observed in 40% of older patients and 60% of non-older patients. These variables were not

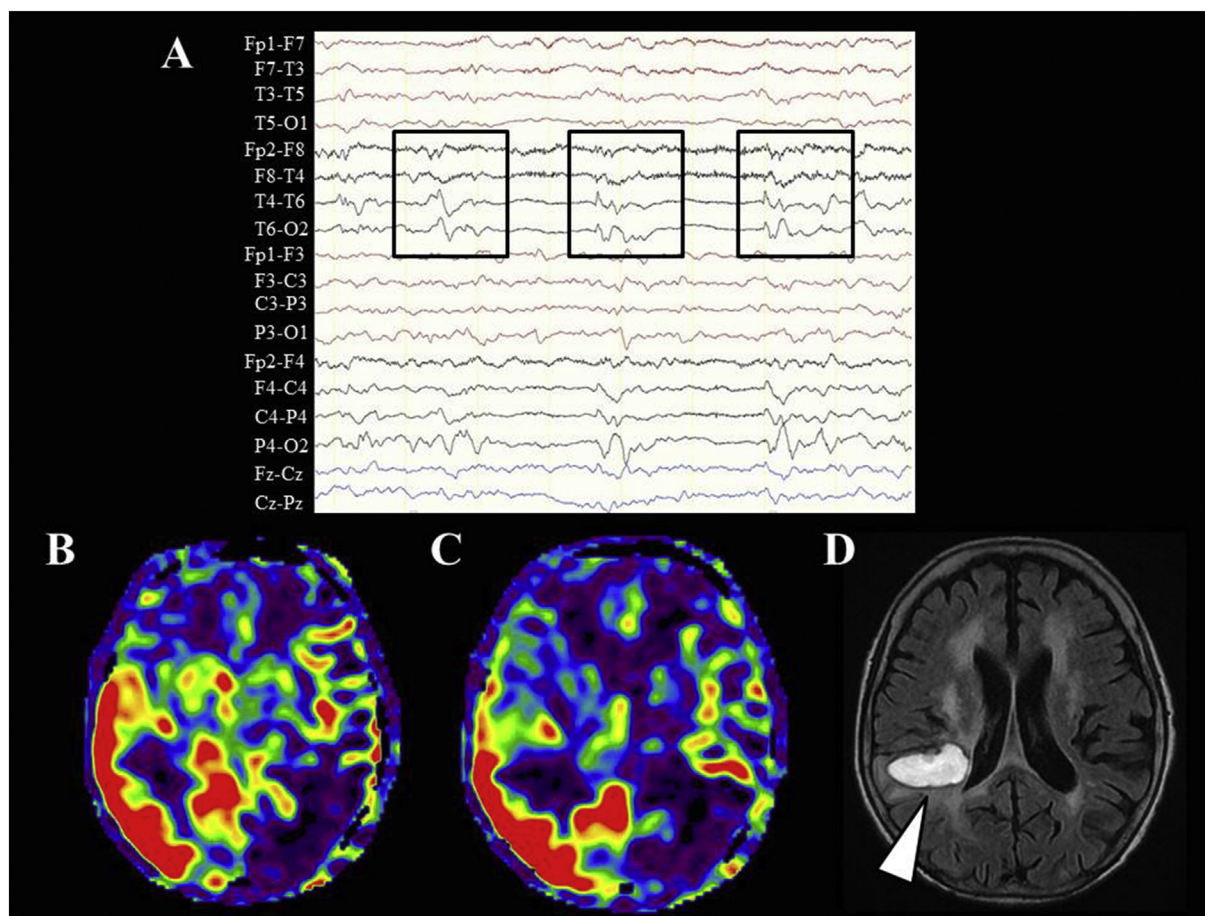


Fig. 1. An 85-year-old woman with right temporal intracerebral hemorrhage presenting with generalized tonic-clonic seizure. (A) Electroencephalography recording shows right-side lateralized periodic discharges (boxes). (B, C) Arterial spin labeling image shows hyperperfusion of cerebral blood flow in the right temporo-parietal lobe. Hyperperfusion is indicated by the red color. (D) Fluid-attenuated inversion recovery image displays an intracerebral hemorrhage (arrow) in the right temporal lobe. (For interpretation of the references to color in this figure legend, the reader is referred to the web version of this article.)

significantly different between the two groups (95% confidence interval: 15.1% to 55.1%, $P = .47$). Time from seizure onset to MRI and EEG was not significantly different between older and non-older patients (MRI: 9 vs. 8.5 h, $P = .84$; EEG: 75.5 vs. 72 h, $P = .87$). With regard to change in mRS, there was no significant difference in overall seizures between older and non-older patients ($P = .65$). The type of CSE and whether anti-epileptic drugs were used before ASL showed no significant differences in CBF abnormalities.

Representative EEG recordings and ASL images from the same patient are shown in Fig. 1. ASL showed regional CBF hyperperfusion in SE.

4. Discussion

Here, ASL detected CBF abnormalities in 40% of older patients (≥ 70 years) with CSE or NCSE. The rate of CBF abnormality in older patients was not significantly different compared with that in non-older patients. Furthermore, ASL detected CBF abnormalities more often in patients with NCSE. Changes in mRS were not significantly different between older and non-older patients.

NCSE tends to occur more frequently in older patients [12]. Although continuous EEG is the gold standard for diagnosing NCSE, few facilities have the capabilities to perform continuous or emergent EEG, which limits their clinical use outside of epileptic centers. This may result in a time delay from seizure onset to initial EEG assessment in a community hospital. The frequency of NCSE may be underestimated in this study because the average time delay from seizure onset to EEG

was 73 h in all patients. ASL can rapidly and non-invasively evaluate CBF [8]. In this study, time from seizure onset to performing MRI was 8.8 h, which was evaluated earlier than EEG (73 h). As a result, ASL detected CBF abnormalities in 40% of older patients and 60% of non-older patients with CSE or NCSE. The rate of CBF abnormality was not significantly different between older and non-older patients. Few older patients with seizures have abnormal interictal EEG [15], and performing continuous and emergent EEG for detecting ictal EEG is difficult. Therefore, we believe that if ASL can be performed as soon as possible from seizure onset, peri-ictal ASL may be a useful diagnostic tool for older patients with SE. It is important to note however, that cortical hyperperfusion shown by ASL does not always indicate SE. In the clinical course of acute onset, the differential diagnosis of cortical hyperperfusion in ASL includes hyperperfusion after vascular recanalization in ischemic stroke [16] and hyperperfusion in SE [4,8]. To identify the cause of hyperperfusion, clinicians should consider the clinical course, vascular territories in cortical hyperperfusion, and other MRI sequences, such as diffusion weighted imaging and MR angiography.

Shimogawa et al. have demonstrated that patients with NCSE show local CBF abnormalities, and initial use of ASL can diagnose NCSE [8]. In the present study, of seven excluded patients, five patients were inferred to be NCSE from the clinical course and MRI findings, such as diffusion weighted imaging and MR angiography. These five patients had positive ASL findings and negative EEG findings. We were not able to definitively diagnose NCSE because of the negative EEG findings. One reason for dissociation of the MRI and EEG findings in these

patients may be due to a delay in the time to perform the EEG. Because this study has a time discrepancy between EEG and ASL, the EEG findings may not accurately represent the ictal period of NCSE. Nonetheless, we detected CBF abnormalities in all three patients with NCSE using ASL. These results suggest that patients with NCSE show ictal ASL findings because the diagnostic criteria for NCSE requires ictal EEG [2]. However, ASL detected a CBF abnormality in only 30.8% of older patients with CSE. For patients with CSE, MRI was performed after administration of necessary treatment because patient rest is necessary for ASL imaging. If we could not control SE in the patient, continuous midazolam infusion or phenobarbital were started. We performed ASL MRI when patients with CSE were stable. This was because CSE is easily diagnosed based on clinical symptoms and is a life-threatening emergent disorder [1]. Because of this delay, ASL findings might not represent ictal perfusion, and thus may not have detected a CBF abnormality in the CSE cases in our study. If the increase of localized CBF is shown by ASL MRI after treatment of CSE, the possibility of localization-related epilepsy increases [9], thereby indicating a need for a therapy specific to localization-related epilepsy, such as sodium channel blockers. NCSE develops after CSE in some patients [17]. Another reason for performing ASL MRI after CSE is that if the disturbance of consciousness persists after CSE in a patient, ASL MRI may show regional hyperperfusion due to NCSE. Thus, ASL might be a useful additional tool to characterize a patient with SE, and in selected cases, the information of hyperperfusion in symptomatic areas could help to confirm the diagnosis.

In our study, we found that mRS changes were not significantly different between older and non-older patients. Preadmission mRS may contribute to the rate of change in mRS. This possibility is supported by our finding that mRS was 3–4 at preadmission in 60% of older patients and 26.7% of non-older patients. Older patients tend to have more comorbidities before admission to hospital, such as cerebrovascular disease and neurodegenerative disease. Therefore, differences in mRS changes may have resulted from preadmission complications in older patients.

Our study has several limitations. First, this was a retrospective study, with a small number of patients from a single community hospital. Because of the small sample size, we could not control for confounding factors and were unable to conclude whether older and non-older patients show positive ASL findings at the same rate. Further prospective studies are needed to examine this issue. Second, we may have underestimated the frequency of NCSE because we could not perform continuous and emergent EEG in our hospital. Although we excluded patients suspected of having NCSE with positive ASL findings and negative EEG findings, the EEG time delay may contribute to the detection rate of ictal EEG for diagnosing NCSE. Finally, the median time from seizure onset to MRI was 8.8 h. This prolonged time gap between seizure onset and performing ASL might have decreased the sensitivity of ASL.

In conclusion, ASL may help physicians diagnose SE in older patients in a community hospital setting if continuous EEG and emergent EEG cannot be immediately performed.

Conflicts of interest

None.

Funding

This research did not receive any specific grant from funding agencies in the public, commercial, or not-for-profit sectors.

Acknowledgments

The authors would like to thank the staff of the Department of Radiology. Edanz Group (www.edanzediting.com/ac) supplied English language editing services for a draft of this manuscript.

References

- [1] E. Trinka, H. Cock, D. Hesdorffer, et al., A definition and classification of status epilepticus—report of the ILAE task force on classification of status epilepticus, *Epilepsia* 56 (10) (2015) 1515–1523.
- [2] M. Leitinger, S. Beniczky, A. Rohrer, et al., Salzburg consensus criteria for non-convulsive status epilepticus—approach to clinical application, *Epilepsy Behav.* 49 (2015) 158–163.
- [3] P.N. Varelas, M.V. Spanaki, L. Hacin-Bey, et al., Emergent EEG: indications and diagnostic yield, *Neurology* 61 (5) (2003) 702–704.
- [4] R.E. Yoo, T.J. Yun, B.W. Yoon, et al., Identification of cerebral perfusion using arterial spin labeling in patients with seizures in acute settings, *PLoS One* 12 (3) (2017) e0173538.
- [5] T.H. Schwartz, Neurovascular coupling and epilepsy: hemodynamic markers for localizing and predicting seizure onset, *Epilepsy Curr.* 7 (4) (2007) 91–94.
- [6] D.C. Alsop, A. Connelly, J.S. Duncan, et al., Diffusion and perfusion MRI in epilepsy, *Epilepsia* 43 (s1) (2002) 69–77.
- [7] E. Wilder-Smith, A.C. Nirako, Contribution of concurrent Doppler and EEG in differentiating occipital epileptic discharges from migraine, *Neurology* 41 (12) (1991) 2005–2007.
- [8] T. Shimogawa, T. Morioka, T. Sayama, et al., The initial use of arterial spin labeling perfusion and diffusion-weighted magnetic resonance images in the diagnosis of nonconvulsive partial status epilepticus, *Epilepsy Res.* 129 (2017) 162–173.
- [9] B.S. Kim, S.T. Lee, T.J. Yun, et al., Capability of arterial spin labeling MR imaging in localizing seizure focus in clinical seizure activity, *Eur. J. Radiol.* 85 (7) (2016) 1295–1303.
- [10] D. Nguyen, V. Kapina, M. Seeck, et al., Ictal hyperperfusion demonstrated by arterial spin-labeling MRI in status epilepticus, *J. Neuroradiol.* 37 (4) (2010) 250–251.
- [11] N. Pendse, M. Wissmeyer, S. Altrichter, et al., Interictal arterial spin-labeling MRI perfusion in intractable epilepsy, *J. Neuroradiol.* 37 (1) (2010) 60–63.
- [12] A. Rohrer, D.P. Reiter, F. Brigo, et al., Status epilepticus in the elderly—a retrospective study on 120 patients, *Epilepsy Res.* 127 (2016) 317–323.
- [13] J.L. Banks, C.A. Marotta, Outcomes validity and reliability of the modified Rankin scale: implications for stroke clinical trials: a literature review and synthesis, *Stroke* 38 (3) (2007) 1091–1096.
- [14] Y. Kanda, Investigation of the freely available easy-to-use software ‘EZR’ for medical statistics, *Bone Marrow Transplant.* 48 (3) (2013) 452–458.
- [15] L.J. Stephen, M.J. Brodie, Epilepsy in elderly people, *Lancet* 355 (9213) (2000) 1441–1446.
- [16] S. Vercllytte, O. Fisch, L. Colas, et al., ASL and susceptibility-weighted imaging contribution to the management of acute ischaemic stroke, *Insights Imaging* 8 (1) (2017) 91–100.
- [17] R.J. Delorenzo, E.J. Waterhouse, A.R. Towne, et al., Persistent nonconvulsive status epilepticus after the control of convulsive status epilepticus, *Epilepsia* 39 (8) (1998) 833–840.