

# Effect of Intravitreal Injection of Bevacizumab on Acute Central Serous Chorioretinopathy Patients Who Visited Feiz Hospital during 2014–2015 Period

## Abstract

**Background:** Aim of this clinical trial is the evaluation of the effect of intravitreal injection of bevacizumab on acute central serous chorioretinopathy (CSC). **Materials and Methods:** In a nonrandomized clinical trial, 36 CSC eyes (with <1-month disease history) were examined. Initially, all the patients underwent posterior and anterior segment examinations as well as complete eye examination to evaluate the best spectacle-corrected visual acuity (BSCVA). Then, optical coherence tomography was performed to confirm the diagnosis. The patients were divided to the two groups each of 18 subjects, which 18 patients received intravitreal injection of bevacizumab (1.25 mg) and the rest of them did not receive any treatment (control group). The patients were health checked by the end of the 1<sup>st</sup> and 3<sup>rd</sup> months. Significance level was considered as  $P < 0.05$ . **Results:** In the BSCVA, no significant difference in visual improvement was observed in baseline vision compared to each other ( $P = 0.481$ ). There was also no significant difference in the vision of intervention and control groups 1 and 3 months after injection ( $P = 0.379$  and  $P = 0.557$ ). A significant decrement existed in the intervention group compared with the control group in the maximum central macular thickness at 1 month after injection ( $P = 0.001$ ); however, the difference was not significant when comparing the two groups at baseline and 3 months after injection ( $P = 0.925$  and  $P = 0.338$ ). **Conclusion:** In general, according to the results of this study, intravitreal injection of bevacizumab was not effective in improvement of patients with acute CSC, although it had no side effects.

**Keywords:** Bevacizumab, central serous chorioretinopathy, intravitreal injection

## Introduction

Central serous chorioretinopathy (CSC), also known as central serous retinopathy (CSR), is an eye disease which causes visual impairment, often temporary and usually in one eye.<sup>[1,2]</sup> CSC is characterized by a serous detachment of the neurosensory retina, usually in the macular region and among men aged 30–50 years.<sup>[3,4]</sup> Active CSC is characterized by the leakage of fluid under the retina that has a propensity to accumulate under the yellowish central portion of the retina (macula).

This leads to blurred and distorted vision (metamorphopsia). A blurred or gray spot in the central visual field is common when the retina is detached. Reduced visual acuity may persist after the fluid has been absorbed.<sup>[5,6]</sup> Risk factors include stress, type A personality, systemic corticosteroid use, and pregnancy.<sup>[7-9]</sup>

The exact mechanism of CSC is not clear, but abnormal choroidal vessels

congestion appears to have an important role.<sup>[10-12]</sup> CSC may be due to arterial ischemia caused by delayed arterial filling.<sup>[9,10]</sup> Traditional follow-up has been observed until the disease's symptoms have been spontaneously improved. Laser photocoagulation is an alternative laser treatment for curing leakage and absorption of sub retinal fluid.<sup>[11,12]</sup> Although laser treatment accelerates CSC improvement, it has no impact on the ultimate vision of the patients.<sup>[5]</sup> Photodynamic therapy (PDT) is also another treatment method for CSC. Although several studies have proven the positive effect of PDT on CSC treatment,<sup>[13-15]</sup> it is associated with potential complications namely retinal pigment epithelium (RPE) layer atrophy, choroidal neo-vascularization, and choroidal ischemia.<sup>[16]</sup>

Vascular endothelial growth factor (VEGF) is caused by vessel cells damaged by

**How to cite this article:** Akhlaghi MR, Nasrollahi C, Namgar SM, Kianersi F, Dehghani AR, Arefpour R. Effect of Intravitreal Injection of Bevacizumab on Acute Central Serous Chorioretinopathy Patients who Visited Feiz Hospital during 2014–2015 Period. *Adv Biomed Res* 2017;6:125.

**Received:** June, 2015. **Accepted:** October, 2015.

Mohamad Reza Akhlaghi,  
Cobra Nasrollahi,  
Seyed Mohamad Namgar,  
Farzan Kianersi,  
Ali Reza Dehghani,  
Reza Arefpour

From the Isfahan Eye Research Center, Isfahan University of Medical Sciences, Isfahan, Iran

*Address for correspondence:*  
Dr. Seyed Mohamad Namgar,  
Isfahan Eye Research Center,  
Isfahan University of Medical  
Sciences, Isfahan, Iran.  
E-mail: s.mnamgar11@gmail.com

Access this article online

Website: [www.advbiores.net](http://www.advbiores.net)

DOI: 10.4103/abr.abr\_193\_15

Quick Response Code:



This is an open access article distributed under the terms of the Creative Commons Attribution-NonCommercial-ShareAlike 3.0 License, which allows others to remix, tweak, and build upon the work non-commercially, as long as the author is credited and the new creations are licensed under the identical terms.

For reprints contact: [reprints@medknow.com](mailto:reprints@medknow.com)

vascular blood disorder-induced ischemia and increases vascular permeability and tissue edema.<sup>[17]</sup> Recently in some cases, intravitreal injection of anti-VEGF factors such as bevacizumab and lucentis has been used for CSC treatment, leading to a variety of results.<sup>[5,18]</sup> Aydin studied the efficiency of intravitreal bevacizumab for acute CSC and found that it resulted in a remarkable improvement in visual acuity within 3 months, compared to the control group. These results suggest intravitreal injection to be a promising solution for curing acute CSC patients.<sup>[19]</sup> Results from a study by Korean J entitled, “the effect of intravitreal bevacizumab in patients with acute CSC,” showed that it was associated with the improvement of visual acuity and reduction of neural sensitivity; in addition, there were no adverse effects of treatment.<sup>[20]</sup>

On the other hand, a study by Mehany *et al.*, entitled “intravitreal bevacizumab to treat acute CSC,” suggested that intravitreal bevacizumab had no positive effect on CSC, compared to the control group; in addition, it had no treatment complications.<sup>[8]</sup> Discrepancy of results motivated us to investigate the effect of intravitreal injection of bevacizumab on acute CSC patients.

## Materials and Methods

In a nonrandomized clinical trial, 53 consecutive patients, who visited Feiz Hospital in Isfahan for acute CSC, were examined. Among the 53 patients, 36 patients had the inclusion criteria.

The inclusion criteria were as follows: Patients with acute CSC of <1-month duration. Lack of cooperation or unwillingness to cooperate with follow-up within 1 or 3 months after the treatment; patients with a history of chronic illness, single eye, and a history of CSC and other eye diseases that have a devastating effect on the retina, comprised the exclusion criteria.

All the patients were examined first for and then underwent posterior and anterior segment examinations and complete eyes examinations to evaluate the best spectacle-corrected visual acuity (BSCVA) using Snellen visual chart. Then, optical coherence tomography (OCT) was performed to confirm the diagnosis [Figure 1]. The patients were divided to the two groups each of 18 subjects, out of which 18 patients received intravitreal injection of

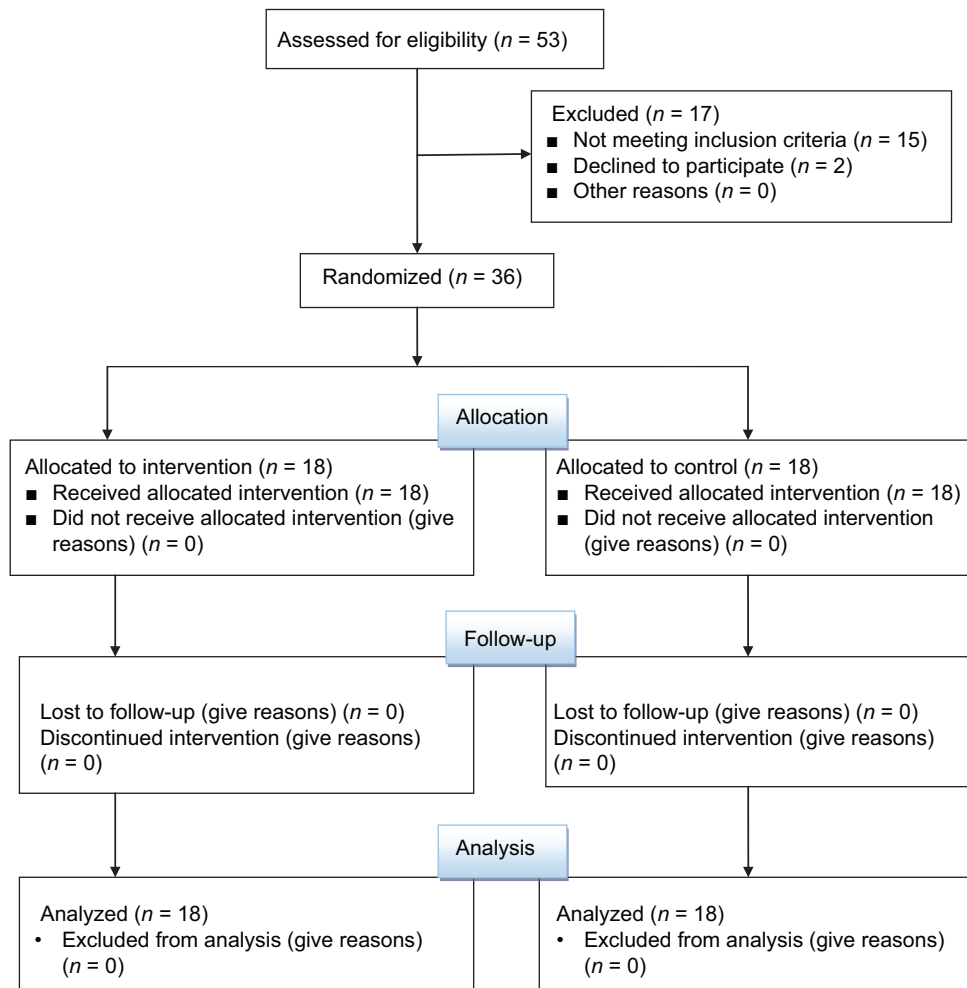


Figure 1: Criteria eligibility

bevacizumab (1.25 mg), and the rest of them did not receive any treatment (control group).

All intravitreal injections were performed in the operating room under sterile conditions. Topical anesthetic drops were given first and then a lid speculum was inserted. After cleaning the injection site with 5% povidone-iodine, a 30-gauge needle was inserted through the pars plana and 0.05 mL (1.25 mg) of bevacizumab was injected. Tonometry and funduscopy were performed 1 day after the procedure to detect any injection-related complications. Patients were given topical antibiotics 4 times daily for 1 week after each injection procedure.

The patients were examined by the end of the 1<sup>st</sup> and 3<sup>rd</sup> months and at each follow-up examination of BCVA, and funduscopy and OCT were performed.

Data analysis was done by descriptive statistical methods (mean ± standard deviation), means difference test for independent groups, *t*-test, and Fisher exact test with the use of SPSS 20 software (SPSS Inc., Chicago, Illinois, USA). *P* < 0.05 was considered statistically significant.

## Results

A total of 36 patients (eyes) were evaluated in this study. They were divided into two groups of 18 subjects; patients in the intervention group received intravitreal bevacizumab and the controls received no treatment. The intervention and control groups included 1 and 3 women and 17 and 15 men, respectively. No significant difference was observed between the groups in terms of age and gender [Table 1].

Although the BSCVA was significantly reduced in both intervention and control groups, no significant improvement was observed in baseline vision compared to each other (*P* = 0.481). There was also no significant difference in the vision of intervention and control groups 1 and 3 months after injection (*P* = 0.379, *P* = 0.557) [Table 2].

A significant decrement existed in the intervention group compared with the control group in the maximum central macular thickness (CMT max) at 1 month after injection (*P* = 0.001); however, the difference was not significant when comparing the two groups at baseline and 3 months after injection (*P* = 0.925 and *P* = 0.338) [Table 3].

## Discussion

CSC, also known as CSR, is an eye disease which causes visual impairment, often temporary, usually in one eye.<sup>[21,8]</sup> When the disorder is active, it is characterized by leakage of fluid under the retina that has a propensity to accumulate under the central macula. This results in blurred or distorted vision (metamorphopsia). A blurred or gray spot in the central visual field is common when the retina is detached. Reduced visual acuity may persist after the fluid has disappeared.<sup>[22]</sup> The disease is considered idiopathic, but mostly affects white males in the age group 20–50, but

**Table 1: Comparison of demographic data in both groups**

	Control group	Intervention group	<i>P</i>
Mean age (year)	31.38±4.8	32.88±6.32	0.428
Gender (male/female)	15/3	17/1	0.302

**Table 2: The BSCVA in both groups according to Log MAR**

Timing	Mean±SD		<i>P</i>
	Intervention group	Control group	
Baseline	0.40±0.26	0.35±0.17	0.481
1 month	0.22±0.13	0.25±0.12	0.379
3months	0.13±0.09	0.15±0.09	0.557

BSCVA: Best spectacle-corrected visual acuity, SD: Standard deviation

**Table 3: CMT max in both groups in µm**

Timing	Mean±SD		<i>P</i>
	Intervention group	Control group	
Baseline	540.44±130.7	536.33±127.17	0.925
1 month	321.17±48.38	373.89±38.25	0.001
3months	274.5±38.46	288.72±48.72	0.338

CMT max: Maximum central macular thickness, SD: Standard deviation

occasionally other groups. The condition is believed to be exacerbated by stress or corticosteroid use. SC has long been considered a condition that will resolve spontaneously and thus the mainstay of management is usually observation alone.<sup>[5]</sup> There is, however, some evidence to support the benefit of early treatment of acute CSC. A potential benefit of early resolution of sub retinal fluid might be mediated by a lower rate of RPE degeneration in the treated eye, which might be warranted due to the uncertain relationship between the onset of detachment and the onset of symptoms and special occupational demands for binocular vision function. This has led clinicians to search for a more effective treatment alternative, one less likely than PDT or focal laser photocoagulation to cause side effects. Although focal laser photocoagulation and PDT have proven effective for the treatment of CSC, these treatments can cause permanent damage to the RPE or choriocapillaris, retinal thermal injury, and subretinal choroidal neovascularization, often many years following the primary incident.<sup>[5,18]</sup> VEGF has dramatic effects on vascular permeability. The direct role of VEGF in CSC, however, remains unknown. Indocyanine green in patients with CSC has provided evidence of choroidal lobular ischemia, choroidal venous congestion, and multiple areas of choroidal vascular hyperpermeability.<sup>[15,18]</sup> Choroidal ischemia in CSC may induce an increase in the concentration of VEGF.

In Lim *et al.* study<sup>[19]</sup> demonstrated that aqueous VEGF levels are increased in a portion of patients with chronic CSC, but not in acute CSC. Several reports, however,

indicate that intravitreal bevacizumab injection improves vision and reduces the incidence of neurosensory detachment in patients with acute CSC.<sup>[8,20]</sup> Ranibizumab is a humanized anti-VEGF antibody that inhibits all forms of biologically active VEGF.<sup>[22]</sup> Our results showed that no significant difference exists between the intervention and control groups in the BSCVA. However, in the study of Aydin showed that intravitreal bevacizumab injection for acute Central Serous Chorioretinopathy (CSCR) can lead to remarkable improvements of visual acuity within 3 months follow-up compared with controls. These results demonstrated that intravitreal bevacizumab injection may be a promising option for selected patients in the treatment of acute CSCR. Moreover, also in a study, Mehany *et al.* showed intravitreal Avastin injection with improved vision and decreased sensory nerve detachment and had no side effects in patients with CSC. The results were promising, but the authors recommend that, randomized controlled studies would be more useful to understand the treatment for patients with CSC. Moreover, in another study, intravitreal bevacizumab showed no positive effect in acute CSC patients compared to the observation group.

The present study has some limitations. First, this is not a randomized, controlled clinical study and the follow-up duration was limited to approximately 3 months. Second, our study has a relatively small sample size.

## Conclusion

At last, compared with observation, intravitreal anti-VEGF therapy showed no positive effect in terms of visual outcome during the 3 months' follow-up period, although it had no side effects. In a recent study, a significant reduction in CMT was only 1 month after injection. However, there was not significant difference between the two groups in other times. Therefore, it is possible to increase the number of samples and there was a significant difference in this regard.

## Financial support and sponsorship

Nil.

## Conflicts of interest

There are no conflicts of interest.

## References

1. Wang M, Munch IC, Hasler PW, Prunte C, Larsen M. Central serous chorioretinopathy. *Acta Ophthalmol* 2008;86:126-45.
2. Torres-Soriano ME, García-Aguirre G, Kon-Jara V, Ustariz-González O, Abraham-Marín M, Ober MD, *et al.* A pilot study of intravitreal bevacizumab for the treatment of central serous chorioretinopathy (case reports). *Graefes Arch Clin Exp Ophthalmol* 2008;246:1235-9.
3. Boscia F. When to treat and not to treat patients with central serous retinopathy. *Retin Today* 2010;42:32-34.
4. Wei SY, Yang CM. Transpupillary thermotherapy in the treatment of central serous chorioretinopathy. *Ophthalmic Surg Lasers Imaging* 2005;36:412-5.
5. Taban M, Boyer DS, Thomas EL, Taban M. Chronic central serous chorioretinopathy: Photodynamic therapy. *Am J Ophthalmol* 2004;137:1073-80.
6. Ryan SJ. Retina. In: Christina M, editor. *Central Serous Chorioretinopathy*. 4<sup>th</sup> ed. China: Elsevier, Mosby; 2006. p. 1135-61.
7. Maia A. A new treatment for chronic central serous retinopathy. *Retin Today* 2010. Retrieved 2013-08-11. [Last accessed on 2013 Aug 11].
8. Mehany SA, Shawkat AM, Sayed MF, Mourad KM. Role of avastin in management of central serous chorioretinopathy. *Saudi J Ophthalmol* 2010;24:69-75.
9. Caccavale A, Romanazzi F, Imparato M, Negri A, Morano A, Ferentini F. Central serous chorioretinopathy: A pathogenetic model. *Clin Ophthalmol* 2011;5:239-43.
10. Colucciello M. Central serous retinopathy. *Retin Physician* 2010. Available from: <http://www.retinalphysician.com/article.aspx>. [Last accessed on 2012 Jun 01].
11. Meyerle CB, Freund KB, Bhatnagar P, Shah V, Yannuzzi LA. Ketoconazole in the treatment of chronic idiopathic central serous chorioretinopathy. *Retina* 2007;27:943-6.
12. Avery RL, Pieramici DJ, Rabena MD, Castellarin AA, Nasir MA, Giust MJ. Intravitreal bevacizumab (Avastin) for neovascular age-related macular degeneration. *Ophthalmology* 2006;113:363-372.e5.
13. Costa RA, Jorge R, Calucci D, Melo LA Jr, Cardillo JA, Scott IU. Intravitreal bevacizumab (avastin) for central and hemicentral retinal vein occlusions: IBeVO study. *Retina* 2007;27:141-9.
14. Rabena MD, Pieramici DJ, Castellarin AA, Nasir MA, Avery RL. Intravitreal bevacizumab (avastin) in the treatment of macular edema secondary to branch retinal vein occlusion. *Retina* 2007;27:419-25.
15. Yap EY, Robertson DM. The long-term outcome of central serous chorioretinopathy. *Arch Ophthalmol* 1996;114:689-92.
16. Vingrys AJ, Pesudovs K. Localized scotomata detected with temporal modulation perimetry in central serous chorioretinopathy. *Aust N Z J Ophthalmol* 1999;27:109-16.
17. Prunte C, Flammer J. Choroidal capillary and venous congestion in central serous chorioretinopathy. *Am J Ophthalmol* 1996;121:26-34.
18. Prunte C. Indocyanine green angiographic findings in central serous chorioretinopathy. *Int Ophthalmol* 1995;19:77-82.
19. Aydin E. The efficacy of intravitreal bevacizumab for acute central serous chorioretinopathy. *J Ocul Pharmacol Ther* 2013;29:10-3.
20. Lim JW, Ryu SJ, Shin MC. The effect of intravitreal bevacizumab in patients with acute central serous chorioretinopathy. *Korean J Ophthalmol* 2010;24:155-8.
21. Lim SJ, Roh MI, Kwon OW. Intravitreal bevacizumab injection for central serous chorioretinopathy. *Retina* 2010;30:100-6.
22. Seong HK, Bae JH, Kim ES, Han JR, Nam WH, Kim HK. Intravitreal bevacizumab to treat acute central serous chorioretinopathy: Short-term effect. *Ophthalmologica* 2009;223:343-7.