

# Osteomyelitis Caused by Carbapenemase-Producing *Klebsiella Pneumoniae*: A Diagnosis to Consider in Patients with Hematologic Malignancies and Stem Cell Transplant Recipients

Authors' Contribution:  
Study Design A  
Data Collection B  
Statistical Analysis C  
Data Interpretation D  
Manuscript Preparation E  
Literature Search F  
Funds Collection G

ABCDEF 1 **Ana C. Alho**  
ABCDEF 1 **Joana Infante**  
AE 2 **Eduarda Carmo**  
AEG 1 **João Raposo**

1 Department of Hematology and Bone Marrow Transplantation, Hospital de Santa Maria, CHLN – EPE, Lisboa, Portugal  
2 Intensive Care Unit, Hospital de Egas Moniz, CHLO – EPE, Lisboa, Portugal

**Corresponding Author:** Ana C. Alho, e-mail: [anaalho@medicina.ulisboa.pt](mailto:anaalho@medicina.ulisboa.pt)

**Conflict of interest:** None declared

## Case series

**Patients:** Female, 49 • Female, 47  
**Final Diagnosis:** Osteomyelitis by *Klebsiella pneumoniae*  
**Symptoms:** Fever  
**Medication:** —  
**Clinical Procedure:** —  
**Specialty:** Hematology

**Objective:** Rare disease

**Background:** Osteomyelitis (OM) due to carbapenemase-producing *Klebsiella pneumoniae* (CPKp) is a very rare but severe condition, particularly among patients with hematologic malignancies and stem cell transplant recipients, who are especially at risk of developing nosocomial infections caused by this bacterium.

**Case Report:** We describe 2 cases of acute and chronic OM by CPKp in adults with hematologic disorders. Patient 1, with acute lymphoblastic leukemia, developed bacteremia due to multidrug CPKp after induction chemotherapy. Despite pathogen-directed antibiotic treatment, blood cultures remained positive for CPKp, with an increase in its resistance pattern, and worsening of clinical condition. A pelvic computed tomography revealed air bubbles in the femoral head and ilium, suggestive of OM, and bone culture was positive for pandrug-resistant CPKp. The clinical condition deteriorated rapidly and the patient died. Patient 2, with aplastic anemia, developed multidrug CPKp bacteremia after immunosuppressive therapy, with good response to pathogen-directed antibiotic treatment. Ten months later, she underwent a hematopoietic stem cell transplant, and at the time of neutrophil engraftment, an abscess developed in the right thigh. An extensively drug-resistant CPKp was isolated from the pus, and antibiotics were started, without clinical improvement. A magnetic resonance of the thigh revealed an intraosseous abscess, suggestive of OM, and after debridement surgery and 6 weeks of parenteral antibiotics, she was successfully discharged home.

**Conclusions:** OM due to CPKp is uncommonly reported. These 2 cases illustrate the complex management of OM by CPKp in immunocompromised hematologic patients, and the importance of clinical suspicion for a prompt diagnosis, early treatment, and successful outcome.

**MeSH Keywords:** Hematologic Diseases • Immunocompromised Host • *Klebsiella Pneumoniae* • Osteomyelitis

**Full-text PDF:** <https://www.amjcaserep.com/abstract/index/idArt/909965>



2090 2 2 22

## Background

Osteomyelitis (OM) is one of the most challenging bone infections, characterized by inflammatory destruction of bone marrow and surrounding bone, caused by an infecting microorganism [1,2]. Its incidence is low, since the normal bone is highly resistant to infection, and most cases occur in patients with risk factors such as diabetes, immunosuppression, malignancy, decubitus ulcers, surgery, trauma, chronic intravenous drug users, and/or smoking [3]. Despite the low incidence of OM, the number of cases have increased over the last decades, partly due to a significant increase in the prevalence of patients at risk [4].

The prognosis of OM depends on the immune status and comorbidities of the patient, and on the virulence of the infecting microorganism [5]. Gram-negative bacilli such as *Klebsiella pneumoniae* represent a minor portion of all the microorganisms isolated in OM [6]. However, with the global emergence of nosocomial infections by highly drug-resistant CPKp, we expect an increasing incidence of OM caused by this agent, particularly among immunocompromised patients [7,8]. So far, only 2 cases of OM by CPKp have been reported [9,10]. Patients with hematologic malignancies and stem cell transplant recipients are a very high-risk population for both severe OM and CPKp infections [11].

The pathophysiology of OM is multifactorial, and the microorganism may reach the bone by either hematogenous spread or spread from a contiguous focus [1,12]. In adults, OM cases result mostly from a contiguous focus of infection with vascular insufficiency, as observed in diabetic patients. OM from a contiguous focus without vascular insufficiency occurs most frequently after trauma or surgery [13–15]. Hematogenous OM is primarily a disease of children but may also occur in adults, particularly in those at risk for blood stream infection, such as immunocompromised patients, patients with in-dwelling catheters, and intravenous drug users [13,14].

According to disease duration, OM can be classified as acute or chronic [1]. Acute OM corresponds to the initial phase of bone infection, and may present with fever, raised levels of inflammatory markers, and in the hematogenous form, with positive blood cultures (BCs). Following untreated infection or treatment failure, OM may progress to a chronic phase, which is characterized by the persistence of the microorganism, and the presence of necrotic bone (sequestrum) and fistulous tracts [16]. Chronic OM may present as a recurrent or intermittent disease, with periods of quiescence of variable duration.

The successful management of OM requires timely and prolonged administration of pathogen-directed antibiotic treatment. This can be a serious challenge, particularly in

immunocompromised patients, in which resistance can develop rapidly upon therapy, leading to treatment failure. In these cases, extensive surgical debridement is required, in addition to antibiotics [18–21].

We present these 2 cases to illustrate 2 different clinical presentations of OM by CPKp, and to raise awareness of this severe diagnosis, particularly among patients with hematologic malignancies and stem cell transplant recipients.

## Case Report

### Case 1

A 49-year-old white female was admitted to our department with the diagnosis of acute lymphoblastic leukemia, and was treated with a first course of induction chemotherapy with high-dose cyclophosphamide, vincristine, doxorubicin, and dexamethasone. Three weeks later, she developed painless neutropenic enterocolitis, and after BC sampling we started empiric antibacterial therapy with meropenem (1 gr q8h) and amikacin (1gr q24h). Multidrug-resistant CPKp (*Kp1*), as defined by Magiorakos et al. [22], was isolated after 48 h of incubation. Bacteria isolated on cultures (*Kp*) and their susceptibility patterns are listed in Table 1. Susceptibility to each antibiotic was defined according to the observed minimum inhibitory concentration (MIC), which were interpreted using the 2017 European Committee Antimicrobial Susceptibility Testing (EUCAST) recommendations and breakpoint tables. Based on these results, we added colistin to the antibiotic regimen (a loading dose of 8 MU IV, followed by a maintenance dose of 4 MU IV q12h), with no clinical improvement. BCs repeated after 48 h remained positive for CPKp, which now displayed a higher meropenem MIC (*Kp2*), and we decided to increase the meropenem dose to 2 gr q8h, in a 3-h extended infusion. Despite treatment, the patient's condition deteriorated, with clinical instability and substantial increase in the C-reactive protein (CRP) level (36.9 mg/dL) and leukocyte count ( $23\,599\text{ cells} \times 10^9/\text{L}$ ). She was admitted to the intensive care unit (ICU), where she rapidly progressed to multi-organ failure, requiring invasive mechanical ventilation and renal replacement therapy. BCs collected at ICU admission isolated a CPKp with increased amikacin MIC (*Kp3*), and amikacin was suspended. An abdominal/pelvic computed tomography (CT) scan was performed to evaluate the abdomen, and incidentally found intramedullary gas bubbles in the iliac bone and in the right femoral neck and head, suggestive of OM (Figure 1). Repeated BCs were positive for CPKp fully resistant to amikacin (*Kp4*). We admitted treatment failure, and decided to increase the dose of colistin (5 MU IV q12h) and associated tigecycline (200 mg loading dose, followed by 100 mg q12h), despite an unknown tigecycline susceptibility pattern.

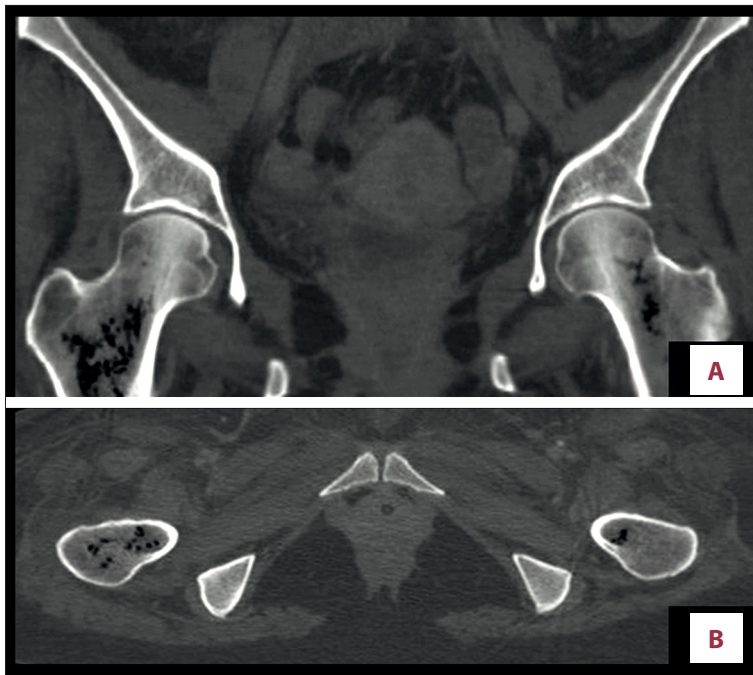
**Table 1.** List of isolated *Klebsiella pneumoniae* (Kp) over time and corresponding minimal inhibitory concentrations (MIC) of selected antimicrobial agents in Case 1.

Date (day/month/year)		27-Jun-17	29-Jun-17	2-Jul-17	9-Jul-17	12-Jul-17	
(Case 1)	Origin	Blood				Bone	
	Isolate	<i>Kp1</i>	<i>Kp2</i>	<i>Kp3</i>	<i>Kp4</i>	<i>Kp5</i>	
		*Multidrug-resistant	*Extensively drug-resistant			*Pandrug-resistant	
	Carbapenamase	P	P	P	P	P	
	Meropenem	S (MIC 2 mcg/mL)	R	R	R (MIC 32 mcg/mL)	R	
	Imipenem	S (MIC 2 mcg/mL)	NA	NA	R (MIC 16 mcg/mL)	R	
AST of culture isolates (with available MIC)	Ertapenem	R	NA	NA	R	R	
	Ampicillin	R	R	R	R	R	
	Cefuroxime	R	R	R	R	R	
	Cefotaxime	R	R	R	R	R	
	Ceftazidime	R	R	NA	NA	R	
	Amoxicillin-Clavulanic acid	R	R	R	R	R	
	Piperacillin-Tazobactam	R	NA	R	R	R	
	Trimethoprim/Sulfamethoxazole	R	R	R	R	R	
	Ciprofloxacin	R	R	R	R	R	
	Fosfomycin	R	NA	NA	NA	R	
	Amikacin	S (MIC 4 mcg/mL)	S	R	R	R	
	Gentamicin	R	R	R	R	R	
	Colistin	S	S	S	S	R	
	Tigecycline	NA	NA	NA	NA	R	
	Aztreonam	NA	NA	NA	NA	R	
	Neutrophil count (×10 <sup>9</sup> /L)		0	0.86	19.1	5.37	4.35
	IV Antibiotic therapy	Colistin	Loading dose of 8MU, followed by maintenance of 4MU q12h		4MU q12h	5MU q12h	
Meropenem		1 gr q8h	2 gr q8h				
Amikacin		1 gr q24h					
Tigecycline						200 mg loading dose, followed by 100 mg q12h	

\* Drug-resistance was defined as follows: *multidrug-resistant* are non-susceptible to at least 1 agent in ≥3 antimicrobial categories; *extensively drug-resistant* are non-susceptible to at least 1 agent in all but 2 or fewer antimicrobial categories; *pandrug-resistant* are non-susceptible to all agents in all antimicrobial categories [22]. AST – antimicrobial susceptibility testing; MIC – minimum inhibitory concentration; S – susceptible; R – resistant; NA – not available.

To confirm the diagnosis of OM and re-evaluate disease status, we performed a bone biopsy and bone marrow aspiration from the posterior iliac crest. The aspirate morphology showed disease remission, with no blasts, and the bone culture was

positive for CPKp with a pandrug-resistant pattern (*Kp5*). Her condition worsened over the following days and she died of exacerbation of multi-organ failure.



**Figure 1.** Pelvic computed tomography. Images in bone window show coronal (A) and axial (B) cuts from right femoral neck and head. The different cuts show intramedullary gas bubbles characteristic of osteomyelitis.

## Case 2

A 47-year-old black female was admitted to our department with the diagnosis of aplastic anemia. Here, she received an initial immunosuppressive regimen with cyclosporine, antithymocyte globulin, and methylprednisolone. During treatment, she developed neutropenic fever with bacteriemia due to CPKp (*Kp1*). Bacteria isolated on cultures (*Kp*) and their susceptibility patterns are listed in Table 2. A 14-day course of colistin (a loading dose of 8 MU, followed by a maintenance dose of 4 MU q12h) and amikacin (1 gr q24h) was completed with successful clinical response. Ten months later, she underwent an allogeneic hematopoietic stem cell transplant from a related donor. At the time of neutrophil engraftment, she developed a painful abscess in the right thigh, 5 cm in diameter, and its content was drained by aspiration. Due to clinical stability and absence of fever, we collected blood samples and postponed antibacterial therapy until culture results were available. After 48 h of incubation, cultures of the drained abscess fluid yielded CPKp susceptible only to colistin, tigecycline, and fosfomycin (*Kp2*); BCs were negative. We then initiated dual therapy with colistin (8 MU loading dose, followed by 4 MU q12h) and tigecycline (200 mg loading dose, followed by 100 mg q12). Despite treatment, the patient became febrile; the inflammatory lesion increased in size, and CRP level increased to a maximum of 31 mg/dL. Several BC sets were collected, with negative results. A CT scan of the thigh was performed, showing a deep collection adjacent to the femur, suggestive of OM (Figure 2A, 2B). This image was confirmed by magnetic resonance imaging (MRI), which showed an intraosseous abscess 14 cm in length. This abscess was connected to a subcutaneous

collection measuring 5.6 cm in diameter, via an opening in the femoral metaphyseal region (Figure 2C). The patient underwent extensive surgical debridement of the right femur, followed by the same regimen of IV antibiotics for 6 weeks, with improvement of clinical condition. The endomedular culture grew a CPKp (*Kp3*) with a similar susceptibility pattern as the previous isolate. At the end of treatment, a whole-body bone scintigraphy with gadolinium showed inflammatory activity in the right femur, suggestive of OM. However, the patient was asymptomatic, with complete healing of the surgical wound and negative CRP, and she was discharged home without further antibacterial therapy. She currently presents no pain in the right leg, and is in complete hematologic recovery while still under post-transplant cyclosporine-based immunosuppression.

## Discussion

The spread of CPKp, members of the Enterobacteriaceae family, is an emerging public health threat. Carbapenemases can confer resistance or reduced susceptibility to various groups of antibiotics, which limits treatment options and results in significantly increased mortality [8].

Despite being frequently encountered in nosocomial infections, CPKp are uncommon pathogens causing OM, with very few cases described in the literature.

Patients with hematologic malignancies and stem cell transplant recipients are at risk for OM and CPKp infections due to the severe immunosuppression caused by prolonged neutropenia,

**Table 2.** List of isolated *Klebsiella pneumoniae* (Kp) over time and corresponding minimal inhibitory concentrations (MIC) of selected antimicrobial agents in Case 2.

Date (day/month/year)		1-Jul-16	24-Apr-17	22-Jun-17
Origin		Blood	Abscess fluid	Bone
(Case 2)		Kp1	Kp2	Kp3
Isolate		*Multidrug-resistant	*Extensively drug-resistant	
Carbapenamase		P	P	P
Meropenem		R (MIC 16 mcg/mL)	R (MIC >16 mcg/mL)	R (MIC >16 mcg/mL)
Imipenem		R (MIC 8 mcg/mL)	R (MIC >8 mcg/mL)	R (MIC >16 mcg/mL)
Ertapenem		R	NA	R
Ampicillin		R	R	R
Cefuroxime		R	R	R
Cefotaxime		R	R	R
Ceftazidime		R	R	R
Amoxicillin-Clavulanic acid		R	R	R
Piperacillin-Tazobactam		R	NA	R
Trimethoprim/Sulfamethoxazole		R	R	R
Ciprofloxacin		R	R	R
Fosfomycin		NA	S	NA
Amikacin		S (6 mcg/mL)	R (MIC 16 mcg/mL)	R (MIC 24 mcg/mL)
Gentamicin		R	R	R
Colistin		S	S	S
Tigecycline		S	S	S
Neutrophil count (×10 <sup>9</sup> /L)		1.1	22.03	3.54
IV Antibiotic therapy	Colistin	Loading dose of 8MU, followed by maintenance of 4MU q12h		4MU q12h
	Amikacin	1 gr q24h		
	Tigecycline	200 mg loading dose, followed 100 mg q12h		100 mg q12h

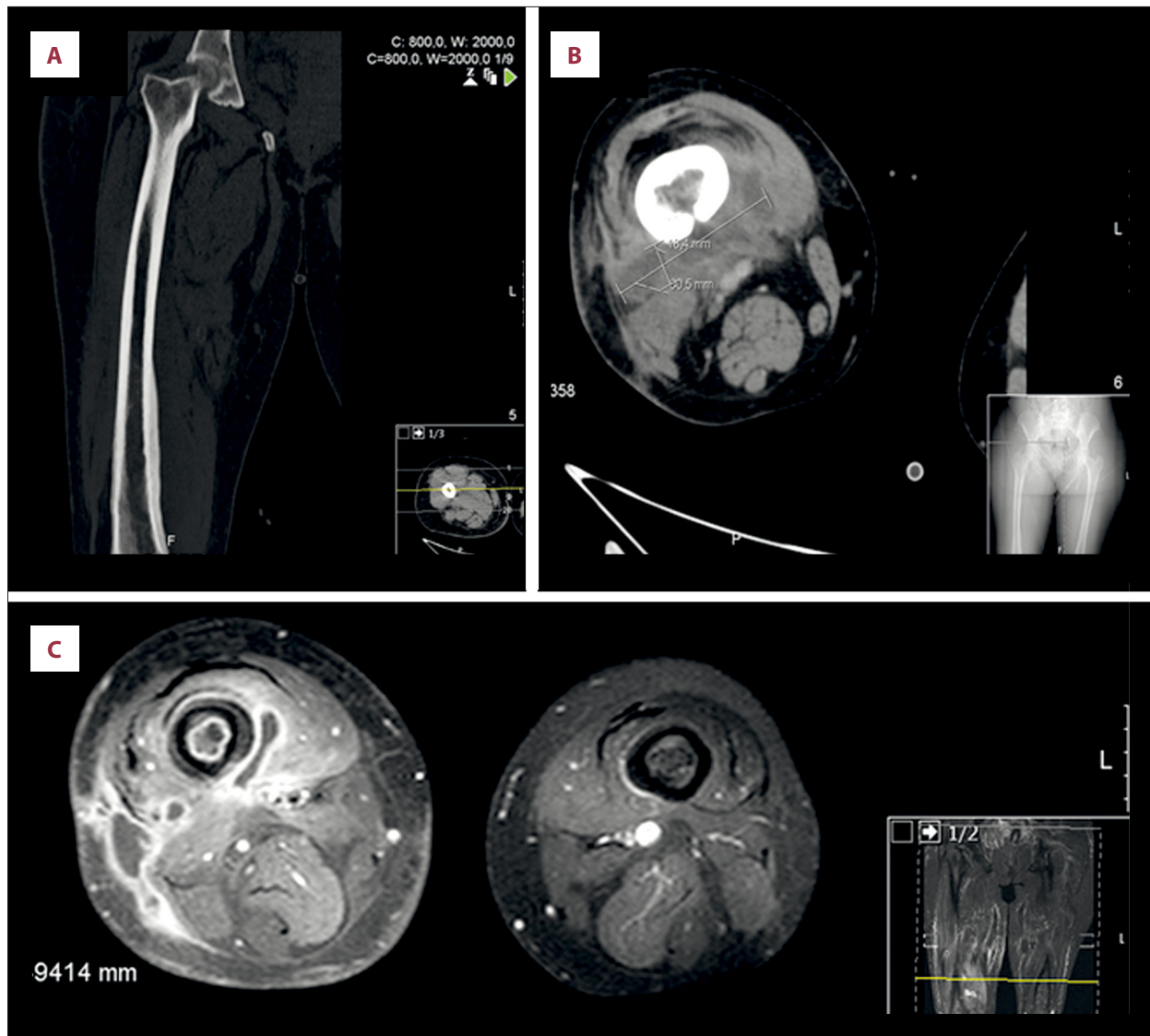
\* Drug-resistance was defined as follows: *multidrug-resistant* are non-susceptible to at least 1 agent in ≥3 antimicrobial categories; *extensively drug-resistant* are non-susceptible to at least 1 agent in all but 2 or fewer antimicrobial categories; *pandrug-resistant* are non-susceptible to all agents in all antimicrobial categories [22]. AST – antimicrobial susceptibility testing; MIC – minimum inhibitory concentration; S – susceptible; R – resistant; NA – not available.

lymphocyte dysfunction (humoral and cell-mediated), chemotherapy-induced gastrointestinal mucositis, prolonged hospitalization, and the use of broad-spectrum antibacterial agents [8].

The nonspecific signs and symptoms of OM may lead to a delay in diagnosis, which, in the context of immunosuppression and infection with a resistant microorganism, can result in an unfavorable outcome.

These 2 cases are clear examples of the effect of host factors, bacterial virulence, and time to diagnosis and treatment on the outcome of OM. Although both cases were immunosuppressed patients, in Case 1 the patient developed a prolonged neutropenia, followed by a severe gastrointestinal mucositis and multi-organ failure. In contrast, in Case 2 the patient had a rapid neutrophil recovery after stem cell transplant and remained clinically stable throughout follow-up. Comparing the





**Figure 2. Computed tomography and magnetic resonance imaging of both thighs.** Coronal (A) and axial (B) CT images (bone window) of the right thigh, show a deep longitudinal collection adjacent to the femur which is connected to a subcutaneous collection, measuring 5.6 cm in diameter, through a cloaca in the femoral metaphyseal region. T1-weighted MRI image (C) shows an axial cut of both thighs. On the right thigh there is an intramedullary lesion consistent with an intraosseous abscess.

bacterial virulence, in Case 1 there were 5 consecutive isolates of CPKp, with a progressively reduced susceptibility to antibiotics. The initial isolate *Kp1* was a multi-drug-resistant bacterium only susceptible to aminoglycosides (except for gentamicin), polymyxins, and carbapenems. Isolates *Kp2* to *Kp4* had an increase in the MICs, initially for both carbapenems and subsequently for amikacin; these were extensively drug-resistant bacteria [22]. *Kp5*, isolated in the bone, was fully resistant to all the antibiotics, and thus was considered a pandrug-resistant bacterium [11,22]. In this case, we observed a persistent and sustained bacteremia by extensively drug-resistant CPKp, and the bone culture was positive for a pandrug-resistant CPKp. However, in Case 2 there was no bacteremia,

and the endomedular culture was positive for extensively drug-resistant CPKp. We assume that the emergence of colistin and amikacin resistance, in Case 1 and Case 2, respectively, were related to strain evolution caused by drug-selection pressure and antibiotic overuse.

Regarding the clinical presentation, in Case 1 there were only nonspecific signs and symptoms of neutropenic sepsis, with no local inflammation, and the late diagnosis was based on an incidental radiological finding, confirmed with a positive bacterial bone culture. In contrast, in Case 2 the early diagnosis was possible due to the presence of pain and local signs of inflammation, plus a high clinical suspicion. Although in this

later case the host and virulence factors also favored the development of a severe OM, the timely recognition and early and correct intervention resulted in a successful outcome.

These 2 cases most likely correspond to an acute and chronic presentation of hematogenous OM, respectively. In Case 1 there were symptoms of an inflammatory response, without localizing signs of infection, and concomitant CPKp bacteremia; but in Case 2 there was a history of CPKp bacteremia, which resolved, followed by appearance of a local inflammation with radiological signs suggestive of chronic inflammation [16], and isolation of CPKp resistant to amikacin. In this particular case, we hypothesize that the patient remained colonized with CPKp in the femur, and relapsed after neutrophil recovery, with the formation of an abscess.

Although acute hematogenous OM might respond favorably to a 4- to 6-week course of IV antibiotics alone, in this case the treatment was compromised by the emergence of wide antibiotic resistance. In the chronic form, antibacterial therapy alone without adequate surgical debridement may be unsuccessful, regardless of the duration of therapy, due to the limited bone penetration of many antibiotics. Thus, surgical debridement is recommended in chronic OM [1].

As described in Case 1, the symptoms and the clinical manifestations of OM may be nonspecific and mimic other infectious conditions; therefore, a high index of suspicion is required for early diagnosis. This raises the question of whether OM is underdiagnosed,

particularly among neutropenic patients with a microbiologically confirmed infection and no identified primary infection locus.

## Conclusions

CPKp OM is an important diagnostic and therapeutic challenge, as illustrated by these 2 cases. Although rare, OM by CPKp should always be considered as a possible diagnosis, particularly among hospitalized patients with hematologic malignancies and stem cell transplant recipients, and a concomitant or previous infection by CPKp. Early recognition followed by an appropriate and aggressive treatment approach can improve the outcome of this severe and life-threatening condition.

## Acknowledgements

The authors would like to acknowledge all the physicians involved in the patient's care, in the Clinical Hematology Department at Hospital de Santa Maria, and in the Intensive Care Unit at Hospital Egas Moniz.

## Statement

The authors declare that they have received an unrestricted grant from Pfizer to cover the fees for publication. This work was independent of any pharmaceutical support. The authors declare no competing financial interests.

## References:

1. Lew DP, Waldvogel FA: Osteomyelitis. *Lancet*, 2004; 364: 369–79
2. Carek PJ, Dickerson LM, Sack JL: Diagnosis and management of osteomyelitis. *Am Fam Physician*, 2001; 63: 2413–20
3. Eid AJ, Berbari EF: Osteomyelitis: Review of pathophysiology, diagnostic modalities and therapeutic options. *J Med Liban*, 2012; 60: 51–60
4. Kremers HM, Nwojo ME, Ransom JE et al: Trends in the epidemiology of osteomyelitis: A population-based study, 1969 to 2009. *J Bone Joint Surg Am*, 2015; 97: 837–45
5. Tice AD, Hoaglund PA, Shoultz DA: Risk factors and treatment outcomes in osteomyelitis. *J Antimicrob Chemother*, 2003; 51: 1261–68
6. Sanders JA: *Klebsiella pneumoniae* osteomyelitis: Demonstration by three-phase radionuclide bone imaging. *J Nucl Med*, 1989; 30: 1412–14
7. Murillo O, Grau I, Lora-Tamayo J et al: The changing epidemiology of bacterial osteoarticular infections in the early 21<sup>st</sup> century. *Clin Microbiol Infect*, 2015; 21: 254e1–8
8. Sattlin MJ, Jenkins SG, Walsh TJ: The global challenge of carbapenem-resistant *Enterobacteriaceae* in transplant recipients and patients with hematologic malignancies. *Clin Infect Dis*, 2014; 58: 1274–83
9. Sepehri S, Poliquin G, Alfattoh N et al: Osteomyelitis due to multiple carbapenemase-producing Gram-negative bacteria: The first case report of a GES-13-producing *Pseudomonas aeruginosa* isolate in Canada. *Can J Infect Dis Med Microbiol*, 2014; 25: 229–31
10. Abboud CS, Miglioli L, Romero AP et al: First report of *Klebsiella pneumoniae* carbapenemase-producing *K. pneumoniae* sternum osteomyelitis relapsing 6 years after mediastinitis following cardiac surgery. *Int J Antimicrob Agents*, 2017; 49: 262–63
11. Perez F, Adachi J, Bonomo RA: Antibiotic-resistant gram-negative bacterial infections in patients with cancer. *Clin Infect Dis*, 2014; 59(Suppl. 5): S335–39
12. Waldvogel FA, Medoff G, Swartz MN: Osteomyelitis: A review of clinical features, therapeutic considerations and unusual aspects. *N Engl J Med*, 1970; 282: 198–206
13. Brennan PJ, DeGirolamo MP: Musculoskeletal infections in immunocompromised hosts. *Orthop Clin North Am*, 1991; 22: 389–99
14. Hsieh PH, Lee MS, Hsu KY et al: Gram-negative prosthetic joint infections: Risk factors and outcome of treatment. *Clin Infect Dis*, 2009; 49: 1036–43
15. Fritz JM, McDonald JR: Osteomyelitis: Approach to diagnosis and treatment. *Phys Sportsmed*, 2008; 36: nihpa116823
16. Fritz J: The contributions of whole-body magnetic resonance imaging for the diagnosis and management of chronic recurrent multifocal osteomyelitis. *J Rheumatol*, 2015; 42: 1359–60
17. Mouzopoulos G, Kanakaris NK, Kontakis G et al: Management of bone infections in adults: The surgeon's and microbiologist's perspectives. *Injury*, 2011; 42(Suppl. 5): S18–23
18. Ford CA, Cassat JE: Advances in the local and targeted delivery of anti-infective agents for management of osteomyelitis. *Expert Rev Anti Infect Ther*, 2017; 15: 851–60
19. Fang RC, Galiano RD: Adjunctive therapies in the treatment of osteomyelitis. *Semin Plast Surg*, 2009; 23: 141–47
20. Rao N, Ziran BH, Lipsky BA: Treating osteomyelitis: Antibiotics and surgery. *Plast Reconstr Surg*, 2011; 127(Suppl. 1): 177S–87S
21. Spellberg B, Lipsky BA: Systemic antibiotic therapy for chronic osteomyelitis in adults. *Clin Infect Dis*, 2012; 54: 393–407
22. Magiorakos AP, Srinivasan A, Carey RB et al: Multidrug-resistant, extensively drug-resistant and pandrug-resistant bacteria: An international expert proposal for interim standard definitions for acquired resistance. *Clin Microbiol Infect*, 2012; 18: 268–81