

Correlations of Cervical Sagittal Alignment before and after Occipitocervical Fusion

Yoshitaka Matsubayashi¹ Takachika Shimizu² Hirotaka Chikuda¹ Katsushi Takeshita³
Yasushi Oshima¹ Sakae Tanaka¹

¹ Department of Orthopaedic Surgery, The University of Tokyo, Tokyo, Japan

² Department of Orthopaedic Surgery, Gunma Spine Center (Harunaso Hospital), Gunma, Japan

³ Department of Orthopaedic Surgery, Jichi Medical University, Tochigi, Japan

Address for correspondence Yoshitaka Matsubayashi, MD, Department of Orthopaedic Surgery, Faculty of Medicine, The University of Tokyo, 7-3-1, Hongo, Bunkyo-ku, Tokyo 113-8655, Japan (e-mail: ymatsubayashi-tky@umin.ac.jp).

Global Spine J 2016;6:362–369.

Abstract

Study Design Retrospective radiographic study.

Objective To investigate changes and correlations of cervical sagittal alignment including T1 slope before and after occipitocervical corrective surgery. We also investigated the relevance for preoperative planning.

Methods We conducted a retrospective radiographic analysis of 27 patients who underwent surgery for occipitocervical deformity. There were 7 men and 20 women with a mean age of 56.0 years. Mean follow-up was 68.0 months (range 24 to 120). The radiographic parameters measured before surgery and at final follow-up included McGregor slope, T1 slope, occipito (O)–C2 angle, O–C7 angle, and C2–C7 angle. Pearson correlation coefficient was used to examine the correlation between the radiographic parameters.

Results There was a stronger positive correlation between the T1 slope and the O–C7 angle both preoperatively and postoperatively ($r = 0.72$ and $r = 0.83$, respectively) than between the T1 slope and the C2–C7 angle ($r = 0.60$ and $r = 0.76$, respectively). The O–C2 angle and C2–C7 angle had inverse correlations to each other both pre- and postoperatively ($r = -0.50$ and -0.45). McGregor slope and T1 slope did not significantly change postoperatively at final follow-up. Increase in O–C2 angle after surgery (mean change, 10.7 degrees) inversely correlated with decrease in postoperative C2–C7 angle (mean change, 12.2 degrees). As result of these complementary changes, O–C7 angle did not statistically change.

Conclusions Our results suggest that the O–C7 angle is regulated by T1 slope and the corresponding O–C7 angle is divided into the O–C2 and C2–C7 angles, which have inverse correlation to each other and then maintain McGregor slope (horizontal gaze).

Keywords

- ▶ cervical alignment
- ▶ sagittal alignment
- ▶ occipitocervical fusion
- ▶ deformity

Introduction

Careful consideration of the sagittal parameters of the spine and pelvis is essential for the treatment of the spine, particu-

larly the thoracolumbar spine.^{1–3} Although malalignment of the thoracolumbar spine is associated with poor long-term clinical outcomes and postoperative health-related quality of life, the clinical impact of cervical alignment has not been

received
June 15, 2015
accepted after revision
July 24, 2015
published online
September 5, 2015

DOI <http://dx.doi.org/10.1055/s-0035-1563725>.
ISSN 2192-5682.

© 2016 Georg Thieme Verlag KG
Stuttgart · New York

License terms



sufficiently investigated.³⁻⁶ Prior studies indicated that the significance of sagittal parameters such as the negative impact of kyphotic deformity in cervical laminoplasty or the positive sagittal malalignment following posterior cervical fusion correlated with the severity of disability.^{7,8} The occipito (O)–C2 angle reportedly accounts for 77% of cervical lordosis, and a correlation between the alignment of the upper and lower cervical spine has been already reported.^{9,10} Although there are studies on the relationship between the atlantoaxial angle and subaxial cervical lordosis after atlantoaxial fixation,¹¹⁻¹⁴ there are few studies on the occipitocervical angle in cervical sagittal alignment.^{15,16} Furthermore, although several reports indicated the correlation between the T1 slope and thoracolumbar sagittal alignment,¹⁷⁻¹⁹ only few studies reported the correlation of the T1 slope and cervical sagittal alignment.⁹ The purpose of this study was to examine the potential impact of the occipitocervical fusion on subaxial sagittal alignment and to clarify the correlations of these sagittal parameters. We also investigated the relevance for preoperative planning.

Materials and Methods

A total of 33 consecutive patients who underwent posterior O–C3 fixation for the treatment of occipitocervical deformity between 2002 and 2011 were retrospectively investigated. Six patients did not fulfill at least one of the necessary parameters and were excluded, and thus 27 patients were included in the present study. The surgical procedures consisted of a posterior approach, and we used a screw and loop rod system with posterior wiring.

The McGregor slope, T1 slope, O–C2 angle, O–C7 angle, and C2–C7 angle were measured preoperatively and at the final follow-up on lateral cervical X-ray in the sitting position. The McGregor slope and T1 slope are defined as the angle of the McGregor line and T1 superior end plate against a horizontal line, respectively.²⁰ The O–C2 angle and O–C7 angle consist of the angles of the C2 inferior end plate and C7 inferior end plate against the McGregor line, respectively. The C2–C7 angle was measured using the Cobb method between the inferior end plate of C2 and that of C7. Considering the role of the occipitocervical angle in cervical alignment, it is essential to include the craniocervical junction in the assessment of cervical sagittal alignment. Thus we used the McGregor slope to assess cranial position. To minimize the effect of change in the thoracolumbar alignment, we evaluated the X-rays of patients while sitting, which can provide direct information of the occipitocervical fixation for cervical alignment.

The severity of myelopathy was assessed using the Japanese Orthopaedic Association (JOA) score. Two patients could not be evaluated, one because of cerebral infarction after surgery and one because of mental retardation.

The Ethics Committee of the Gunma Spine Center approved the study protocol, and informed consent was obtained from the study participant or the person authorized to give consent.

The Statistical Package for the Social Sciences (SPSS version 21.0, SPSS Inc., Chicago, Illinois, United States) software was

used for all statistical analysis. The correlations between the parameters were analyzed with the Pearson correlation coefficient. The relationship between the postoperative cervical lordosis and radiographic parameters was calculated using forward stepwise multivariate linear regression analysis. Statistical analyses were two-sided, and a *p* value of ≤ 0.05 was considered statistically significant.

Results

There were 7 men and 20 women. The average age at surgery was 56.0 years (range 14 to 83). The mean follow-up period was 68.0 months (range 24 to 120). Twenty-four patients had rheumatoid arthritis, 1 had os odontoideum, 1 had Klippel-Feil syndrome, and 1 had spondylosis. Myelopathy was observed in 21 patients. Pre- and postoperative JOA scores of the patients with myelopathy are listed in ►Table 1. The mean preoperative JOA score was 11.7, and it significantly improved to 13.6 postoperatively. The recovery rate of JOA score was 45%. With regard to surgical procedure, 23 patients underwent C1 posterior arch resection. Pedicle screws were used at C2 in 2 patients and at C3 in 21 patients. Sublaminar wiring was used at C1 in 1 patient, at C2 in 26 patients, and at C3 in 12 patients. Five patients received subaxial cervical laminoplasty. Postoperative screw breakage was observed in 1 case, and postoperative instability (olisthesis ≥ 3 mm) was observed in 2 cases. Deterioration of the subaxial cervical kyphotic deformity was observed in 1 case, and de novo kyphotic deformity was observed in 2 cases. One patient with rheumatoid arthritis required revision surgery at 28 months after primary surgery because of deterioration and C5–C6 instability.

The measured values of the radiographic parameters are listed in ►Table 1. The McGregor slope did not significantly change after surgery ($p = 0.07$), despite a statistically significant increase in the O–C2 angle (mean change 10.7 degrees, $p < 0.001$) for correction of occipitocervical kyphosis. In contrast to the increase in the O–C2 angle, the C2–C7 angle significantly decreased (mean change 12.2 degrees, $p = 0.002$). As a result of these changes, the O–C7 angle and T1 slope did not significantly change postoperatively ($p = 0.46$ and 0.40 , respectively). Correlations between the radiographic parameters are summarized in ►Table 2 and ►Fig. 1. The pre- and postoperative McGregor slopes were significantly correlated ($r = 0.63$), and a similar correlation was observed for T1 slope ($r = 0.62$). A previous study indicated correlation between the T1 slope and C2–C7 angle and between the C2–C7 angle and O–C2 angle.⁹ But in this study, the correlation coefficients between the T1 slope and the O–C7 angle both preoperatively and postoperatively ($r = 0.72$ and $r = 0.83$, respectively) were higher than between the T1 slope and the C2–C7 angle ($r = 0.60$ and $r = 0.76$, respectively). We observed an inverse correlation between the O–C2 and C2–C7 angles pre- and postoperatively ($r = -0.50$ and $r = -0.45$, respectively). The JOA score and its recovery rate did not correlate with the radiographic cervical sagittal parameters.

►Table 3 shows the correlation coefficient between the pre- and postoperative parameters. There was an inverse

Table 1 Pre- and postoperative parameters values and JOA scores

	Min	Max	Mean	SD	p Value
McGregor slope pre	-20	9	-4.0	6.7	0.07
McGregor slope post	-11	9	-2.0	5.8	
T1 slope pre	17	47	30.9	7.8	0.40
T1 slope post	12	64	32.5	12.4	
O-C2 angle pre	-13	25	4.7	10.7	0.0001
O-C2 angle post	-4	38	15.4	10.7	
C2-C7 angle pre	4	50	21.8	13.8	0.002
C2-C7 angle post	-17	42	9.6	15.2	
O-C7 angle pre	4	45	26.4	12.6	0.46
O-C7 angle post	4	60	25.0	14.1	
JOA score pre	7.0	16.0	11.7	2.9	0.0001
JOA score post	8.5	17.0	13.6	2.7	

Note: Wilcoxon signed rank test.

Abbreviations: JOA, Japanese Orthopaedic Association; Min, minimum; Max, maximum; O, occipito; pre, preoperative value; post, postoperative value; SD, standard deviation.

correlation between the mean pre- versus postoperative change (Δ) in O-C2, the angle created by correction surgery, and Δ C2-C7, the reciprocal change of the correction angle (\rightarrow Fig. 2). The Δ O-C7 angle, which is the sum of these two changes, was correlated with the Δ T1 slope ($r = 0.76$).

We conducted a multiple linear regression model for postoperative cervical lordosis to predict the postoperative cervical subaxial kyphotic deformity. We used preoperative parameters and postoperative O-C2 angle for the analysis and excluded the McGregor and T1 slopes and the C2-C7 angle from this analysis to avoid multicollinearity with the O-C7

angle. The predicted C2-C7 angle model was $4.085 + 0.988 \cdot O-C7 \text{ pre} - 1.340 \cdot O-C2 \text{ post}$ ($p < 0.001$). The formula had a strong correlation ($r = 0.79$) with the postoperative C2-C7 angle (\rightarrow Fig. 3).

Discussion

In this study, we found that the correlation coefficient between the T1 slope and the O-C7 angle (O-C2 angle plus C2-C7 angle) is higher than that with the C2-C7 angle alone both pre- and postoperatively. Correlations between the T1 slope

Table 2 Pearson correlation coefficient between the parameters

	McGregor slope pre	T1 slope pre	O-C2 pre	O-C7 pre	C2-C7 pre	McGregor slope post	T1 slope post	O-C2 post	O-C7 post	C2-C7 post
McGregor slope pre	-	-0.16	-0.39 ^a	-0.68 ^b	-0.31	0.63 ^b	-0.06	-0.42 ^a	-0.38	-0.06
T1 slope pre		-	0.08	0.72 ^b	0.60 ^b	-0.31	0.62 ^b	0.26	0.68 ^b	0.45 ^a
O-C2 pre			-	0.30	-0.50 ^c	-0.38	0.15	0.35	0.28	0.01
O-C7 pre				-	0.67 ^b	-0.55 ^c	0.42 ^a	0.60 ^b	0.72 ^b	0.25
C2-C7 pre					-	-0.20	0.27	0.27	0.44 ^a	0.22
McGregor slope post						-	0.10	-0.40 ^a	-0.28	0.02
T1 slope post							-	0.01	0.83 ^b	0.76 ^b
O-C2 post								-	0.27	-0.45 ^a
O-C7 post									-	0.74 ^b

Abbreviations: pre, preoperative value; O, occipito; post, postoperative value.

^a $p < 0.05$.

^b $p < 0.001$.

^c $p < 0.01$.

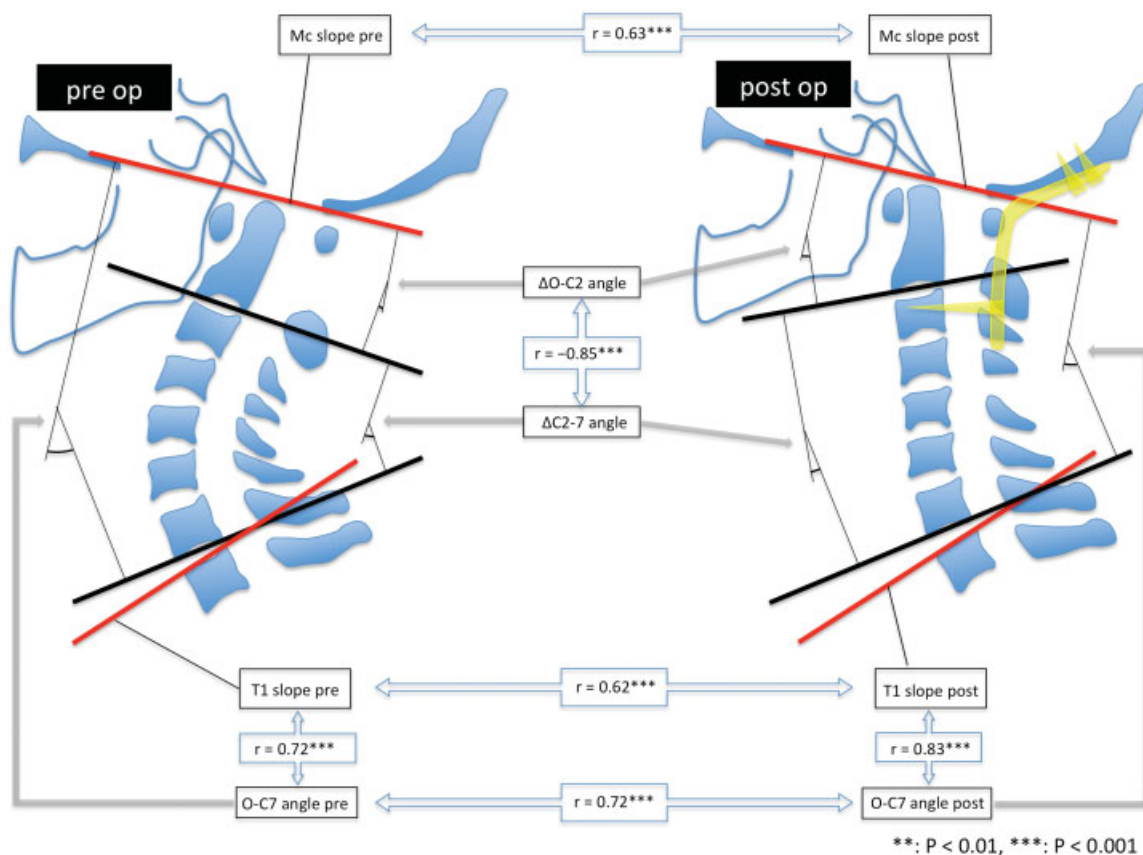


Fig. 1 Correlations between the cervical parameters. Abbreviations: Δ, change between preoperative and postoperative values; Mc, McGregor; pre, preoperative values; post, postoperative values.

and C2–C7 lordosis and between the O–C2 angle and C2–C7 lordosis were mentioned in previous studies.^{6,9} These results suggest that the subaxial cervical spine compensated for the deformity of the upper cervical spine preoperatively, and the entire cervical spine was realigned against the T1 slope, which represents thoracolumbar spine alignment, to maintain the McGregor slope (horizontal gaze). After surgery, increases of the occipitocervical angle led to decreases of the subaxial cervical lordosis to maintain whole cervical lordosis against the T1 slope. In this study, we used the McGregor slope as a parameter of skull alignment, which can be measured in a normal lateral cervical X-ray.²⁰ The McGregor line is the most reproducible and reliable method for measuring the occipitocervical angle among the lines of the skull base, including the McGregor, Chamberlain, and

McRae lines.^{21,22} The McGregor slope was expected to maintain its angle even after occipitocervical surgery for horizontal gaze.²⁰

In addition, we found that the majority of the correction angles of the upper cervical spine were absorbed by reciprocal change of the subaxial cervical spine at the final follow-up (→ Fig. 2). Preoperatively, C2–C7 created hyperlordosis if there was O–C2 kyphotic deformity to maintain the horizontal gaze. After occipitocervical corrective surgery, subaxial lordosis decreased to absorb the increase of occipitocervical lordosis, and the horizontal gaze was maintained. This result indicates that an excessive lordosis at the craniocervical junction by correction surgery can lead to kyphotic changes of the subaxial cervical spine, which was also noted in a previous study.¹⁶ However, that

Table 3 Pearson correlation coefficient between the pre- and postoperative change of parameters

	ΔMcGregor slope	ΔT1 slope	ΔO–C2	ΔO–C7	ΔC2–C7
ΔMcGregor slope	–	0.38	0.05	–0.05	–0.06
ΔT1 slope		–	–0.28	0.76 ^a	0.61 ^a
ΔO–C2			–	–0.34	–0.85 ^a
ΔO–C7				–	0.78 ^a

Abbreviations: Δ, change between pre- and postoperative values; O, occipito.
^ap < 0.001.

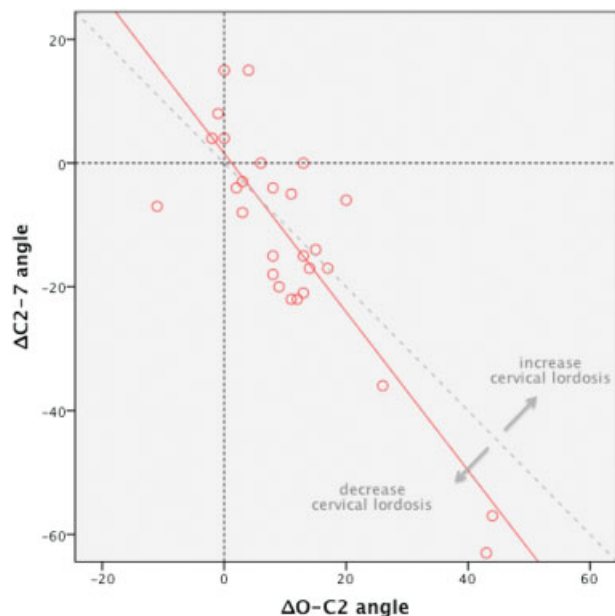


Fig. 2 Correlation between Δ O-C2 angle and Δ C2-C7 angle. Abbreviations: Δ , change between preoperative and postoperative values; O, occipito.

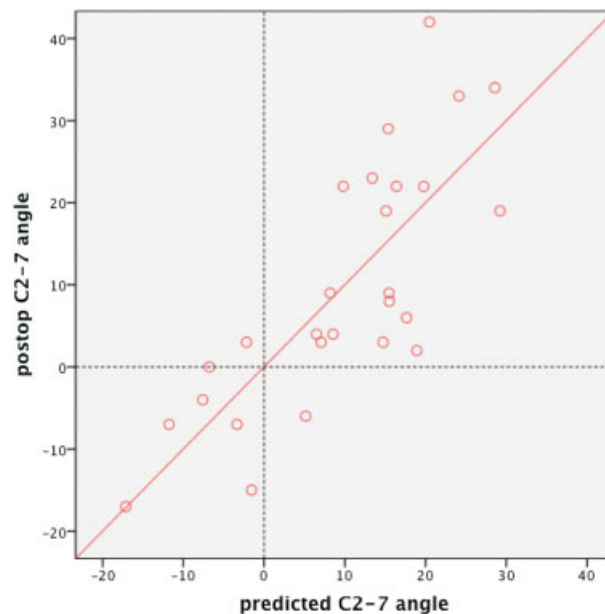


Fig. 3 Correlation between postoperative C2-C7 angle and predicted C2-7 angle.

study included both occipito-atlanto-axial fusion and atlantoaxial fusion; thus, in some cases, the correction angle could be absorbed not only by the subaxial spine but also by the atlanto-occipital junction. Therefore, to the best of our knowledge, this study is the first to show the direct impact of occipitocervical correction on subaxial cervical alignments. The postoperative C2-C7 angle absorbed most of the upper cervical correction angle because the O-C7 angle was postoperatively maintained. **►Fig. 2** shows the correlation

between the Δ O-C2 and Δ C2-C7 angles. The correction angle of the upper cervical deformity was absorbed by a decrease of the subaxial lordosis, even if the correction angle was ≥ 20 degrees. **►Fig. 2** shows that some patients had increased or decreased cervical lordosis. The greatest cause of large increases of cervical lordosis was the increase of T1 slope, which is suggestive of a thoracolumbar kyphotic deformity such as a compression fracture. The greatest cause of decreases of cervical lordosis was postoperative

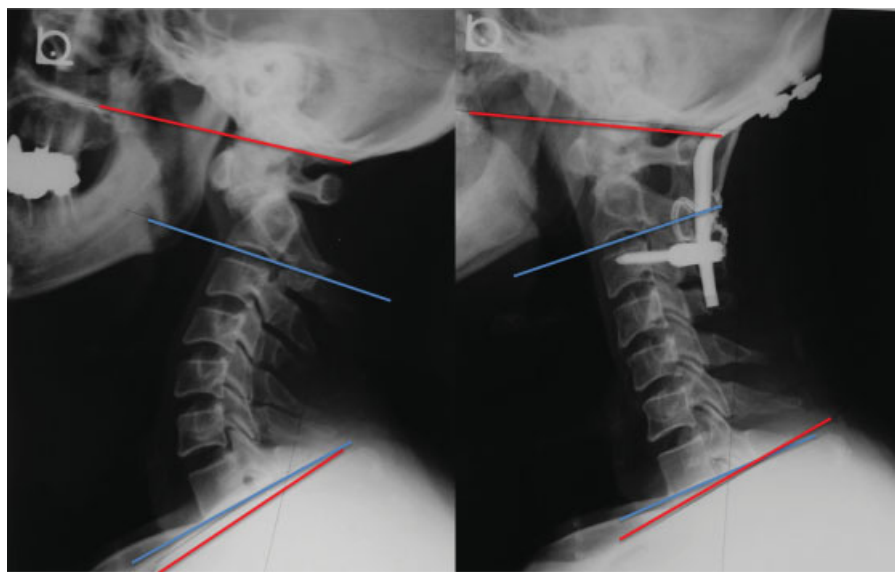


Fig. 4 Case 1. A 54-year-old man with os odontoideum. Preoperative (left) and 3 years postoperative (right) X-rays. Occipitocervical kyphosis was corrected and lordosis gained at 3 years postoperatively. Conversely, subaxial lordosis decreased, and the McGregor and T1 slopes were maintained.

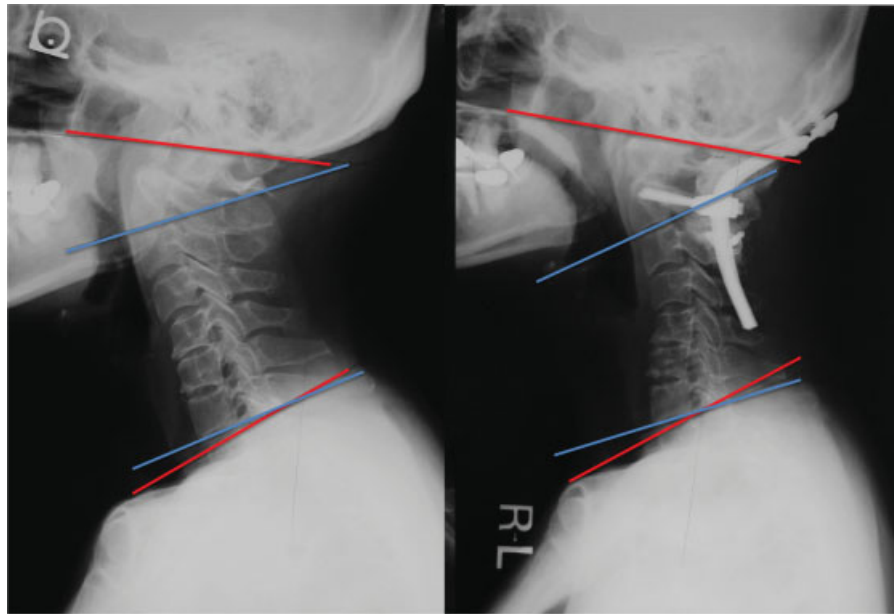


Fig. 5 Case 2. A 55-year-old woman with rheumatoid arthritis. Preoperative (left) and 5 years postoperative (right) X-rays. Occipito–C2 lordosis increased after correction surgery, and the subaxial cervical spine presented kyphotic changes 5 years postoperatively. The McGregor slope and T1 slope were maintained.

subaxial kyphotic deformity. ► **Figs. 4, 5, 6, and 7** show representative cases of this study.

Finally, the multiple linear regression model for postoperative cervical alignment demonstrated that the postoperative subaxial cervical angle could be predicted from the preoperative O–C7 angle and postoperative O–C2 angle. These findings indicate that we should preoperatively plan the occipitocervical fixation angle, considering not only the preoperative occipitocervical angle but also the whole cervical spine sagittal alignment, including the T1 slope.

There are several limitations in this study. This study included patients with rheumatoid arthritis who generally have a fragile spine, and thus a change of alignment could be influenced by concurrent deformity or progression of the disease. There were relatively few patients with sitting X-ray. Standing X-ray may provide additional information for understanding the influence of thoracolumbar alignment. Further investigations on a healthy population with standing whole spine X-ray should be conducted to provide additional information.

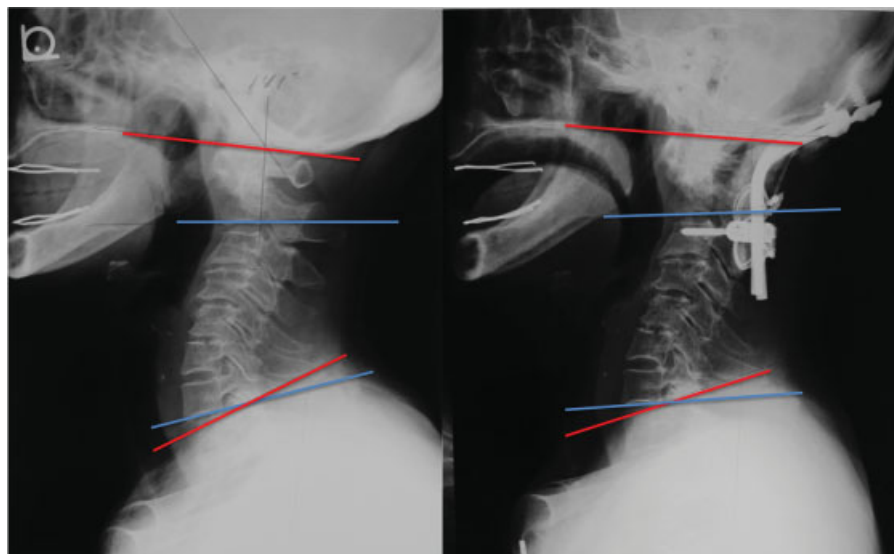


Fig. 6 Case 3. A 78-year-old woman with rheumatoid arthritis. Preoperative (left) and 5 years postoperative (right) X-rays. Occipito–C2 angle did not change postoperatively, and none of the sagittal parameters changed 5 years postoperatively.



Fig. 7 Case 4. A 63-year-old woman with rheumatoid arthritis. Preoperative (left), 6 months postoperative (middle), and 4 years postoperative (right) X-rays. Although the occipito-C2 angle did not change postoperatively, T1 slope increased 6 months postoperatively, probably because of the kyphotic changes of thoracic spine. Compensational lordotic change of the subaxial cervical spine maintained the McGregor slope. Four years postoperatively, the T1 slope increased beyond the limit of cervical compensation, and then the McGregor slope changed.

Conclusions

In the present study, we demonstrated that correlation between the T1 slope and the O-C7 angle is stronger than that with the C2-C7 angle both pre- and postoperatively. Our results suggest that the O-C7 angle is regulated by the T1 slope, and the corresponding O-C7 angle was divided into the O-C2 and C2-C7 angles with inverse correlation to each other and then maintained horizontal gaze (McGregor slope). We should pay close attention to the alignment of the craniocervical junction, as well as the subaxial cervical spine when considering cervical spine treatment.

Disclosures

Yoshitaka Matsubayashi, none
Takachika Shimizu, Royalties: Robert Reid, Inc.
Hirotaka Chikuda, none
Katsushi Takeshita, none
Yasushi Oshima, none
Sakae Tanaka, none

References

- Glassman SD, Bridwell K, Dimar JR, Horton W, Berven S, Schwab F. The impact of positive sagittal balance in adult spinal deformity. *Spine (Phila Pa 1976)* 2005;30(18):2024-2029
- Jackson RP, McManus AC. Radiographic analysis of sagittal plane alignment and balance in standing volunteers and patients with low back pain matched for age, sex, and size. A prospective controlled clinical study. *Spine (Phila Pa 1976)* 1994;19(14):1611-1618
- Schwab F, Patel A, Ungar B, Farcy JP, Lafage V. Adult spinal deformity-postoperative standing imbalance: how much can you tolerate? An overview of key parameters in assessing alignment and planning corrective surgery. *Spine (Phila Pa 1976)* 2010;35(25):2224-2231
- Glassman SD, Berven S, Bridwell K, Horton W, Dimar JR. Correlation of radiographic parameters and clinical symptoms in adult scoliosis. *Spine (Phila Pa 1976)* 2005;30(6):682-688
- Takayama K, Nakamura H, Matsuda H. Quality of life in patients treated surgically for scoliosis: longer than sixteen-year follow-up. *Spine (Phila Pa 1976)* 2009;34(20):2179-2184
- Ames CP, Blondel B, Scheer JK, et al. Cervical radiographical alignment: comprehensive assessment techniques and potential importance in cervical myelopathy. *Spine (Phila Pa 1976)* 2013;38(22, Suppl 1):S149-S160
- Suda K, Abumi K, Ito M, Shono Y, Kaneda K, Fujiya M. Local kyphosis reduces surgical outcomes of expansive open-door laminoplasty for cervical spondylotic myelopathy. *Spine (Phila Pa 1976)* 2003;28(12):1258-1262
- Tang JA, Scheer JK, Smith JS, et al; ISSG. The impact of standing regional cervical sagittal alignment on outcomes in posterior cervical fusion surgery. *Neurosurgery* 2012;71(3):662-669, discussion 669
- Lee SH, Kim KT, Seo EM, Suk KS, Kwack YH, Son ES. The influence of thoracic inlet alignment on the craniocervical sagittal balance in asymptomatic adults. *J Spinal Disord Tech* 2012;25(2):E41-E47
- Nojiri K, Matsumoto M, Chiba K, et al. Relationship between alignment of upper and lower cervical spine in asymptomatic individuals. *J Neurosurg* 2003;99(1, Suppl):80-83
- Ishii K, Matsumoto M, Takahashi Y, et al. Risk factors for development of subaxial subluxations following atlantoaxial arthrodesis for atlantoaxial subluxations in rheumatoid arthritis. *Spine (Phila Pa 1976)* 2010;35(16):1551-1555
- Ito H, Neo M, Sakamoto T, Fujibayashi S, Yoshitomi H, Nakamura T. Subaxial subluxation after atlantoaxial transarticular screw fixation in rheumatoid patients. *Eur Spine J* 2009;18(6):869-876
- Yoshida G, Kamiya M, Yoshihara H, et al. Subaxial sagittal alignment and adjacent-segment degeneration after atlantoaxial fixation performed using C-1 lateral mass and C-2 pedicle screws or transarticular screws. *J Neurosurg Spine* 2010;13(4):443-450
- Yoshimoto H, Ito M, Abumi K, et al. A retrospective radiographic analysis of subaxial sagittal alignment after posterior C1-C2 fusion. *Spine (Phila Pa 1976)* 2004;29(2):175-181

- 15 Matsunaga S, Onishi T, Sakou T. Significance of occipitoaxial angle in subaxial lesion after occipitocervical fusion. *Spine (Phila Pa 1976)* 2001;26(2):161–165
- 16 Passias PG, Wang S, Kozanek M, Wang S, Wang C. Relationship between the alignment of the occipitoaxial and subaxial cervical spine in patients with congenital atlantoaxial dislocations. *J Spinal Disord Tech* 2013;26(1):15–21
- 17 Ha Y, Schwab F, Lafage V, et al. Reciprocal changes in cervical spine alignment after corrective thoracolumbar deformity surgery. *Eur Spine J* 2014;23(3):552–559
- 18 Knott PT, Mardjetko SM, Tschy F. The use of the T1 sagittal angle in predicting overall sagittal balance of the spine. *Spine J* 2010; 10(11):994–998
- 19 Smith JS, Shaffrey CI, Lafage V, et al; International Spine Study Group. Spontaneous improvement of cervical alignment after correction of global sagittal balance following pedicle subtraction osteotomy. *J Neurosurg Spine* 2012;17(4):300–307
- 20 Shimizu T, Oyama M, Fueki K, et al. Correction surgeries for irreducible kyphotic deformities at craniovertebral junction (in Japanese). *Orthop Surg* 2013;64:939–945
- 21 McGregor M. The significance of certain measurements of the skull in the diagnosis of basilar impression. *Br J Radiol* 1948;21(244): 171–181
- 22 Shoda N, Takeshita K, Seichi A, et al. Measurement of occipitocervical angle. *Spine (Phila Pa 1976)* 2004;29(10): E204–E208