




# Combined Transcranial and Endoscopic Endonasal Approach for Resection of a Complex Sinonasal Squamous Cell Carcinoma: Two-Dimensional Operative Video

Peyton L. Nisson, MD<sup>1,2</sup>  Michael Gaub, MD<sup>2,3</sup> Gabriel S. Gonzales-Portillo, BS<sup>4</sup>  
Nikolay Martirosyan, MD, PhD<sup>2</sup> Christopher Le, MD<sup>5</sup> G. Michael Lemole Jr., MD<sup>6</sup>

<sup>1</sup> Department of Neurosurgery, Cedars-Sinai, Los Angeles, California, United States

<sup>2</sup> Department of Neurosurgery, Banner-University Medical Center, Tucson, Arizona, United States

<sup>3</sup> Department of Neurosurgery University of Texas Health Science Center, San Antonio, Texas, United States

<sup>4</sup> College of Medicine, University of Arizona, Tucson, Arizona, United States

<sup>5</sup> Department of Otolaryngology, Banner-University Medical Center, Tucson, Arizona, United States

<sup>6</sup> Department of Neurological Surgery, Thomas Jefferson University, Abington, PA, United States

Address for correspondence G. Michael Lemole Jr., MD, Department of Neurological Surgery, Thomas Jefferson University, Abington Hospital 1 Widener, 1200 Old York Road, Abington, PA 19001, United States (e-mail: michael.lemole@jefferson.edu).

J Neurol Surg B Skull Base 2022;83(suppl S3):e657–e658.

## Abstract

Sinonasal squamous cell carcinoma (SCC) is a rare head-and-neck neoplasm that has a propensity to locally invade vital structures. Currently, the combination of surgical resection and radiation remains the optimal treatment.<sup>1</sup> However, the extent of disease burden and involvement of surrounding anatomy may make these inoperable. Here, we demonstrate the successful application of multidisciplinary approach for surgical resection of a large, complex SCC lesion centered at the superior nasal cavity with extension into the eye orbits and brain. A two-step approach was performed; transcribiform, endoscopic piecemeal resection with reconstruction of the skull base, followed by a bifrontal craniotomy. Reconstruction was achieved using an inlay of DuraMatrix allograft (Stryker Inc., Kalamzoo, Michigan, United States) followed by an inlay of AlloDerm (Allergan Inc., Irvine, California, United States), anchored anteriorly and posteriorly with wide wings placed over the respective orbital roofs. Major steps include (1) a summary of the patient presentation and preoperative imaging, (2) resection of the tumor endonasally, (3) resection of the tumor intracranially from a bifrontal craniotomy, and (4) a review of the postoperative imaging. The patient tolerated the procedure (► **Fig. 1**) well, returned to his baseline with no new neurologic deficits, and was placed on 6-week antibiotics regimen for osteomyelitis discovered during the operation. Approximately, 2 months after discharge, the patient unfortunately returned with altered mental status, was found to have sepsis, and expired shortly thereafter. This operative video illustrates the technical steps and capabilities of surgical treatment, achieving near-complete gross total resection of a complex SCC lesion using a multidisciplinary approach. The link to the video can be found at: <https://youtu.be/8ffckKluBzM>.

## Keywords

- skull base
- tumor
- microsurgery
- squamous cell carcinoma
- sinonasal
- transcribiform
- endonasal

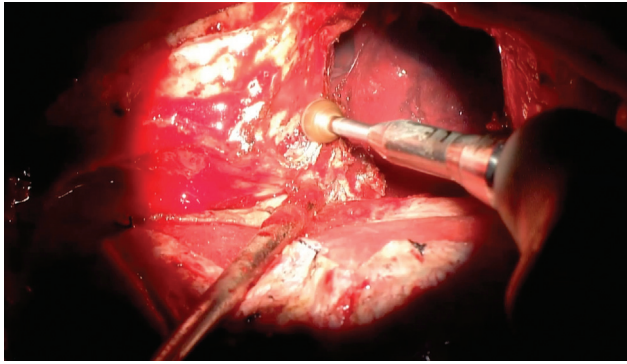
received  
March 26, 2020  
accepted after revision  
September 23, 2021  
published online  
December 1, 2021

DOI <https://doi.org/10.1055/s-0041-1736629>.  
ISSN 2193-6331.

© 2021. The Author(s).

This is an open access article published by Thieme under the terms of the Creative Commons Attribution-NonDerivative-NonCommercial-License, permitting copying and reproduction so long as the original work is given appropriate credit. Contents may not be used for commercial purposes, or adapted, remixed, transformed or built upon. (<https://creativecommons.org/licenses/by-nc-nd/4.0/>)

Georg Thieme Verlag KG, Rüdigerstraße 14, 70469 Stuttgart, Germany



**Fig 1** In this operative photograph, drilling of the superomedial orbit for the purpose of removing tumor-infiltrated bone is depicted.

[www.thieme.com/skullbasevideos](http://www.thieme.com/skullbasevideos)  
[www.thieme.com/jnlsbvideos](http://www.thieme.com/jnlsbvideos)

**Financial Disclosures**  
None.

**Conflict of Interest**  
None declared.

#### **References**

- 1 Llorente JL, López F, Suárez C, Hermsen MA. Sinonasal carcinoma: clinical, pathological, genetic and therapeutic advances. *Nat Rev Clin Oncol* 2014;11(08):460–472