

Are inferior facetectomies adequate and suitable for surgical treatment of adolescent idiopathic scoliosis?

Hiroyuki Yoshihara, MD, PhD*, Gregory S. Penny, MD, Harleen Kaur, BA, Neil V. Shah, MD, MS, Carl B. Paulino, MD

Abstract

Study Design: Retrospective review.

Background: Inferior facetectomies, with the utilization of segmental pedicle screw constructs for corrective fixation, can provide adequate flexibility and post less risk of neural tissue and blood loss. We analyzed outcomes of surgical treatment for adolescent idiopathic scoliosis (AIS) using inferior facetectomies and segmental pedicle screw constructs. We hypothesized that adequate main curve correction and suitable surgical outcomes would be observed using this technique.

Methods: We reviewed 38 AIS patients who underwent inferior facetectomies and segmental pedicle screw constructs by 2 surgeons at a single institution between May 2014 and December 2016. Coronal and sagittal radiographic measurements were evaluated over 1-year follow-up by 2 trained observers not associated with the surgeries. Surgical details, complications, and hospital length of stay (LOS) were also recorded.

Results: Mean fusion levels were 11.0 ± 1.7 . The mean Cobb angle of main AIS curves improved from 48.6 ± 10.1 degree preoperatively to 11.8 ± 6.2 degree postoperatively and 12.4 ± 6.2 degree at 1-year follow-up, which percentage correction was 75.9% and 74.6%, respectively. The mean thoracic kyphosis (T5-12) angle was 20.7 ± 11.6 degree preoperatively, 17.4 ± 8.0 degree postoperatively, and 16.8 ± 8.4 degree at 1-year follow-up. The mean surgical time, estimated blood loss, and LOS were 232.4 ± 35.7 minutes, 475.0 ± 169.6 mL, and 3.5 ± 1.3 days. Twelve patients received blood transfusion. There were no neurological or wound complications.

Conclusions: This case series demonstrated adequate correction of main AIS curves, acceptable thoracic kyphosis and blood loss, and short surgical time and LOS in AIS patients treated with inferior facetectomies and segmental pedicle screw constructs, potentially indicating that inferior facetectomies are adequate and suitable for AIS surgery when segmental pedicle screw constructs are utilized.

Abbreviations: AIS = adolescent idiopathic scoliosis, CoCr = cobalt chrome, EBL = estimated blood loss, LOS = length of stay, M = mean, MEP = motor evoked potential, mL = milliliters, PA = posteroanterior, SD = standard deviation, SSEP = somatosensory evoked potential.

Keywords: adolescent idiopathic scoliosis, inferior facetectomy, pedicle screw constructs, Ponte osteotomy, posterior spinal fusion

Editor: Yan Li.

The following authors report no disclosures: HY, GSP, HK, NVS. The following author is a consultant for, or has received institutional or research support from the following companies: CBP – DePuy/Johnson & Johnson/Ethicon.

This research received no specific grant from any funding agency in the public, commercial, or not-for-profit sectors. The manuscript submitted does not contain any information about medical device(s)/drug(s).

The authors report no conflicts of interest.

Department of Orthopaedic Surgery & Rehabilitation Medicine, State University of New York (SUNY), Downstate Medical Center, Brooklyn, NY.

* Correspondence: Hiroyuki Yoshihara, Department of Orthopaedic Surgery and Rehabilitation Medicine, SUNY Downstate Medical Center, 450 Clarkson Ave, MSC 30, Brooklyn, NY 11203 (e-mail: Hiroyuki.Yoshihara@downstate.edu).

Copyright © 2019 the Author(s). Published by Wolters Kluwer Health, Inc.

This is an open access article distributed under the terms of the Creative Commons Attribution-Non Commercial License 4.0 (CCBY-NC), where it is permissible to download, share, remix, transform, and buildup the work provided it is properly cited. The work cannot be used commercially without permission from the journal.

How to cite this article: Yoshihara H, Penny GS, Kaur H, Shah NV, Paulino CB. Are inferior facetectomies adequate and suitable for surgical treatment of adolescent idiopathic scoliosis?. *Medicine* 2019;98:47(e18048).

Received: 5 June 2019 / Received in final form: 12 October 2019 / Accepted: 21 October 2019

<http://dx.doi.org/10.1097/MD.00000000000018048>

1. Introduction

Surgical treatment of adolescent idiopathic scoliosis (AIS) has been performed for more than half a century. During this time period, surgical techniques, procedures, and instrumentations have certainly evolved. Posterior spinal fusion using segmental pedicle screw instrumentation has recently been utilized as a standard technique to correct and stabilize the scoliotic curve.^[1–5] This technique provides strong correction and fixation.^[6–8]

Osteotomy is an essential technique to make spinal deformity flexible. Ponte osteotomy is a widespread technique for achieving correction of major curves in the setting of AIS^[9–14]; however, this technique theoretically owns an increased risk of neural tissue injury and blood loss. In contrast, inferior facetectomies are able to provide flexibility with less risk to neural tissue and of blood loss; it may also provide adequate correction with the utilization of segmental pedicle screw instrumentation.^[12]

In this study, we analyzed the outcomes of surgical treatment for AIS patients using inferior facetectomies with segmental pedicle screw constructs. We hypothesized AIS patients would have adequate main curve correction and suitable surgical outcomes when surgery was performed using inferior facetectomies and segmental pedicle screw constructs.

2. Materials and methods

2.1. Patient population

We reviewed a retrospectively collected database of AIS patients from a single, academic institution. Included in this study were AIS patients who underwent posterior spinal fusion surgery using inferior facetectomies and pedicle screw instrumentation by the same 2 surgeons (HY and CBP) between May 2014 and December 2016. Patients were excluded if there was no 1-year follow-up or adequate radiographs were not available. This study was approved by the institutional review board of State University of New York, Downstate Medical Center.

2.2. Surgical technique

With the patient prone on the Jackson table, the spine was exposed subperiosteally from the proximal to distal levels of planned fusion using an electrocautery blade. We exposed up to the tip of the transverse processes at each level. We securely saved soft tissues such as ligaments and facet joint capsule at proximal and distal ends to prevent junctional kyphosis. The superior spinous ligament, interspinous ligament, and spinous processes were removed between the planned fusion levels. Inferior facetectomy procedures were performed by removing a portion of the inferior articular process at each level, using an osteotome to expose the superior articular process of the lower vertebra. The entry point for each pedicle screw was made using a burr. A gearshift probe, ball-tipped feeler, and tap were then used to prepare the pedicle screw path, under fluoroscopic guidance. Placement of pedicle screws was attempted at all levels on both sides. After placement of all screws, we stimulated the screws directly using electromyographic thresholds. The Expedium Spine System (DePuy-Synthes Spine, Inc., a Johnson & Johnson Company, Raynham, MA) for posterior segmental instrumentation was used in all cases. Subsequently, contoured 5.5-mm cobalt chrome (CoCr) rods were dropped down along the clips with gradual correction of scoliosis. Adequate scoliosis correction was confirmed fluoroscopically. We decorticated superior

articular processes, laminae, and transverse processes at each vertebral level to obtain suitable posterior fusion and used local autograft and allograft bone for fusion. All cases were performed with neuromonitoring for somatosensory evoked potentials, transcranial motor evoked potentials, and direct pedicle screw electromyographic monitoring.

2.3. Data collection

Patient demographics such as age and sex were recorded. Surgical and postoperative details were reviewed, including surgical time (from incision to wound closure), number of fused levels, instrumented levels, neuromonitoring signal changes, estimated blood loss (EBL), blood transfusion utilization, hospital length of stay (LOS), and any in-hospital complications. We also reviewed clinical outpatient visits for any reported complications.

Two trained observers who were not associated with the surgeries evaluated radiographs at preoperation, first-erect (a few weeks following surgery), and 1-year follow-up. Figure 1 presents a radiographic case example. Coronal measurements included the Major Cobb angle on standing and bending radiographs. Sagittal measurements included Cobb angles at levels T5-T12 on standing radiographs. Criteria for radiological evaluation of pseudarthrosis were loss of Cobb angle correction of >10 degree and/or instrumentation failure.

The operative time per level, blood loss per level, flexibility ratio of the largest curve, and percent main curve correction were calculated.

3. Results

A total of 38 patients met the inclusion criteria (Table 1). The mean age at surgery was 15.2 ± 3.1 years. There were 11 males and 27 females. The mean preoperative coronal Cobb angle of main curve was 48.6 ± 10.1 degree. That angle on bending film was 24.9 ± 13.7 degree and the flexibility index was $50.3\% \pm 23.0\%$. The mean preoperative thoracic kyphosis (T5-12) angle was 20.7 ± 11.6 degree.

Cobalt chrome rod of 5.5mm was used in all patients. One screw was skipped in 9 patients, 2 screws in 4 patients, 3 screws in 2 patients, and 6 screws in 1 patient. The mean number of fused levels was 11.0 ± 1.7 . The mean surgical time was 232.4 ± 35.7 minutes. The mean surgical time per level was 21.4 ± 4.4 minutes. Intraoperative monitoring signal changes were not reported for any patient. The mean EBL was 475.0 ± 169.6 mL. The mean EBL per level was 43.3 ± 14.3 mL. Two patients received cell saver transfusion. Twelve patients received blood products transfusion. Among 12 patients, 10 patients received during surgery, 1 patient received during and after surgery, and 1 patient received after surgery. The mean LOS was 3.5 ± 1.3 days including the day of surgery. One patient received an unintentional Vancomycin overdose and had to stay 10 days for observation. There were no other major complications in any patients, including neurological or wound complications.

The mean coronal Cobb angle of main curve was 11.8 ± 6.2 degree postoperatively and 12.4 ± 6.2 degree at 1-year follow-up, for which percentage correction was 75.9% and 74.6%, respectively. The mean thoracic kyphosis (T5-12) angle was 17.4 ± 8.0 degree postoperatively and 16.8 ± 8.4 degree at 1-year follow-up. We noted no cases of obvious pseudarthrosis at 1-year follow-up.

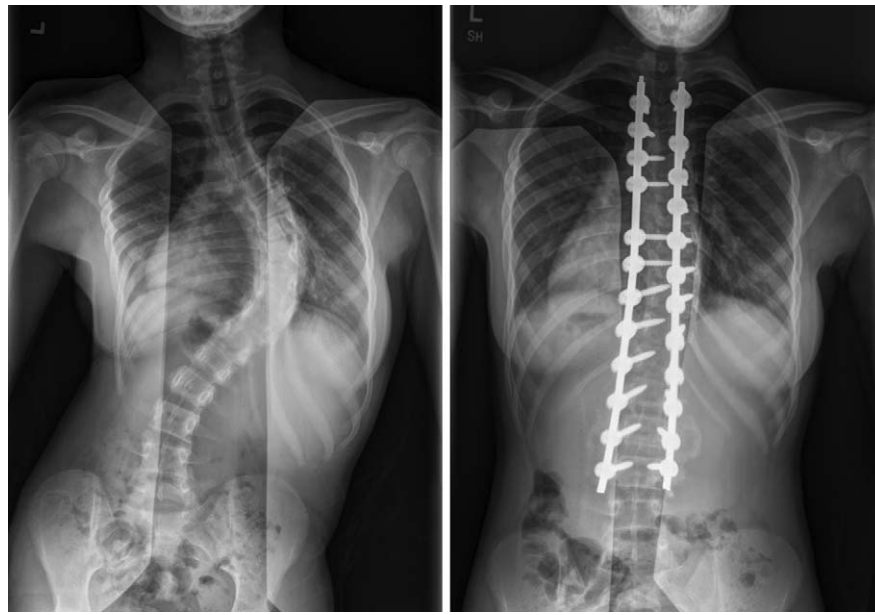


Figure 1. Case illustration of a 15-year-old female who underwent inferior facetectomies with pedicle screw instrumentation from T3-L3. (Left) Preoperative posteroanterior (PA) radiograph shows a 76 degree main thoracic curve. (Right) An immediate postoperative PA radiograph, showing a 14 degree main thoracic curve.

4. Discussion

Achieving adequate correction of a scoliotic curve is one of the major goals of AIS surgery, although preventing curve progression is the most important goal. Osteotomy is a crucial technique to make the spinal deformity flexible. Ponte osteotomy is a widespread technique to achieve correction of major curves in AIS. Shufflebarger et al^[9,10] first described the use of this technique for the correction of lumbar and thoracolumbar AIS and showed better curve correction with the use of both hooks

and pedicle screws as anchors. Recently, Shah et al^[13] also reported an improvement of major thoracic curve in AIS patients treated with segmental pedicle screw constructs and Ponte osteotomies. In their study, the mean coronal thoracic Cobb angle improved from 57.1 to 18.3 degree at 1-year follow-up, for which percentage correction was 69.6%. In contrast, although it is not as wide posterior release as Ponte osteotomy, inferior facetectomy is likewise able to provide flexibility and has been utilized in AIS surgery. Several studies have also reported on the outcomes of inferior facetectomies in AIS surgery.^[12,14] Halanski and Cassidy^[12] found no difference in the largest coronal curve correction while utilizing inferior facetectomies when compared to Ponte osteotomies, although Samdani et al^[14] reported a significant difference. In the previous literature, the percentage correction of the main curve was reported to be 62% to 84%, using pedicle screw constructs that possess strong correction force.^[4,12–14] Our case series demonstrated that the mean Cobb angle of main AIS curves improved from 48.6 degree preoperatively to 12.4 degree at 1-year follow-up, with a percentage correction of 74.6%. Therefore, in terms of coronal deformity correction, our results may support the notion that inferior facetectomies can achieve adequate correction when segmental pedicle screw constructs are concurrently utilized.

It is important to place pedicle screws in an adequate position, particularly when deformity correction is performed with inferior facetectomies. As inferior facetectomies do not provide as wide of a posterior release as Ponte osteotomies do, more biomechanical stress is applied to pedicles screws while performing corrective manipulation. If pedicle screws are not in the adequate position and strong force for the deformity correction is applied, such screws can breach the pedicle and possibly damage the spinal cord or chest cavity. Our pedicle screw placement was performed under fluoroscopic guidance and those screws were securely placed in the pedicle; therefore, it should be noted that strong

Table 1

Summary of patient demographics, surgery data, and radiographic measurements of AIS patients who underwent inferior facetectomies with segmental pedicle screw constructs.

Patient demographics	M ± SD
Age at surgery, y	15.2 ± 3.1
Male/female	11/27
Surgery data	
Fused levels	11.0 ± 1.7
Surgical time, min	232.4 ± 35.7
Surgical time per level, min	21.4 ± 4.4
Estimated blood loss, mL	475.0 ± 169.6
Estimated blood loss per level, mL	43.3 ± 14.3
Hospital length of stay, days	3.5 ± 1.3
Radiographic measurements	
Coronal Cobb angle of main curve, degree	
Preoperative	48.6 ± 10.1
First-erect postoperative	11.8 ± 6.2
1-y postoperative	12.4 ± 6.2
Thoracic kyphosis (T5-12) angle, degree	
Preoperative	20.7 ± 11.6
First-erect postoperative	17.4 ± 8.0
1-y postoperative	16.8 ± 8.4

AIS=adolescent idiopathic scoliosis, M=mean, SD=standard deviation.

force for the deformity correction could be applied to the pedicle screws more safely in our procedure.

Our study results showed decreased thoracic kyphosis after surgery (20.7 degree preoperatively to 17.4 degree postoperatively and 16.8 degree at 1-year follow-up). Loss of kyphosis in deformity correction of AIS using pedicle screw constructs has been reported.^[4,15–17] Lehman et al^[4] found the mean lateral Cobb angle decreased from 26.2 to 14.5 degree postoperatively in a single-center series of 114 consecutive AIS patients treated with pedicle screw constructs. Although it is not proven, preservation and restoration of thoracic kyphosis are important for maintaining lumbar lordosis and preventing flatback and loss of sagittal balance with aging.^[18] Wide posterior release such as Ponte osteotomy may improve thoracic kyphosis. However, Halanski and Cassidy^[12] found no significant difference in thoracic kyphosis restoration between inferior facetectomy and Ponte osteotomy techniques, although Samdani et al^[14] found a significant difference. We acknowledge that we focused more on the coronal scoliosis correction than sagittal thoracic kyphosis preservation during the study period. We have considered that technical adjustments, such as contouring the rod with more thoracic kyphosis, using a larger diameter rod, or in-situ bending after rod placement, could achieve around 5 to 10 degree kyphosis restoration without requiring additional release.

AIS surgery is a major procedure associated with long operative time, significant amount of blood loss, and major complications such as spinal cord injury; therefore, patient safety is more crucial than deformity correction in AIS surgery. Despite the positive aspects of deformity correction, osteotomy techniques have drawbacks such as blood loss and risk of neurologic injury. Inferior facetectomy is a less invasive osteotomy technique than Ponte osteotomy, requiring closer exposure to spinal cord and epidural vessels. In fact, a recent multicenter study reported the mean EBL was 970 mL for Ponte osteotomy group and 778 mL for inferior facetectomy group.^[14] Furthermore, inferior facetectomy is a part of the Ponte osteotomy procedure and requires less procedure time. Halanski and Cassidy^[12] reported shorter surgical time and less blood loss in the inferior facetectomy group compared to the Ponte osteotomy group. Surgical time for posterior AIS surgery using pedicle screw constructs has been reported to be 277 to 321 minutes in recent literature.^[13,14] In our case series, the mean surgical time and EBL were 232.4 minutes and 475.0 mL, and there were no neurologic or wound complications observed. Therefore, our study demonstrated favorable results of patient safety factors, which may support inferior facetectomies as suitable for AIS surgery. Additionally, the mean LOS in this study (3.5 days) was shorter than that of multicenter studies (5.3 days) and national data (5.5 days),^[14,19] and we believe that short surgery and anesthesia time, along with a relatively small amount of blood loss contributed to the short LOS.

This study has several limitations. We did not have a control group to compare with other techniques, such as Ponte osteotomy, and historical controls are not sufficient to make conclusions. Additionally, our cohort did not have many severe or stiff main coronal curves (only 1 patient >70°). We acknowledge that patients with severe or stiff coronal curves, or kyphoscoliotic deformity, may need additional tissue release, such as Ponte osteotomy.^[12] Other limitations of this study include its retrospective nature, the relatively small sample size, and short follow-up. Our follow-up of 1 year is not sufficient to adequately evaluate for pseudarthrosis, which is a potential risk

with any spinal osteotomy. However, we believe the duration of follow-up was sufficient enough to answer the purpose of current study. Despite these limitations, all patients underwent surgery by the same 2 surgeons using the same technique, and radiographic measurements were performed by 2 trained observers who were not associated with the surgeries. Thus, we believe that our study results add meaningful knowledge to the limited literature on this technique.

5. Conclusions

This case series demonstrated adequate correction of main AIS curves, acceptable thoracic kyphosis, acceptable blood loss, short surgical time, and short hospital stay in AIS patients treated with inferior facetectomies and segmental pedicle screw constructs. Although patients with severe or stiff coronal curve may need additional tissue release such as Ponte osteotomy, our results could indicate that inferior facetectomies are adequate and suitable for AIS surgery when segmental pedicle screw constructs are utilized.

Author contributions

Conceptualization: Hiroyuki Yoshihara.

Data curation: Gregory S. Penny, Neil V. Shah, Harleen Kaur, Carl B. Paulino, Hiroyuki Yoshihara.

Investigation: Gregory S. Penny, Neil V. Shah, Harleen Kaur, Carl B. Paulino, Hiroyuki Yoshihara.

Methodology: Hiroyuki Yoshihara.

Resources: Gregory S. Penny, Neil V. Shah, Harleen Kaur, Carl B. Paulino, Hiroyuki Yoshihara.

Supervision: Hiroyuki Yoshihara.

Writing – original draft: Hiroyuki Yoshihara.

Writing – review & editing: Hiroyuki Yoshihara.

References

- [1] Halm H, Niemeyer T, Link T, et al. Segmental pedicle screw instrumentation in idiopathic thoracolumbar and lumbar scoliosis. *Eur Spine J* 2000;9:191–7. Available from: <http://www.ncbi.nlm.nih.gov/pubmed/10905435>.
- [2] Gaines RW. The use of pedicle-screw internal fixation for the operative treatment of spinal disorders. *J Bone Joint Surg Am* 2000;82-A:1458–76. Available from: <http://www.ncbi.nlm.nih.gov/pubmed/11057475>.
- [3] Kim YJ, Lenke LG, Cho SK, et al. Comparative analysis of pedicle screw versus hook instrumentation in posterior spinal fusion of adolescent idiopathic scoliosis. *Spine (Phila Pa 1976)* 2004;29:2040–8. Available from: <http://www.ncbi.nlm.nih.gov/pubmed/15371706>.
- [4] Lehman RA, Lenke LG, Keeler KA, et al. Operative treatment of adolescent idiopathic scoliosis with posterior pedicle screw-only constructs minimum three-year follow-up of one hundred fourteen cases. *Spine (Phila Pa 1976)* 2008;33:1598–604. Available from: <http://www.ncbi.nlm.nih.gov/pubmed/18552676>.
- [5] Li M, Shen Y, Fang X, et al. Coronal and sagittal plane correction in patients with Lenke 1 adolescent idiopathic scoliosis: a comparison of consecutive versus interval pedicle screw placement. *J Spinal Disord Tech* 2009;22:251–6. Available from: <http://www.ncbi.nlm.nih.gov/pubmed/19494744>.
- [6] Liljenqvist U, Hackenberg L, Link T, et al. Pullout strength of pedicle screws versus pedicle and laminar hooks in the thoracic spine. *Acta Orthop Belg* 2001;67:157–63. Available from: <http://www.ncbi.nlm.nih.gov/pubmed/11383294>.
- [7] Lehman RA, Polly DW, Kuklo TR, et al. Straight-forward versus anatomic trajectory technique of thoracic pedicle screw fixation: a biomechanical analysis. *Spine (Phila Pa 1976)* 2003;28:2058–65. Available from: <http://www.ncbi.nlm.nih.gov/pubmed/14501914>.

- [8] Lehman RA, Kuklo TR. Use of the anatomic trajectory for thoracic pedicle screw salvage after failure/violation using the straight-forward technique: a biomechanical analysis. *Spine (Phila Pa 1976)* 2003;28:2072–7. Available from: <http://www.ncbi.nlm.nih.gov/pubmed/14501916>.
- [9] Shufflebarger HL, Clark CE. Effect of wide posterior release on correction in adolescent idiopathic scoliosis. *J Pediatr Orthop B* 1998;7:117–23. Available from: <http://www.ncbi.nlm.nih.gov/pubmed/9597586>.
- [10] Shufflebarger HL, Geck MJ, Clark CE. The posterior approach for lumbar and thoracolumbar adolescent idiopathic scoliosis: posterior shortening and pedicle screws. *Spine (Phila Pa 1976)* 2004;29:269–76. discussion 276. Available from: <http://www.ncbi.nlm.nih.gov/pubmed/14752348>.
- [11] Pizones J, Izquierdo E, Sánchez-Mariscal F, et al. Does wide posterior multiple level release improve the correction of adolescent idiopathic scoliosis curves? *J Spinal Disord Tech* 2010;23:e24–30. Available from: <http://www.ncbi.nlm.nih.gov/pubmed/20075750>.
- [12] Halanski MA, Cassidy JA. Do multilevel Ponte osteotomies in thoracic idiopathic scoliosis surgery improve curve correction and restore thoracic kyphosis? *J Spinal Disord Tech* 2013;26:252–5.
- [13] Shah SA, Dhawale AA, Oda JE, et al. Ponte osteotomies with pedicle screw instrumentation in the treatment of adolescent idiopathic scoliosis. *Spine Deform* 2013;1:196–204.
- [14] Samdani AF, Bennett JT, Singla AR, et al. Do Ponte osteotomies enhance correction in adolescent idiopathic scoliosis? An analysis of 191 Lenke 1A and 1B curves. *Spine Deform* 2015;3:483–8.
- [15] Kim YJ, Lenke LG, Kim J, et al. Comparative analysis of pedicle screw versus hybrid instrumentation in posterior spinal fusion of adolescent idiopathic scoliosis. *Spine (Phila Pa 1976)* 2006;31:291–8. Available from: <http://www.ncbi.nlm.nih.gov/pubmed/16449901>.
- [16] Lowenstein JE, Matsumoto H, Vitale MG, et al. Coronal and sagittal plane correction in adolescent idiopathic scoliosis: a comparison between all pedicle screw versus hybrid thoracic hook lumbar screw constructs. *Spine (Phila Pa 1976)* 2007;32:448–52.
- [17] Imrie M, Yaszay B, Bastrom TP, et al. Adolescent idiopathic scoliosis: should 100% correction be the goal? *J Pediatr Orthop* 2011;31(1 suppl): S9–13. Available from: <http://www.ncbi.nlm.nih.gov/pubmed/21173626>.
- [18] Newton PO, Yaszay B, Upasani VV, et al. Preservation of thoracic kyphosis is critical to maintain lumbar lordosis in the surgical treatment of adolescent idiopathic scoliosis. *Spine (Phila Pa 1976)* 2010;35:1365–70. [cited 2015 Mar 6]. Available from: <http://www.ncbi.nlm.nih.gov/pubmed/20505560>.
- [19] Yoshihara H, Paulino C, Yoneoka D. Predictors of increased hospital stay in adolescent idiopathic scoliosis patients undergoing posterior spinal fusion: analysis of National Database. *Spine Deform* 2018;6:226–30. Available from: <http://www.ncbi.nlm.nih.gov/pubmed/29735130>.