



Cardiac Tuberculosis on ^{18}F -FDG PET Imaging—A Great Masquerader of Cardiac Sarcoidosis

Sumati Sundaraiya¹ Abubacker Sulaiman² Adhithyan Rajendran²

¹Department of Nuclear Medicine, Apollo Proton Cancer Centre, Tharamani, Tamil Nadu, India

²Department of Radiology, Apollo Proton Cancer Centre, Tharamani, Tamil Nadu, India

Address for correspondence Abubacker Sulaiman, DNB, MNAMS, Department of Radiology, Apollo Proton Cancer Centre, 4/661, Dr. Vikram Sarabai Instronic Estate 7th St, Dr. Vasi Estate, Phase II, Tharamani, Chennai, Tamil Nadu - 600096, India (e-mail: drabubacker_s@apollohospitals.com).

Indian J Radiol Imaging 2021;31:1002–1007.

Abstract

A young gentleman with suspected cardiac sarcoidosis and LV dysfunction whose CMR revealed multifocal subepicardial to mid myocardial linear enhancement in the left ventricular myocardium underwent cardiac ^{18}F -FDG PET imaging. The images revealed patchy regions of increased FDG uptake involving the apical to mid anterolateral, mid to basal anteroseptal/ right ventricular and mildly increased FDG uptake in apical inferior segments of the LV myocardium concordant with CMR findings. Whole body PET CT imaging showed multiple hypermetabolic supra and infra diaphragmatic lymphadenopathy, with no pulmonary lesion identified. Biopsy from the left para aortic lymph node revealed necrotizing granulomatous inflammation consistent with tuberculosis. Based on the histopathological findings of the lymph nodes, diagnosis of cardiac tuberculosis was made, given the similar imaging appearances in both sarcoidosis and TB. This case highlights that cardiac TB although rare, should be included in the differential diagnosis in patients with suspected infiltrative cardiomyopathy, particularly in TB endemic regions.

Keywords

- ▶ cardiac tuberculosis
- ▶ tuberculous myocarditis
- ▶ cardiac ^{18}F -FDG PET
- ▶ myocardial hypermetabolism

Introduction

Mycobacterium tuberculosis has the ability to invade almost every organ of the body. Cardiomyopathy due to granulomatous myocarditis comprises sarcoidosis, tuberculosis (TB), and other rare granulomatous diseases. Though a very rare and under-recognized entity, it is increasingly being recognized as compared with the past.^{1,2} The clinical presentation of cardiac TB mimics that of cardiac sarcoidosis, making an early diagnosis quite challenging.³ Delayed diagnosis may be attributed to the lack of constitutional symptoms and patients usually present with ventricular arrhythmias, conduction abnormalities, or heart failure. The diagnosis involves various investigations such as tuberculin skin test, imaging, histopathology, microbi-

ology, and immunology. Advanced imagings such as cardiac magnetic resonance (CMR) and ^{18}F -fluorodeoxyglycose (^{18}F -FDG) cardiac positron emission tomography/computed tomography (PET-CT) are routinely performed to diagnose cardiac involvement in sarcoidosis, with patchy uptake of FDG seen in isolated segments representing inflammation.⁴ We describe a case of TB myocarditis in a young patient being evaluated for inflammatory or infiltrative cardiomyopathy, with the imaging appearances similar to that of cardiac sarcoidosis.

Case Report

A 32-year-old euglycemic, normotensive gentleman presented with a 2-week history of breathlessness associated

published online
November 30, 2021

DOI <https://doi.org/10.1055/s-0041-1739379>
ISSN 0971-3026.

© 2021. Indian Radiological Association. All rights reserved.

This is an open access article published by Thieme under the terms of the Creative Commons Attribution-NonDerivative-NonCommercial-License, permitting copying and reproduction so long as the original work is given appropriate credit. Contents may not be used for commercial purposes, or adapted, remixed, transformed or built upon. (<https://creativecommons.org/licenses/by-nc-nd/4.0/>)

Thieme Medical and Scientific Publishers Pvt. Ltd., A-12, 2nd Floor, Sector 2, Noida-201301 UP, India

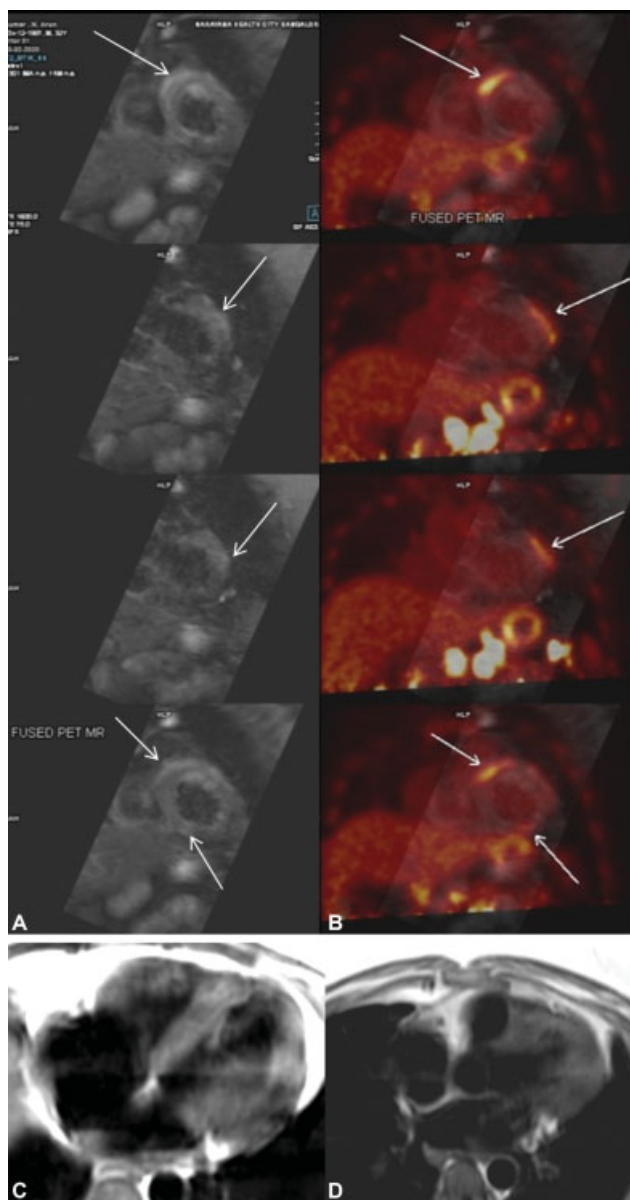


Fig. 1 (A) Cardiac magnetic resonance (CMR) shows multifocal subepicardial to mid-myocardial linear enhancement along the right ventricular insertion site, mid-anterolateral, and inferior segments (arrows) with corresponding focal myocardial edema. (B) Fused cardiac positron emission tomography CMR shows patchy areas of increased ^{18}F -fluorodeoxyglucose (FDG) uptake in the apical to mid-anterolateral, mid-to-basal anteroseptal at the right ventricular insertion site, and mildly increased FDG uptake in the apical inferior segments of the left ventricular myocardium corresponding to the regions of myocardial enhancement seen on CMR. (C and D) T2 black blood image showing T2 hyperintense changes in the left ventricular myocardium

with chest discomfort. He had no significant medical history. On evaluation, his electrocardiogram (ECG) showed atrial flutter and ventricular tachycardia for which direct current cardioversion was done. Two-dimensional echocardiography revealed global hypokinesia of left ventricle (LV) with severe LV dysfunction (32% left ventricular ejection fraction). He underwent CMR that revealed multifocal subepicardial to mid-myocardial linear enhancement along the right ventricular insertion site, mid, anterolateral, and inferior segments with corresponding focal myocardial edema (►Fig. 1B).

These findings favored inflammatory or infiltrative cardiomyopathy with sarcoidosis being the most likely diagnosis. He was treated with antiarrhythmic medications and anti-failure measures. In view of the CMR findings, the patient was referred to us for cardiac PET imaging along with whole body PET-CT.

A week later, cardiac PET was performed after 24 hours of high fat and protein diet and overnight fasting of 12 hours. He also received unfractionated heparin (5000 units/kg body weight) intravenously and 15 minutes later 8 mCi ^{18}F -FDG was injected. On the subsequent day, he underwent resting myocardial perfusion imaging (single-photon emission computerized tomography [SPECT]) after 1 hour of intravenous administration of 10 mCi $^{99\text{m}}\text{Tc}$ -sestamibi. Reconstructed cardiac PET images in short, horizontal, and vertical long axes showed patchy regions of increased FDG uptake involving the apical to mid-anterolateral, mid-to-basal anteroseptal at the right ventricular insertion site and mildly increased FDG uptake in the apical inferior segments of the LV myocardium (►Fig. 2A–E). The resting $^{99\text{m}}\text{Tc}$ -sestamibi scan showed a uniform perfusion in the LV myocardium, with no discrete perfusion defects corresponding to the regions of FDG uptake (►Fig. 2A). The LV cavity was nondilated with no significant regional wall motion abnormality. ECG gating of the resting tomograms revealed a mildly impaired LVEF of 47% suggesting interval improvement in the LV function. Fused PET CMR showed increased FDG uptake corresponding to the regions of myocardial enhancement seen on CMR (►Fig. 1A).

The whole-body PET-CT scan showed multiple metabolically active discrete and conglomerate lymphadenopathy involving bilateral infraclavicular, mediastinal, and bilateral hilar, right cardiophrenic, gastrohepatic, peripancreatic, splenic hilar, and retroperitoneal regions (►Fig. 3A–C). No pulmonary lesion was identified. Hence, the differentials of extrapulmonary sarcoidosis and tuberculosis were considered with a remote possibility of lymphoma or even metastatic disease to be excluded.

Follow-up blood investigations were within normal limits. Mantoux was negative with low induration. Serum angiotensin-converting enzyme (ACE) was not elevated. Holter monitoring showed sinus rhythm with frequent premature ventricular contractions and nonsustained ventricular tachycardia with no significant sinus pauses or atrioventricular block. Needle biopsy of the left paraaortic lymph node revealed necrotizing granulomatous inflammation consistent with tuberculosis and the patient was started on antitubercular drugs.

Discussion

Cardiac TB is found in ~0.5% of patients with extrapulmonary TB (EPTB) most commonly affecting the pericardium⁵ in the form of pericardial thickening and less commonly as pericardial effusion. Myocardial involvement is very rare, described in up to 0.3% of cases² and is known to present typically with congestive cardiac failure, tachy- and bradyarrhythmias, ventricular aneurysms, right ventricular outflow

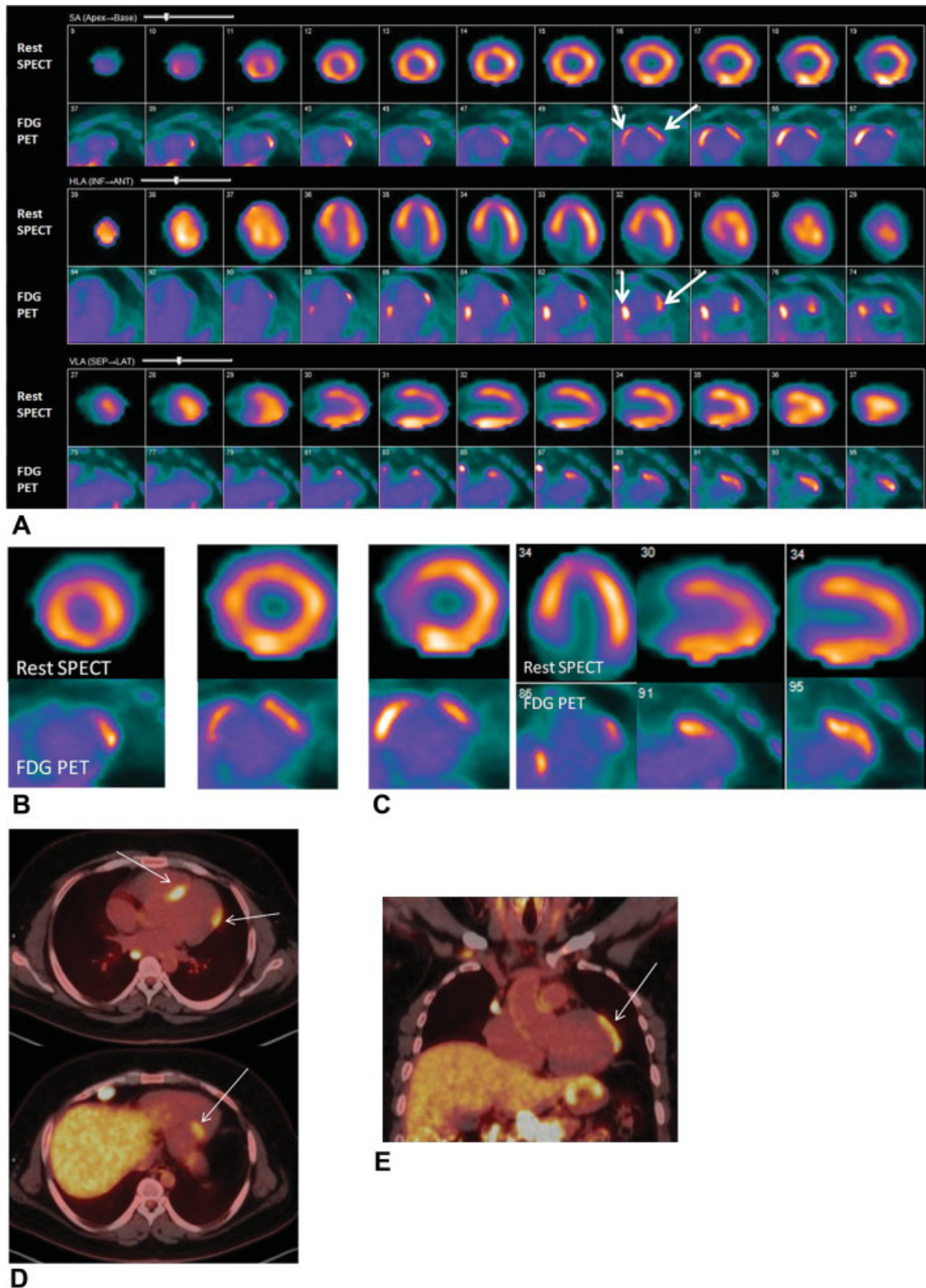


Fig. 2 (A–C) Reconstructed cardiac positron emission tomography (PET) images (bottom panel) in short, horizontal, and vertical long axis show patchy regions of increased ^{18}F -fluorodeoxyglycose (FDG) uptake involving the apical to mid-anterolateral, mid-to-basal anteroseptal at the right ventricular insertion site (arrows), and mildly increased FDG uptake in the apical inferior segments of the left ventricular (LV) myocardium (arrows). The study was performed after 24 hours of high-fat and high-protein diet and overnight fasting of 12 hours and 15 minutes after intravenous administration of unfractionated heparin to suppress physiological myocardial FDG uptake. Top panel shows reconstructed $^{99\text{m}}\text{Tc}$ -sestamibi rest perfusion scan showing uniform perfusion in the LV myocardium, with no discrete perfusion defects corresponding to the regions of FDG uptake. (D, E) Transaxial and coronal views of ^{18}F -FDG PET showing discrete regions of increased FDG uptake in LV myocardium suggesting active infection and/ or inflammation. SPECT, single-photon emission computerized tomography.

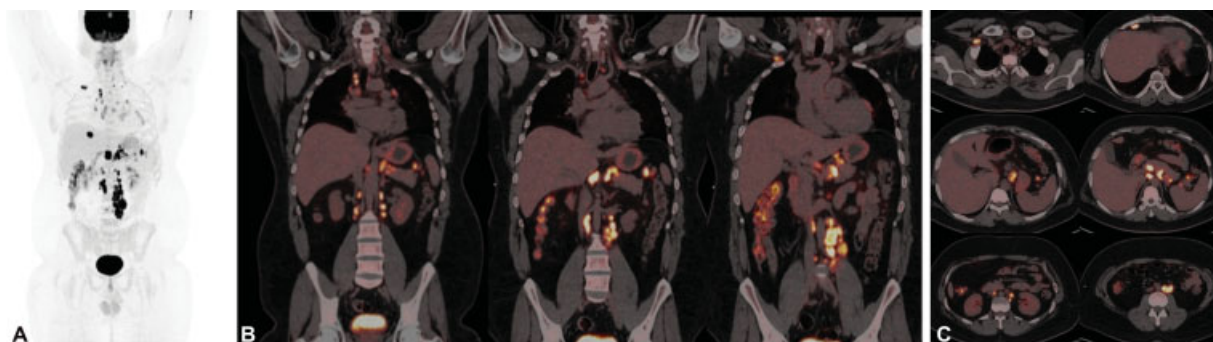


Fig. 3 Multiple intensity projection image in (A) coronal (B) and transaxial (C) sections of whole-body ^{18}F -fluorodeoxyglucose positron emission tomography/computed tomography shows the extent of disease involvement with multiple extracardiac metabolically active discrete and conglomerate lymphadenopathy involving bilateral infraclavicular, mediastinal and bilateral hilar, right cardiophrenic, gastrohepatic, peripancreatic, splenic hilar, and retroperitoneal regions. No pulmonary lesion was identified.

obstruction, and sudden cardiac death.^{6,7} Myocardial TB usually occurs either via lymphatic spread from mediastinal lymph nodes, direct spread from the pericardium, or by hematogenous seeding from a remote focus.⁵ Pathologically, TB infiltration of the myocardium has been described as either diffuse infiltrative, caseating nodular, or military, and can often mimic other cardiac infiltrative diseases such as sarcoidosis.⁵

The case described presented with chest discomfort and breathlessness with no constitutional symptoms. He had tachyarrhythmia in the form of atrial flutter and ventricular tachycardia that necessitated cardioversion and antiarrhythmic medication.

While TB can affect any organ in the body, lymph nodal TB is the most common form of EPTB that accounts for ~20 to 40% of all cases and usually presents as a gradually increasing painless swelling of one or more lymph nodes. It can be either a primary form or reactivation of a focus.⁸ The most common location is cervical lymphadenopathy (63–77%), although it can also affect other regions such as the supraclavicular, axillary, thoracic, and abdominal nodes.^{9,10} Biopsy of the affected lymph node and microbiological cytological smear testing as well as culture and polymerase chain reaction studies (sensitivity 77%, specificity 80%) show caseating granulomas that are highly suggestive of TB.^{9,10}

TB and sarcoidosis are granulomatous diseases that can challenge clinicians^{3,11}, with TB resulting in a caseating granuloma as opposed to sarcoidosis, which presents with a non-caseating epithelioid cell granuloma.^{3,12} The main manifestations of both diseases are in the lungs, in association with systemic symptoms such as fever, malaise, anorexia, and weight loss, and commonly affect the same organs. Musculoskeletal involvement is a well-known manifestation of both diseases, with peripheral arthritis found in up to 5% of patients with TB and up to 21% of patients with sarcoidosis.¹² While cardiac manifestation of sarcoidosis is seen with a prevalence of ~5%, tubercular involvement is more rare.^{2,5} Given the similar appearance of myocardial FDG uptake in sarcoidosis and TB by PET imaging, as seen in our patient, a detailed medical history and histological correlation are essential for differentiating tuberculous myocarditis and sarcoidosis. As per the current diagnostic criteria based on the modified Japanese

Ministry of Health and Welfare guidelines published in 2006 and the Heart Rhythm Society consensus statement published in 2014, the diagnosis of cardiac sarcoidosis involves either a histological demonstration of endomyocardial biopsy or integration of relevant clinical and imaging features.^{13,14} Since biopsy is not commonly done in view of the risks involved and lack of sensitivity (19% sensitivity) owing to the patchy involvement of myocardium, advanced imaging modalities such as CMR and FDG PET-CT have emerged as important tools to improve the diagnostic certainty and management of cardiac sarcoidosis.^{13,14} Both imaging modalities have been found to be complementary.¹³

The ability to detect changes in metabolic uptake makes ^{18}F -FDG PET-CT a specific complementary tool to structural imaging,^{14–17} wherein each test evaluates different aspects of the pathobiology of cardiac sarcoidosis that are relevant in clinical decision making. The cellular uptake of ^{18}F -FDG in sarcoidosis/tuberculosis is related to the presence of inflammatory cell infiltrates exhibiting high glycolytic activity.^{14–16} The differential increase in tissue glycolysis in inflamed tissues, as opposed to normal cells, forms the pathophysiological basis for the use of ^{18}F -FDG PET-CT in inflammatory/infective disease processes.¹⁵ Integrating both techniques can, therefore, enhance diagnostic certainty in the absence of late gadolinium enhancement of CMR excluding the disease in most patients and increase ^{18}F -FDG uptake on PET-CT indicating the presence and extent of myocardial inflammation.^{15–17} The CMR and ^{18}F -FDG PET-CT findings in the case described were concordant with the abnormal enhancement and increased FDG uptake noted in the same segments of LV myocardium, with no hypoperfusion in the abnormal segments. The complementary value of CMR and PET has been evaluated in 111 consecutive patients, which revealed that the addition of PET information to CMR leads to reclassification of subjects with a higher or lower likelihood of cardiac sarcoidosis in ~45% of patients. About 11% were reclassified as having highly probable, that is, having greater than 90% likelihood of sarcoidosis. Those having both late gadolinium enhancement and FDG uptake yielded an even higher likelihood of CS and identified candidates suitable for immunosuppressive therapies.¹³ The authors, therefore, inferred that individuals who are most

likely to benefit from PET after CMR include the following groups: (1) equivocal or negative CMR findings in the setting of high clinical suspicion; (2) CMR findings with highly probable cardiac sarcoidosis, wherein ^{18}F -FDG PET-CT could serve to identify the inflammation and guide potential role for immunosuppressive therapies.¹³ Conversely, CMR after an inconclusive PET may be helpful in cases when there is diffuse FDG uptake involving the myocardium, which could be because of incomplete suppression of FDG in the normal myocardium rather than diffuse inflammation.

Typical radionuclide protocols for imaging cardiac sarcoidosis include ^{18}F -FDG PET-CT combined with myocardial perfusion imaging (SPECT or PET), wherein preprocedural high fat/high protein and no/very low carbohydrate diet for 18 to 24 hours with 12 hours of overnight fasting prior to the study followed by the intravenous administration of unfractionated heparin (50 units/kg) 15 minutes prior to FDG injection facilitates the complete suppression of physiological myocardial FDG uptake.^{14,15} Cardiac involvement of the disease is represented by increased FDG uptake in isolated segments or a patchy distribution representing inflammation. While a concurrent rest myocardial perfusion study can increase the diagnostic confidence of cardiac sarcoidosis, the perfusion may remain normal as was seen in our patient or even increased instead of decreased perfusion as reported in other studies.^{14,16,17}

In patients being evaluated for the diagnosis of infiltrative cardiomyopathy, other differentials of tuberculous and viral myocarditis should also be included apart from cardiac sarcoidosis in patients showing heterogeneous FDG uptake on PET imaging, particularly in developing countries such as India where there is high prevalence of TB.

PET-CT in such cases allows additional whole-body imaging to identify the extent of disease in patients with EPTB. Considering the risks involved and nonfeasibility of taking endomyocardial biopsy, whole-body PET most importantly helps to detect any tubercular lymphadenopathy or lesion to select the most accessible lesion for biopsy. Apart from assisting in the selection of the site for biopsy, PET-CT may also play a significant role in monitoring the response to treatment.¹⁴⁻¹⁸

Given the similar appearance of myocardial FDG uptake in both sarcoidosis and TB on PET imaging, the diagnosis of cardiac TB in the above-described case was based on the histopathology of the lymph nodes and a negative serum ACE level. A detailed clinical history and histologic correlation are therefore essential for differentiating tuberculous myocarditis from sarcoidosis. It has also been observed as reported in previous studies that both sarcoidosis and TB can coexist,^{19,20} causing diagnostic dilemma and the presence of both disease conditions in the same patient does not exclude each other and need to be considered. At the time of writing this case report, antitubercular treatment had been initiated and the importance of follow-up imaging has been explained to monitor treatment response.

Conclusion

This case highlights that cardiac TB, although rare, should be included in the differential diagnosis of patients showing

heterogeneous FDG uptake in the myocardium on PET study performed for the diagnosis of infiltrative cardiomyopathy, particularly in TB endemic regions. Whole-body FDG PET further helps in defining the extent of disease involvement, particularly in detecting lymphadenopathy and guides biopsy from the most accessible lesion.

Declaration of Patient Consent

The authors certify that they have obtained all appropriate patient consent forms. In the form, the patients have given their consent for their images and other clinical information to be reported in the journal. The patients understand that their names and initials will not be published and due efforts will be made to conceal their identity, but anonymity cannot be guaranteed.

Financial Support and Sponsorship

Nil.

Conflicts of Interest

There are no conflicts of interest.

References

- Mortaz E, Masjedi MR, Matroodi S, et al. Concomitant patterns of tuberculosis and sarcoidosis. *Tanaffos* 2013;12(04):6-9
- Rose AG. Cardiac tuberculosis. A study of 19 patients. *Arch Pathol Lab Med* 1987;111(05):422-426
- Badar F, Azfar SF, Ahmad I, Yasmeen S, Kirmani S. Diagnostic difficulties in differentiating sarcoidosis from tuberculosis. *Oman Med J* 2011;26(03):210-211
- Orii M, Imanishi T, Akasaka T. Assessment of cardiac sarcoidosis with advanced imaging modalities. *BioMed Res Int* 2014;2014:897956
- Cowley A, Dobson L, Kurian J, Saunderson C. Acute myocarditis secondary to cardiac tuberculosis: a case report. *Echo Res Pract* 2017;4(03):K25-K29
- Chan AC, Dickens P. Tuberculous myocarditis presenting as sudden cardiac death. *Forensic Sci Int* 1992;57(01):45-50
- Khurana R, Shalhoub J, Verma A, et al. Tubercular myocarditis presenting with ventricular tachycardia. *Nat Clin Pract Cardiovasc Med* 2008;5(03):169-174
- Gupta PR. Difficulties in managing lymph node tuberculosis. *Lung India* 2004;21:50-53
- Fazal-I-wahid, Habib-Ur-Rehman, Ahmad I. Extrapulmonary tuberculosis in patients with cervical lymphadenopathy. *J Pak Med Assoc* 2013;63(09):1094-1097
- Mert A, Tabak F, Ozaras R, Tahan V, Oztürk R, Aktuğlu Y. Tuberculous lymphadenopathy in adults: a review of 35 cases. *Acta Chir Belg* 2002;102(02):118-121
- Soejima K, Yada H. The work-up and management of patients with apparent or subclinical cardiac sarcoidosis: with emphasis on the associated heart rhythm abnormalities. *J Cardiovasc Electrophysiol* 2009;20(05):578-583
- Diagnostic standard and guidelines for sarcoidosis. *Jpn J Sarcoidosis Granulomatous Disord* 2007;27:89-102
- Vita T, Okada DR, Veillet-Chowdhury M, et al. Complementary value of cardiac magnetic resonance imaging and positron emission tomography/computed tomography in the assessment of cardiac sarcoidosis. *Circ Cardiovasc Imaging* 2018;11(01):e007030
- Brudin LH, Valind S-O, Rhodes CG, et al. Fluorine-18 deoxyglucose uptake in sarcoidosis measured with positron emission tomography. *Eur J Nucl Med* 1994;21(04):297-305

- 15 Kung BT, Seraj SM, Zadeh MZ, et al. An update on the role of ¹⁸F-FDG-PET/CT in major infectious and inflammatory diseases. *Am J Nucl Med Mol Imaging* 2019;9(06):255–273
- 16 Skali H, Schulman AR, Dorbala S. ¹⁸F-FDG PET/CT for the assessment of myocardial sarcoidosis. *Curr Cardiol Rep* 2013;15(04):352
- 17 Hulten E, Aslam S, Osborne M, Abbasi S, Bittencourt MS, Blankstein R. Cardiac sarcoidosis—state of the art review. *Cardiovasc Diagn Ther* 2016;6(01):50–63
- 18 Yu W-Y, Lu P-X, Assadi M, et al. Updates on ¹⁸F-FDG-PET/CT as a clinical tool for tuberculosis evaluation and therapeutic monitoring. *Quant Imaging Med Surg* 2019;9(06):1132–1146
- 19 Mandal SK, Ghosh S, Mondal SS, Chatterjee S. Coexistence of pulmonary tuberculosis and sarcoidosis: a diagnostic dilemma. *BMJ Case Rep* 2014;2014:bcr2014206016. Doi: 10.1136/bcr-2014-206016
- 20 Litinsky I, Elkayam O, Flusser G, Segal R, Yaron M, Caspi D. Sarcoidosis: TB or not TB? *Ann Rheum Dis* 2002;61(05):385–386