

Evaluation of a new slim radial echoendoscope: A better option for an aging population

Pietro Fusaroli, Marta Serrani, Andrea Lisotti

Department of Medical and Surgical Sciences, GI Unit, Hospital of Imola, University of Bologna, Bologna, Italy

ABSTRACT

Background and Objectives: The radial echoendoscope is still widely used for the investigation of abnormalities in the gastrointestinal wall and for stone detection in the extrahepatic biliary tree. Due to aging patient population, EUS is frequently performed in fragile and elderly individuals. We aimed to compare the maneuverability and image quality of a new thin radial echoendoscope to the current one. **Patients and Methods:** This evaluation was conducted at a referral academic EUS center. The new radial echoendoscope has a thinner shaft and distal tube and a shorter bending section compared to the previous one. Patients referred for diagnostic EUS with a radial echoendoscope were enrolled. Indications included pancreaticobiliary disease, esophagogastric abnormalities, and neoplasms and rectal cancer staging. **Results:** We enrolled 177 patients (122 pancreaticobiliary, 48 esophagogastric, and 7 rectal cases). Overall, the new echoendoscope performed better than the previous model in terms of maneuverability during esophageal intubation and transition from the duodenal bulb to the second portion. On the other hand, pylorus traversing was comparable to the current radial echoendoscope. No loss in image quality was appreciated at predefined stations (esophagus, stomach, and duodenum) compared to the current model. On the other hand, image penetration depth in tissue harmonic mode was significantly improved with the new echoendoscope. **Conclusions:** A new thinner radial echoendoscope showed improved maneuverability compared to the existing version. Image quality was also improved thanks to increased penetration depth in the tissue harmonic mode. We speculate that this new echoendoscope may allow for safer and faster EUS examination, which may prove useful in an aging patient population.

Key words: Bending section, EUS, image quality, procedure safety, radial echoendoscope

INTRODUCTION

EUS has been used for decades for the diagnosis and staging of gastrointestinal and pancreaticobiliary neoplasms, along with benign conditions such as common bile duct stones.^[1]

The radial echoendoscope was first introduced to the market in the early 80s by Olympus (Olympus Corp., Tokyo, Japan). At that time, EUS was mainly used for investigation of the gastric wall,

This is an open access journal, and articles are distributed under the terms of the Creative Commons Attribution-NonCommercial-ShareAlike 4.0 License, which allows others to remix, tweak, and build upon the work non-commercially, as long as appropriate credit is given and the new creations are licensed under the identical terms.

For reprints contact: reprints@medknow.com

How to cite this article: Fusaroli P, Serrani M, Lisotti A. Evaluation of a new slim radial echoendoscope: A better option for an aging population. *Endosc Ultrasound* 2019;8:329-33.

Access this article online	
Quick Response Code: 	Website: www.eusjournal.com
	DOI: 10.4103/eus.eus_3_19

Address for correspondence

Prof. Pietro Fusaroli, GI Unit, Hospital of Imola, University of Bologna, Via Montericco 4, 40026 Imola, Bologna, Italy.

E-mail: pietro.fusaroli@unibo.it

Received: 2018-08-02; **Accepted:** 2018-09-30; **Published online:** 2019-03-12

portal hypertension, pancreatic parenchyma, and biliary tree.^[2-7]

In the early 90s, the innovative linear echoendoscope by Pentax (Pentax Corp., Tokyo, Japan) allowed the performance of the first EUS-guided fine-needle aspiration.^[8,9] In subsequent years, linear echoendoscopes gained increasing popularity over radial ones due to the wide demand for tissue acquisition and to the advent of several EUS-guided interventions.^[10-15] More recently, a third type of instrument was invented, namely the forward view echoendoscope, allowing further therapeutic interventions in areas of the gastrointestinal tract that are not easily accessible with the oblique-viewing linear echoendoscope.^[16,17]

Nevertheless, in all these years, the radial echoendoscope has not become obsolete as it renders complete and straightforward imaging of abnormalities in the gastrointestinal wall and the common bile duct. Many experts claim that the radial echoendoscope cannot be lacking in EUS centers as it allows complementing the linear echoendoscope for a thorough anatomical investigation.^[18-26] When common bile duct exploration is the main indication to detect biliary stones, the radial echoendoscope grants a swift and accurate examination.^[27,28]

Echoendoscopes are the most difficult endoscopes to maneuver as they are thicker and more rigid than their optical-only counterparts. With aging population, certain areas of the gastrointestinal tract may become more difficult to traverse with echoendoscopes due to increased tissue fragility. For this reason, slimmer and less rigid instruments are advocated.

We aimed to evaluate the thin Olympus radial echoendoscope GF-Y0016-UE in a standard clinical setting according to several indications. In particular, maneuverability and EUS images were analyzed and compared to the standard Olympus radial echoendoscope GF-UE160-AL5 that is currently available.

PATIENTS AND METHODS

Our institution is an academic referral EUS center in Northern Italy, at the University of Bologna in Imola. We perform an average of 600 EUS examinations per year, including all major types of diagnostic and therapeutic procedures.

We evaluated the Olympus radial GF-Y0016-UE (Olympus Corp., Tokyo, Japan) during the second half of 2017. When compared to the GF-UE160-AL5, the insertion tube and the distal end diameter of the new echoendoscope are thinner and the bending section is shorter [Table 1 and Figure 1].

Every patient referred for diagnostic EUS with a radial echoendoscope was enrolled in this retrospective analysis of a prospectively maintained database. EUS examinations were performed on patients lying on their left lateral decubitus and with conscious sedation using fentanyl and midazolam. All patients signed informed consent to grant permission to evaluate their data for anonymous research purposes. We did not consult with the institutional review board in view of the retrospective nature of the study.

The echoendoscopes' maneuverability and image quality were analyzed and compared to a similar cohort of

Table 1. Comparison between standard and new radial echoendoscope

	GF-Y0016-UE	GF-UE160-AL5
Optical system		
Field of view	100°	100°
Direction of view	50° forward oblique	55° forward oblique
Outer diameter (mm)		
Distal end	Φ13.4	Φ13.8
Insertion tube	Φ10.9	Φ11.8
Channel inner diameter (mm)	Φ2.2	Φ2.2
Working length (mm)	1250	1250
Angulation range	U: 130° D/R/L: 90°	U: 130° D/R/L: 90°
Ultrasound scanning range	360°	360°
Balloon function	Yes	Yes
Ultrasound cable	Detachable	Nondetachable



Figure 1. Head-to-head comparison of the new GF-Y0016-UE (right) with the GF-UE160-AL5 (left). Notice the shorter bending section of the new echoendoscope

patients who had undergone EUS with the standard radial echoendoscope during the first half of 2017.

All the procedures were performed by one of three experienced operators (PF, AL, and MS). Before starting enrollment, all endoscopists met to find an agreement related to the study standards of care and definitions.

Echoendoscope maneuverability was evaluated at three levels: intubation of cervical esophagus, traversing of the pylorus, and transition from the first to the second duodenal portion. In case of rectal examinations, ease of passage of the rectosigmoid junction was also evaluated. All the maneuvers were analyzed according to a qualitative scale using the standard radial echoendoscope as a reference (superior to/equal to/inferior to).

Image quality was assessed at four standard stations (second part of the duodenum, duodenal bulb, stomach, and esophagus) and recorded as excellent/good/fair and compared to the standard echoendoscope as well. Excellent was defined as a clean EUS view of the target organ with an adequate resolution; good was defined as a minimal loss in image resolution, but still adequate for the diagnosis; fair was defined as a significant loss in image quality, barely adequate for the diagnosis.

RESULTS

We enrolled 177 patients during the study period. According to the indications, 122 patients underwent EUS for pancreaticobiliary examination, 48 patients were referred for esophagogastric abnormalities, and seven patients for rectal cancer staging.

Detailed results are shown in Table 2. In brief, overall imaging quality of the new echoendoscope was rated excellent in the majority of cases. In particular, image penetration depth in tissue harmonic enhancement of

the GF-Y0016-UE was greater than that obtained with the standard echoendoscope thanks to its blending with B-mode imaging in the deep scanning areas.

While the maneuverability of the GF-Y0016-UE was deemed equivalent to the standard echoendoscope for traversing the pylorus, esophageal intubation and passage from the first to the second duodenal portion were rated easier with the new echoendoscope than with the standard one [Table 3]. Similarly, passage from the rectum to the sigmoid colon was also considered easier with the new model compared to the previous one.

All the patients tolerated well the procedures under conscious sedation with a mean dose of 100 mcg of fentanyl and 2.5 mg of midazolam. No adverse events occurred during the study period.

DISCUSSION

We evaluated a new radial echoendoscope that is thinner and has a shorter bending section compared to the previous model. We showed that the maneuverability of the new echoendoscope was improved at certain critical steps of EUS examination, such as esophageal intubation and passage from the duodenal bulb to the second portion.

On the other hand, image quality was not inferior to the preexisting model and was considered superior in the tissue harmonic enhancement mode thanks to the increased penetration depth.

The radial echoendoscope has represented the mainstay of EUS examinations for at least two decades after its introduction to the market. All the earliest publications and meetings dealt with radial examination for the staging of esophagogastric cancer and lymphoma, portal hypertension assessment, and differential diagnosis of submucosal tumors [Figures 2 and 3]. Subsequently,

Table 2. Patients population and imaging results

Indication	# Cases; M/F; median age	EUS diagnosis	Overall imaging quality	Image artifacts
Pancreaticobiliary	122; 60/62; 67 (range 22-89)	40 CBD stones	98% excellent 2% good	2% minor air artifacts
		54 Normal findings	100% excellent	none
		28 Neoplasms	95% excellent 5% good	5% minor air artifacts
Esophagogastric	48; 23/25; 67.5 (range 44-88)	5 Esophageal cancer	100% excellent	none
		15 Normal findings	100% excellent	none
		16 SMTs	100% excellent	none
Rectal	7; 3/4; 66 (range 55-78)	7 Rectal cancer	95% excellent 5% good	5% minor air artifacts

M/F: Male/Female; CBD: Common bile duct; SMTs: Submucosal tumors

Table 3. Maneuverability of the GF-Y0016-UE

Comparison with GF-UE160-AL5	Esophageal intubation (%)	Pylorus traversing (%)	Duodenal transition (%)
Superior to	140/177 (79)	20/177 (11)	132/177 (75)
Equal to	37/177 (21)	157/177 (89)	45/177 (25)
Inferior to	0/177	0/177	0/177

EUS exploration of the common bile duct for stones detection emerged as the main indication for radial imaging.

Radial EUS is still considered a powerful diagnostic tool at major referral centers as it allows for quick and accurate exploration of the extrahepatic biliary tree and is a useful complement to linear EUS in difficult pancreaticobiliary cases. Moreover, it is optimal for the staging of esophageal, gastric, and rectal cancer.

However, the radial echoendoscope is stiff and rigid and is regarded as the most difficult endoscope to maneuver through the gastrointestinal tract. For this reason, a thinner echoendoscope would be desirable in an aging patient population who is more fragile and potentially more exposed to adverse events. In theory, the improved maneuverability of the new echoendoscope could allow for safer examinations and better patient tolerance. Therefore, the need for patient sedation could be diminished thereby limiting the risk of drug-related adverse events.

The improved penetration depth of tissue harmonic was of particular interest. The smaller penetration depth of the radial echoendoscope has been considered its main limitation when compared to the linear one. Tissue harmonic enhancement allows for improved EUS imaging as it emphasizes the boundaries between structures and lesions with different acoustic impedance. The better acoustical properties of the GF-Y0016-UE under evaluation could represent a useful tool to improve the diagnostic and staging accuracy [Figure 4].

As far as rectal cancer staging was concerned, we found it easier to reach the sigmoid colon with the GF-Y0016-UE than with the GF-UE160-AL5. Visualization through the sigmoid is essential for iliac lymph nodes detection to perform a complete locoregional staging. We also noticed that overall endoscopic exploration and the visualization of the papilla of Vater had improved thanks to the greater maneuverability of the echoendoscope, thereby potentially reducing the need for resorting to esophagogastroduodenoscopy before EUS.



Figure 2. Among the earliest publications in EUS were reports about the gastrointestinal wall layer structure




Figure 3. Proceedings of some of the earliest international meetings in EUS

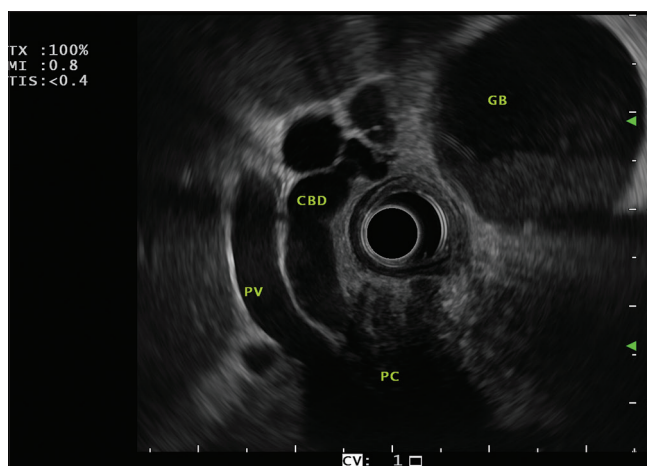


Figure 4. A typical image obtained with the new radial echoendoscope. Pancreatic head cancer (PC) is shown infiltrating the common bile duct (CBD) and the portal vein (PV). The gallbladder (GB) is dilated and contains sludge

Our study has several limitations. First, due to its retrospective design, it is open to inherent methodological flaws and inaccurate data collection. However, we arranged a structured database to gather all relevant study information and images. In addition, the analysis of the echoendoscope's maneuverability and image quality was subjective and prone to evaluation bias, although it was performed by experienced endosonographers with longstanding experience of EUS examination using the radial echoendoscope.

CONCLUSION

We tested the GF-Y0016-UE radial echoendoscope in a group of patients with pancreaticobiliary, esophagogastric, and rectal indications. Compared to the previous radial echoendoscope, the new model has a thinner shaft and distal tube and a shorter bending section. The new echoendoscope showed improved maneuverability particularly during some critical examination steps such as esophageal intubation and transition from the duodenal bulb to the second portion. Moreover, image quality was improved thanks to increased penetration depth in the tissue harmonic mode. We speculate that this new echoendoscope may allow for safer and faster EUS examination that is advantageous in an aging patient population, which is more fragile and exposed to adverse events.

Financial support and sponsorship

Nil.

Conflicts of interest

Olympus Corp. loaned us the echoendoscope that was used for this study.

REFERENCES

- Palazzo L. How to perform EUS in the pancreaticobiliary area. *Minerva Med* 2014;105:371-89.
- Dimagno EP, Regan PT, Clain JE, *et al.* Human endoscopic ultrasonography. *Gastroenterology* 1982;83:824-9.
- Caletti G, Bolondi L, Labò G. Ultrasonic endoscopy – The gastrointestinal wall. *Scand J Gastroenterol Suppl* 1984;102:5-8.
- Caletti G, Bolondi L, Labò G. Anatomical aspects in ultrasonic endoscopy for the stomach. *Scand J Gastroenterol Suppl* 1984;94:34-42.
- Caletti GC, Lorena Z, Bolondi L, *et al.* Impact of endoscopic ultrasonography on diagnosis and treatment of primary gastric lymphoma. *Surgery* 1988;103:315-20.
- Caletti G, Brocchi E, Zani L, *et al.* The important role of EUS in the assessment of patients with portal hypertension. *Gastrointest Endosc* 1988;34:154-5.
- Tio LT, Blank LE, Wijers OB, *et al.* Staging and prognosis using endosonography in patients with inoperable esophageal carcinoma treated with combined intraluminal and external irradiation. *Gastrointest Endosc* 1994;40:304-10.
- Vilmann P, Jacobsen GK, Henriksen FW, *et al.* Endoscopic ultrasonography with guided fine needle aspiration biopsy in pancreatic disease. *Gastrointest Endosc* 1992;38:172-3.
- Vilmann P, Hancke S, Henriksen FW, *et al.* Endoscopic ultrasonography-guided fine-needle aspiration biopsy of lesions in the upper gastrointestinal tract. *Gastrointest Endosc* 1995;41:230-5.
- Wiersema MJ, Wiersema LM. Endosonography-guided celiac plexus neurolysis. *Gastrointest Endosc* 1996;44:656-62.
- Wiersema MJ. Endosonography-guided cystoduodenostomy with a therapeutic ultrasound endoscope. *Gastrointest Endosc* 1996;44:614-7.
- Wiersema MJ, Sandusky D, Carr R, *et al.* Endosonography-guided cholangiopancreatography. *Gastrointest Endosc* 1996;43:102-6.
- Ashida R, Arisaka Y, Masuda D, *et al.* The role of linear array EUS for diagnosis of pancreatic malignancies in the current situation. *Dig Endosc* 2011;23 Suppl 1:12-6.
- Cazacu IM, Luzuriaga Chavez AA, Saftoiu A, *et al.* A quarter century of EUS-FNA: Progress, milestones, and future directions. *Endosc Ultrasound* 2018;7:141-60.
- Rimbaş M, Crino SF, Gasbarrini A, *et al.* EUS-guided fine-needle tissue acquisition for solid pancreatic lesions: Finally moving from fine-needle aspiration to fine-needle biopsy? *Endosc Ultrasound* 2018;7:137-40.
- Fusaroli P, Ceroni L, Caletti G. Forward-view endoscopic ultrasound: A systematic review of diagnostic and therapeutic applications. *Endosc Ultrasound* 2013;2:64-70.
- Fusaroli P, Serrani M, Lisotti A, *et al.* Performance of the forward-view echoendoscope for pancreaticobiliary examination in patients with status post-upper gastrointestinal surgery. *Endosc Ultrasound* 2015;4:336-41.
- Irisawa A. Current role of radial and curved-linear arrayed EUS scopes for diagnosis of pancreatic abnormalities in Japan. *Dig Endosc* 2011;23 Suppl 1:9-11.
- Colaiácovo R, Assef MS, Ganc RL, *et al.* Rectal cancer staging: Correlation between the evaluation with radial echoendoscope and rigid linear probe. *Endosc Ultrasound* 2014;3:161-6.
- ASGE Technology Committee, Murad FM, Komanduri S, *et al.* Echoendoscopes. *Gastrointest Endosc* 2015;82:189-202.
- Stevens T, Zuccaro G Jr., Dumot JA, *et al.* Prospective comparison of radial and linear endoscopic ultrasound for diagnosis of chronic pancreatitis. *Endoscopy* 2009;41:836-41.
- Kanazawa K, Imazu H, Mori N, *et al.* A comparison of electronic radial and curvilinear endoscopic ultrasonography in the detection of pancreatic malignant tumor. *Scand J Gastroenterol* 2012;47:1313-20.
- Shin EJ, Topazian M, Goggins MG, *et al.* Linear-array EUS improves detection of pancreatic lesions in high-risk individuals: A randomized tandem study. *Gastrointest Endosc* 2015;82:812-8.
- Lisotti A, Serrani M, Caletti G, *et al.* EUS liver assessment using contrast agents and elastography. *Endosc Ultrasound* 2018;7:252-6.
- Wang Y, Chai N, Feng J, *et al.* A prospective study of endoscopic ultrasonography features, cyst fluid carcinoembryonic antigen, and fluid cytology for the differentiation of small pancreatic cystic neoplasms. *Endosc Ultrasound* 2018;7:335-42.
- Dong Y, D'Onofrio M, Hocke M, *et al.* Autoimmune pancreatitis: Imaging features. *Endosc Ultrasound* 2018;7:196-203.
- Amouyal P, Amouyal G, Lévy P, *et al.* Diagnosis of choledocholithiasis by endoscopic ultrasonography. *Gastroenterology* 1994;106:1062-7.
- Kaneko M, Katanuma A, Maguchi H, *et al.* Prospective, randomized, comparative study of delineation capability of radial scanning and curved linear array endoscopic ultrasound for the pancreaticobiliary region. *Endosc Int Open* 2014;2:E160-70.