

## Research Article

# Williams-Beuren Syndrome: A Clinical Study of 55 Brazilian Patients and the Diagnostic Use of MLPA

Rachel Sayuri Honjo,<sup>1</sup> Roberta Lelis Dutra,<sup>2</sup> Erika Arai Furusawa,<sup>3</sup>  
Evelin Aline Zanardo,<sup>2</sup> Larissa Sampaio de Athayde Costa,<sup>1</sup> Leslie Domenici Kulikowski,<sup>2</sup>  
Debora Romeo Bertola,<sup>1</sup> and Chong Ae Kim<sup>1</sup>

<sup>1</sup>Clinical Genetics Unit, Instituto da Criança, Hospital das Clínicas, Faculdade de Medicina, Universidade de São Paulo, 05403-000 São Paulo, SP, Brazil

<sup>2</sup>Department of Pathology, Laboratório de Citogenômica, LIM 03, Hospital das Clínicas, Faculdade de Medicina, Universidade de São Paulo, 05403-000 São Paulo, SP, Brazil

<sup>3</sup>Department of Nephrology, Instituto da Criança, Hospital das Clínicas, Faculdade de Medicina, Universidade de São Paulo, 05403-000 São Paulo, SP, Brazil

Correspondence should be addressed to Rachel Sayuri Honjo; [rachel.honjo@gmail.com](mailto:rachel.honjo@gmail.com)

Received 7 October 2014; Accepted 24 December 2014

Academic Editor: Yi Guo

Copyright © 2015 Rachel Sayuri Honjo et al. This is an open access article distributed under the Creative Commons Attribution License, which permits unrestricted use, distribution, and reproduction in any medium, provided the original work is properly cited.

Williams-Beuren syndrome (WBS) is a genetic disease caused by a microdeletion in the 7q11.23 region. It is characterized by congenital heart disease, mainly supravalvular aortic stenosis, mental retardation, mild short stature, facial dysmorphisms, and variable abnormalities in different systems. *Objectives.* To report the clinical findings of 55 Brazilian patients confirmed by multiplex ligation-dependent probe amplification (MLPA). *Methods.* Patients were followed up for 4 years at the Genetics Unit of the Instituto da Criança of the Hospital das Clínicas, FMUSP, Brazil. A kit specific for WBS was used to detect the 7q11.23 microdeletion. *Results.* Two patients with negative FISH results had positive MLPA results for WBS. The characteristics of the patients with the deletion were as follows: typical WBS facies (98.2%), neuropsychomotor delay (98.2%), hypersocial behavior (94.5%), hyperacusis (94.5%), and congenital heart disease (81.8%). *Conclusions.* MLPA was effective in detecting the microdeletion in the 7q11.23 region to confirm the diagnosis of WBS. MLPA was also able to confirm the diagnosis of WBS in two patients with typical clinical characteristics but negative FISH results. Thus, MLPA is a promising method in the diagnostic investigation of WBS. WBS is a multisystemic disorder and therefore requires multidisciplinary care and specific follow-up to prevent complications.

## 1. Introduction

Williams-Beuren syndrome (WBS) is a genetic multisystemic disease characterized by congenital heart disease, mainly supravalvular aortic stenosis (SVAS), mental retardation, mild short stature, facial dysmorphisms, and variable abnormalities in the genitourinary, endocrinological, ophthalmological, and skeletal systems [1, 2]. The incidence is estimated to be 1 in 20,000 live births [3], but some authors report a prevalence of approximately 1 in 7,500 [4].

The typical facial dysmorphisms found in WBS are as follows: high forehead, medial broadening of the eyebrows, periorbital fullness, depressed nasal bridge, malar hypoplasia,

thick lips, and long nasolabial philtrum [1, 2, 5]. Short stature is common [6] but not severe.

Several studies report that patients with WBS have unique cognitive and behavioral profiles, with characteristic dissociations among different domains, such as better skills in language and deficits in motor and visuospatial activities [7–9]. Patients also have characteristic hypersocial behavior, even with strangers [10, 11].

WBS is caused by a 1-2 Mb microdeletion in 7q11.23, a region that contains 28 genes [12]. Approximately 90% of WBS patients have a 1.55 Mb microdeletion and 8% have a 1.84 Mb microdeletion. These are considered “typical” WBS microdeletions. Microdeletions larger than 1.84 Mb or

smaller than 1.55 Mb are termed “atypical,” are often associated with atypical clinical manifestations, and occur in only 2% of cases [13]. The recognition and description of these cases have been very helpful for genotype-phenotype correlation studies. Whether the parental origin of the microdeletion has any impact on the phenotype of the patient remains under debate [14–16].

WBS is generally sporadic [16–18], is caused by de novo deletions, and has a recurrence risk lower than 5% [19–21]. A few cases of vertical transmission have been reported [12, 22–24]. People with microinversions of 1.5–1.9 Mb in the WBS critical region are predisposed to having children with WBS [25–27].

The chromosomal region 7q11.23 comprises a region of approximately 1.2 Mb of single copy genes and three blocks of low copy repeat sequences. Due to the high similarity of those blocks, nonallelic homologous recombination is possible and can result in microdeletion or microduplication within the region [12, 16, 28].

Although individuals with WBS present with a highly characteristic phenotypic profile, the diagnosis of WBS is often confirmed by molecular testing. Currently, the microdeletion in the 7q11.23 region can be detected by several methods, including fluorescence in situ hybridization (FISH), polymorphic microsatellite markers, chromosomal microarray analysis (CMA), and *multiplex ligation-dependent probe amplification* (MLPA).

Some studies have shown that MLPA is an alternative to FISH, which is the current gold-standard method for diagnosing WBS. Cho et al. [29] found concordant results in four patients using both techniques.

Here, we report the clinical findings of 55 Brazilian patients with WBS confirmed by MLPA.

## 2. Methods

The patients were evaluated at the Genetics Unit of the Instituto da Criança of the Hospital das Clínicas da Faculdade de Medicina da Universidade de São Paulo (ICr, HCFMUSP), São Paulo, Brazil. The study was approved by the local Ethics Board, and informed consent form was obtained from all families. All patients were evaluated and followed up by a single examiner over a period of 4 years (2008–2011). Clinical and laboratory data were collected following a protocol that included the following: anamnesis, physical examination, cardiovascular assessment (arterial pressure and echocardiogram), urinary tract evaluation (renal ultrasonogram, BUN, and creatinine), plasmatic and urinary calcium, thyroid function tests, and referral to specialists for baseline and/or follow-up evaluations (ophthalmology, cardiology, nephrology, psychiatry, and endocrinology, among others).

DNA was extracted from peripheral blood by the salting-out method [30]. MLPA analyses were performed using kit P029 from MRC Holland (Amsterdam, Netherlands), following the manufacturer’s instructions. This kit contained probes of genes mapped to the WBS critical region (*ELN*, *CLIP2*, *LIMK1*, *TBL2*, *STX1A*, *RFC2*, *FZD9*, and *FKBP6*) and controls. Data were analyzed using the GeneMarker software.

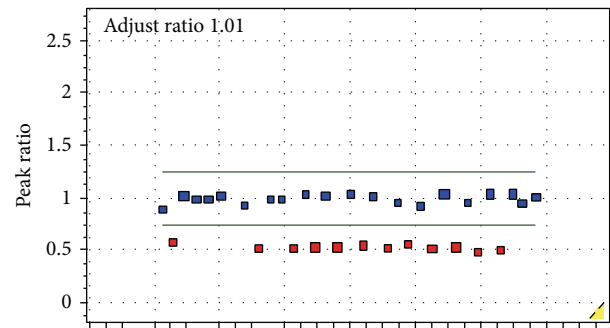


FIGURE 1: MLPA showing deletion of the probes in the 7q11.23 region (red squares).

## 3. Results

Fifty-five patients (34 males and 21 females) with clinical diagnoses of WBS were evaluated. The age at diagnosis ranged from 2 to 30 years old (median = 14 years). MLPA confirmed the microdeletion in 7q11.23 (Figure 1).

FISH results were available for 18 of the 55 patients; the results were positive for all but two. MLPA confirmed the diagnosis in these two patients. The first patient was a girl (Figure 2(a)), born at term, after an uneventful pregnancy except for the use of penicillin by the mother in the 2nd month. The mother had had one previous spontaneous abortion and had another child with autism. The patient was born by cesarean section due to fetal bradycardia, with 2620 g and 47 cm. She had meningitis within 21 days and presented with neuromotor development delay (sat after 8 months, walked at 2 years of age, and spoke first words at 5 years). The patient has typical WBS behavior and facies, as seen in Figure 2, besides constipation, scoliosis, enuresis, precocious puberty, and mental retardation. Pituitary microadenoma was diagnosed at 11 years of age. The second patient (Figure 2(b)) was a boy, born at term, cyanotic, with no available information regarding weight and height at birth. He had neuromotor development delay (sat at 2 years, walked at 3 years, and spoke at 2 years of age) and showed typical WBS facies and behaviour, hypothyroidism, unilateral radioulnar synostosis, and bladder diverticulum.

The most prevalent clinical characteristics of the 55 patients are shown in Table 1. These included typical WBS facies (98.2%), developmental delay (98.2%), hypersocial behavior (94.5%), hyperacusis (94.5%), and congenital heart disease (81.2%).

Congenital heart disease was present in 45/55 patients, and SVAS was the most prevalent type (19/45 or 42.2% of the cases). Isolated SVAS was present in 12 patients; SVAS was associated with other cardiac anomalies in 7 patients. Three patients had echocardiogram reports of aortic stenosis, but it was not supravalvular. Pulmonary stenosis was the second most frequent abnormality, detected in 12/45 (26.7%) of the patients. Other cardiac anomalies were found in the other patients (14/45), either in isolation or in combination, as follows: mitral valve prolapse, aortic coarctation, pulmonary artery stenosis, interatrial septal defect, ventricular septal

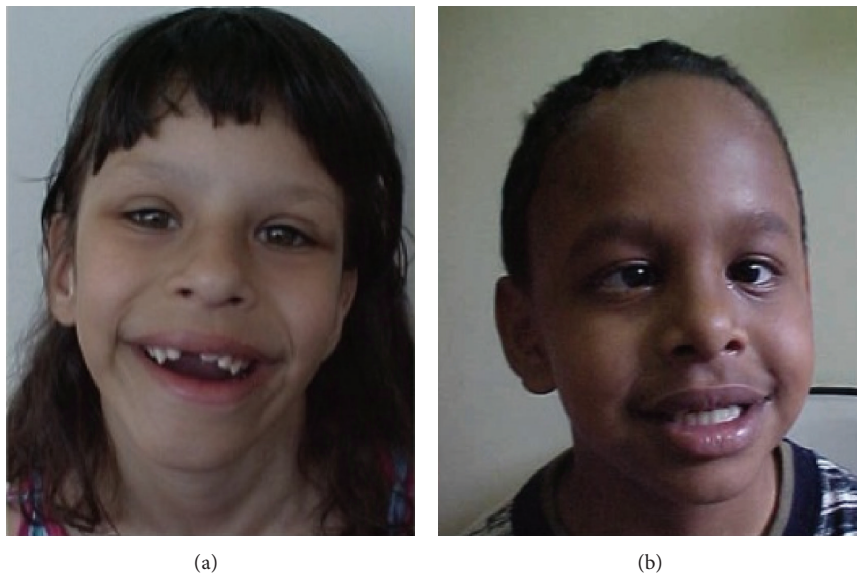


FIGURE 2: Patients with positive MLPA but negative FISH results for WBS.

TABLE 1: Clinical characteristics of WBS patients.

Clinical characteristic	<i>n</i>	%
Typical WBS facies*	54/55	98.2
Developmental delay	54/55	98.2
Hypersocial behavior	52/55	94.5
Hyperacusis	52/55	94.5
Congenital heart disease	45/55	81.2
Genitourinary symptoms	47/55	85.5
Short stature	24/55	43.6
Hypertension	20/55	36.4
Microcephaly	17/55	31.0

\*Typical WBS facies based on the score proposed by the Genetics Committee of the American Academy of Pediatrics (2001).

defect, tricuspid insufficiency, pulmonary valve insufficiency, mitral valve insufficiency, and bicuspid aortic valve.

One patient with SVAS that was surgically repaired in childhood presented with congestive heart failure at 19 years of age and needed a heart transplant. However, she died due to CMV infection on the 30th day after transplant.

Two other patients, a 13-year-old girl and a 19-year-old boy, died due to cardiovascular complications.

Ten out of 55 patients (18.2%) did not have congenital heart disease.

Short stature was present in 24 patients (12 females and 12 males). Microcephaly was present in 17 patients, 13 of whom were females.

Hypercalcemia was detected in only one patient, at 1.6 years of age. Another patient had serum calcium in the upper limit of normal. Two other patients presented with nephrocalcinosis, and one presented with hypercalciuria but normal serum calcium.

Noncongenital hypothyroidism was diagnosed in 8 patients (14.5%). Seven patients (7.3%) had subclinical hypothyroidism. None of the patients had abnormal fasting blood glucose levels.

Strabismus was present in 19 patients (34.5%), and hernias, either umbilical or inguinal, were present in 20 patients (36.4%). Three patients (5.4%) presented with lacrimal duct obstruction.

Genitourinary symptoms, including mainly urinary urgency and nocturnal enuresis, were reported in 45 patients (85.4%).

Twenty patients (36.4%) presented with arterial pressures above the normal levels for their age, gender, and height percentiles. The ages of these patients ranged from 4 to 23 years old. Four of them (20% of the patients with hypertension) had renal artery stenosis. Three (aged 7–13 years old) underwent corrective surgery, and one is awaiting the intervention. One patient required 2 procedures at 8 and 11 years of age.

Scoliosis was present in 31 of the 55 patients (56.4%), and radioulnar synostosis was present in 6 (10.9%).

All patients had delays in at least one motor milestone and/or had mental retardation. One patient was diagnosed with panic disorder, and one had visual hallucinations.

Some clinical manifestations rarely described in WBS were found in our patients as follows: vertebral fusion (2 patients with cervical vertebral fusion and another with lumbosacral vertebral fusion), accessory spleen ( $n = 1$ ), scrotal nodule ( $n = 1$ ), labia majora hypertrophy ( $n = 1$ ), sagittal craniosynostosis ( $n = 1$ ), neonatal tooth ( $n = 1$ ), and muscular hernia in the leg ( $n = 1$ ).

#### 4. Discussion

For geneticists, WBS is a well-known syndrome. It is usually promptly recognizable by the characteristic facial dysmorphisms and typical hypersocial behavior. Severe cases of

neonatal hypercalcemia can result in death before a diagnosis of WBS has been considered. For this reason, neonatologists should consider WBS diagnosis in neonates with hypercalcemia and/or intrauterine restriction and SVAS.

Regarding the frequency of congenital heart disease in this cohort (81.8%) and the most prevalent type, SVAS (42.2%), the data are concordant with the literature [2]. A significant number of the patients were referred to our service from the WBS National Patient Association (ABSW), not from the cardiology department of the hospital. This could have contributed to the SVAS frequency being below 50%. Although it is an important sign of the syndrome, SVAS is not pathognomonic. It is important to reinforce that the absence of congenital heart disease does not rule out WBS diagnosis. Because cardiovascular disease in WBS has been credited to the *ELN* gene deletion, it is intriguing that at least 15% of the patients with this deletion do not have cardiac abnormalities. Epigenetic factors such as copy number variation in other regions of the genome might play a role.

Sudden death is one of the complications in WBS [31–35]. Some necropsy cases revealed stenoses of the coronary arteries and severe biventricular obstruction with myocardial ischemia, decreased cardiac output, and arrhythmias as causes of death [31]. Other patients died after anesthetic procedures [36]. A phenomenon called Kounis syndrome can occur when inflammatory mediators, possibly due to massive mast cells degranulation, induce coronary spasm or obstruction in patients with preexisting coronary disease [37, 38]. We had 3 patients that died during adolescence due to cardiovascular complications. One underwent heart transplantation; the indications and outcome of this procedure in WBS are scarce in the literature.

The prevalence of other findings in WBS in this cohort is the same as reported by other groups in regard to facial dysmorphisms, hypersocial behavior, neuromotor delay, hyperacusis, short stature, and microcephaly [39]. However, only one patient presented with hypercalcemia, a feature that is usually linked to WBS because of its description. Hypercalcemia often manifests in the first years of life [2], and some of our patients might have presented this abnormality before the diagnosis of WBS was considered. Because serum calcium is not routinely measured in the neonate unit or the pediatric ER and most of our patients have not been diagnosed with WBS by this time, this may be a bias in our cohort. In addition, hypercalcemia can present at any time in a WBS patient's life; thus, although our patients did not have hypercalcemia during the assessment period, they are still at risk and should be periodically monitored for calcium disturbances [39, 40].

The prevalence of thyroid abnormalities in our cohort (14.3% of hypothyroidism and 7.3% of subclinical hypothyroidism) is similar to that of other studies, even though there is a wide range of the reported prevalences (2–38%) [39, 41]. Because hypothyroidism can aggravate some of the clinical manifestations of WBS and is a treatable condition, periodic monitoring of thyroid hormone levels in WBS patients is recommended. Currently, there is a recommendation of assessment every two years (American Academy of Pediatrics, 2001); however, in our protocol, we tested yearly,

and several cases were diagnosed; thus, the interval of testing should be shorter.

Diabetes mellitus is a well-described late manifestation of WBS [40]. Although none of our patients had abnormal fasting glucose levels, most of them were children and adolescents; diabetes in WBS is more common in the adult population [40, 42].

The frequencies of other manifestations in this cohort, such as strabismus, hernias, scoliosis, and radioulnar synostosis, were concordant to the prevalence and variations described in literature [16, 39, 43, 44].

On the other hand, urinary problems were somewhat more frequent in this cohort (85.4% in our study versus 68% in the literature) [16, 39]. This could be due to the fact that a urologist evaluated all of our patients.

Arterial hypertension was detected in 20/55 patients (36.4%), one of whom was diagnosed at 4 years old; this can be an early complication in WBS. In this syndrome, there is a lifetime risk of developing arterial hypertension of 50% [45], and this has been reported even in 1-month-old patients [46]. Four out of 20 patients in our group (20%) had renovascular disease. Arterial hypertension due to renal artery stenosis is described in 44% of WBS patients [47]. Thus, every patient with WBS, regardless of age, should be monitored for blood pressure (American Academy of Pediatrics, 2001), and, in the case of hypertension (using appropriate curves for age and height percentiles), evaluation of the renal arteries is mandatory.

The occurrence of other rare findings in our patients (e.g., accessory spleens, neonatal tooth, and muscle hernias) and their relation to WBS could not be determined because the prevalence of each finding separately was low. Lacrimal duct stenosis and craniosynostosis, although uncommon, were already described in WBS [48, 49]. One patient presented with recurrent patellar dislocation, which has also already been described in WBS [50].

FISH has been the gold-standard method for the diagnosis of WBS. Among the 55 patients studied by MLPA in this study, 16 also had positive FISH results. However, two patients with typical physical and behavioral characteristics of WBS had negative FISH results but positive polymorphic marker analysis and MLPA results, which detected the typical deletion. After the positive results in both cases using MLPA method (deletion of all the probes, not an atypical deletion), we contacted the laboratory that had performed FISH. The FISH tests were repeated and the results were positive for the microdeletion. This emphasizes the importance of testing with another method or repeating the test when clinical and laboratory analyses diverge. A group from Netherlands studied 63 patients by FISH and MLPA. In 53/63 patients, the microdeletion was detected by both methods. In 10 patients, the results were negative with MLPA and FISH. However, one patient with a small, atypical microdeletion could only be diagnosed with MLPA; FISH using commercial probes was negative [51]. Thus, the gold-standard test to the diagnosis of WBS should be revised.

MLPA is also used to diagnose many other syndromes of microdeletion and microduplication, such as Smith-Magenis, DiGeorge, Alagille, Prader-Willi, and Angelman syndrome.



There are specific kits for each syndrome or kits with a few probes of multiple syndromes (e.g., kits to diagnose some mental retardation syndromes). MLPA has also been proven useful for prenatal diagnosis using amniotic fluid for microdeletion and microduplication syndromes and for the diagnosis of trisomies [52–55].

## 5. Conclusions

The assessment and long follow-up of WBS patients by several medical specialties is of great relevance due to the relatively high prevalence of multisystem manifestations and complications.

MLPA was effective in confirming the diagnosis of WBS and can be used as the first exam in developing countries due to its lower cost compared with FISH. In addition, MLPA has the advantage of detecting atypical deletions and can be useful when FISH is negative in patients with clinical characteristics that are highly suggestive of WBS.

## Conflict of Interests

The authors declare that there is no conflict of interests regarding the publication of this paper.

## References

- [1] K. L. Jones and D. W. Smith, "The Williams elfin facies syndrome. A new perspective," *The Journal of Pediatrics*, vol. 86, no. 5, pp. 718–723, 1975.
- [2] D. Donnai and A. Karmiloff-Smith, "Williams syndrome: from genotype through to the cognitive phenotype," *American Journal of Medical Genetics*, vol. 97, no. 2, pp. 164–171, 2000.
- [3] A. Meyer-Lindenberg, C. B. Mervis, and K. Faith Berman, "Neural mechanisms in Williams syndrome: a unique window to genetic influences on cognition and behaviour," *Nature Reviews Neuroscience*, vol. 7, no. 5, pp. 380–393, 2006.
- [4] P. Strømme, P. G. Bjørnstad, and K. Ramstad, "Prevalence estimation of Williams syndrome," *Journal of Child Neurology*, vol. 17, no. 4, pp. 269–271, 2002.
- [5] J. Burn, "Williams syndrome," *Journal of Medical Genetics*, vol. 23, no. 5, pp. 389–395, 1986.
- [6] U. Francke, "Williams-Beuren syndrome: genes and mechanisms," *Human Molecular Genetics*, vol. 8, no. 10, pp. 1947–1954, 1999.
- [7] U. Bellugi, L. Lichtenberger, W. Jones, Z. Lai, and M. St. George, "I. The neurocognitive profile of Williams syndrome: a complex pattern of strengths and weaknesses," *Journal of Cognitive Neuroscience*, vol. 12, supplement 1, pp. 7–29, 2000.
- [8] M. K. Greer, F. R. Brown III, G. S. Pai, S. H. Choudry, and A. J. Klein, "Cognitive, adaptive, and behavioral characteristics of Williams syndrome," *American Journal of Medical Genetics*, vol. 74, no. 5, pp. 521–525, 1997.
- [9] O. Udewin and W. Yule, "A cognitive and behavioural phenotype in Williams syndrome," *Journal of Clinical and Experimental Neuropsychology*, vol. 13, no. 2, pp. 232–244, 1991.
- [10] T. F. Doyle, U. Bellugi, J. R. Korenberg, and J. Graham, "Everybody in the world is my friend' hypersociability in young children with Williams syndrome," *American Journal of Medical Genetics Part A*, vol. 124, no. 3, pp. 263–273, 2004.
- [11] A. Gosch and R. Pankau, "Social-emotional and behavioral adjustment in children with Williams-Beuren syndrome," *American Journal of Medical Genetics*, vol. 53, no. 4, pp. 335–339, 1994.
- [12] C. Schubert, "The genomic basis of the Williams-Beuren syndrome," *Cellular and Molecular Life Sciences*, vol. 66, no. 7, pp. 1178–1197, 2009.
- [13] M. Bayés, L. F. Magano, N. Rivera, R. Flores, and L. A. Pérez Jurado, "Mutational mechanisms of Williams-Beuren syndrome deletions," *American Journal of Human Genetics*, vol. 73, no. 1, pp. 131–151, 2003.
- [14] Y.-Q. Wu, V. R. Sutton, E. Nickerson et al., "Delineation of the common critical region in Williams syndrome and clinical correlation of growth, heart defects, ethnicity, and parental origin," *American Journal of Medical Genetics*, vol. 78, no. 1, pp. 82–89, 1998.
- [15] R. L. Dutra, *Análise de marcadores moleculares para o diagnóstico da síndrome de Williams-Beuren*, Departamento de Pediatria, Universidade de São Paulo, São Paulo, Brazil, 2011.
- [16] L. A. P. Jurado, R. Peoples, P. Kaplan, B. C. J. Hamel, and U. Francke, "Molecular definition of the chromosome 7 deletion in Williams syndrome and parent-of-origin effects on growth," *The American Journal of Human Genetics*, vol. 59, no. 4, pp. 781–792, 1996.
- [17] A. Antonell, M. del Campo, R. Flores, V. Campuzano, and L. A. Pérez-Jurado, "Williams syndrome: its clinical aspects and molecular bases," *Revista de Neurologia*, vol. 42, supplement 1, pp. S69–S75, 2006.
- [18] A. K. Ewart, C. A. Morris, D. Atkinson et al., "Hemizygoty at the elastin locus in a developmental disorder, Williams syndrome," *Nature Genetics*, vol. 5, no. 1, pp. 11–16, 1993.
- [19] X. Cortada, K. Taysi, and A. F. Hartmann, "Familial Williams syndrome," *Clinical Genetics*, vol. 18, no. 3, pp. 173–176, 1980.
- [20] C. A. Morris, "Williams syndrome," in *GeneReviews*, R. A. Pagon, T. D. Bird, C. R. Dolan, and K. Stephens, Eds., University of Washington, Seattle, Wash, USA, 1993.
- [21] R. Pankau, R. Siebert, M. Kautza et al., "Familial Williams-Beuren syndrome showing varying clinical expression," *American Journal of Medical Genetics*, vol. 98, no. 4, pp. 324–329, 2001.
- [22] C. A. Morris, J. Loker, G. Ensing, and A. D. Stock, "Supravalvular aortic stenosis cosegregates with a familial 6;7 translocation which disrupts the elastin gene," *American Journal of Medical Genetics*, vol. 46, no. 6, pp. 737–744, 1993.
- [23] K. Ounap, P. Laidre, O. Bartsch, R. Rein, and M. Lipping-Sitska, "Familial Williams-Beuren syndrome," *American Journal of Medical Genetics*, vol. 80, no. 5, pp. 491–493, 1998.
- [24] L. S. Sadler, L. K. Robinson, K. R. Verdaasdonk, and R. Gingell, "The Williams syndrome: evidence for possible autosomal dominant inheritance," *American Journal of Medical Genetics*, vol. 47, no. 4, pp. 468–470, 1993.
- [25] L. R. Osborne, M. Li, B. Pober et al., "A 1.5 million-base pair inversion polymorphism in families with Williams-Beuren syndrome," *Nature Genetics*, vol. 29, no. 3, pp. 321–325, 2001.
- [26] S. W. Scherer, K. W. Gripp, J. Lucena et al., "Observation of a parental inversion variant in a rare Williams-Beuren syndrome family with two affected children," *Human Genetics*, vol. 117, no. 4, pp. 383–388, 2005.
- [27] H. H. Hobart, C. A. Morris, C. B. Mervis et al., "Inversion of the Williams syndrome region is a common polymorphism found more frequently in parents of children with Williams syndrome," *American Journal of Medical Genetics Part C: Seminars in Medical Genetics*, vol. 154, no. 2, pp. 220–228, 2010.

- [28] Z. Urban, C. Helms, G. Fekete et al., "7q11.23 deletions in Williams syndrome arise as a consequence of unequal meiotic crossover," *The American Journal of Human Genetics*, vol. 59, no. 4, pp. 958–962, 1996.
- [29] E. H. Cho, B. Y. N. Park, J. H. Cho, and Y. S. Kang, "Comparing two diagnostic laboratory tests for several microdeletions causing mental retardation syndromes: multiplex ligation-dependent amplification vs fluorescent *in situ* hybridization," *The Korean Journal of Laboratory Medicine*, vol. 29, no. 1, pp. 71–76, 2009.
- [30] S. A. Miller, D. D. Dykes, and H. F. Polesky, "A simple salting out procedure for extracting DNA from human nucleated cells," *Nucleic Acids Research*, vol. 16, no. 3, article 1215, 1988.
- [31] L. M. Bird, G. F. Billman, R. V. Lacro et al., "Sudden death in Williams syndrome: report of ten cases," *The Journal of Pediatrics*, vol. 129, no. 6, pp. 926–931, 1996.
- [32] M. P. Suárez-Mier and B. Morentin, "Supravalvular aortic stenosis, Williams syndrome and sudden death. A case report," *Forensic Science International*, vol. 106, no. 1, pp. 45–53, 1999.
- [33] E. E. Conway Jr., J. Noonan, R. W. Marion, and C. N. Steeg, "Myocardial infarction leading to sudden death in the Williams syndrome: report of three cases," *The Journal of Pediatrics*, vol. 117, no. 4, pp. 593–595, 1990.
- [34] D. Kececioglu, S. Kotthoff, and J. Vogt, "Williams-Beuren syndrome: a 30-year follow-up of natural and postoperative course," *European Heart Journal*, vol. 14, no. 11, pp. 1458–1464, 1993.
- [35] A. Wessel, V. Gravenhorst, R. Buchhorn, A. Gosch, C.-J. Partsch, and R. Pankau, "Risk of sudden death in the Williams-Beuren syndrome," *American Journal of Medical Genetics Part A*, vol. 127, no. 3, pp. 234–237, 2004.
- [36] P. Gupta, J. D. Tobias, S. Goyal et al., "Sudden cardiac death under anesthesia in pediatric patient with Williams syndrome: a case report and review of literature," *Annals of Cardiac Anaesthesia*, vol. 13, no. 1, pp. 44–48, 2010.
- [37] N. G. Kounis, G. D. Soufras, and A. Mazarakis, "The mystery of sudden death in Williams-Beuren syndrome: cardiomyopathy or Kounis syndrome?" *International Journal of Cardiology*, vol. 156, no. 3, pp. 251–252, 2012.
- [38] N. G. Kounis, G. Tsigkas, G. Almpanis, A. Mazarakis, and G. N. Kounis, "Kounis syndrome—the killer for Williams syndrome," *Annals of Cardiac Anaesthesia*, vol. 13, no. 3, pp. 265–266, 2010.
- [39] Committee on Genetics, "American Academy of Pediatrics: health care supervision for children with Williams syndrome," *Pediatrics*, vol. 107, no. 5, pp. 1192–1204, 2001.
- [40] B. R. Pober and C. A. Morris, "Diagnosis and management of medical problems in adults with Williams-Beuren syndrome," *American Journal of Medical Genetics, Part C: Seminars in Medical Genetics*, vol. 145, no. 3, pp. 280–290, 2007.
- [41] A. Selicorni, A. Fratoni, M. A. Pavesi, M. Bottigelli, E. Arnaboldi, and D. Milani, "Thyroid anomalies in Williams syndrome: investigation of 95 patients," *American Journal of Medical Genetics*, vol. 140, no. 10, pp. 1098–1101, 2006.
- [42] B. R. Pober, E. Wang, S. Caprio et al., "High prevalence of diabetes and pre-diabetes in adults with Williams syndrome," *American Journal of Medical Genetics Part C: Seminars in Medical Genetics*, vol. 154, no. 2, pp. 291–298, 2010.
- [43] F. Greenberg and R. A. Lewis, "The Williams syndrome: spectrum and significance of ocular features," *Ophthalmology*, vol. 95, no. 12, pp. 1608–1612, 1988.
- [44] M. F. Bedeschi, V. Bianchi, A. M. Colli et al., "Clinical follow-up of young adults affected by Williams syndrome: experience of 45 Italian patients," *American Journal of Medical Genetics, Part A*, vol. 155, no. 2, pp. 353–359, 2011.
- [45] M. del Campo, A. Antonell, L. F. Magano et al., "Hemizyosity at the *NCF1* gene in patients with Williams-Beuren syndrome decreases their risk of hypertension," *The American Journal of Human Genetics*, vol. 78, no. 4, pp. 533–542, 2006.
- [46] K. Bouchireb, O. Boyer, D. Bonnet et al., "Clinical features and management of arterial hypertension in children with Williams-Beuren syndrome," *Nephrology Dialysis Transplantation*, vol. 25, no. 2, pp. 434–438, 2010.
- [47] R. Pankau, C.-J. Partsch, M. Winter, A. Gosch, and A. Wessel, "Incidence and spectrum of renal abnormalities in Williams-Beuren syndrome," *American Journal of Medical Genetics*, vol. 63, no. 1, pp. 301–304, 1996.
- [48] B. R. Pober, "Williams-Beuren syndrome," *The New England Journal of Medicine*, vol. 362, no. 3, pp. 239–252, 2010.
- [49] M. Morimoto, B. An, A. Ogami et al., "Infantile spasms in a patient with Williams syndrome and craniosynostosis," *Epilepsia*, vol. 44, no. 11, pp. 1459–1462, 2003.
- [50] C. A. Morris, A. M. Pani, C. B. Mervis, C. M. Rios, D. J. Kistler, and R. G. Gregg, "Alpha 1 antitrypsin deficiency alleles are associated with joint dislocation and scoliosis in Williams syndrome," *American Journal of Medical Genetics Part C: Seminars in Medical Genetics*, vol. 154, no. 2, pp. 299–306, 2010.
- [51] J. M. van Hagen, H. J. F. M. M. Eussen, R. van Schooten et al., "Comparing two diagnostic laboratory tests for Williams syndrome: fluorescent *in situ* hybridization versus multiplex ligation-dependent probe amplification," *Genetic Testing*, vol. 11, no. 3, pp. 321–327, 2007.
- [52] A. Weise, K. Mrasek, E. Klein et al., "Microdeletion and microduplication syndromes," *The Journal of Histochemistry and Cytochemistry*, vol. 60, no. 5, pp. 346–358, 2012.
- [53] F. S. Jehee, J. T. Takamori, P. F. Medeiros et al., "Using a combination of MLPA kits to detect chromosomal imbalances in patients with multiple congenital anomalies and mental retardation is a valuable choice for developing countries," *European Journal of Medical Genetics*, vol. 54, no. 4, pp. e425–e432, 2011.
- [54] N. H. Hamidah, A. R. Munirah, A. Hafiza et al., "Prenatal diagnosis of aneuploidies in amniotic fluid by multiple ligation-dependent probe amplification (MLPA) analysis," *The Malaysian Journal of Pathology*, vol. 36, no. 3, pp. 163–168, 2014.
- [55] C.-P. Chen, J.-P. Huang, Y.-Y. Chen et al., "Chromosome 22q11.2 deletion syndrome: prenatal diagnosis, array comparative genomic hybridization characterization using uncultured amniocytes and literature review," *Gene*, vol. 527, no. 1, pp. 405–409, 2013.