

## Case Report

# Endoscope-Assisted Trans-Sphenoidal Approach for Treatment of Sternberg's Canal

Giuliano Maselli, M.D.,<sup>1</sup> Alessandro Ricci, M.D.,<sup>2</sup> Renato J. Galzio, M.D.<sup>1</sup>

*Health Sciences Department and Operative Unit of Neurosurgery,<sup>1</sup> University of L'Aquila, San Salvatore Hospital, L'Aquila, Italy  
Operative Unit of Neurosurgery;<sup>2</sup> San Salvatore Hospital, L'Aquila, Italy*

We report an uncommon case of a 45-year-old woman who presented with spontaneous rhinorrhea. A computed tomography (CT) scan of the head revealed an abnormally large sphenoid sinus associated with a parasellar bony defect (Sternberg's canal) through which magnetic resonance imaging could detect an encephalocele of the right temporal lobe. An endoscope-assisted trans-sphenoidal approach was performed and, with the aid of image guided surgery, reduction of the encephalocele was obtained and followed by surgical repair of the dural and bony defects. The postoperative course was uneventful and the cerebrospinal fluid fistula was closed as confirmed by the postoperative CT scan and by the absence of rhinorrhea. After three years of monitoring the patient remained asymptomatic.

**Key Words :** Cerebrospinal fluid · Endoscope-assisted procedures · Sternberg's canal.

## INTRODUCTION

Spontaneous sphenoidal encephaloceles are uncommon entities and the presence of lateral sphenoidal encephalocele is a rare congenital anomaly<sup>3</sup>. Sternberg's canal is a lateral cranio-pharyngeal canal resulting from incomplete fusion of different sphenoid bone components<sup>5</sup>.

Congenital skull base abnormalities are believed to be the result of incomplete or premature fusion of the normal bony elements involved in the complex process of central skull base ossification. Due to their rarity, these lesions are seldom discussed in the medical literature and, to date, only isolated reports and small series are found<sup>4</sup>. The persistence of these abnormalities is often associated with cerebrospinal fluid (CSF) leak and encephaloceles<sup>8</sup>.

The efficacy and safety of the trans-sphenoidal approach for the resection of pituitary tumours and the treatment of associated CSF rhinorrhea has encouraged surgeons to use the trans-nasal route for the repair of all CSF leaks in the middle cranial fossa and sphenoidal sinus region<sup>1,7,10</sup>.

In the present case, we report the effectiveness of surgical treatment of a persistent Sternberg's canal by an endoscope-as-

sisted trans-sphenoidal approach.

## CASE REPORT

A 45-year-old female presented with complaints of intermittent right-sided watery nasal discharge for one year, without headache, nausea or fever. The symptom was worsened by clinostatic position : during the night, the patient referred watering fluid in the pharynx. This was accompanied by confusion sensation and, sometimes, positional headache. There was no history of meningitis or trauma.  $\beta$ 2-Transferrin-analysis and albumin/prealbumin tests of the nasal discharge indicated cerebrospinal fluid. The high resolution computed tomography of facial massix scans, including coronal reconstructions, revealed a particularly extended sphenoidal sinus on the right side (Fig. 1A, 2A). Magnetic resonance imaging with contrast medium demonstrated peripheral enhancement of the lesion. We diagnosed the lesion as sphenoidal encephalocele (Fig. 1B, 2B).

We decided to approach the lesion by an endoscope-assisted trans-sphenoidal approach, supported by neuronavigation, and the parasellar bony defect was confirmed (Fig. 3). The right temporal lobe pole was herniated into the accessory sphenoidal

• Received : December 25, 2011 • Revised : August 10, 2012 • Accepted : December 14, 2012

• Address for reprints : Giuliano Maselli, M.D.  
via Giuseppe Garibaldi, 19, 64023 Mosciano Sant'Angelo, Teramo, Italy  
Tel : +39-3497310041, Fax : +39-0862368233, E-mail : giuliano.maselli@tin.it

• This is an Open Access article distributed under the terms of the Creative Commons Attribution Non-Commercial License (<http://creativecommons.org/licenses/by-nc/3.0>) which permits unrestricted non-commercial use, distribution, and reproduction in any medium, provided the original work is properly cited.

cell. Furthermore, the endoscope-assisted observation permitted to individuate cerebrospinal liquor outflow, under brain pulsation (Fig. 4).

The herniated brain material was removed under endoscopic control, until the individuation the bone defect on anterior wall of accessory cell. After abdominally fat and muscle graft by a right paraumbilical incision, under intraoperative microscopic control, a sphenoidal accessory cell duroplasty was accomplished by inserting grafts of abdominal fat into the “bottleneck” of the meningocele. With the aid of neuronavigation, reduction of the right sphenoidal encephalocele was obtained and the persistent canal was sealed with the aid of fat, muscle graft and fibrin glue.

The nasal discharge stopped immediately after surgery and postoperative computed tomography demonstrated the complete reconstruction by a duroplasty (Fig. 5).

Three years later the patient had no evidence of cerebrospinal fluid leakage.

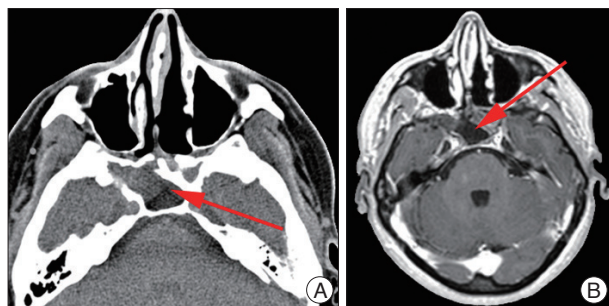
## DISCUSSION

Spontaneous CSF leaks have been estimated an infrequent entity, but recently this idea has changed<sup>9)</sup>. Skull base malformations and obesity are considered risk factors for their development<sup>6)</sup>. An overpneumatized sphenoid sinus, especially in its lateral wall, is often a site where a CSF leak may emerge<sup>13)</sup>. This

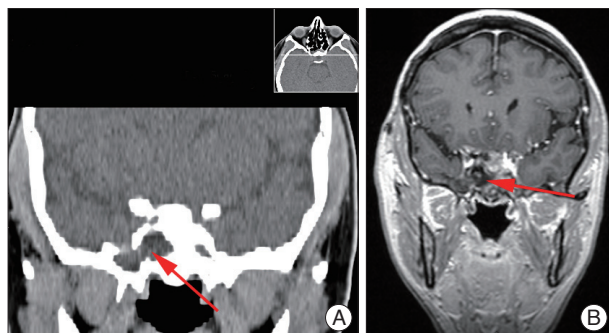
pneumatization might contribute to weakening of the sphenoid roof. In fact, pit holes in the floor of the middle cranial fossa have been indicated as causes of encephaloceles, especially when associated with large pneumatization. In the presence of sufficient pneumatization, Sternberg’s canal may act as the site of origin of congenital meningoceles or CSF fistulas<sup>12)</sup>. Furthermore, normal spikes of CSF pressure, and evidently hydrocephalus, may facilitate the development of small holes with herniation of the dura/arachnoid or brain tissue<sup>13)</sup>.

The treatment of spontaneous sphenoidal CSF fistulae has historically involved both extra- and intracranial approaches. The extracranial approaches are desirable from a noninvasive standpoint; however, they fail to provide control of possible lateral extension of the sphenoidal sinus, where several of these fistulae arise<sup>8)</sup>.

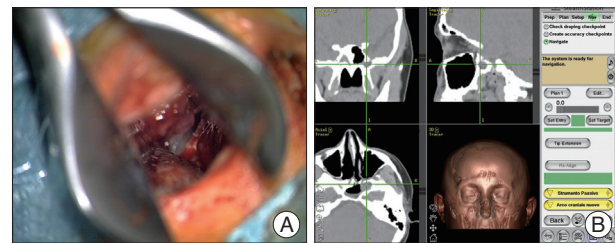
The transnasal approaches to the sphenoid sinus have been proven to be safe and effective in the treatment of CSF rhinor-



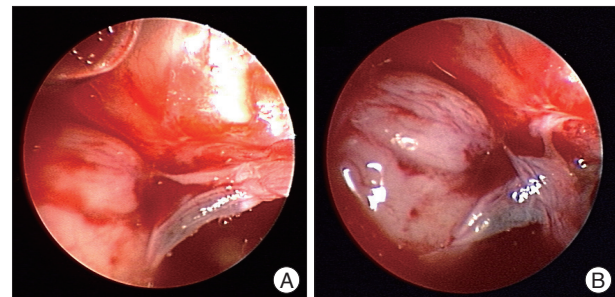
**Fig. 1.** A : High resolution computed tomography of facial massix revealing an accessory cell posterior to the right maxillary sinus. B : Magnetic resonance imaging with contrast medium demonstrating peripheral enhancement of the right sphenoidal encephalocele.



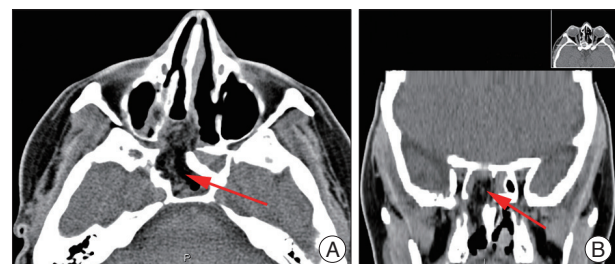
**Fig. 2.** A : High resolution computed tomography of facial massix; coronal reconstruction scan revealing the persistent Sternberg’s canal. B : Magnetic resonance imaging with contrast medium coronal scan demonstrating peripheral enhancement of the right sphenoidal encephalocele.



**Fig. 3.** A : Endoscope-assisted trans-sphenoidal approach. B : Neuronavigation image confirms the bony defect.



**Fig. 4.** A : Endoscopic image of the right sphenoidal encephalocele with cerebrospinal fluid fistula in the endoscopic-assisted trans-sphenoidal approach. B : Endoscopic-assisted trans-sphenoidal approach : a particular of the cerebrospinal liquor outflow under brain pulsation.



**Fig. 5.** A : Postoperative high resolution computed tomography of facial massix demonstrating the reduction of the encephalocele and the complete closure of the defect by duroplasty. B : Postoperative high resolution computed tomography of facial massix; coronal reconstruction scan demonstrating the complete reconstruction by a duroplasty.

rhea associated with post-trans-sphenoidal pituitary surgery, postoperative anterior cranial fossa cranial base surgery, and even medial intrasphenoidal and sellar encephalocele<sup>1,6</sup>.

The endoscope-assisted observation provided the treatment of sellar and parasellar lesions, although pure endoscopic trans-sphenoidal approach have been proposed for this purpose<sup>2,4,11,14</sup>.

Surgeons performing endoscope-assisted microneurosurgical procedures have to see through an operative microscope during specific microsurgical approach. The visualization of the same structures as seen through a different tool, also considering that scope with a different viewing angle provides quite different vision.

During microsurgical procedures, the operative microscope provides direct illumination and magnification of the operative field. However it allows detailed view only of superficially located structures requires manipulation and retraction of intact superficial anatomical sectors, which unavoidably results in iatrogenic traumatism. This may be obviated combining microsurgical techniques to the use of the endoscope, which allows atraumatic vision of the structures located beyond and behind the superficial structures "around the corner".

Endoscope-assisted management is technically challenging, nevertheless its advantages are a good view of the surgical field while being less traumatic than pure trans-sphenoidal or transcranial approaches.

## CONCLUSION

Spontaneous sphenoidal encephaloceles are rare entities often associated with a persistent Sternberg's canal. A case of middle cranial fossa spontaneous CSF fistulae, involving a temporal encephalocele through lateral excision of this sinus, has been presented.

Our experience shows how the endoscope assisted trans-sphenoidal approach allows a wide, safe, and direct route to the lateral recess of the sphenoid sinus. Compared with traditional transcranial routes, this approach provides a good exposure of the

bony defect with minor morbidity and considerable advantages.

## References

1. Albernaz MS, Horton WD, Adkins WY, Garen PD : Intrasphenoidal encephalocele. *Otolaryngol Head Neck Surg* 104 : 279-281, 1991
2. Barañano CF, Curé J, Palmer JN, Woodworth BA : Sternberg's canal : fact or fiction? *Am J Rhinol Allergy* 23 : 167-171, 2009
3. Buchfelder M, Fahlbusch R, Huk WJ, Thierauf P : Intrasphenoidal encephaloceles--a clinical entity. *Acta Neurochir (Wien)* 89 : 10-15, 1987
4. Castelnovo P, Dallan I, Pistochini A, Battaglia P, Locatelli D, Bignami M : Endonasal endoscopic repair of Sternberg's canal cerebrospinal fluid leaks. *Laryngoscope* 117 : 345-349, 2007
5. Catala M : [Embryology of the sphenoid bone]. *J Neuroradiol* 30 : 196-200, 2003
6. Cheung DK, Attia EL, Kirkpatrick DA, Marcarian B, Wright B : An anatomic and CT scan study of the lateral wall of the sphenoid sinus as related to the transnasal transethmoid endoscopic approach. *J Otolaryngol* 22 : 63-68, 1993
7. DeBartolo HM, Vrabec D : Sphenoid encephalocele : report of a case. *Arch Otolaryngol* 103 : 172-174, 1977
8. Landreneau FE, Mickey B, Coimbra C : Surgical treatment of cerebrospinal fluid fistulae involving lateral extension of the sphenoid sinus. *Neurosurgery* 42 : 1101-1104; discussion 1104-1105, 1998
9. Lopatin AS, Kapitanov DN, Potapov AA : Endonasal endoscopic repair of spontaneous cerebrospinal fluid leaks. *Arch Otolaryngol Head Neck Surg* 129 : 859-863, 2003
10. Myssiorek D, Cohen NL : Intrasphenoidal meningoencephalocele : a case report. *Am J Otolaryngol* 8 : 391-394, 1987
11. Pasquini E, Sciarretta V, Farneti G, Mazzatenta D, Modugno GC, Frank G : Endoscopic treatment of encephaloceles of the lateral wall of the sphenoid sinus. *Minim Invasive Neurosurg* 47 : 209-213, 2004
12. Schick B, Brors D, Prescher A : Sternberg's canal--cause of congenital sphenoidal meningocele. *Eur Arch Otorhinolaryngol* 257 : 430-432, 2000
13. Shetty PG, Shroff MM, Fatterpekar GM, Sahani DV, Kirtane MV : A retrospective analysis of spontaneous sphenoid sinus fistula : MR and CT findings. *AJNR Am J Neuroradiol* 21 : 337-342, 2000
14. Tomazic PV, Stammberger H : Spontaneous CSF-leaks and meningoencephaloceles in sphenoid sinus by persisting Sternberg's canal. *Rhinology* 47 : 369-374, 2009