



## Original Article

# Application of three-dimensional prototyping in planning the treatment of proximal humerus bone deformities<sup>☆</sup>



Fernando Carlos Mothes<sup>a</sup>, Almiro Britto<sup>a</sup>, Fábio Matsumoto<sup>a</sup>, Marco Tonding<sup>a,\*</sup>, Rafael Ruaro<sup>b</sup>

<sup>a</sup> Grupo de Cirurgia de Ombro, Santa Casa de Misericórdia de Porto Alegre, Porto Alegre, RS, Brazil

<sup>b</sup> Hospital Unimed Nordeste, Caxias do Sul, RS, Brazil

## ARTICLE INFO

## Article history:

Received 9 May 2017

Accepted 18 July 2017

Available online 2 August 2018

## Keywords:

Humerus

Upper extremity congenital deformities

Bone fractures

Arthroplasty

Osteotomy

## ABSTRACT

**Objective:** To describe the use of three-dimensional prototyping or rapid prototyping in acrylic resin to create synthetic three-dimensional models in order to promote the understanding of bone deformities of the shoulder.

**Methods:** Five patients were analyzed between ages of 11 and 73 years old, treated between 2008 and 2013 with glenohumeral deformities that required a more thorough review of the anatomical alterations, for whom three-dimensional prototyping was performed.

**Results:** Patient 1 was treated conservatively and is awaiting humeral head arthroplasty if symptoms get worse. Patient 2 underwent a valgus proximal humerus osteotomy secured with pediatric locked hip plate according to a prior assessment with prototyping. Patient 3 underwent a disinsertion of the rotator cuff, tubercleplasty and posterior reinsertion of the rotator cuff. Patient 4 underwent an arthroscopic step-off resection, 360-degree capsulotomy, and tenolysis of the subscapularis. Patient 5 underwent a reverse shoulder arthroplasty with an L-shaped bone graft on the posterior glenoid.

**Conclusions:** Rapid prototyping in acrylic resin allows a better preoperative planning in treatment of bone deformities in the shoulder, minimizing the risk of intraoperative complications in an attempt to improve the results.

© 2018 Published by Elsevier Editora Ltda. on behalf of Sociedade Brasileira de Ortopedia e Traumatologia. This is an open access article under the CC BY-NC-ND license (<http://creativecommons.org/licenses/by-nc-nd/4.0/>).

<sup>☆</sup> Study conducted at Grupo de Cirurgia de Ombro, Santa Casa de Misericórdia de Porto Alegre, Porto Alegre, RS, Brazil.

\* Corresponding author.

E-mail: [marcotonding@gmail.com](mailto:marcotonding@gmail.com) (M. Tonding).

<https://doi.org/10.1016/j.rboe.2018.07.016>

2255-4971/© 2018 Published by Elsevier Editora Ltda. on behalf of Sociedade Brasileira de Ortopedia e Traumatologia. This is an open access article under the CC BY-NC-ND license (<http://creativecommons.org/licenses/by-nc-nd/4.0/>).

## O uso da prototipagem tridimensional para o planejamento do tratamento das deformidades ósseas do úmero proximal

### R E S U M O

#### Palavras-chave:

Úmero  
Deformidades congênicas das extremidades superiores  
Fraturas ósseas  
Artroplastia  
Osteotomia

**Objetivo:** Descrever o uso da prototipagem tridimensional ou prototipagem rápida em resina acrílica na criação de modelos sintéticos tridimensionais para facilitar o entendimento das deformidades ósseas do ombro.

**Métodos:** Foram analisados cinco pacientes entre 11 e 73 anos, tratados entre 2008 e 2013, com deformidades glenoumerais, que necessitavam de uma avaliação mais precisa da alteração anatômica, nos quais foi feita a prototipagem tridimensional.

**Resultados:** O paciente 1 foi tratado conservadoramente e aguarda artroplastia da cabeça umeral caso haja piora dos sintomas. O paciente 2 foi submetido a osteotomia valgizante do úmero proximal, fixada com placa bloqueada de quadril pediátrica conforme avaliação prévia da prototipagem. O paciente 3 foi submetido a desinserção do manguito e plastia dos tubérculos e posterior reinserção do manguito rotador. O paciente 4 foi submetido a ressecção artroscópica do degrau articular, capsulotomia 360 graus e tenólise do subescapular. O paciente 5 foi submetido a artroplastia reversa de ombro com enxerto ósseo em L na glenoide posterossuperior.

**Conclusão:** A prototipagem rápida em resina acrílica permite um melhor planejamento pré-operatório no tratamento das deformidades ósseas no ombro, minimiza o risco de intercorrências intraoperatórias, numa tentativa de aprimorar os resultados.

© 2018 Publicado por Elsevier Editora Ltda. em nome de Sociedade Brasileira de Ortopedia e Traumatologia. Este é um artigo Open Access sob uma licença CC BY-NC-ND (<http://creativecommons.org/licenses/by-nc-nd/4.0/>).

## Introduction

The shoulder is the joint with the greatest range of motion of the human body and, in order to function properly, it is imperative that all articular and periarticular structures are in anatomical positions.<sup>1-6</sup> Bone anatomy plays a fundamental role because it is the basis for the origin and insertion of all other tissues, such as cartilage, labrum, ligaments, muscles, and tendons. Changes in the bone structure cause a biomechanical imbalance, with alterations in joint congruence as well as in muscle length and angulation, leading to shoulder girdle dysfunction.<sup>4</sup>

Bone deformities at the proximal end of the humerus can be traumatic (fractures) or degenerative (arthrosis). For the adequate treatment of these deformities, it is important to have a clear understanding of the anatomical changes through imaging tests. Simple radiography is limited, as it only provides a two-dimensional image.<sup>7</sup> Computed tomography with three-dimensional reconstructions allow a more detailed evaluation of the bone anatomy, but still presents limitations, such as limited accuracy and magnification of the exam; moreover, it does not allow the manipulation of the studied structure.<sup>8,9</sup>

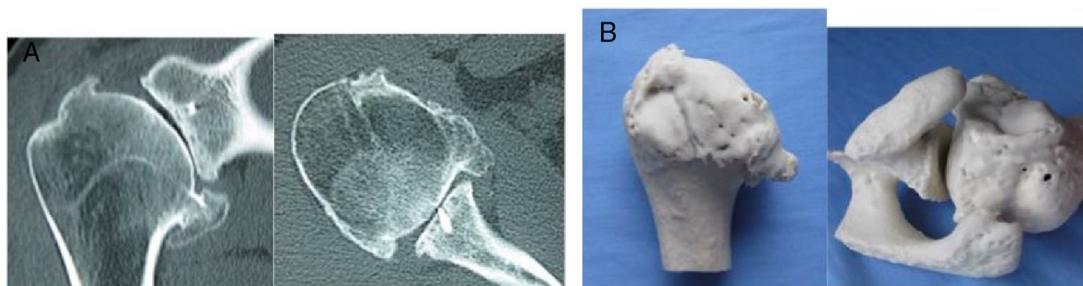
Rapid prototyping is a method that makes real three-dimensional models based on virtual three-dimensional models.<sup>10,11</sup> It uses synthetic models to produce an accurate three-dimensional copy of the bone anatomy. This technique was developed in the 1980s and was initially used for industrial purposes and for detailed reconstructions of complex sculptures.<sup>8</sup> In the healthcare area, it is known as Medical

Rapid Prototyping (MRP) and is most commonly used in oral and maxillofacial surgeries and neurosurgeries.<sup>12</sup> The first prototyping reconstructions were used for oral and maxillofacial reconstructions in the early 1990s; they began to be used in orthopedic surgeries at the end of that decade.<sup>13</sup> Nowadays, the biomedical use of prototyping already represents approximately 10% of the total market for the use of this technology, especially in oral and maxillofacial reconstruction and neurological surgeries;<sup>11,13</sup> it has even been used in the preparation of guides for placing screws that were planned preoperatively.<sup>14,15</sup>

In orthopedics, prototyping can be used from the treatment of fractures and malunion to the planning of orthopedic orthoses.<sup>13,9,16,17</sup> The technique has two stages: virtual (three-dimensional image) and physical (model manufacture). Initially, a computerized image of the structure to be studied is made; subsequently, the physical model is then manufactured by using computer-aided design (CAD) through the deposition of synthetic material.<sup>10,11,18,19</sup>

With the aid of the synthetic models produced through the prototyping technique, the surgeon can make a precise preoperative plan<sup>9,20</sup> by performing the technique on the prototype before the actual surgery or even by using the prototype in the intraoperative period, since the three-dimensional models produced from polyamide can be autoclaved.<sup>21</sup>

In this study, the authors describe five clinical cases in which the prototyping technique was used to study bone deformities of the shoulder. The goal is to promote and provide orthopedic surgeons with a more efficient and affordable method of surgical planning.



**Fig. 1 – (A) Computed tomography demonstrating severe glenohumeral arthrosis after arthroscopic treatment of anterior shoulder instability; (B) three-dimensional prototyping demonstrating loss of sphericity of the humeral head.**

## Material and methods

The authors report five cases of patients in which three-dimensional prototyping was used. The objective was not to analyze the final result, but rather to demonstrate how prototyping can help in the diagnosis, understanding of the lesions, and surgical planning.

Case 1 – a patient with glenohumeral arthrosis due to chondrolysis caused by metallic anchors after shoulder instability repair. Case 2 – an 11-year-old patient with varus deformity of the proximal humerus due to a physeal bar, a sequela of an epiphyseal fracture. Case 3 – a patient with malunion of the proximal humerus, a sequela of a four-part fracture, impacted in valgus. Case 4 – a proximal humerus fracture, secured with a locking plate, with severe stiffness and step-off articular deformity. Case 5 – a patient with degenerative arthropathy of the rotator cuff, with posterior glenoid erosion. Three-dimensional solid models of the involved joints were made based on tomographic sections that were then analyzed using a specific software.

## Results

### Case 1

A 32-year-old male patient had undergone right shoulder video arthroscopy at another medical facility, five years earlier, due to recurrent dislocation. At the time, a capsuloplasty was done and the labrum was reinserted with metal anchors. After surgery, the patient presented with pain and limited range of motion. He evolved with mild pain but had significant loss of internal and external rotation. Imaging exams indicated glenohumeral arthrosis with humeral osteophytes that involved the glenoid (Fig. 1A). Prototyping was performed to better understand the deformity and to plan a possible surgical treatment with osteophyte removal. As the loss of sphericity of the humeral head (Fig. 1B) was demonstrated, the only possible surgical treatment would have been partial shoulder arthroplasty. As the patient's symptoms were mild, the authors opted for a waiting attitude.

### Case 2

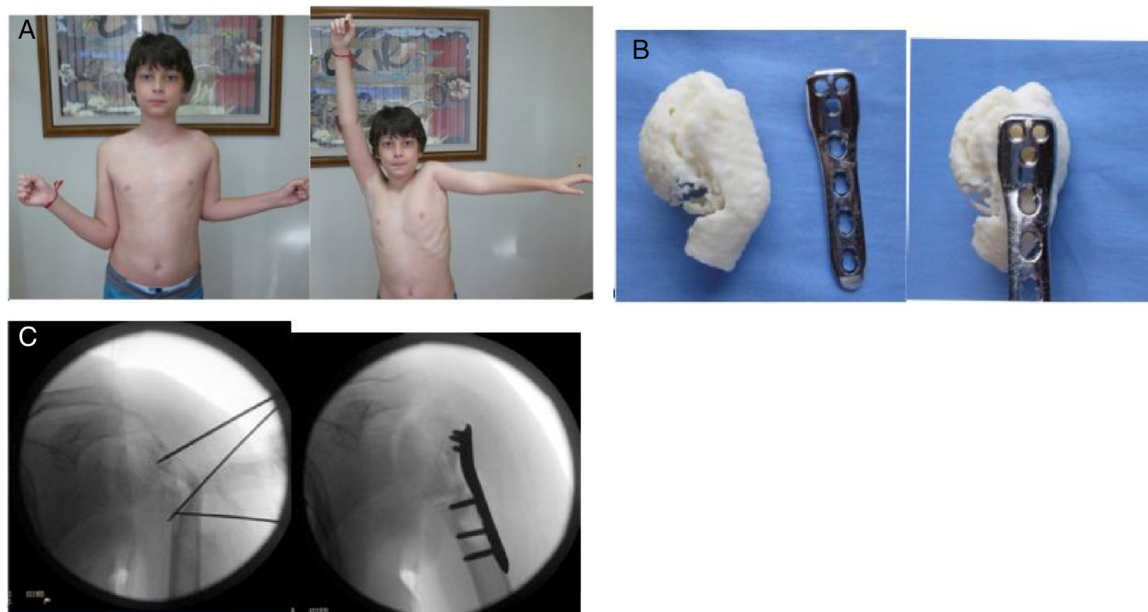
An 11-year-old male patient reported a progressive loss of left shoulder range of motion with arm shortening (Fig. 2A). He had a history of shoulder trauma: a fall from a tree four years before. Since then, he was followed-up by a pediatric orthopedist. Imaging tests indicated an important varus deformity of the proximal humerus, due to a physeal bar in the medial part of the proximal humeral physis (Fig. 2B). Prototyping was used to plan a corrective osteotomy and the implant to be used. The physeal bar was removed with fat interposition; a valgus osteotomy was performed with a lateral subtraction wedge, secured with a locking pediatric hip plate (Fig. 2C).

### Case 3

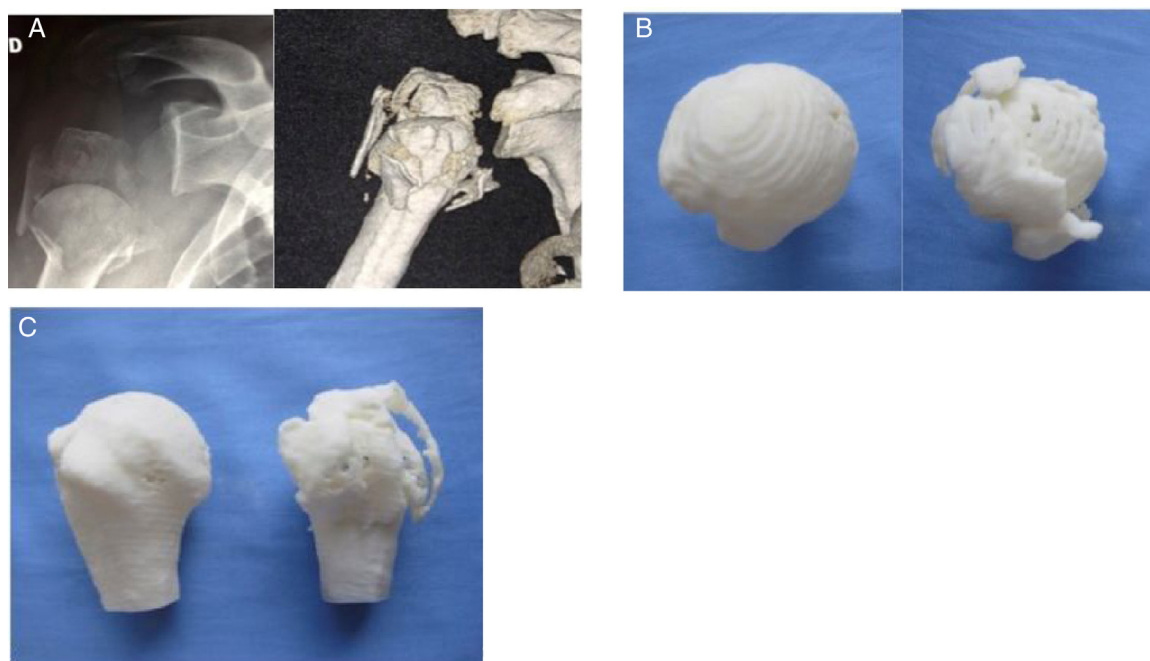
A 69-year-old female patient, who had sequelae from a fracture of the proximal end of the left humerus that had occurred six months before, presented with pain and functional limitation in the shoulder. On radiographic imaging, fractures of the greater tubercle were diagnosed, with a small posterosuperior deviation and as well as the surgical neck with valgus deviation. In this case, the contralateral side was prototyped using a mirror tomography of the right humerus (Fig. 3A–C). As the greater tubercle deformity was very large in several planes, the rotator cuff was disinserted; subsequently, a tubercleplasty was performed and the tendons of the rotator cuff reinserted.

### Case 4

A 59-year-old male patient had suffered a fall from a height, which caused a four-part fracture of the proximal end of the humerus, according to Neer's classification; he underwent open reduction and fixation with a locking proximal humeral plate. He evolved with pain and limited passive range of motion, mainly of internal rotation. The prototyping evidenced an anterior step-off in the humeral head, blocking mobility (Fig. 4A and B). An arthroscopy was performed to resect the step-off using a bone shaver tip; a 360° capsulotomy was also performed.



**Fig. 2 – (A) Patient with loss of range of motion of the left shoulder and shortening of left arm; (B) three-dimensional prototyping for surgical planning; (C) intraoperative fluoroscopy of the surgical procedure.**



**Fig. 3 – (A) Malunion of fracture of the proximal end of right humerus; (B) three-dimensional prototyping showing large deformity; (C) three-dimensional prototyping mirrored of the contralateral shoulder.**

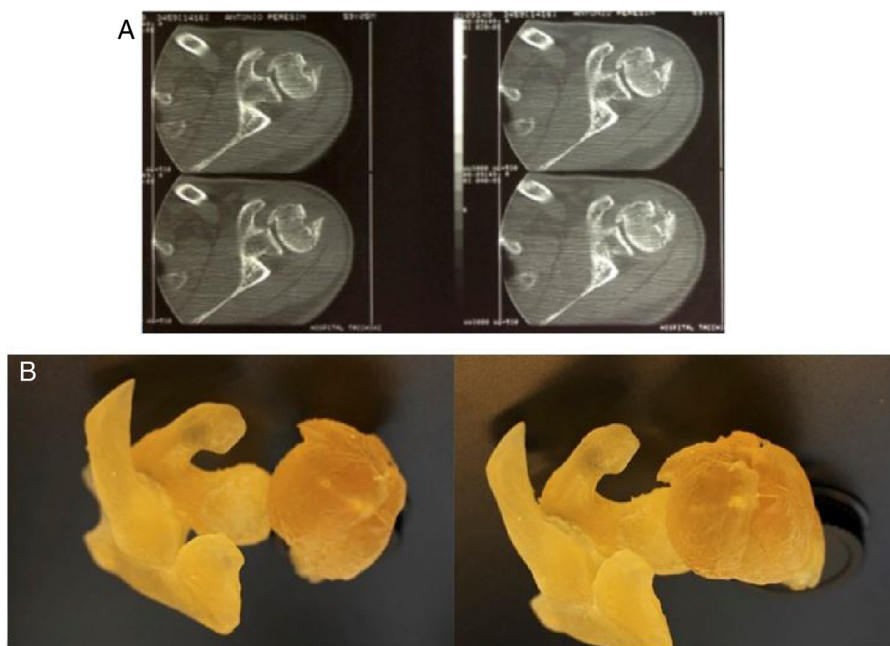
#### Case 5

A 73-years-old female patient with degenerative arthropathy of the rotator cuff on the right shoulder had a posterosuperior erosion of the glenoid (Fig. 5A). Prototyping was performed to plan a glenoid graft. The patient underwent a reverse prosthesis with an L-shaped iliac bone graft in the glenoid, which modeled the erosion (Fig. 5B).

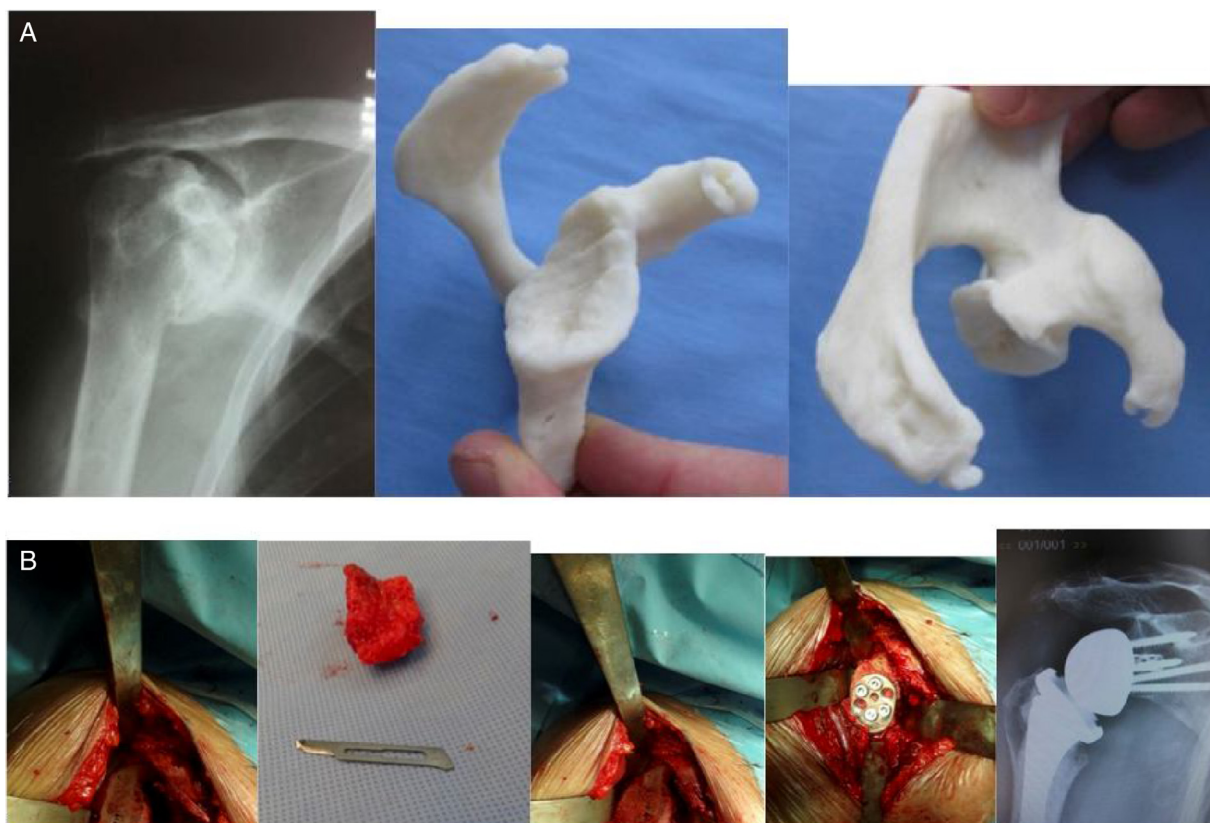
#### Discussion

The treatment of complex fractures and malunion of the humerus presents unpredictable and poor results.<sup>1-6</sup> Corrective osteotomies are often necessary, and it is difficult to know where and how to perform them three-dimensionally.<sup>2,3,5,6,8</sup> Imaging tests are limited, as they do not allow a free





**Fig. 4 – (A) Computed tomography demonstrating articular deformity; (B) prototyping demonstrating mobility locking by the bone.**



**Fig. 5 – (A) Degenerative rotator cuff arthropathy and prototyping evidencing posterosuperior erosion of the glenoid; (B) reverse arthroplasty with L-graft modeling the erosion.**

handling of the part studied. The use of software with three-dimensional correction is useful as a simulation of the procedure,<sup>8,9,20</sup> but this understanding is two-dimensional, as the model is shown through a computer screen, which hinders the understanding of the injury's complexity. Rapid prototyping is an interesting option for such cases, as it allows a perfect understanding of bone deformities.

Some of the main advantages of these models are the better understanding of the configuration of the fracture or deformity; sense of depth of the structures, which is not available in imaging exams, an opportunity to manipulate the lesion and operate on the model before doing surgery on the patient, which from a preoperative planning standpoint is incomparable to traditional designs or even to the reproduction of the surgery using specific software; reduction of surgical time with consequent reduction of blood loss and risk of infection; possibility of achieving a more anatomical reconstruction; and finally, opportunity to use the prototype intraoperatively, as the material can be sterilized.<sup>7-9,12,13,22</sup>

Prototyping may also aid in the planning of surgeries through contralateral symmetry, as demonstrated in Case 3, where the opposite humerus was prototyped based on a mirror tomography. In such a case, the surgeon can have an exact notion of bone deformities of the proximal humerus, since the prototype of the contralateral side, mirrored, is available for handling.

Varus deviation of the humeral head, for example, is a common finding in sequelae of proximal humeral fractures and may cause limitation of shoulder elevation, flexion, and abduction.<sup>4</sup> Malunions with deviations above 20°, as observed in Case 2, should be corrected, as they are not well tolerated by patients.<sup>23,24</sup> The authors believe that, in these cases, prototyping can be of even greater help because, in addition to providing a more detailed anatomical study, it is also possible to plan and perform the osteotomies before the surgical procedure and then reproduce them intraoperatively; it even makes it possible to estimate the size of the implants that will be used and their placement, which can decrease surgical time and possible measurement errors.

Recently, Iannotti et al. reported difficulty in assessing glenoid deformities and the possibility of early release of poorly implanted glenoid components.<sup>14</sup> In that study, the authors used prototyping to prepare a guide made with a Kirschner wire and bone cement (polymethylmethacrylate) before the surgical procedure to aid in the permanent drilling of the central peg of the glenoid implant, minimizing the chance of incorrect positioning.

Three-dimensional prototyping also has an excellent indication for acute fractures, as it shows surgeons the deviations of the bone fragments, allowing them to visualize and handle the reductions that will be needed and to measure the size of the implants that will be used. Resch et al.<sup>25</sup> used prototyping models in a classification study of acute fractures of the proximal humerus. Brown et al.<sup>20</sup> even hypothesized that rapid prototyping will be the future of trauma surgery, as it is possible for the surgeon to benefit from handling the fracture before operating on it, as this facilitates the conceptualization and understanding of the injury patterns, particularly in cases of the spine and acetabular fractures.

In the present study, no reproductions were made with other bone structures; however, the literature features several reports on the use of this technique in other regions, such as the hip and the spine.<sup>9,26-28</sup> Certainly, prototyping can be used in any bone structure in which computed tomography is done.

Currently, osteosynthesis material can already be prepared with the aid of prototyping,<sup>29</sup> which allows the pre-modeling of plates, creation of customized orthoses, and planning for the best positioning and screw size.

---

## Conclusion

The authors believe that the prototyping technique is a useful method for reproducing bone changes in deformities and deviations of the proximal and glenoid humerus, allowing more accurate preoperative planning and minimizing the complications resulting from the difficult three-dimensional understanding of such alterations. The present study has limitations due to the small number of cases and the absence of a control group; more investigation is needed in order to determine its clinical value.

---

## Conflicts of interest

The authors declare no conflicts of interest.

---

## REFERENCES

- Boileau P, Krishnan SG, Tinsi L, Walch G, Coste JS, Molé D. Tuberosity malposition and migration: reasons for poor outcomes after hemiarthroplasty for displaced fractures of the proximal humerus. *J Shoulder Elbow Surg.* 2002;11(5):401-12.
- Boileau P, Trojani C, Walch G, Krishnan SG, Romeo A, Sinnerton R. Shoulder arthroplasty for the treatment of the sequelae of fractures of the proximal humerus. *J Shoulder Elbow Surg.* 2001;10(4):299-308.
- Smith AM, Mardones RM, Sperling JW, Cofield RH. Early complications of operatively treated proximal humeral fractures. *J Shoulder Elbow Surg.* 2007;16(1):14-24.
- Benegas E, Zoppi Filho A, Ferreira Filho AA, Ferreira Neto AA, Negri JH, Prada FS, et al. Surgical treatment of varus malunion of the proximal humerus with valgus osteotomy. *J Shoulder Elbow Surg.* 2007;16(1):55-9.
- Siegel JA, Dines DM. Techniques in managing proximal humeral malunions. *J Shoulder Elbow Surg.* 2003;12(1):69-78.
- Antuña SA, Sperling JW, Sánchez-Sotelo J, Cofield RH. Shoulder arthroplasty for proximal humeral malunions: long-term results. *J Shoulder Elbow Surg.* 2002;11(2):122-9.
- Zhang YZ, Lu S, Chen B, Zhao JM, Liu R, Pei GX. Application of computer-aided design osteotomy template for treatment of cubitus varus deformity in teenagers: a pilot study. *J Shoulder Elbow Surg.* 2011;20(1):51-6.
- Bagaria V, Deshpande S, Rasalkar DD, Kuthe A, Paunipagar BK. Use of rapid prototyping and three-dimensional reconstruction modeling in the management of complex fractures. *Eur J Radiol.* 2011;80(3):814-20.
- Yang JC, Ma XY, Lin J, Wu ZH, Zhang K, Yin QS. Personalised modified osteotomy using computer-aided design-rapid

- prototyping to correct thoracic deformities. *Int Orthop*. 2011;35(12):1827-32.
10. Yang S, Leong KF, Du Z, Chua CK. The design of scaffolds for use in tissue engineering. Part II. Rapid prototyping techniques. *Tissue Eng*. 2002;8(1):1-11.
  11. Lantada AD, Morgado PL. Rapid prototyping for biomedical engineering: current capabilities and challenges. *Annu Rev Biomed Eng*. 2012;14:73-96.
  12. Peng Q, Tang Z, Liu O, Peng Z. Rapid prototyping-assisted maxillofacial reconstruction. *Ann Med*. 2015;47(3):186-208.
  13. Ahn DG, Lee JY, Yang DY. Rapid prototyping and reverse engineering application for orthopedic surgery planning. *J Mech Sci Technol*. 2006;20(1):19-28.
  14. Iannotti JP, Greeson C, Downing D, Sabesan V, Bryan JA. Effect of glenoid deformity on glenoid component placement in primary shoulder arthroplasty. *J Shoulder Elbow Surg*. 2012;21(1):48-55.
  15. Van der Meer WJ, Vissink A, Raghoobar GM, Visser A. Digitally designed surgical guides for placing extraoral implants in the mastoid area. *Int J Oral Maxillofac Implants*. 2012;27(3):703-7.
  16. Schrank ES, Hitch L, Wallace K, Moore R, Stanhope SJ. Assessment of a virtual functional prototyping process for the rapid manufacture of passive-dynamic ankle-foot orthoses. *J Biomech Eng*. 2013;135(10):101011-7.
  17. Mavroidis C, Ranky RG, Sivak ML, Patrilli BL, DiPisa J, Caddle A, et al. Patient specific ankle-foot orthoses using rapid prototyping. *J Neuroeng Rehabil*. 2011;8:1.
  18. Da Rosa EL, Oleskovicz CF, Aragão BN. Rapid prototyping in maxillofacial surgery and traumatology: case report. *Braz Dent J*. 2004;15(3):243-7.
  19. Li MG, Tian XY, Chen XB. A brief review of dispensing-based rapid prototyping techniques in tissue scaffold fabrication: role of modeling on scaffold properties prediction. *Biofabrication*. 2009;1(3):032001.
  20. Brown GA, Firozabakhsh K, DeCoster TA, Reyna JR Jr, Moneim M. Rapid prototyping: the future of trauma surgery? *J Bone Joint Surg Am*. 2003;85 Suppl 4:49-55.
  21. Fogaça ACM, Dreyer J, Júnior AN, Moraes JF, Oliveira MG. Dimensional accuracy of select laser sintering and three-dimensional printing biomodels after autoclaving: a preliminar descriptive study. *Arch Oral Res*. 2011;7(1):27-33.
  22. Kermer C, Lindner A, Friede I, Wagner A, Millesi W. Preoperative stereolithographic model planning for primary reconstruction in craniomaxillofacial trauma surgery. *J Craniomaxillofac Surg*. 1998;26(3):136-9.
  23. Solberg BD, Moon CN, Franco DP, Paiement GD. Surgical treatment of three and four-part proximal humeral fractures. *J Bone Joint Surg Am*. 2009;91(7):1689-97.
  24. Solberg BD, Moon CN, Franco DP, Paiement GD. Locked plating of 3- and 4-part proximal humerus fractures in older patients: the effect of initial fracture pattern on outcome. *J Orthop Trauma*. 2009;23(2):113-9.
  25. Resch H. Proximal humeral fractures: current controversies. *J Shoulder Elbow Surg*. 2011;20(5):827-32.
  26. Kawaguchi Y, Nakano M, Yasuda T, Seki S, Hori T, Kimura T. Development of a new technique for pedicle screw and Magerl screw insertion using a 3-dimensional image guide. *Spine (Phila PA 1976)*. 2012;37(23):1983-8.
  27. Zhang YZ, Chen B, Lu S, Yang Y, Zhao JM, Liu R, et al. Preliminary application of computer-assisted patient-specific acetabular navigational template for total hip arthroplasty in adult single development dysplasia of the hip. *Int J Med Robot*. 2011;7(4):469-74.
  28. Lu S, Zhang YZ, Wang Z, Shi JH, Chen YB, Xu XM, et al. Accuracy and efficacy of thoracic pedicle screws in scoliosis with patient-specific drill template. *Med Biol Eng Comput*. 2012;50(7):751-8.
  29. Morrison DA, Guy DT, Day RE, Lee GY. Simultaneous repair of two large cranial defects using rapid prototyping and custom computer-designed titanium plates: a case report. *Proc Inst Mech Eng H*. 2011;225(11):1108-12.