

# Radiotherapy in aggressive cutaneous pseudolymphoma: a case report and review of literature

Deepa Joseph, MD, Monica Malik Irukulla, MD, Syed Fayaz Ahmed, MD,  
Deepthi Valiyaveetil, MBBS, Syed Akram, MD

Department of Radiation Oncology, Nizam's Institute of Medical Sciences, Hyderabad, India

Pseudolymphoma is a nonspecific disease characterized by lesions with lymphomatous-appearing but benign accumulation of inflammatory cells. They generally present as small ulcero-nodular lesions confined to skin which often respond to local therapies. We describe an unusual presentation of an extensive and locally aggressive cutaneous pseudolymphoma in a 21-year-old male patient who presented with extensive cutaneous eruptions gradually progressing over 6 years to involve the entire circumference of his left arm. Magnetic resonance imaging scans of his left arm showed a lesion deeply infiltrating into the soft tissue reaching up to the humerus with intense periosteal reaction. He was successfully treated with radiotherapy after many failed attempts with surgery and chemotherapy.

**Keywords:** Pseudolymphoma, Radiotherapy

## Introduction

Pseudolymphoma (PSL) is a nonspecific disease characterized by inflammatory response to known or unknown stimuli that result in a lymphomatous-appearing but benign accumulation of inflammatory cells [1]. It is a reactive process and usually has a benign course. Cutaneous pseudolymphoma (CPSL) has been described under various terminologies like sarcomatosis cutis, lymphocytoma cutis, lymphadenosis benigna cutis, pseudolymphoma of Spiegler and Fendt, cutaneous lymphoid hyperplasia and actinic reticuloid [1]. Most cases are idiopathic. Cases with known etiologies include reaction to tattoo dye or gold and other jewelry, arthropod bites, infection with *Borrelia burgdorferi* or molluscum contagiosum, leishmaniasis, vaccinations and acupuncture [2]. It has also been linked to certain drugs like anticonvulsants, antipsychotics, antihypertensives, cytotoxics, antirheumatics, antibiotics,

antidepressants, anxiolytics, antihistamines, antiarrhythmics, sex steroids, and lipid lowering agents [1]. There are recent case reports implicating drugs like infliximab [3], zoledronic acid [4] etc. as the causative agents. CD8 positive CPSL has also been reported in human immunodeficiency virus (HIV) positive patients [5]. Pseudolymphomas have been described in various other sites and organs including eye, parotid gland, larynx, gastrointestinal tract, lung, tongue [6], orbit [7], kidney [8], breast [9] etc. We describe an unusual presentation of an extensive and locally aggressive CPSL in a young patient and his successful treatment with radiation therapy.

## Case Report

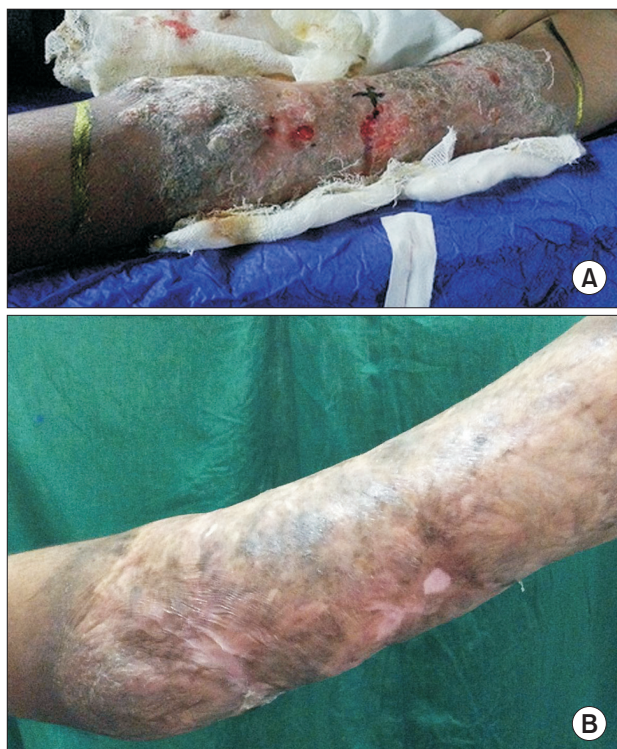A 21-year-old male presented with diffuse lesions over his left upper limb involving the full circumference of his arm extending till the elbow (Fig. 1A). The lesions initially started

Received 1 November 2015, Revised 12 January 2016, Accepted 16 February 2016.

Correspondence: Deepa Joseph, MD, Department of Radiation Oncology, Nizam's Institute of Medical Sciences, Punjagutta, Hyderabad, Telangana 500082, India. Tel: +91-4023489354, E-mail: drdeepajoseph@yahoo.com

© This is an Open Access article distributed under the terms of the Creative Commons Attribution Non-Commercial License (<http://creativecommons.org/licenses/by-nc/4.0/>) which permits unrestricted non-commercial use, distribution, and reproduction in any medium, provided the original work is properly cited.

[www.e-roj.org](http://www.e-roj.org)

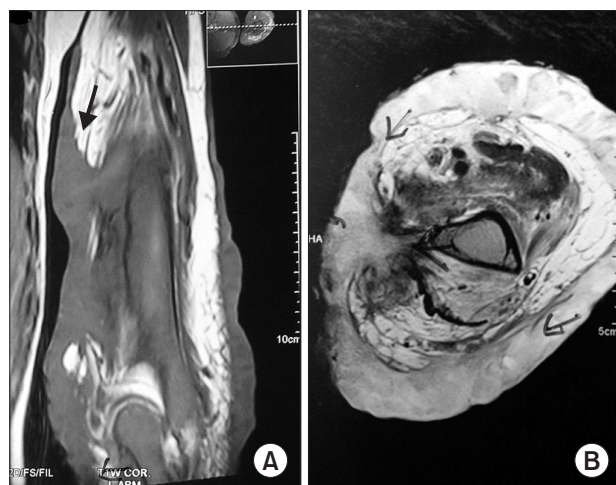

**Fig. 1.** (A) Pre-treatment photograph showing involvement of the entire circumference of the arm with extensive ulcero-nodular skin lesions with diffuse scaling, bleeding and crust formation. (B) Post-treatment photograph showing complete resolution of the skin lesions.

as a small nodule first noticed by him about 6 years ago and recurred despite repeated excisions, each recurrence being more extensive and aggressive than the previous. Histopathological evaluation suggested nonspecific inflammatory lesions. There was no history of any precipitating factors.

On evaluation, magnetic resonance imaging of the left upper limb revealed a fairly large, locally invasive cutaneous and subcutaneous lesion along the middle and lower third of left upper arm. Medially the lesion was insinuating between brachialis and triceps brachii muscle up to the shaft of the humerus with dense periosteal thickening. He also had associated atrophic changes in the muscles of the upper arm (Fig. 2).

Excision of the lesion with skin grafting was performed. Histopathological examination of the excised specimen revealed regular acanthosis of keratinized stratified squamous epithelium with elongation of rete pegs. Superficial dermis showed diffuse infiltrate with inflammatory cells. Deep dermis showed sheets of lymphoid aggregates along with tangible body macrophages. There was destruction of adnexal

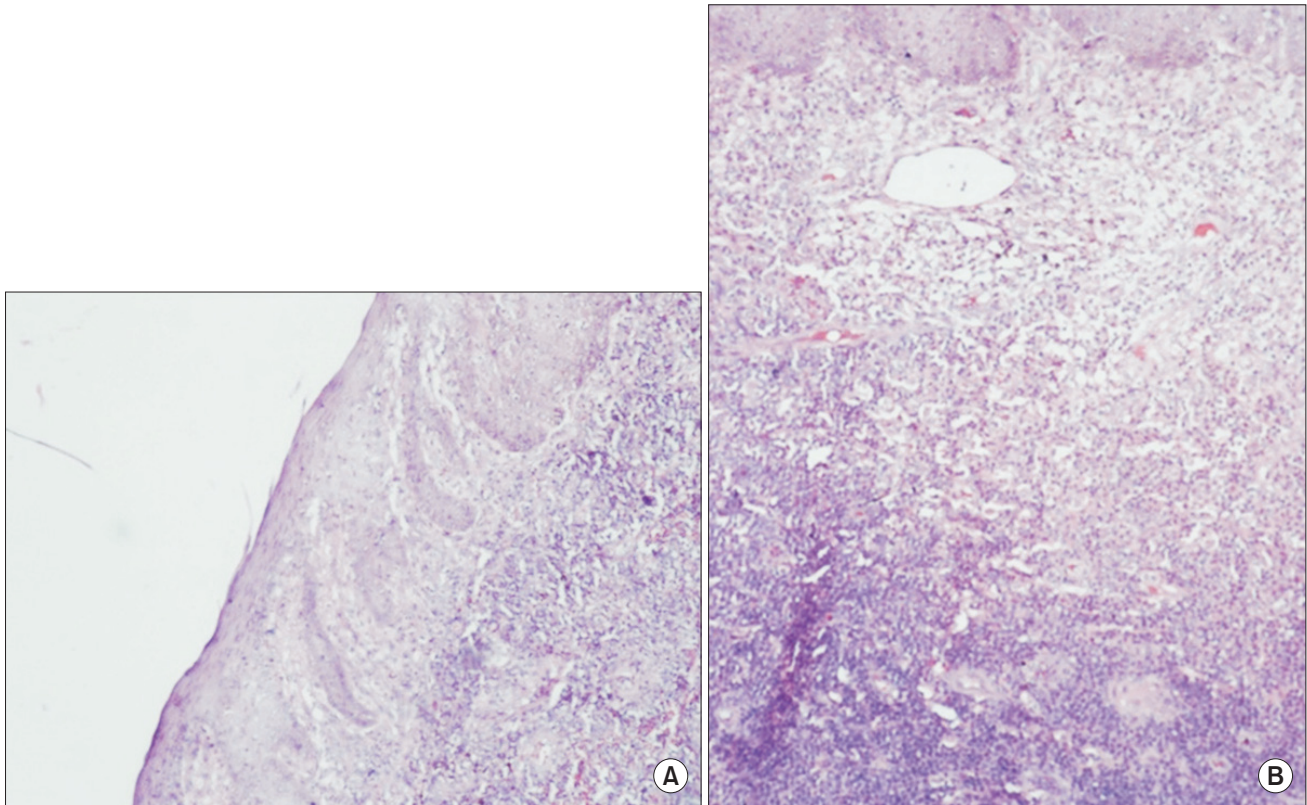


**Fig. 2.** (A) Coronal (T1-weighted) and (B) axial (T2-weighted) magnetic resonance images showing locally invasive cutaneous and subcutaneous lesion along the middle and lower third of left upper arm reaching up to the shaft of the humerus with dense periosteal thickening.

structures. Immuno-histochemical (IHC) studies showed CD3 positivity in most of the cells, CD20 was focally positive, CD30 was negative and a Ki-67 was 1% (Fig. 3). Hence he was diagnosed with CPSL with predominant T-cell infiltrate. His bone marrow biopsy revealed a reactive marrow. Chest and abdominal imaging were normal except for mild splenomegaly. Blood counts and chemistries were normal. Post-excision, the lesions recurred within 2–3 weeks and progressed rapidly to involve the entire circumference of the arm.

Subsequently, he was treated with chemotherapy with oral cyclophosphamide and prednisolone for 4 months followed by maintenance prednisolone for a total of 9 months. Response to chemotherapy was partial and lesions progressed on withdrawal of chemotherapy. There was no significant response to steroids alone. He was referred for radiation oncology opinion in view of rapid progression after stopping chemotherapy. Clinical examination at that time revealed extensive skin lesions involving the entire left upper arm, extending from the level of deltoid insertion superiorly to the elbow inferiorly. Lesions were diffuse, erythematous, ulcero-nodular with foul smelling seropurulent discharge, bleeding and crust formation. Range of motion at the elbow joint was significantly reduced. Skin over the rest of his body was normal. He was in severe psychological distress due to the nonhealing extensive skin lesions and the associated disability.

He was treated with radiation therapy to a total dose of 30 Gy in 15 fractions to the left arm. Radiation portals covered



**Fig. 3.** (A) Section shows skin with focal ulceration and acanthosis. Dermis shows diffuse inflammatory infiltrate (H&E, 100 $\times$ ). (B) Section shows dense infiltrate composed of lymphocytes, histiocytes, eosinophils, mast cells and neutrophils, along with foreign-body type giant cells (H&E, 100 $\times$ ).

the entire involved area with 2-cm superoinferior margins. Treatment was delivered with 6 MV photons using parallel opposed fields of size 34 cm  $\times$  11 cm. During radiation, the lesions initially showed increased erythema and edema with spontaneous bleeding which subsided over 3 weeks. The seropurulent discharge gradually subsided and the treated area was replaced with healthy granulation tissue. There was near complete healing of the affected part, with few areas of scarring, over a period of 6 months (Fig. 1B). The range of motion at the elbow improved considerably. At 26 months following radiation, he had no signs of recurrence and was able to do active work.

## Discussion

CPSL most often presents as a solitary nodule that can range from red brown to violaceous in color with a doughy to firm consistency. Other presentations include localized arrays of nodules, plaques or papules and rarely generalized forms [10]. These lesions are generally confined to skin and do not invade

into the deeper planes [11].

Pathologically, CPSL is classified into ordinary PSL (O-PSL), PSL with predominant B-cell infiltrates (B-PSL), PSL with predominant T-cell infiltrates (T-PSL) and PSL with mixed and unclassified infiltrates [12]. Our patient had a predominant T-cell infiltrate in his lesions. CPSL is differentiated from cutaneous lymphoma based on the pathological appearance, IHC studies and/or molecular analysis and absence of systemic B symptoms. There have been suggestions to rename this entity as lymphoproliferations of undetermined significance as the terminology is ambiguous in some parts of the world [13].

CPSL lesions are known to regress spontaneously on removal of the known triggering factors. Many cases have been reported to resolve with a short course of topical/systemic steroids. Due to the heterogeneous presentations and clinical behaviors, optimal therapy remains unclear. Persistent disease has been managed with various modalities including local therapies like surgical excision, laser removal, cryosurgery or intralesional corticosteroids [14]. CPSL has also been treated with immunomodulatory agents such as



steroids, interferon  $\alpha$ -2b [15], antimalarials, cephalosporins, and minocycline [2]. There are case reports of successful treatment with thalidomide [16], methotrexate [5], amoxicillin [17], cyclosporine, etc. Photodynamic therapy has also been used in the treatment of this condition [18]. Our case was highly unusual due to the aggressive course with extensive destruction of skin and involvement of deeper tissues up to the periosteum. Only one other case report describes a 63-year-old female with an eruption over the thigh following a presumed insect bite with histological and IHC features suggestive of CPSL with deep subcutaneous involvement [19].

Radiation therapy has been occasionally offered to patients who failed with other modalities. Due to the rarity of the condition, optimal radiation dose in CPSL remains unclear. Relatively lower doses in the range of 15–30 Gy have led to effective control rates. In a series by Olson et al. [20], patients were successfully treated with doses of 15 to 18 Gy. Curative radiation dose for orbital pseudolymphoma has been described as 16 to 20 Gy [7]. Taylor et al. [2] reported a case of CPSL which recurred after radiation therapy with 20 Gy in 10 fractions and was successfully treated with a second course of radiation to a dose of 36 Gy in 18 fractions. Our patient was treated with 30 Gy in 15 fractions following which he had complete and sustained remission with healing of the affected area. Generally patients are treated with electron beam therapy. Since our patient had deep invasion reaching up to the bone, he was treated with 6 MV photons.

Patients should be watched for a rare possibility of progression to cutaneous lymphoma. A series of four cases of CPSL transforming to cutaneous B-cell lymphoma has been reported by Kulow et al. [21].

In conclusion, CPSL generally presents as small ulceronodular lesions confined to skin which follow a benign course. The lesion(s) may regress spontaneously on removal of the triggering factor. Most lesions subside with local therapies or systemic steroids. Immunomodulator drugs have also been used successfully. Persistent, refractory CPSL with locally aggressive behavior and deep soft tissue infiltration is extremely rare. The inflammatory infiltrates are usually highly sensitive to radiation and low doses of radiation therapy have been shown to effectively control the disease. Radiation therapy may be a good option in patients with persistent or aggressive lesions who do not respond to other treatment modalities.

## Conflict of Interest

No potential conflict of interest relevant to this article was reported.

## References

1. Ploysangam T, Breneman DL, Mutasim DF. Cutaneous pseudolymphomas. *J Am Acad Dermatol* 1998;38(6 Pt 1):877-95.
2. Taylor RB, Fortney JA, Pollack RB, Metcalf JS, Jenrette JM. Radiation therapy for B-cell cutaneous lymphoid hyperplasia. *Jpn J Radiol* 2010;28:385-7.
3. Safa G, Luce K, Darrieux L, Tisseau L, Ortonne N. Erythrodermic CD8+ pseudolymphoma during infliximab treatment in a patient with psoriasis: use of cyclosporine as a rescue therapy. *J Am Acad Dermatol* 2014;71:e149-50.
4. Kitagawa KH, Grassi M. Zoledronic acid-induced cutaneous B-cell pseudolymphoma. *J Am Acad Dermatol* 2011;65:1238-40.
5. Ingen-Housz-Oro S, Sbidian E, Ortonne N, et al. HIV-related CD8+ cutaneous pseudolymphoma: efficacy of methotrexate. *Dermatology* 2013;226:15-8.
6. Robbins R, Peale AR, al-Saleem T. Pseudolymphomas. *Am J Roentgenol Radium Ther Nucl Med* 1970;108:149-53.
7. Gordon PS, Juillard GJ, Selch MT, Parker RG, Fu YS. Orbital lymphomas and pseudolymphomas: treatment with radiation therapy. *Radiology* 1986;159:797-9.
8. Fukuda H, Inoue Y, Nishimura Y, Takashi R. Pseudolymphoma of the kidney: a case report. *J Urol* 1995;153:387-8.
9. Lin JJ, Farha GJ, Taylor RJ. Pseudolymphoma of the breast. I: in a study of 8,654 consecutive tylectomies and mastectomies. *Cancer* 1980;45:973-8.
10. Wood GS. Inflammatory diseases that simulate lymphomas: cutaneous pseudolymphomas. In: Goldsmith LA, Katz SI, Gilchrist BA, Paller AS, Leffell DJ, Wolff K, editors. *Fitzpatrick's dermatology in general medicine*. 8th ed. New York, NY: McGraw-Hill Companies, Inc; 2012.
11. Kerl H, Fink-Puches R, Cerroni L. Diagnostic criteria of primary cutaneous B-cell lymphomas and pseudolymphomas. *Keio J Med* 2001;50:269-73.
12. Terada T. Cutaneous pseudolymphoma: a case report with an immunohistochemical study. *Int J Clin Exp Pathol* 2013;6:966-72.
13. Levy E, Godet J, Cribier B, Lipsker D. Pseudolymphoma of the skin: ambiguous terminology: a survey among dermatologists and pathologists. *Ann Dermatol Venereol* 2013;140:105-11.
14. Kluger N, Vermeulen C, Moguelet P, et al. Cutaneous lymphoid hyperplasia (pseudolymphoma) in tattoos: a case series of seven patients. *J Eur Acad Dermatol Venereol* 2010;24:208-13.

15. Tomar S, Stoll HL, Grassi MA, Cheney R. Treatment of cutaneous pseudolymphoma with interferon alfa-2b. *J Am Acad Dermatol* 2009;60:172-4.
16. Benchikhi H, Bodemer C, Fraitag S, et al. Treatment of cutaneous lymphoid hyperplasia with thalidomide: report of two cases. *J Am Acad Dermatol* 1999;40(6 Pt 1):1005-7.
17. Ohzono A, Tsuruta D, Hashikawa K, et al. Three cases of pseudolymphoma successfully treated with amoxicillin. *Eur J Dermatol* 2013;23:717-8.
18. Mikasa K, Watanabe D, Kondo C, Tamada Y, Matsumoto Y. Topical 5-aminolevulinic acid-based photodynamic therapy for the treatment of a patient with cutaneous pseudolymphoma. *J Am Acad Dermatol* 2005;53:911-2.
19. Gosain AK, Drolet BA, Neuburg M, Whittaker MH. Cutaneous pseudolymphoma: an unusual presentation of a deep subcutaneous thigh mass. *Ann Plast Surg* 1995;35:541-5.
20. Olson LE, Wilson JF, Cox JD. Cutaneous lymphoid hyperplasia: results of radiation therapy. *Radiology* 1985;155:507-9.
21. Kulow BF, Cualing H, Steele P, et al. Progression of cutaneous B-cell pseudolymphoma to cutaneous B-cell lymphoma. *J Cutan Med Surg* 2002;6:519-28.