



## NOTE

Pathology

# Immunohistochemical studies on meningoencephalitis in feline infectious peritonitis (FIP)

Huanan WANG<sup>1,2</sup>#, Miyuki HIRABAYASHI<sup>1</sup>#, James K. CHAMBERS<sup>1</sup>,  
Kazuyuki UCHIDA<sup>1</sup>\* and Hiroyuki NAKAYAMA<sup>1</sup><sup>1</sup>Laboratory of Veterinary Pathology, Graduate School of Agricultural and Life Sciences, The University of Tokyo, 1-1-1 Yayoi, Bunkyo-ku, Tokyo 113-8657, Japan<sup>2</sup>Department of Veterinary Medicine, College of Animal Sciences, Zhejiang University, 866 Yuhangtang Road, Xihu, Hangzhou, 310058, China*J. Vet. Med. Sci.*

80(12): 1813–1817, 2018

doi: 10.1292/jvms.18-0406

Received: 12 July 2018

Accepted: 8 October 2018

Published online in J-STAGE:  
17 October 2018

**ABSTRACT.** The present study describes the association between inflammatory cell types and feline infectious peritonitis virus (FIPV) antigen in the brain of 4 cats diagnosed as feline infectious peritonitis (FIP). Immunohistochemically, FIPV antigens were detected in the inflammatory foci of the leptomeninges, choroid plexus and ventricles in 3 of the 4 cats. In 3 cases, inflammatory foci mainly consisted of CD204- and Iba1-positive macrophages, and the FIPV antigens were found in the macrophages. In the other case which was negative for FIPV antigen, severe inflammation predominantly consisting of CD20-positive B lymphocytes was observed in the leptomeninges and subventricles, accompanied with diffuse proliferation of gemistocytic astrocytes. The difference in histopathology may reflect the inflammatory process or the strain variation of FIP virus.

**KEY WORDS:** feline infectious peritonitis, macrophage, meningoencephalitis

Feline infectious peritonitis (FIP) is a widely distributed infectious disease caused by feline coronavirus (FCoV) in domestic and wild cat species [1, 2, 11, 13]. FCoV consists of two biotypes including feline enteric coronavirus (FECV) and FIP virus (FIPV). FECV infection is asymptomatic or exclusively causes mild gastrointestinal clinical symptoms, while FIPV causes fatal symptoms such as fever, anorexia, weight loss, abdominal distention and neurological symptoms in young cats [2, 13]. The clinical symptoms differ depending on the form and organ distribution of the lesion, and in cases with lesions in central nervous system, neurological symptoms such as depression, ataxia and seizures appear in 85% of cases [15]. It was assumed that FIPV originating from FECV acquired its monocyte- or macrophage- tropism responsible for viral dissemination and developed specific FIP lesions due to vasculitis [17, 18].

The FIP lesions are characterized by localized or disseminated fibrinous, pyogranulomatous, or granulomatous inflammation with protein-rich effusion in the body cavities [9, 10]. These lesions are often accompanied with granulomatous or necrotizing phlebitis and/or periphlebitis, which have been considered as a typical hallmark of FIP [3, 10]. Lesions in the central nervous system (CNS) are frequently observed mainly in the leptomeninges, ventricles, choroid plexus and sometimes neuroparenchyma [5, 12, 16]. Although histopathological features of FIP lesions in the CNS have been well documented [6, 14, 15], the association between inflammatory cell types and the distribution of viral antigens remains to be clarified. The present study describes the inflammatory cell types and viral antigen distribution in the brain lesions of 4 cats diagnosed as FIP. Also, considering that the FIPV has monocyte and macrophage tropism, immunohistochemical examinations were performed using two kinds of macrophage markers: CD204 (monocyte and macrophage marker) and Iba-1 (microglia and macrophage marker).

Four necropsy cases of cats diagnosed as FIP were obtained from the specimen archives of the Laboratory of Veterinary Pathology, Graduate School of Agricultural and Life Sciences, the University of Tokyo. Diagnoses of FIP were mainly based on clinical history, physical examination findings, general blood chemistry and antibody titer for FCoV antigen. Final diagnoses were based on gross findings at necropsy and histopathological findings. Information of the 4 cases, including age, sex, major clinical signs, the antibody titer of FCoV and organs with histologically severe inflammatory lesions is summarized in Table 1. The cats died at the age of 6 months (Case Nos. 3 and 4), 8 months (Case No. 2) and 7 years (Case No. 1), respectively. The main neurological sign was ataxia (Case Nos. 1 and 4). Three cats (Case Nos. 2, 3 and 4) had fluid accumulation in the peritoneal and pleural cavities (effusive FIP). In Case No. 1, there was no fluid accumulation in the peritoneal and pleural cavities (non-effusive

\*Correspondence to: Uchida, K.: auchidak@mail.ecc.u-tokyo.ac.jp

#These authors contributed equally to this work.

©2018 The Japanese Society of Veterinary Science

This is an open-access article distributed under the terms of the Creative Commons Attribution Non-Commercial No Derivatives (by-nc-nd) License. (CC-BY-NC-ND 4.0: <https://creativecommons.org/licenses/by-nc-nd/4.0/>)

**Table 1.** Clinical and pathological information on cats examined

Case No.	Breed	Age	Sex	Clinical signs	FIP disease type	Antibody titer of FCoV <sup>a)</sup>	Organs with severe inflammatory lesions
1	Birman	7 y	F	Ataxia, loss of appetite	Non-effusive	NE	Brain, lung, liver, kidneys, adrenal glands
2	Exotic short hair	8 m	M	Dyspnea, loss of appetite, abdominal distension	Effusive	NE	Brain, lung, liver, spleen
3	Mix	6 m	M	Disappearance, loss of appetite, abdominal distension	Effusive	6,400	Brain, lung, kidneys, eyes
4	Rossian blue	6 m	F	Ataxia	Effusive	400	Brain, spinal cord, pancreas

y, years; m, months; F, female; M, male; NE, not examined. a) In the presence of clinical signs, titers greater than 100 indicate FIP infection.

**Table 2.** Primary antibodies and antigen retrieval methods used in the present study

Antibody to	Type <sup>a)</sup>	Dilution	Manufacturer	Antigen retrieval
FCoV (FIPV3-70)	mAb	1:100	Bio-Rad (Hercules, CA, U.S.A.)	Heat (121°C, 10 min), citrate buffer, pH6.0
Iba-1	pAb	1:250	Wako (Osaka, Japan)	Heat (121°C, 10 min), citrate buffer, pH6.0
CD204	mAb	1:50	Trans Genic (Kobe, Japan)	Heat (121°C, 10 min), target retrieval solution, pH9.0
GFAP	pAb	1:1,000	Doko Japan (Tokyo, Japan)	None
CD3	mAb	Ready to use	Dako Japan (Tokyo, Japan)	Heat (121°C, 10 min), citrate buffer, pH6.0
CD20	pAb	1:100	Thermo Fisher Scientific (Waltham, MA, U.S.A.)	Heat (121°C, 10 min), citrate buffer, pH6.0

a) pAb, polyclonal antibody; mAb: monoclonal antibody.

FIP). For case Nos. 3 and 4, the antibody titer of FCoV was elevated (FIP: >100).

All tissues were fixed in 10% neutral-buffered formalin, routinely processed and embedded in paraffin wax. Tissue sections of 4  $\mu$ m-thick were stained with hematoxylin and eosin (HE). Selected brain sections were subjected to immunohistochemical examinations. Normal feline brain tissue was also stained as a control. Deparaffinized and rehydrated sections were treated through the antigen retrieval methods listed in Table 2. After being immersed in 3% hydrogen peroxide in methanol at room temperature for 5 min, the sections were treated with 8% skim milk at 37°C for 40 min. The sections were then incubated with the primary antibodies listed in Table 2 at 4°C overnight, and then incubated with the Dako EnVision + System horseradish peroxidase (HRP)-labelled anti-rabbit (Dako-Japan, Tokyo, Japan) or anti-mouse secondary antibodies (Dako-Japan) at 37°C for 40 min. The antigen-antibody reaction was visualized with 0.05% 3,3'-diaminobenzidine and 0.03% hydrogen peroxide in tris-hydrochloric buffer. Counterstaining was performed with hematoxylin.

Inflammatory changes were observed in the brain and spinal cord of all the 4 cases. They were located in the leptomeninges (Fig. 1a), choroid plexus (Fig. 1c) and subventricular area (Fig. 1e) of the lateral, third and fourth ventricles (Table 3). These inflammatory lesions were characterized by perivascular accumulations of inflammatory cells, and the inflammatory cells consisted of macrophages, lymphocytes, plasma cells and neutrophils. Some macrophages showed an epithelioid cell morphology, forming granulomatous lesions. In all cases there were no notable neuronal degeneration or glial nodules in the brain parenchyma.

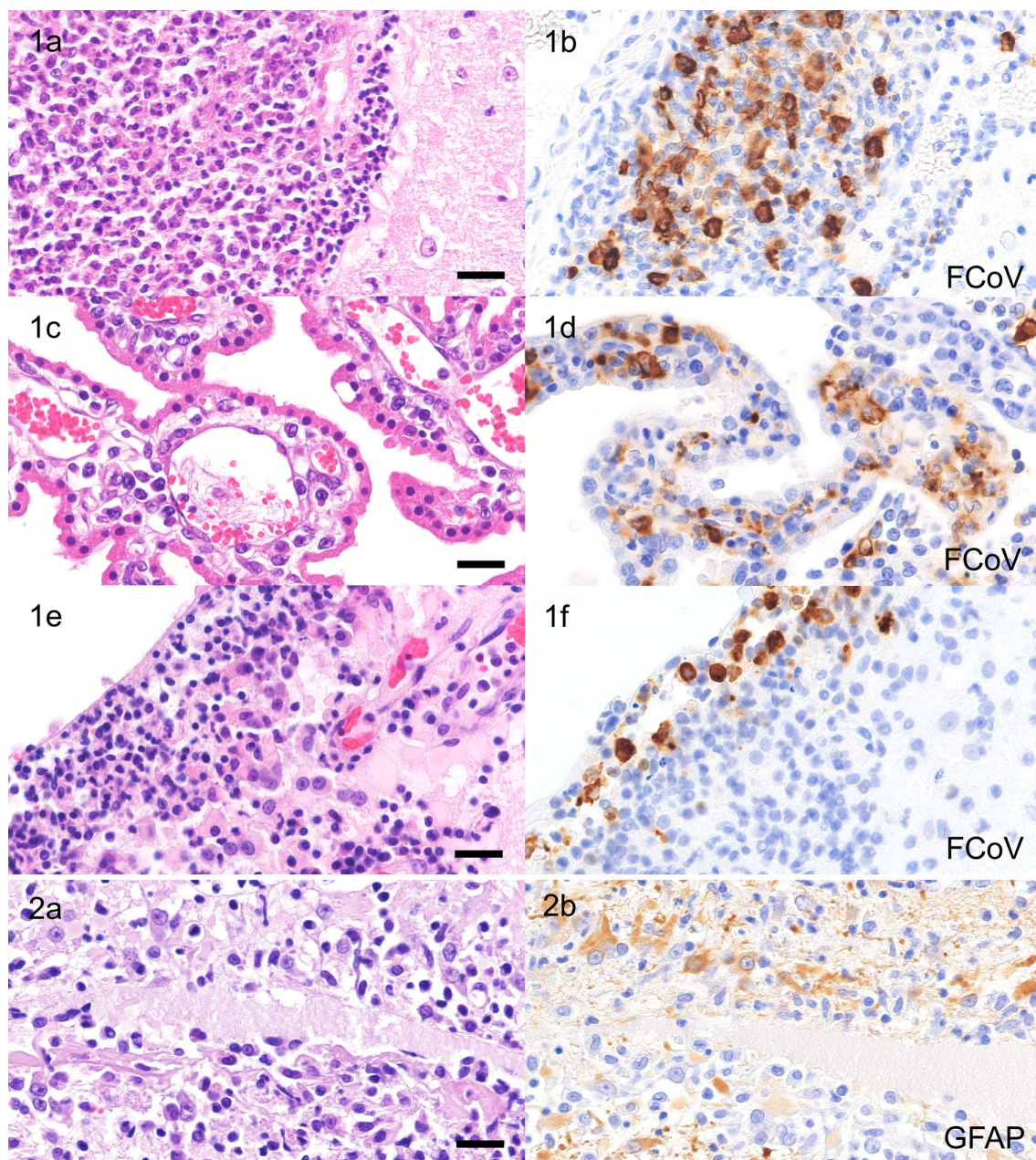
In the three cases (Case Nos. 1 to 3), viral antigens were detected within the inflammatory foci but not in the brain parenchymal cells including neurons and glial cells (Figs. 1b, 1d and 1f). On the other hand, in case No. 4, viral antigens were observed neither in the inflammatory foci nor brain parenchyma (Table 3). Further differently, in three of the 4 cases (Case Nos. 1 to 3), brain parenchymal lesions were not evident, while in case No. 4, glial fibrillary acidic protein (GFAP)-positive gemistocytic astrocytes proliferated diffusely in the subventricular parenchyma adjacent to severe inflammatory lesions (Fig. 2a and 2b).

In Case Nos. 1 (Fig. 3a–f), 2 and 3, viral antigens (Fig. 3b) were scattered within the perivascular area where a large number of Iba1- and CD204-positive macrophages accumulated (Fig. 3c and 3d). Besides, a moderate number of CD20-positive B lymphocytes accumulated around the glia limitans adjacent to the inflammatory foci (Fig. 3e). A few CD3-positive T lymphocytes were diffusely observed in the foci (Fig. 3f). Neutrophils were observed in various degrees.

In contrast, in case No. 4, Iba1- and CD204-positive macrophages were sparsely scattered in the inflammatory foci (Fig. 4a, 4c and 4d) without a distinct granuloma formation. No FIPV antigens were detected in the foci (Fig. 4b). A large number of CD20-positive B lymphocytes accumulated mainly in the perivascular areas (Fig. 4e). The distribution pattern of CD3-positive T lymphocytes was similar to those of the other three cases (Fig. 4f). Neutrophils were observed in various degrees.

In addition to brain lesions, severe inflammatory lesions were observed in the lung (Case Nos. 1 to 3), liver (Case Nos. 1 and 2), pancreas (Case No. 4), spleen (Case No. 2), kidney (Case Nos. 1 and 3), adrenal glands (Case No. 1) and eyes (Case No. 3) (Table 1). The type of inflammatory cells in each organ were similar to the brain. Inflammation was also found in adipose tissue and serosa of the thoracic and abdominal organs for Case Nos. 2 and 3, and of the abdominal organs for Case No. 4.

In the present study, all the 4 cases examined were diagnosed as FIP based on the clinical and pathologic findings. Viral antigens were detected in macrophages around vessels of the lesions in the leptomeninges and subventricles of Case Nos. 1 to 3. These findings were in conformity with those in a recent report on FIP meningoencephalitis [15]. On the other hand, viral antigen was not



**Fig. 1.** Inflammatory lesions (a, c and e) and distribution of viral antigens (b, d and f) in the cerebral leptomeninges (a and b), choroid plexus (c and d) and lateral ventricle (e and f). Case Nos. 1 to 3. HE stain (a, c and e) and immunohistochemistry for FCoV antigen (b, d and f). Bar=20  $\mu$ m.

**Fig. 2.** Severe inflammation (a) and proliferation of gemistocytic astrocytes (b) in the subventricular lesion of the cerebrum. Case No. 4. HE stain (a) and immunohistochemistry for GFAP (b). Bar=20  $\mu$ m.

detected in the brain of Case No. 4, though the cat was clinically diagnosed as FIP because of neurological symptoms and elevated antibody titer of FCoV.

Pathological diagnosis of FIP is mainly performed by immunofluorescence (IF) using fresh tissues or immunohistochemistry on formalin-fixed paraffin sections [7]. Immunohistochemistry was believed to be more specific than IF [15], while some previous reports also raised questions about its specificity [4]. The antibody used in this study, FIPV3-70, is known to react with the nucleocapsid antigen of FIPV and is considered a valuable diagnostic tool for FIP [8]. However, a previous paper demonstrated antigenic heterogeneity in FIPV nucleocapsid proteins [14]. Thus, it is possible that the difference in FIPV antigen type cause the lack of viral antigen in lesions of Case No. 4.

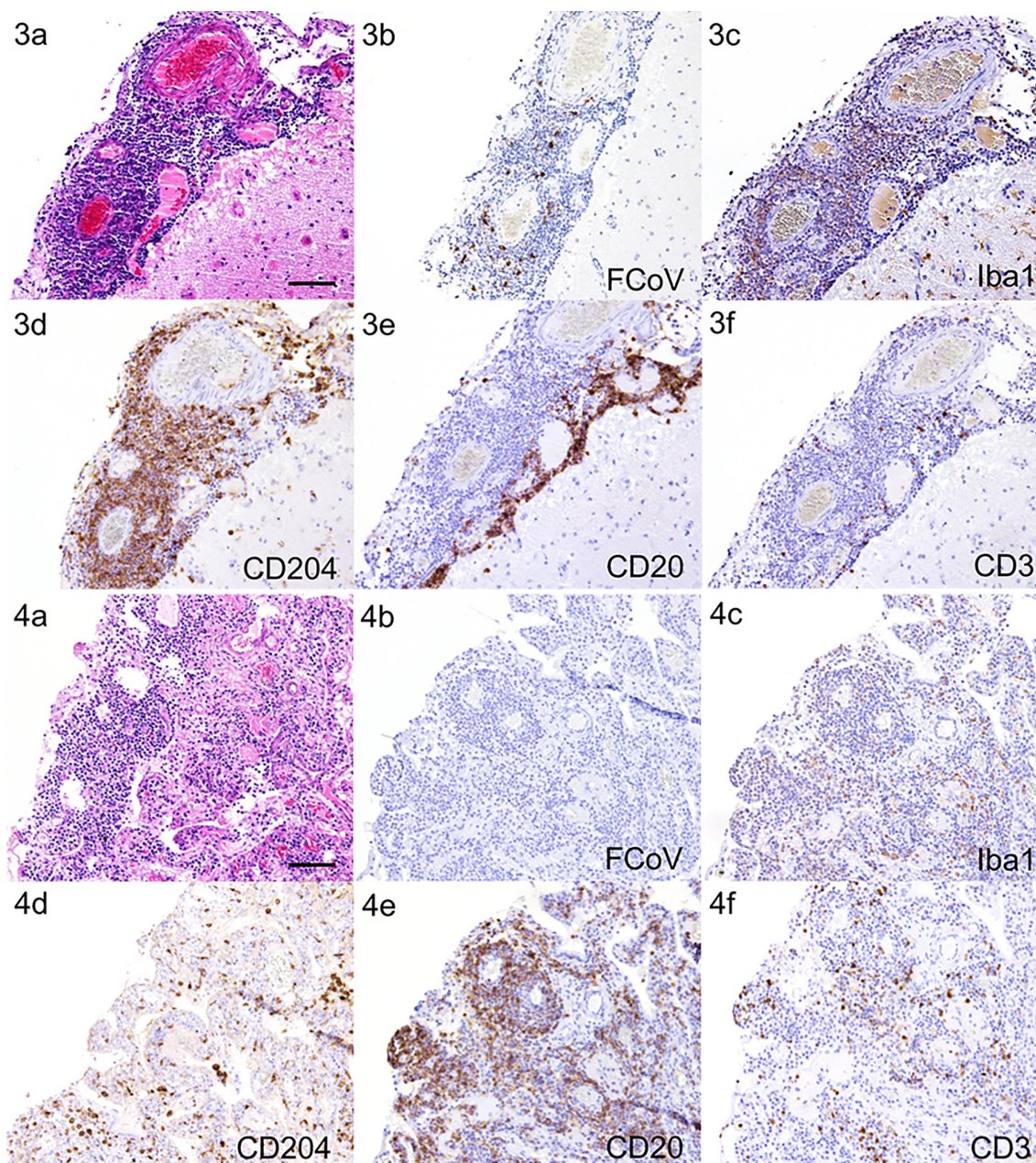
For the constitution of inflammatory cells in the lesion, CD204- and/or Iba1-positive macrophages, CD20-positive B cells, CD3-positive T lymphocytes and neutrophils were detected in all 4 cases with various severities.

In three cases (Case Nos. 1 to 3), the majority of inflammatory cells was CD204- and/or Iba1-positive macrophages and a

**Table 3.** Distribution of inflammatory lesions and viral antigens in the brain

Case No.	Cerebrum					Cerebellum, pons and medulla oblongata			
	Leptomeninges	Parenchyma	CP	LV	III	Leptomeninge	Parenchyma	CP	IV
1	+/- <sup>a)</sup>	-/-	-/+	-/+	-/-	+/+	-/-	+/+	+/+
2	-/+	-/-	-/+	-/+	-/-	-/+	-/-	+/+	-/+
3	+/+	-/-	+/+	+/+	+/+	+/+	-/-	+/+	+/+
4	+/-	+/-	+/-	+/-	+/-	+/-	-/-	+/-	+/-

CP, choroid plexus; LV, lateral ventricle; III, third ventricle; IV, fourth ventricle. a) Result are represented as inflammatory changes/viral antigens: +, present; -, absent.



**Fig. 3.** Inflammatory foci of the cerebral leptomeninges. Case No. 1. HE stain (a) and immunohistochemistry for FCoV (b), Iba1 (c), CD204 (d), CD20 (e) and CD3 (f). Viral antigens (b) are distributed within the foci of CD204- and Iba1-positive macrophage accumulation (c and d). A quite number of CD20-positive B cells are located along the glial limitans (e). CD3-positive T lymphocytes are a minor population. Bar=100  $\mu$ m.

**Fig. 4.** Inflammatory foci of the cerebral leptomeninges. Case No. 4. HE stain (a) and immunohistochemistry for FCoV (b), Iba1 (c), CD204 (d), CD20 (e) and CD3 (f). No viral antigens were detected in the lesion of the case (b). CD204- and Iba1-positive macrophages are scattered (c and d). CD20-positive B cells are most predominant (e). CD3-positive T lymphocytes are a minor population (f). Bar=100  $\mu$ m.

moderate number of CD20-positive B lymphocytes accumulated around the glia limitans adjacent to the inflammatory foci. On the contrary, in Case No. 4, the majority of the inflammatory cells was CD20-positive B lymphocytes and moderate to severe diffuse GFAP-positive astrogliosis in the subventricular lesions was also observed adjacent to inflammatory foci. Similar astrocytic response together with microglial reaction have been reported also in previous FIP cases [12].

In a previous study on FIP, it was reported that viral antigens were detected in macrophage dominant lesions, and B lymphocytes and plasma cells which were positive for coronavirus-specific antibodies were observed as bands around or the basal side of the lesion. On the other hand, viral antigens were rarely detected in B lymphocytes and plasma cells dominant lesions. B lymphocytes and plasma cells are considered to induce FIP virus-specific immune responses and be replaced by macrophages [8, 9].

Therefore, in the present study, the lesion of Case No.4 with abundant CD20-positive B lymphocytes and GFAP-positive astrocytes was considered to be a subacute to chronic stage lesion of FIP that lacked active virus replication.

**ACKNOWLEDGMENT.** The authors would like to express sincere gratitude to The Japan Veterinary Medical Association for giving Huanan WANG the opportunity to join the research work.

## REFERENCES

1. Addie, D., Belák, S., Boucraut-Baralon, C., Egberink, H., Frymus, T., Gruffydd-Jones, T., Hartmann, K., Hosie, M. J., Lloret, A., Lutz, H., Marsilio, F., Pennisi, M. G., Radford, A. D., Thiry, E., Truyen, U. and Horzinek, M. C. 2009. Feline infectious peritonitis. ABCD guidelines on prevention and management. *J. Feline Med. Surg.* **11**: 594–604. [Medline] [CrossRef]
2. Addie, D. D., Toth, S., Murray, G. D. and Jarrett, O. 1995. Risk of feline infectious peritonitis in cats naturally infected with feline coronavirus. *Am. J. Vet. Res.* **56**: 429–434. [Medline]
3. Bauer, B. S., Kerr, M. E., Sandmeyer, L. S. and Grahn, B. H. 2013. Positive immunostaining for feline infectious peritonitis (FIP) in a Sphinx cat with cutaneous lesions and bilateral panuveitis. *Vet. Ophthalmol.* **16** Suppl 1: 160–163. [Medline] [CrossRef]
4. Felten, S., Matiasek, K., Gruendl, S., Sangl, L., Wess, G. and Hartmann, K. 2017. Investigation into the utility of an immunocytochemical assay in body cavity effusions for diagnosis of feline infectious peritonitis. *J. Feline Med. Surg.* **19**: 410–418. [Medline] [CrossRef]
5. Foley, J. E., Lapointe, J. M., Koblik, P., Poland, A. and Pedersen, N. C. 1998. Diagnostic features of clinical neurologic feline infectious peritonitis. *J. Vet. Intern. Med.* **12**: 415–423. [Medline] [CrossRef]
6. Foley, J. E. and Leutenegger, C. 2001. A review of coronavirus infection in the central nervous system of cats and mice. *J. Vet. Intern. Med.* **15**: 438–444. [Medline] [CrossRef]
7. Giori, L., Giordano, A., Giudice, C., Grieco, V. and Paltrinieri, S. 2011. Performances of different diagnostic tests for feline infectious peritonitis in challenging clinical cases. *J. Small Anim. Pract.* **52**: 152–157. [Medline] [CrossRef]
8. Kipar, A., Bellmann, S., Kremendahl, J., Köhler, K. and Reinacher, M. 1998. Cellular composition, coronavirus antigen expression and production of specific antibodies in lesions in feline infectious peritonitis. *Vet. Immunol. Immunopathol.* **65**: 243–257. [Medline] [CrossRef]
9. Kipar, A., May, H., Menger, S., Weber, M., Leukert, W. and Reinacher, M. 2005. Morphologic features and development of granulomatous vasculitis in feline infectious peritonitis. *Vet. Pathol.* **42**: 321–330. [Medline] [CrossRef]
10. Kipar, A. and Meli, M. L. 2014. Feline infectious peritonitis: still an enigma? *Vet. Pathol.* **51**: 505–526. [Medline] [CrossRef]
11. Leutenegger, C. M., Hofmann-Lehmann, R., Riols, C., Liberek, M., Worel, G., Lups, P., Fehr, D., Hartmann, M., Weilenmann, P. and Lutz, H. 1999. Viral infections in free-living populations of the European wildcat. *J. Wildl. Dis.* **35**: 678–686. [Medline] [CrossRef]
12. Mesquita, L. P., Hora, A. S., de Siqueira, A., Salvagni, F. A., Brandão, P. E. and Maiorka, P. C. 2016. Glial response in the central nervous system of cats with feline infectious peritonitis. *J. Feline Med. Surg.* **18**: 1023–1030. [Medline] [CrossRef]
13. Pedersen, N. C. 2009. A review of feline infectious peritonitis virus infection: 1963–2008. *J. Feline Med. Surg.* **11**: 225–258. [Medline] [CrossRef]
14. Poncelet, L., Coppens, A., Peeters, D., Bianchi, E., Grant, C. K. and Kadhim, H. 2008. Detection of antigenic heterogeneity in feline coronavirus nucleocapsid in feline pyogranulomatous meningoencephalitis. *Vet. Pathol.* **45**: 140–153. [Medline] [CrossRef]
15. Rissi, D. R. 2018. A retrospective study of the neuropathology and diagnosis of naturally occurring feline infectious peritonitis. *J. Vet. Diagn. Invest.* **30**: 392–399. [Medline] [CrossRef]
16. Slauson, D. O. and Finn, J. P. 1972. Meningoencephalitis and panophthalmitis in feline infectious peritonitis. *J. Am. Vet. Med. Assoc.* **160**: 729–734. [Medline]
17. Tasker, S. 2018. Diagnosis of feline infectious peritonitis: Update on evidence supporting available tests. *J. Feline Med. Surg.* **20**: 228–243. [Medline] [CrossRef]
18. Vennema, H., Poland, A., Foley, J. and Pedersen, N. C. 1998. Feline infectious peritonitis viruses arise by mutation from endemic feline enteric coronaviruses. *Virology* **243**: 150–157. [Medline] [CrossRef]