

# A simple technique to achieve vascular access for continuous venous-venous ultrafiltration in a toddler

## ABSTRACT

Acute renal failure is associated with increased mortality in the Pediatric Intensive Care Unit. When anuric or oliguric renal failure occurs, the associated fluid overload may compromise respiratory function and has been shown to be associated with worse outcomes. Renal replacement therapy using continuous venous-venous hemofiltration (CVVH) allows for fluid, solute, and nitrogenous waste removal. However, large bore vascular access with placement of a double-lumen dialysis catheter is necessary to ensure effective flow rates to allow for CVVH. We present a technique to facilitate exchange of a 4 Fr double-lumen central venous catheter to an 8 Fr double-lumen dialysis catheter for CVVH in a 2-year-old toddler who developed acute renal failure following surgery for congenital heart disease. This technique may be particularly valuable in patients with associated conditions including fluid overload and coagulation disturbances which may increase the morbidity of vascular access techniques.

**Key words:** Continuous venous-venous hemofiltration; fluid overload; renal failure; vascular access

## Introduction

Various etiologies may result in renal failure or renal insufficiency.<sup>[1,2]</sup> Recent evidence has demonstrated a correlation with the extent of fluid overload and outcomes following surgery for congenital heart disease.<sup>[3-5]</sup> When renal dysfunction is prolonged, renal replacement therapy may be indicated using continuous venous-venous hemofiltration (CVVH).<sup>[6]</sup> Although generally safe and effective, large bore vascular access is required with placement of a double-lumen dialysis catheter to facilitate the required flow rates that are needed for CVVH.<sup>[7]</sup> We present a technique to facilitate exchange of a 4 Fr double-lumen central venous catheter to an 8 Fr double-lumen dialysis catheter for CVVH in a 2-year-old toddler who developed

anuric renal failure, following surgery for congenital heart disease. This technique may be particularly valuable in patients with associated conditions including fluid overload and coagulation disturbances which may increase the morbidity of vascular access techniques.

## Case Report

The Institutional Review Board approval is not required by the Nationwide Children’s Hospital (Columbus, Ohio) for present of a single case report. The patient was a 2-year-old, 13.7 kg, boy with hypoplastic left heart syndrome who presented for Fontan palliation. Previous surgical procedures included a Glenn shunt at which time hypoplasia of the pulmonary arteries

This is an open access article distributed under the terms of the Creative Commons Attribution-NonCommercial-ShareAlike 3.0 License, which allows others to remix, tweak, and build upon the work non-commercially, as long as the author is credited and the new creations are licensed under the identical terms.

**For reprints contact:** reprints@medknow.com

**How to cite this article:** Tobias JD. A simple technique to achieve vascular access for continuous venous-venous ultrafiltration in a toddler. Saudi J Anaesth 2017;11:96-8.

Access this article online	
<p><b>Website:</b> www.saudija.org</p>	<p><b>Quick Response Code</b></p> 
<p><b>DOI:</b> 10.4103/1658-354X.197343</p>	

## JOSEPH DREW TOBIAS<sup>1,2,3</sup>

<sup>1</sup>Department of Anesthesiology and Pain Medicine, Nationwide Children’s Hospital, Departments of <sup>2</sup>Anesthesiology and Pain Medicine and <sup>3</sup>Pediatrics, The Ohio State University College of Medicine, Columbus, Ohio, USA

**Address for correspondence:** Dr. Joseph Drew Tobias, Department of Anesthesiology and Pain Medicine, Nationwide Children’s Hospital, 700 Children’s Drive, Columbus, Ohio 43205, USA. E-mail: Joseph.Tobias@Nationwidechildrens.org

was noted. Following the Fontan procedure, hemodynamic instability necessitated the use of inotropic agents to support blood pressure and myocardial function. Vascular access included a radial arterial cannula and a double-lumen central venous cannula in the right internal jugular vein. Given the progressive postoperative hemodynamic and respiratory instability with persistent hypoxemia, cardiac catheterization was performed on the postoperative day 2. Inadequate pulmonary blood flow with elevated systemic venous pressures was noted, and the pulmonary arteries were stented to improve pulmonary blood flow. Following the procedure, the second central venous cannula was placed in the left femoral vein, and systemic anticoagulation with heparin was instituted following stent placement. During the ensuing 48–72 h, there was a progressive rise in blood urea nitrogen (BUN) and creatinine, hepatic dysfunction with coagulation disturbances, and a progressive decrease in urine output despite the administration of a diuretic infusion (furosemide-chlorothiazide) and fenoldopam. Anuria developed with fluid overload of 2.5 L, BUN  $\geq 100$  mg/dL, and creatinine  $\geq 2.5$  mg/dL. The decision was made to institute continuous renal replacement therapy using CVVH.

#### Vascular access for continuous venous-venous hemofiltration

The following technique provides a relatively simple means of obtaining large bore venous access in small infants and children for CVVH. The technique uses small gauge introducer needle (22-gauge) and small wire (0.018") initially to gain venous access with progressive dilation to place a larger catheter (8–9 Fr) dialysis catheter. In addition, the technique can be used to exchange out a 4 Fr double-lumen catheter to an 8–9 Fr double-lumen dialysis catheter. For patients without venous access, the femoral or jugular vein is cannulated using either a 4 or 5 Fr double-lumen kit (Cook Critical Care, Bloomington, Indiana). The 0.018" wire is inserted into the vein through the 22-gauge introducer needle. The dilator is then advanced over the wire to dilate the tract. The dilator is removed and the 0.018" wire is left in place. The next step is to use the Cook Micropuncture Introducer Set–Silhouette Transitionless® (Cook Critical Care, Bloomington, Indiana). The Silhouette Transitionless® dilator is placed through the catheter and locked into place. The dilator and catheter are then advanced over the 0.018" wire and into the vein [Figure 1]. Once the catheter and dilator are in the vein, the wire is removed. The dilator is then unhooked and removed, leaving the 5 Fr catheter in place [Figure 2]. The internal lumen of this 5 Fr catheter is large enough to allow placement of a 0.032–0.035" wire through it [Figures 3 and 4]. Once this is accomplished, the 5 Fr catheter is removed, leaving the 0.035" wire in the vessel. This large wire will then accept the dilators and eventually the 8–9 Fr dialysis catheter.

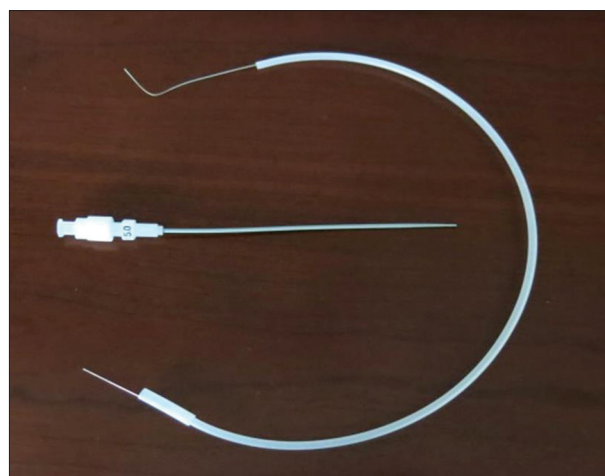


Figure 1: Silhouette Transitionless® catheter with internal dilator in place and 0.018" wire (Cook Critical Care, Bloomington, Indiana)




Figure 2: 5 French catheter (above) with internal dilator removed (below). The dilator is threaded through the catheter and locked into place. It can then be advanced over the 0.018" wire and into the vein. The wire and the dilator are removed, leaving the 5 French catheter in the vein

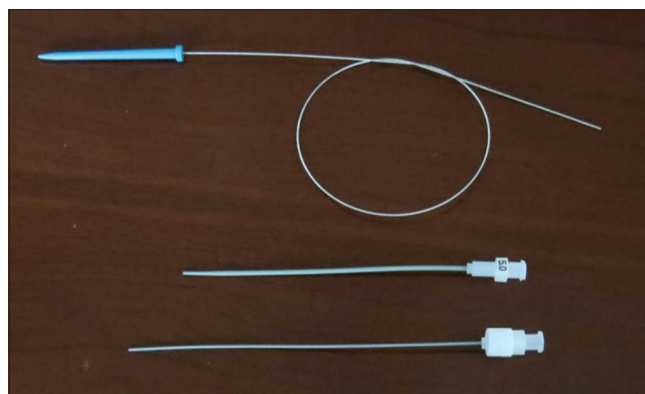
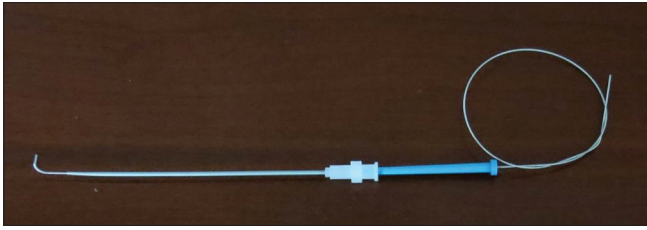


Figure 3: After the dilator (bottom) has been removed, the 0.035" wire (above) passes easily through the 5 French catheter (middle) and into the vein. Once the wire is in the vessel, the 5 French catheter is removed. The dilators for the dialysis catheter are passed over the wire to dilate the tract followed by placement of the 8–9 Fr dialysis catheter

#### Discussion

As fluid overload and acute kidney injury are associated with an increased incidence of mortality in various clinical scenarios in the Pediatric Intensive Care Unit (PICU) patient, the past years have witnessed an increased use of various renal



**Figure 4: The 0.035" wire for eventual placement of the 8–9 French dialysis catheter passes easily through the 5 French catheter**

replacement therapies including CVVH. When using CVVH, the flow rates required to ensure adequate solute and fluid removal as well as to maintain circuit patency without clot formation mandate large bore vascular access. As illustrated by our patient, in the 1–4-year-old age range, routine central venous access for long-term PICU care is generally achieved with a 4 Fr double-lumen catheter. To achieve adequate flows for CVVH, either an 8–9 Fr catheter (double-lumen) is needed or two separate 4–5 Fr single-lumen venous catheters are needed. As such, we were faced with the option of either obtaining additional central venous access or exchanging one of the two central venous catheters that were in place.

Although we chose to exchange one of the catheters over a wire as our patient had two central venous catheters, if we had chosen to secure additional venous access, a similar technique can be used as described above starting. The vessel is accessed with a 22-gauge introducer needle from a standard 4 Fr double-lumen, central line kit. The 0.018" wire is then placed through the needle; the needle removed, and the dilator advanced over the wire. The wire is then left in the vein and the 5 Fr Silhouette Transitionless® catheter placed into the vein. The wire and dilator removed and the 0.032–0.035" wire is placed. In either case, the use of this technique provides a simple and relatively atraumatic mechanism for placement of a large bore dialysis catheter in a small pediatric patient

starting with vascular puncture with a 22-gauge needle. The atraumatic nature is illustrated by its use in our patient who was not only receiving therapeutic anticoagulation with heparin (partial thromboplastin time 60–80 s) but also had an ongoing consumptive coagulation process with prolongation of the prothrombin time and international normalized ratio. This technique may be particularly valuable in patients with associated conditions including fluid overload and coagulation disturbances which may increase the morbidity of vascular access techniques.

#### Financial support and sponsorship

Nil.

#### Conflicts of interest

There are no conflicts of interest.

#### References

1. Cabral FC, Ramos Garcia PC, Mattiello R, Dresser D, Fiori HH, Korb C, *et al*. Influence of acute kidney injury defined by the pediatric risk, injury, failure, loss, end-stage renal disease score on the clinical course of PICU patients. *Pediatr Crit Care Med* 2015;16:e275-82.
2. Shalaby M, Khathlan N, Safder O, Fadel F, Farag YM, Singh AK, *et al*. Outcome of acute kidney injury in pediatric patients admitted to the Intensive Care Unit. *Clin Nephrol* 2014;82:379-86.
3. Seguin J, Albright B, Vertullo L, Lai P, Dancea A, Bernier PL, *et al*. Extent, risk factors, and outcome of fluid overload after pediatric heart surgery. *Crit Care Med* 2014;42:2591-9.
4. Hassinger AB, Wald EL, Goodman DM. Early postoperative fluid overload precedes acute kidney injury and is associated with higher morbidity in pediatric cardiac surgery patients. *Pediatr Crit Care Med* 2014;15:131-8.
5. Wilder NS, Yu S, Donohue JE, Goldberg CS, Blatt NB. Fluid overload is associated with late poor outcomes in neonates following cardiac surgery. *Pediatr Crit Care Med* 2016;17:420-7.
6. Daniels RC, Bunchman TE. Renal complications and therapy in the PICU: Hypertension, CKD, AKI, and RRT. *Crit Care Clin* 2013;29:279-99.
7. Mendley SR, Langman CB. Acute renal failure in the pediatric patient. *Adv Ren Replace Ther* 1997;4 2 Suppl 1:93-101.