

Keratotic spines in a patient with pruritic and dyskeratotic dermatosis: A new clinical finding



Kevin Kwan, BA,^a Samantha Sears, MD,^b Jeffrey Callen, MD,^b Peter Rady, MD,^c Stephen Tying, MD, PhD, MBA,^c Soon Bahrami, MD,^b Meagan Huelsman, MD,^b and Janine Malone, MD^b
Louisville, Kentucky and Houston, Texas

Key words: HPyV6; HPyV7; human polyomavirus; immunosuppression; keratotic papules; PDD; pruritic and dyskeratotic dermatosis; transplant; trichodysplasia spinulosa.

INTRODUCTION

The Polyomaviridae family includes 13 small, nonenveloped, double-stranded, circular human DNA viruses.¹ Polyomavirus infection is usually latent and asymptomatic. Clinical disease, although rare, primarily occurs in patients who are immunosuppressed iatrogenically. In such patients, viral reactivation can cause disease involving the kidneys, central nervous system, or skin.¹ Cutaneous manifestations associated with the Polyomaviridae include Merkel cell carcinoma, trichodysplasia spinulosa (TS), and, more recently, pruritic and dyskeratotic dermatosis (PDD). The viruses responsible for disease are Merkel cell polyomavirus, TS-associated polyomavirus, human polyomavirus 6 (HPyV6), and human polyomavirus 7 (HPyV7).¹⁻³ We report a patient with an unusual presentation of PDD that included a lichenified dermatosis associated with alopecia and follicularly-based keratotic papules.

CASE REPORT

A 44-year-old man who had undergone kidney and pancreas transplantation 7 years prior presented with a 2-year history of a diffuse, pruritic, burning rash associated with dyspigmentation and lichenification as well as tender follicular-based papules involving the dorsal hands and elbows and pits involving the wrists and palms. Transplantation

Abbreviations used:

HPyV6: human polyomavirus 6
 HPyV7: human polyomavirus 7
 PDD: pruritic and dyskeratotic dermatosis
 TS: trichodysplasia spinulosa

was performed for untreated hypertension and diabetes mellitus. Prior to the presentation, his eruption had been diagnosed as psoriasis by another physician, and he had been treated with intramuscular triamcinolone acetonide, triamcinolone 0.1% cream, and narrowband ultraviolet B phototherapy without improvement. At the time of presentation, his medications included doxazosin 8 mg/day, gabapentin 300 mg twice daily, metformin 500 mg/day, metoprolol tartrate 100 mg/day, pantoprazole 20 mg/day, tacrolimus 1 mg/day, and everolimus 2.5 mg twice daily.

Physical examination revealed diffuse, hyperpigmented, scaly, lichenified patches, patchy alopecia, and follicular-based keratotic papules and pits involving the elbows, wrists, and palms (Fig 1). A biopsy from the upper extremity revealed mild acanthosis, spongiosis, and patchy intraepidermal dyskeratosis extending somewhat linearly into a hyperkeratotic stratum corneum (Fig 2). The paraffin-embedded tissue was tested for HPyV6, HPyV7, and TS-associated polyomavirus.

From the Department of Dermatology^a and Department of Medicine, Division of Dermatology, University of Louisville School of Medicine,^b and Department of Dermatology, University of Texas Health Science Center at Houston, McGovern Medical School.^c

Funding sources: None.

Conflicts of interest: None disclosed.

IRB approval status: Not applicable.

Correspondence to: Kevin Kwan, BA, University of Louisville School of Medicine, 3810 Springhurst Blvd #200, Louisville, KY 40241.
 E-mail: krkwan01@louisville.edu.

JAAD Case Reports 2021;7:103-6.
 2352-5126

© 2020 by the American Academy of Dermatology, Inc. Published by Elsevier, Inc. This is an open access article under the CC BY-NC-ND license (<http://creativecommons.org/licenses/by-nc-nd/4.0/>).

<https://doi.org/10.1016/j.jidcr.2020.11.015>

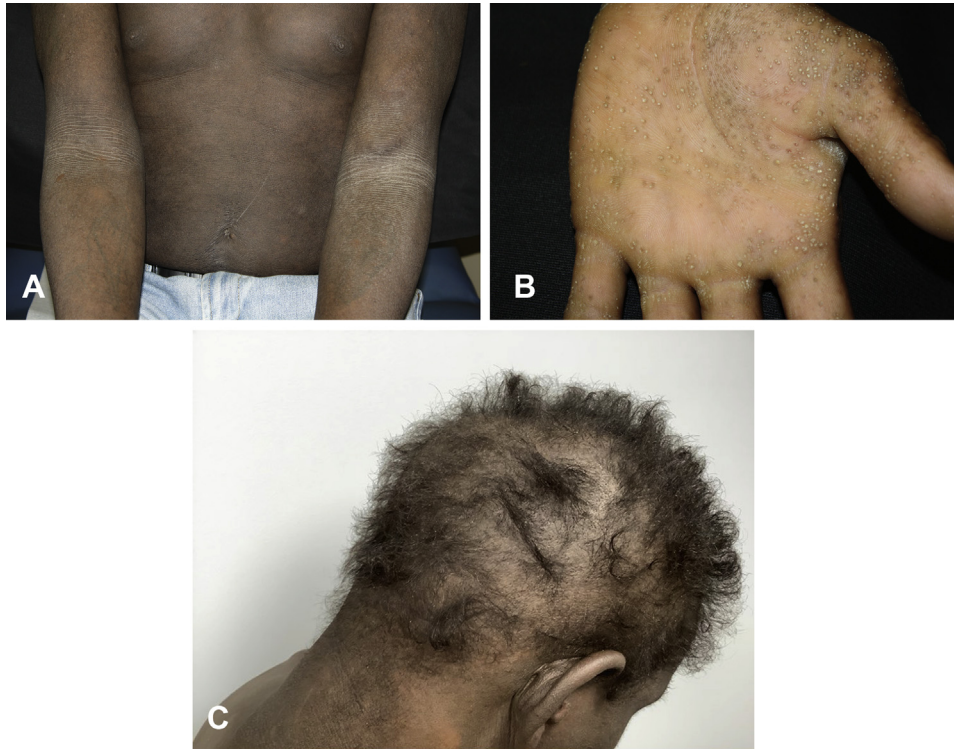

Fig 1. Clinical features. **A**, Diffuse lichenified and hyperpigmented patches involving the trunk and bilateral extremities. **B**, Keratotic papules and pits involving the palmar surfaces. **C**, Patchy moth-eaten alopecia with perifollicular keratotic papules present on the back of the neck.

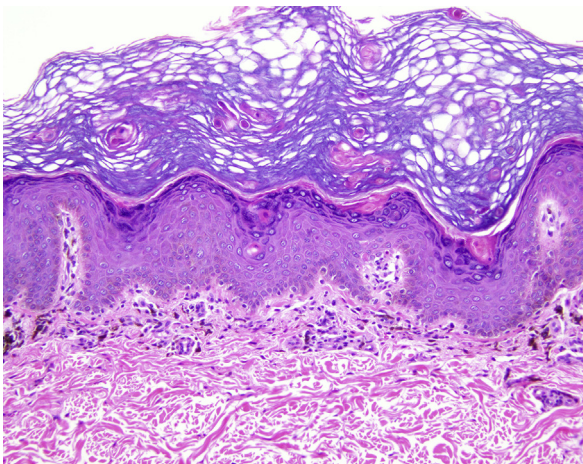


Fig 2. Histologic features. Biopsy of a scaly patch from the torso demonstrating mild verrucous acanthosis and intraepidermal/intracorneal dyskeratosis in a vaguely linear pattern (“peacock plumage”). (Hematoxylin-eosin stain; original magnification: $\times 200$.)

HPyV7 was detected in both specimens. The patient was treated with acitretin, and after 3 months of therapy he has had complete clearance of his pruritic eruption. His follicular lesions and palmar pits remain but are less tender.

DISCUSSION

PDD is a rare disease in immunocompromised individuals caused by the reactivation of HPyV6 or HPyV7 in the epidermis and sparse involvement of the papillary dermis.² Since its initial documentation in 2015, there have been 4 additional reports in the medical literature, all occurring in immunocompromised individuals. However, none of the previously reported patients have demonstrated prominent follicular-based keratotic papules and alopecia.

PDD clinically manifests with pruritic, brown to gray, lichenified plaques involving the trunk and extremities.²⁻⁵ Ho et al first described the histologic finding of “peacock plumage,” which refers to the irregular columns of parakeratosis noted on histopathologic evaluation.⁴ In addition, histopathology reveals variable papillomatosis, intraepidermal dyskeratotic keratinocytes, and a sparse perivascular lymphocytic dermal infiltrate.⁴ The cases of PDD reported in the literature are listed in [Table I](#). We report a patient with PDD with an unusual clinical presentation, including keratotic follicular-based papules and alopecia, which have not been previously reported in HPyV6 or HPyV7 cutaneous infection.

TS is characterized by the presence of spine-like follicular papules that involve the face, ears,

Table I. Summary of all literature-documented cases of PDD due to HPyV6 or HPyV7

Case report	Age (Y)/Sex	Immune status	Clinical presentation	Treatments attempted	Outcome
Ho et al ⁴	1. 73/M	1. Single lung transplant recipient on alemtuzumab, prednisone, azathioprine, and tacrolimus	1. Multiple pruritic, brownish-pink, thin, scaly papules and plaques on the trunk and neck sparing the acral areas and face	1. Topical corticosteroids and antihistamines	1. Worsening progression of symptoms
	2. 72/M	2. Double lung transplant recipient on alemtuzumab, tacrolimus, mycophenolic acid, and prednisone	2. Pruritic, brown, well-defined thin papules and plaques on the trunk, axillae, neck, buttocks, and legs	2. Topical corticosteroids and diphenhydramine	2. Diphenhydramine led to minimal improvement, and topical corticosteroids worsened rash
Nguyen et al ²	1. 52/M	1. Kidney and pancreas transplant recipient on tacrolimus and rapamycin	1. Pruritic rash present for over 2 years	1. Unknown	1. Patient deceased
	2. 36 /F	2. HIV/AIDS	2. Severe pruritic rash worsening over 12 months	2. Unknown	2. Initial worsening for 2 years and then several years of resolution with no immunosuppression
	3. 54/M	3. None at time of diagnosis but was hospitalized for sepsis, parapharyngeal abscess, and pneumonia	3. Pruritic rash worsening over 2 years followed by resolution over several years	3. Unknown	3. Patient deceased
Smith et al ⁵	59/M	Bilateral lobar (living) transplant recipient on prednisone and tacrolimus	Diffuse, gray, lichenified plaques with confetti-like islands of sparing on the trunk and proximal extremities and generalized pruritus	<ul style="list-style-type: none"> • Oral steroid • Topical steroid • Antihistamine • Topical (1% and 3%) cidofovir 	<ul style="list-style-type: none"> • Oral steroid: minimal improvement of rash and pruritus • Topical steroid: no relief • Antihistamine: no relief • Topical (1% and 3%) cidofovir: clinical improvement of the rash on the flanks, near clearance on the extremities, and resolution of generalized pruritus
Canavan et al ³	48/M	Cardiac transplant recipient on sirolimus and tacrolimus	Severely pruritic, pink to gray macules, thin papules, and plaques on the trunk and extremities, sparing acral areas and the face	Cyproheptadine, doxepin, emollients, topical corticosteroids, pamoquine cream, intravenous cidofovir, and oral acitretin 25 mg	No improvement with topical treatments or antihistamines. Temporary improvement with intravenous cidofovir with subsequent relapse within 4-6 weeks. Complete clinical resolution with oral acitretin
Current report	44/M	Kidney and pancreas transplant recipient on tacrolimus and everolimus	Hyperpigmented scaly patches all over body and prominent follicular spines on the elbows and palms	Oral acitretin 25 mg daily	Complete clearing of patches with improvement in keratotic papules at 1-month follow-up

HPyV6, Human polyomavirus 6; HPyV7, human polyomavirus 7; PDD, pruritic and dyskeratotic dermatosis.

extremities, and trunk, also showing lichenification of the skin and alopecia of the eyebrows.⁶ The histopathologic features include enlarged, dystrophic hair follicles and accumulation of eosinophilic, perinuclear globules within inner root sheath cells, and the intrafollicular accumulation of keratotic/parakeratotic material.⁷ The unusual keratotic papules present in our patient suggest that TS and PDD can have similar clinical presentations characterized by keratotic papules and spines, though the clinical distribution of lesions and histopathologic features should allow the distinction of the 2 conditions. Based on our report of alopecia and keratotic papules similar to TS, physicians might consider testing for all 3 polyomaviruses known to cause cutaneous disease to establish a definitive diagnosis in cases showing overlapping clinical features, especially if the histopathologic findings fail to distinguish the conditions. The presence of high sequence homologies in the coding region for all 3 polyomaviruses likely explains the clinical overlap in dermatoses resulting from HPyV6, HPyV7, and TS-associated polyomavirus infection.⁸

The pathogenic mechanism by which HPyV7 causes PDD is unknown, though it is postulated that human polyomavirus causes disease via upregulation of viral oncogenes that include tumor antigens.⁹ The small tumor antigen of HPyV7 is noted to be elevated in virus-positive eruptive pruritic dermatoses. In a recent study, Wu et al found that HPyV7 small tumor antigen was found to dysregulate protein phosphatase 2A through physical interaction, resulting in increased activation of MEK/ERK/c-JUN and 4E-BP1, which may lead to disorganized keratinocyte growth and hyperproliferation.⁹ Further studies are needed to elucidate the pathogenic mechanism.

PDD is a rare cutaneous disease with a limited documentation of effective treatment. The reduction of immunosuppression and initiation of antiviral treatment are effective options to control viral replication and clinical progression if clinically feasible. Anecdotal reports describe treatment failure with antihistamines and corticosteroids. Successful treatment has been documented with topical cidofovir, a cytosine analog that inhibits human polymerase activity required for polyomavirus replication, and/or acitretin, a vitamin A analog that increases keratinocyte turnover.^{1,3,5} Cidofovir and acitretin have also shown efficacy in the treatment of TS, though acitretin was coadministered with antiviral therapy (oral valganciclovir).¹⁰

In summary, we present an additional report of a recently described HPyV7-associated dermatosis in a patient who underwent solid organ transplantation

that was characterized by lichenified plaques, with novel additional findings of follicular-based papules and pits and alopecia. PDD should be included along with TS in the differential diagnosis of a diffuse pruritic rash with keratotic papules and pits and/or alopecia in an immunosuppressed patient. While keratotic papules and spines, alopecia, and response to cidofovir treatment reflect the similar viral class of origin of PDD and TS, the histologic features of the 2 conditions appear to be disparate. Based on the few cases of PDD reported in the literature, a diffuse eruption of lichenified patches or plaques would favor infection with HPyV6 or HPyV7, as the histologic findings fail to show follicular epithelial dysmorphism characteristic of TS. Despite the lack of a specific viral cytopathic effect in lesions of PDD, the presence of columnar parakeratosis and/or spotty intraepidermal dyskeratosis should alert the pathologist to the diagnosis when there is a history of immunosuppression.

Expert technical assistance with molecular analysis was provided by Qin He, MD.

REFERENCES

1. Fava P, Merlino C, Novelli M, et al. HP yV6, HP yV7 and TSP yV DNA sequences detection in skin disease patients and healthy subjects. *J Eur Acad Dermatol Venereol*. 2016;30(4):624-627.
2. Nguyen KD, Lee EE, Yue Y, et al. Human polyomavirus 6 and 7 are associated with pruritic and dyskeratotic dermatoses. *J Am Acad Dermatol*. 2017;76(5):932-940.e3.
3. Canavan T, Baddley J, Pavlidakey P, Tallaj J, Elewski B. Human polyomavirus-7-associated eruption successfully treated with acitretin. *Am J Transplant*. 2018;18(5):1278-1284.
4. Ho J, Jedrych JJ, Feng H, et al. Human polyomavirus 7-associated pruritic rash and viremia in transplant recipients. *J Infect Dis*. 2015;211(10):1560-1565.
5. Smith SD, Erdag G, Cuda JD, et al. Treatment of human polyomavirus-7-associated rash and pruritus with topical cidofovir in a lung transplant patient: case report and literature review. *Transpl Infect Dis*. 2018;20(1):e12793.
6. Haycox CL, Kim S, Fleckman P, et al. Trichodysplasia spinulosa—a newly described folliculocentric viral infection in an immunocompromised host. *J Invest Dermatol Symp Proc*. 1999;4(3):268-271.
7. Kazem S, Van Der Meijden E, Wang RC, et al. Polyomavirus-associated trichodysplasia spinulosa involves hyperproliferation, pRB phosphorylation and upregulation of p16 and p21. *PLoS One*. 2014;9(10):e108947.
8. Van Ghelue M, Khan MTH, Ehlers B, Moens U. Genome analysis of the new human polyomaviruses. *Rev Med Virol*. 2012;22(6):354-377.
9. Wu JH, Narayanan D, Simonette RA, Rady PL, Tying SK. Human polyomavirus 7 (HP yV7)-associated dermatoses: novel molecular mechanism driven by viral activation of 4E-BP1 and MEK-ERK-cJun. *Int J Dermatol*. 2019;58(4):383-387.
10. Aleissa M, Konstantinou MP, Samimi M, et al. Trichodysplasia spinulosa associated with HIV infection: clinical response to acitretin and valganciclovir. *Clin Exp Dermatol*. 2018;43(2):231-233.