



Since January 2020 Elsevier has created a COVID-19 resource centre with free information in English and Mandarin on the novel coronavirus COVID-19. The COVID-19 resource centre is hosted on Elsevier Connect, the company's public news and information website.

Elsevier hereby grants permission to make all its COVID-19-related research that is available on the COVID-19 resource centre - including this research content - immediately available in PubMed Central and other publicly funded repositories, such as the WHO COVID database with rights for unrestricted research re-use and analyses in any form or by any means with acknowledgement of the original source. These permissions are granted for free by Elsevier for as long as the COVID-19 resource centre remains active.



# Optimizing telemedicine encounters for oral and maxillofacial surgeons during the COVID-19 pandemic

Hwi Sean Moon, DDS MD,<sup>a</sup> Tim T. Wang, BA,<sup>b,c</sup> Karthik Rajasekaran, MD,<sup>d</sup> Ryan Brewster, BA,<sup>e</sup> Rabie M. Shanti, DMD, MD,<sup>d,f</sup> and Neeraj Panchal, DDS, MD, MA<sup>g</sup>

The coronavirus disease 2019 (COVID-19) pandemic has changed conventional patterns of medical practice across all health disciplines, including oral and maxillofacial surgery. The use of telemedicine has rapidly expanded to uphold safety strategies of physical distancing and disease transmission reduction while maintaining uninterrupted care of patients. To date, there are no specific guidelines to optimize telemedicine encounters in oral and maxillofacial surgery. The goal of this article is to provide best practices for both oral and maxillofacial surgeons and their patients to effectively use telemedicine for the duration of the COVID-19 pandemic and beyond. (Oral Surg Oral Med Oral Pathol Oral Radiol 2021;131:166–172)

The coronavirus disease 2019 (COVID-19) pandemic has disrupted society in a multitude of ways. Health care is no exception; the rapid transmission and high hospitalization rate of severe acute respiratory syndrome coronavirus 2 (SARS-CoV-2) have strained medical resources, including personal protective equipment (PPE), respiratory ventilators, and hospital beds.<sup>1-4</sup> The virus also poses a major threat to health care personnel, whose risk of exposure are compounded by the aforementioned PPE shortage.<sup>5-7</sup> In response, the American Association of Oral and Maxillofacial Surgeons (AAOMS) recommended delaying elective surgeries, in response to calls from the Centers for Disease Control and Prevention to postpone elective medical and dental procedures.<sup>8-10</sup> Similarly, 4 of every 5 dental offices have suspended all but emergency procedures.<sup>11</sup>

In the face of these challenges, the medical and dental communities have remained steadfast in caring for patients requiring nonelective treatments and innovating alternative ways to deliver care. One of the most important and popular alterations in the delivery of care is the increased use of telemedicine, which allows surgeons and patients to connect virtually.<sup>12,13</sup>

<sup>a</sup>Resident, Department of Oral and Maxillofacial Surgery, University of Pennsylvania, Philadelphia, PA, USA.

<sup>b</sup>DMD Candidate, School of Dental Medicine, University of Pennsylvania, Philadelphia, PA, USA.

<sup>c</sup>MPH Candidate, Perelman School of Medicine, University of Pennsylvania, Philadelphia, PA, USA.

<sup>d</sup>Assistant Professor of Otorhinolaryngology, University of Pennsylvania, Philadelphia, PA, USA.

<sup>e</sup>MD Candidate, Stanford University School of Medicine, Stanford University, Stanford, CA, USA.

<sup>f</sup>Assistant Professor of Oral and Maxillofacial Surgery, University of Pennsylvania, Philadelphia, PA, USA.

<sup>g</sup>Assistant Professor and Section Chief of Oral and Maxillofacial Surgery, Philadelphia Veterans Affairs Medical Center, Penn Presbyterian Medical Center, University of Pennsylvania School of Dental Medicine, Philadelphia, PA, USA.

Received for publication May 31, 2020; returned for revision Aug 2, 2020; accepted for publication Aug 13, 2020.

Published by Elsevier Inc.

2212-4403/\$-see front matter

<https://doi.org/10.1016/j.oooo.2020.08.015>

Telemedicine has enabled patients to access much-needed medical care while conserving supplies of PPE and minimizing exposure to pathogens. Although studies have found telemedicine to decrease costs and save time without compromising patient satisfaction, it was not widely used in health care before the COVID-19 pandemic.<sup>14,15</sup> Similarly, teledentistry was deemed to be “in its infancy” by the founder of the American Teledentistry Association in 2019.<sup>16-18</sup>

Nevertheless, telemedicine has shown promise and has been incorporated into the workflow of various oral and maxillofacial surgery institutions and practices across the United States. Virtual visits are particularly useful in triaging patients. For example, patients with dentoalveolar infections can meet virtually with surgeons and receive prescriptions for appropriate analgesics and antibiotics without going to the emergency department. Also, patients with oral lesions can take photographs that they can show their dental care provider before in-person visits to expedite diagnosis and treatment planning. This enables patients to obtain timely attention of providers while lightening the burden on the health care system by reducing the number of in-person visits.

Associated with the recent rise in telemedicine’s popularity is the learning curve for both surgeons and patients. The incorporation of technology and the shift to virtual visits can cause a certain amount of discomfort in the patient–surgeon relationship and, therefore, must be navigated thoughtfully. Although there have been helpful telehealth guides for surgeons and patients in other surgical specialties, we do not know of any such guidelines for oral and maxillofacial surgery.<sup>13,19</sup> For this reason, we present here suggestions for best practices for both oral and maxillofacial surgeons

## Statement of Clinical Relevance

The goal of this article is to provide best practices for both oral and maxillofacial surgeons and their patients to effectively use telemedicine for the duration of the COVID-19 pandemic and beyond.

(OMSs) and their patients to effectively use telemedicine for the duration of the COVID-19 pandemic and beyond.

## GENERAL CONSIDERATIONS FOR TELEMEDICINE

As recommended by the AAOMS White Paper titled “Telehealth and Remote Treatment,” virtual management of any oral and maxillofacial surgical condition should only be provided by appropriately licensed oral and maxillofacial surgeons, as regulated by the state law.<sup>20</sup> The delivery of patient care through telemedicine must continue to follow evidence-based guidelines to ensure quality and safety for all patients. All providers must comply with the latest telemedicine requirements outlined by the United States Department of Health and Human Services to protect patient privacy and comply with the Health Insurance Portability and Accountability Act.<sup>21</sup> Furthermore, providers are ethically obligated to inform all patients about the potential benefits, limitations, and risks of telemedicine.<sup>22</sup> Patients requiring emergency or urgent services must be directed to the nearest hospital.

## SETTING UP FOR TELEMEDICINE

Although there are several modalities to conduct a telemedicine encounter, we strongly recommend live, synchronous, 2-way interaction between the patient and the OMS, incorporating both audio and visual telecommunications tools. This can be achieved with a desktop computer, laptop, or smartphone. The United States Census Bureau reports that approximately 89% of households have computers or smartphones, and 81% have broadband Internet connection.<sup>23</sup> Of these options, however, we recommend using a desktop or a large-screen laptop with a high-resolution camera, rather than smartphones, even if the latter meets the minimum technical requirements.

Ideally, telemedicine visits can offer a clinic experience that closely simulates in-person encounters. Trained administrative staff members should call patients beforehand to discuss the virtual setup and basic expectations for the visit. [Figure 1](#) (created by Prasad et al.) provides a sample of a patient information handout, with graphic illustrations detailing the setup as well as key examination steps that patients may be asked to perform during the encounter.<sup>13</sup> In the following sections, we will detail key aspects and considerations for both OMSs and patients to optimize telehealth visits.

### Insurance Coverage and Billing

In an effort to reduce the burden on health care entities and facilitate mitigation efforts, the Centers for Medicare and Medicaid Services (CMS) broadened the access to telemedicine coverage, with private payers

following suit. The CMS expansion included voice-only visits, which is critical for patients without access to a smartphone or computer video capabilities. Furthermore, the CMS allowed for parity of payment for telemedicine visits and in-person visits, so providers can bill Medicaid and Medicare at the same rate as they would for an in-person visit.<sup>24</sup> This new policy is especially relevant for older patients covered by Medicare because these patients are generally at higher risk for COVID-19 complications.<sup>25</sup> Therefore, before the telehealth encounter, providers should confirm if the patient’s insurance plan has telemedicine coverage and whether the insurance plan waives all copays for non-COVID-19-related visits to avoid the patient receiving an unexpected bill. The AAOMS provides additional detailed information about telehealth billing relevant for OMSs, including updated links to the American Medical Association and the American Dental Association billing codes, on its website (<https://www.aaoms.org/practice-resources/telehealth-faqs>).

### Professionalism and Provider Attire

During telehealth visits, the same level of professionalism should be maintained as that of in-person appointments. Providers should dress professionally as they would for their office- or hospital-based practice. Before the patient “arrives,” providers should review the patient’s relevant medical records and chief complaints to save time and maximize the efficiency of the visit. Also, in the interests of both time and professionalism, OMSs and patients should both be mindful about starting the visit on time. During the visit, OMSs should communicate openly with patients to maintain transparency. For instance, if an OMS needs to document something during the visit, he or she should respectfully inform the patient of the task to prevent any misunderstanding. At the end of the visit, it is important for the OMS to summarize what he or she accomplished during the visit and provide a clear plan for the appropriate next steps.

### Physical Background

When possible, OMSs and patients should conduct virtual encounters in well-lit spaces. Lighting specifically can have a profound effect on video quality. As such, overhead lights can be helpful, whereas lights behind the person should be avoided. Care should also be taken to prevent other sources of potential disruptions, such as background noise or visual distractions. It may be helpful for OMSs to evaluate their surroundings from the perspective of their patients.

### Technologic Background

It is important for OMSs to test video and audio quality before patient encounters to anticipate any potential

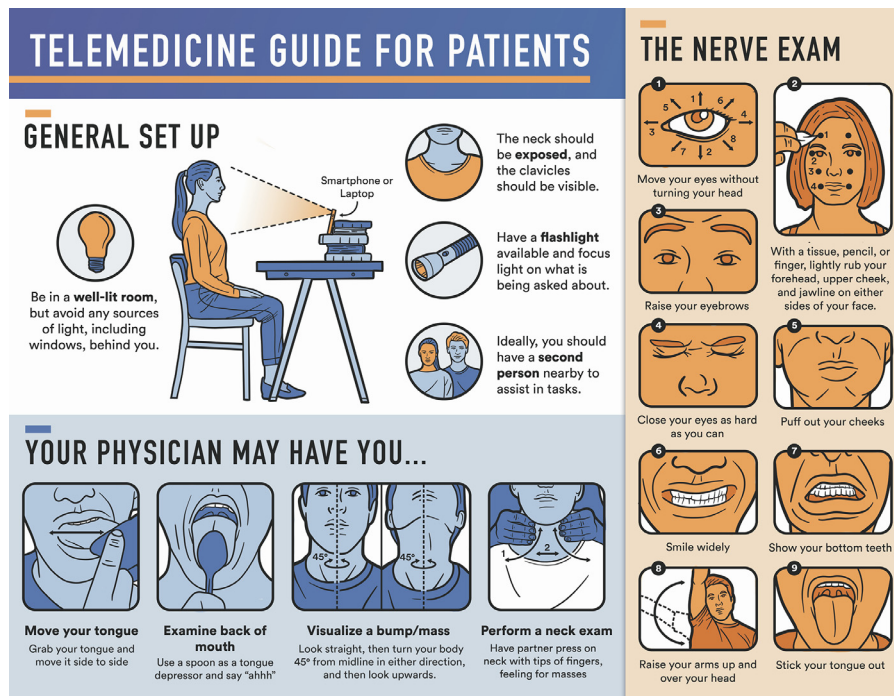


Fig. 1. Patient informational handout with graphic illustrations detailing the set up as well as key examination steps that patients may be asked to perform during the telemedicine encounter. Reprinted from Prasad A, Brewster R, Newman JG, Rajasekaran K. Optimizing your telemedicine visit during the COVID-19 pandemic: practice guidelines for patients with head and neck cancer. *Head Neck*. 2020;42:1317-1321.

technical difficulties that may cause interruptions. A strong Wi-Fi Internet connection is preferred over a cellular connection to ensure a stable signal. With the exception of electronic health records, OMSs should close any unnecessary programs or Internet browser tabs to preserve Internet bandwidth. In addition, OMSs should be mindful of their patients’ varying Internet speeds. As such, OMSs should give approximately 2 seconds of lag time after patients stop speaking to allow all of their words to come through completely.

**Patient and Camera Position**

If possible, patients should sit upright on a chair in front of a computer that is placed on a desk. Patients should sit close enough to the camera so that the entire head and neck area is within the video frame. The camera should be approximately at eye level for both OMSs and patients to maintain eye contact and remain engaged during the virtual encounter. Patients using a smartphone can prop up the device at a 45- to 90-degree angle from the table surface to allow their hands to be free for physical examination tasks.

**Patient Clothing**

Patients must be notified of the appropriate clothing required to be worn for the encounter well in advance. Ideally, clothing should allow the entire head and neck region to be visualized while maintaining the comfort

of patients and the professionalism of OMSs. Any hats or scarves should be removed, if at all possible, while maintaining appropriate cultural and religious norms.

**Patient Items**

Before the appointment, patients should have the following items ready, which can help aid OMSs in visualization and retraction during the virtual physical examination. Most of these items are commonplace, inexpensive, and available at the patient’s home.

1. *Flashlight*: A flashlight or a penlight can enhance visualization of certain obscure head and neck structures, particularly those in the oral cavity. The built-in flashlight of a smartphone can also be used.
2. *Ruler*: A ruler or a measuring tape can be used to measure the patient’s maximal mouth opening and mandibular range of motion.
3. *Napkins*: A napkin can be used to touch any intraoral landmarks and also to clean up after any inadvertent salivation resulting from the virtual physical examination.
4. *Spoon*: A spoon can be used to retract the cheeks or depress the tongue to evaluate structures of the oropharynx, such as the soft palate and the tonsillar pillars.
5. *Cheek retractors*: A fun way for patients to achieve cheek retraction can be to use the plastic props from



the board game “Speak Out,” which was created in 2016.<sup>26</sup> This game provides horseshoe-shaped plastic retractors (Figure 2), which can be placed along the patient’s upper and lower lips to lateralize the cheeks, thus allowing hands-free visualization of the dentition and the oral cavity soft tissue.

### Patient Assistant

The patient could ask a family member or a friend, if available, to be present for the telehealth visit. These individuals can assist the patient perform the physical tasks required during the virtual physical examination. They can also help position the web camera to improve the view for the provider. In fact, such assistance is essentially mandatory for pediatric patients or patients with disabilities.

### Feedback

It is a good practice for providers to seek feedback from patients after a visit. This will help OMSs hone their telehealth skills and ensure that their patients are receiving the appropriate quality of care.

### Virtual History and Physical Examination

Thorough patient assessment, proper medical documentation, and appropriate diagnostic testing are critical components of OMS practice to ensure proper diagnosis and treatment planning. OMSs should obtain patients’ medical histories in a similar manner as they would during in-office visits. New patients must be asked for comprehensive histories that include the chief complaint, history of the present illness, past medical history, past surgical history, dental history, medications, allergies, pertinent family history, social history, and a complete review of systems. For patients on record, medical histories should be updated to reflect the current chief complaint. All patients should also be screened with an up-to-date COVID-19 questionnaire. If an infection is suspected, OMSs should



Fig. 2. Horseshoe-shaped plastic lip and cheek retractors.

refer the patients to their primary care physicians or to the emergency department of a local hospital, depending on the severity of symptoms, for the appropriate workup.

Vitals should be obtained if the patient has access to a thermometer, a blood pressure cuff, a pulse oximeter, and a weighing scale. Even without any of these devices, patients can still measure their pulse by placing 2 fingers on the carotid artery and counting the number of beats per minute. Also, patients can calculate their respiratory rate by observing the number of chest rises in one minute. Finally, oxygen saturation can be measured by using certain mobile health applications, although OMSs should not solely rely on the results from these applications to make any major medical decisions. Finally, patients with fever (body temperature > 100.4°F) warrants further workup in an emergency department setting for a differential diagnosis that includes COVID-19 infection.

The virtual physical examination will be limited to a head and neck examination and a cranial nerve examination. Although inspection and palpation are the basis of a focused physical examination in oral and maxillofacial surgery, OMSs must learn to work together with patients to achieve the same goals virtually. The patient must perform self-maneuvers with guidance from the OMS. To this end, a printed step-by-step schematic, as illustrated in Figure 1, can be helpful to patients if provided before the visit. During the visit, the OMS can reinforce the information on the diagram with clear verbal instructions without any medical jargon. The examination itself must be conducted systematically, with a top-down, outside-in approach as is typical in oral and maxillofacial surgery practice. The examination can be further divided into head and neck subsites. The OMS should ask for specific symptoms related to each subsite and carefully inspect for any abnormalities while guiding the patient or the patient’s assistant through the examination. The following sections offer additional details and considerations for each subsite.

### Head

The OMS should ask about any history of head trauma. The head is assessed to ensure that it is normocephalic and there is no trauma.

### Face

The OMS should ask the patient about any facial pain, swelling, weakness, numbness, or history of trauma to the region. Then, the OMS can start the facial examination by asking the patient to lean close to the camera. First, the face is examined for any skin lesions along the forehead, eyelids, external ears, nose, malar region, vermilion of the lips, and the chin. The left and right sides of the patient’s face should be compared for any

gross asymmetry or deformities. The OMS can then guide the patient through palpating the face for any bony discontinuity or soft tissue swelling. The patient can also tap the face with 2 fingers to identify any tenderness in the sinuses.

With regard to the eyes, the OMS can assess if the pupils are equal. The extraocular muscles along with the oculomotor, supratrochlear, and the abducens nerves can be tested by having the patient look up, down, left, and right without moving the head. The sensory portion of the trigeminal nerve can be tested by asking the patient to close the eyes and slide both index fingers horizontally along the ipsilateral forehead (ophthalmic branch), cheek (maxillary branch), and lip and chin (mandibular branch). The branches of the facial nerves can be assessed by asking the patient to raise the eyebrows, close the eyes tightly, puff out the cheeks, smile widely, and show the bottom teeth.

### **Temporomandibular joint**

The OMS should ask the patient about any facial, jaw, or ear pain; trismus; difficulty mastication; and clicking or locking of the temporomandibular joint (TMJ). Then, the TMJ examination begins by asking the patient to palpate the mandibular condyles and the muscles of mastication to identify any tender spots. The OMS can ask the patient to open and close the mouth while palpating the condyles to feel for any clicks or crepitus. Also, maximal interincisal opening can be roughly estimated by the number of fingerbreadths or precisely measured by using a ruler. The mandibular range of motion can be assessed or measured in protrusive and lateral excursive positions.

### **Neck**

The OMS should ask about any difficulty breathing, dysphagia, sore throat,odynophagia, hoarseness, or new swelling in the neck area. The neck examination begins with inspection to look for any asymmetry or tracheal deviation. The patient can be asked to turn the head from side to side, look upward, and shrug the shoulders to assess the spinal accessory nerves. The OMS should ask the patient's assistant, if possible, to stand right behind the patient and palpate the patient's neck. Using the fingertips on both hands, the assistant can palpate the neck in a unidirectional manner from superior to inferior and then from lateral to medial. The OMS should ask the assistant to note any palpable bumps or tender spots. It is particularly important to palpate the lateral neck for enlarged lymph nodes. Last, the OMS can identify the thyroid by asking patients to swallow while palpating the appropriate area on the neck to rule out thyromegaly.

### **Oral Cavity and Oropharynx**

The OMS should ask about any oral pain, oral swelling or sores, tongue numbness, difficulty with tongue movement or dry mouth. Examination of the oral cavity can be challenging because intraoral structures can be difficult to retract and illuminate. The cheek retractor, whether one from the aforementioned board game or a spoon, can be helpful in retraction of soft tissue and visualization. In addition, the patient's assistant can help a great deal by adjusting the camera and properly orienting an additional light source.

For each intraoral structure, the OMS must carefully inspect for ulcers, raised lesions, and abnormal white (leukoplakic) or bright red (erythroplakic) lesions. In general, the OMS can best visualize structures near or at the level of the maxilla when the patient lifts the heads up to 45 degrees. Likewise, structures near or at level of the mandible are best observed with the patient dropping the chin to approximately 30 degrees. OMSs may find it useful to practice these examination techniques on their own cameras before patient encounters.

The patient should be recommended to wash the hands or to use gloves before touching any intraoral landmarks. The examination begins by having the patient slide the index finger along the maxillary and mandibular vestibules to look for any swelling or fluctuance. With the cheeks retracted, the patient can palpate the buccal and labial mucosae by using the thumb and the index finger, with one finger compressing along the face extraorally. When possible, palpation should be bidigital. Next, the patient can use the index finger to palpate the tuberosity, the retromolar trigone, and the hard palate to identify any tenderness or irregularities.

The tongue is the most common site for oral cancer and must be thoroughly examined. The dorsal surface of the tongue should be examined by asking the patient to fully protrude the tongue. The OMS should also ask the patient to move the protruded tongue to the left and to the right to inspect the lateral tongue and to ensure the function of the hypoglossal nerves. The ventral tongue and the floor of the mouth can be observed by asking the patient to touch the tip of the tongue to the hard palate. The tongue can then be palpated for lumps or masses. Next, the sublingual and submandibular glands can be palpated for symmetry and lack of elevation by the patient with the extended index fingers on the floor of the mouth.

The examination of the oropharynx is mostly limited in virtual encounters. Nevertheless, the soft palate, tonsils, and uvula can be partially visualized with the patient's mouth wide open and a spoon used by the patient to depress the tongue. Although unpleasant, the glossopharyngeal and vagus nerves can be tested by

gently touching the soft palate by using a spoon to induce the gag reflex.

### Dentition

If the patient is dentate, the provider should ask about dental pain, sensitivity, loosening of teeth, bleeding or sore gums, and malocclusion. The patient's dentition can be evaluated after retracting the soft tissue, as described previously. Dental caries, missing teeth, periodontal disease, gingival lesions or swelling can be readily identified. Mobility of teeth can be assessed by having the patient use the thumb and index finger. In edentulous patients, the alveolar ridge should be examined for any abnormalities as part of the aforementioned oral soft tissue examination.

### CONCLUSIONS

The COVID-19 pandemic has catalyzed an exponential increase in the use of telemedicine. Telemedicine helps patients maintain access to care, conserves limited medical resources, and protects both OMSs and patients from exposure to pathogens. Nevertheless, there is an expected learning curve that accompanies such a paradigm shift in the delivery of care. As such, in this article, we provided a guide to best practices to aid both OMSs and patients to navigate this promising electronic tool. In addition, we provided an accessible schematic handout that can be given to patients before a telehealth appointment to help them prepare for the visit, for both setting up and performing physical examination procedures. Because telemedicine may have a role in oral and maxillofacial surgical care even after this pandemic, we are optimistic that these best practices can be helpful and relevant for the present situation and beyond.

### REFERENCES

- Li Q, Guan X, Wu P, et al. Early transmission dynamics in Wuhan, China, of novel coronavirus-infected pneumonia. *N Engl J Med*. 2020;382:1199-1207.
- Feng S, Shen C, Xia N, Song W, Fan M, Cowling BJ. Rational use of face masks in the COVID-19 pandemic. *Lancet Respir Med*. 2020;8:434-436.
- Li R, Rivers C, Tan Q, Murray MB, Toner E, Lipsitch M. Estimated demand for US hospital inpatient and intensive care unit beds for patients with COVID-19 based on comparisons with Wuhan and Guangzhou, China. *JAMA Netw Open*. 2020;3. e208297-e208297. <https://doi.org/10.1001/jamanetworkopen.2020.8297>.
- White DB, Lo B. A framework for rationing ventilators and critical care beds during the COVID-19 pandemic *JAMA*. doi:10.1001/jama.2020.5046, Accessed April 15, 2020. [e-pub ahead of print].
- Heinzerling A, Stuckey MJ, Scheuer T, et al. Transmission of COVID-19 to health care personnel during exposures to a hospitalized patient—Solano County, California, February 2020. *MMWR Morb Mortal Wkly Rep*. 2020;69:472-476.
- Ng K, Poon BH, Kiat Puar TH, et al. COVID-19 and the risk to health care workers: a case report. *Ann Intern Med*. 2020;69:472-476.
- Halepas S, Ferneini EM. A pinch of prevention is worth a pound of cure: proactive dentistry in the wake of COVID-19. *J Oral Maxillofac Surg*. 2020;78:860-861.
- American Association of Oral and Maxillofacial Surgeons (AAOMS). Member alert: COVID-19 update. 2020. Available at: <https://www.aaoms.org/member-center/member-news/member-alert-covid-19-guidance-for-oms-practices?ct=9147806d98abc3a3a1f9f6b5cc93745b456dacf89b8e3-c8e637d26a9f31da147c11e1155f1d4b9f11e9efc15c647753840-f471ad76da9e49403f601b5a5895fa> Accessed May 7, 2020.
- Centers for Disease Control and Prevention (CDC). *Healthcare facilities: preparing for community transmission*. Available at: <https://www.cdc.gov/coronavirus/2019-ncov/hcp/guidance-hcf.html> Accessed May 7, 2020.
- Centers for Disease Control and Prevention (CDC). *CDC guidance for providing dental care during COVID-19*. Available at: <https://www.cdc.gov/oralhealth/infectioncontrol/statement-COVID.html> Accessed May 7, 2020.
- Carey M. *Second Week of HPI Polling Shows Dentists' Response to COVID-19*. Chicago, IL: American Dental Association; 2020.
- Hollander JE, Carr BG. Virtually perfect? Telemedicine for COVID-19. *N Engl J Med*. 2020;382:1679-1681.
- Prasad A, Brewster R, Newman JG, Rajasekaran K. Optimizing your telemedicine visit during the COVID-19 pandemic: practice guidelines for patients with head and neck cancer. *Head Neck*. 2020;42:1317-1321.
- Russo JE, McCool RR, Davies L. VA telemedicine: an analysis of cost and time savings. *Telemed e-Health*. 2015;22:209-215.
- Cain SM, Moore R, Sturm L, et al. Clinical assessment and management of general surgery patients via synchronous telehealth. *J Telemed Telecare*. 2017;23:371-375.
- Teledental practice and teledental encounters: an American Association of Teledentistry position paper. 2020. Available at: [https://www.americanteledentistry.org/wp-content/uploads/2018/10/ATDA\\_TeledentalPracticePositionPaper.pdf](https://www.americanteledentistry.org/wp-content/uploads/2018/10/ATDA_TeledentalPracticePositionPaper.pdf) Accessed May 7, 2020.
- Jampani ND, Nutralapati R, Dontula BSK, Boyapati R. Applications of teledentistry: a literature review and update. *J Int Soc Prev Community Dent*. 2011;1:37-44.
- Wicklund E. *Dentists use telehealth to improve access to care—and fight a phobia*. MHealthIntelligence; Available at: <https://mhealthintelligence.com/news/dentists-use-telehealth-to-improve-access-to-care-and-fight-a-phobia> Accessed May 7, 2020.
- Smith WR, Atala AJ, Terlecki RP, et al. Implementation guide for rapid integration of an outpatient telemedicine program during the COVID-19 pandemic. *J Am Coll Surg*. 2020;231:216-222.e2.
- AAOMS White paper on telehealth and remote treatment. 2020. Available at: [https://www.aaoms.org/docs/govt\\_affairs/advocacy\\_white\\_papers/telehealth\\_remote\\_treatment.pdf](https://www.aaoms.org/docs/govt_affairs/advocacy_white_papers/telehealth_remote_treatment.pdf) Accessed May 7, 2020.
- HHS.gov. *Notification of enforcement discretion for telehealth remote communications during the COVID-19 nationwide public health emergency*. Available at: <https://www.hhs.gov/hipaa/for-professionals/special-topics/emergency-preparedness/notification-enforcement-discretion-telehealth/index.html> Accessed May 7, 2020.

22. American Medical Association. *Ethical practice in telemedicine*. Available at: <https://www.ama-assn.org/delivering-care/ethics/ethical-practice-telemedicine> Accessed May 7, 2020.
23. Ryan C. *Computer and Internet Use in the United States: 2016*. Washington, DC: United States Census Bureau; 2018.
24. CMS.gov. Additional background: sweeping regulatory changes to help U.S. healthcare system address COVID-19 patient surge Available at: <https://www.cms.gov/newsroom/fact-sheets/additional-backgroundsweeping-regulatory-changes-help-us-health-care-system-address-covid-19-patient>. Accessed June 25, 2020.
25. Medicaid Learning Network. Telehealth Services. 2020. Available at: <https://www.cms.gov/Outreach-and-Education/Medicare-Learning-Network-MLN/MLNProducts/Downloads/TelehealthSrvcsfctsh.pdf> Accessed June 24, 2020.
26. Wire Business. *Hasbro brings mouth piece challenge to the masses with new SPEAK OUT game*. Available at: <https://www.businesswire.com/news/home/20160624005633/en/Hasbro-Brings-Mouth-Piece-Challenge-Masses-New> Accessed May 8, 2020.

*Reprint requests:*

Neeraj Panchal  
51 N 39th Street  
Philadelphia  
PA 19104  
USA.  
[Npanchal@upenn.edu](mailto:Npanchal@upenn.edu)