

# Double-Sling Augmentation for Anterior Shoulder Dislocation

Jinzhong Zhao, M.D.



**Abstract:** Anterior capsule ligament deficiency occurs in complicated anterior shoulder dislocation and poses a challenge to surgeons because of the irreparability of the capsule labrum structure or the nonoptimal healing potential after repair. Single-sling augmentation with either conjoined tendon or the long head of the biceps brachii has been reported to enhance the anterior stability of the shoulder. However, single-sling augmentation may still not be enough in cases of complicated anterior shoulder dislocation. Thus we introduce a double-sling anterior shoulder augmentation technique in which both the conjoined tendon and the long head of the biceps brachii are transferred to the anterior inferior side of the glenoid. Our clinical experience indicates that this procedure is effective to address complicated anterior shoulder dislocation. We believe that the introduction of this technique will provide a special choice in the treatment of anterior shoulder dislocation.

Recurrent anterior shoulder dislocation is always combined with capsule ligament deficiency, especially in revision cases.<sup>1</sup> Because of the lack of endpoint restraint, a high failure rate may be encountered after routine capsule ligament repair or reconstruction. Single-sling augmentation provided by the transferred conjoined tendon or the long head of the biceps brachii (LHB) is an effective way to increase shoulder stability.<sup>2,3</sup> However, it is still uncertain whether single-sling augmentation is enough in complicated cases, especially in severe capsule-ligament defects. Thus we introduce a double-sling anterior shoulder augmentation technique that is a combined transfer of both the conjoined tendon-coracoid tip complex (CTCTC)<sup>4</sup> and the LHB.<sup>5</sup> The main indication

of this technique is severe capsule ligament deficiency (Table 1).

## Surgical Technique

General and brachial plexus anesthesia are administered. The patient is placed in the lateral decubitus position with the arm in 30° abduction and with 10 pounds of traction.

## Preparation of CTCTC

A 2 to 3 cm—long longitudinal incision (anterior incision) is made on the lateral side of the coracoid tip. Through the anterior incision, the CTCTC is exposed. The coracoid osteotomy is performed at a site 8 mm proximal from the coracoid tip. The fascia tissue on the medial, lateral, and inferior sides of the coracoid tip is released. The CTCTC is pulled out of the incision. A bur is used to flatten the bony end of the CTCTC. A 4.5-mm hole is drilled through the middle of the coracoid tip. (Fig 1, Table 2, Video 1).

Two no. 2 UHMWPE sutures (Ultrad; Smith & Nephew, Andover, MA) are used to braid the conjoined tendons in a whipstitch style, with all suture ends passing through the coracoid hole. One set of double-button adjustable loops is made with a no. 5 UHMWPE suture and two miniplates, mainly one coracoid plate and one glenoid plate (Ultrad; Smith & Nephew). The self-made adjustable loop is passed through the coracoid hole with the coracoid plate over the anterior orifice. The braiding sutures are passed through the two middle holes of the glenoid plate. The

From the Department of Sports Medicine, Shanghai Sixth People's Hospital, Shanghai Jiao Tong University, Shanghai, China

Funded by National Natural Science Foundation of China (grants 31972923 and 81772341). The author reports no conflicts of interest in the authorship and publication of this article. Full ICMJE author disclosure forms are available for this article online, as [supplementary material](#).

Received September 25, 2020; accepted October 28, 2020.

Address correspondence to Jinzhong Zhao, M.D., Department of Sports Medicine, Shanghai Sixth People's Hospital, Shanghai Jiao Tong University, 600 Yishan Road, Shanghai 200233, China. E-mail: [zhaojinzhong@vip.163.com](mailto:zhaojinzhong@vip.163.com) or [jz Zhao@sjtu.edu.cn](mailto:jz Zhao@sjtu.edu.cn)

© 2020 by the Arthroscopy Association of North America. Published by Elsevier. This is an open access article under the CC BY-NC-ND license (<http://creativecommons.org/licenses/by-nc-nd/4.0/>).

2212-6287/201621

<https://doi.org/10.1016/j.eats.2020.10.066>

**Table 1.** Indications of Double-Sling Augmentation for Anterior Shoulder Dislocation

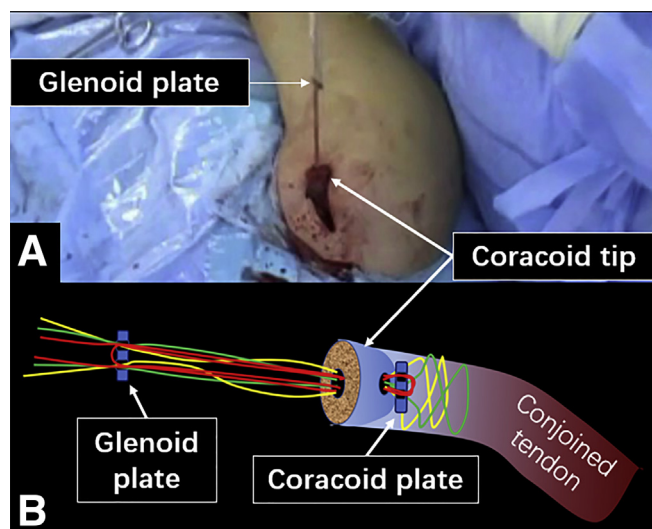
Indications of double-sling technique for anterior shoulder instability
Severe capsule ligament dysplasia in primary surgery
Capsule ligament degeneration or defect in revision surgery
Capsule ligament defect in case of fixed anterior shoulder dislocation
Combination of epilepsy
Contraindication
Conjoined tendon or long head of biceps brachii tendon defect
Relative contraindication
Severe glenoid osteoporosis

incision is temporarily closed with the CTCTC left under it and used as routine anterior portal for subsequent procedure.

### Preparation of the LHB

The routine posterior and anterior superior portals are fashioned. A folded no. 2 polyethylene suture is passed through the intraarticular part of the LHB to ligate it. The LHB is cut near its conjunction with the superior labrum (Fig 2).

The arthroscope is placed into the anterior subdeltoid space via the anterior superior portal. A far lateral portal, which is located at the level of the coracoid process and approximately 1 cm anterior to the lateral midline of the arm, is fashioned. Via the far lateral portal, the LHB is detected and exposed at the superior



**Fig 1.** Fabrication of the conjoined tendon–coracoid tip complex (CTCTC). (A) Gross view after fabrication (superior view of right shoulder in lateral decubitus position of the patient). The CTCTC is connected to a double-plate adjustable loop. (B) Illustration of fabrication of the CTCTC. The conjoined tendon is braided, with all the suture ends passing through the coracoid hole. One set of double-button adjustable loops is used to set the coracoid plate over the anterior orifice of the coracoid hole. The braiding sutures are passed through the two middle holes of the glenoid plate.

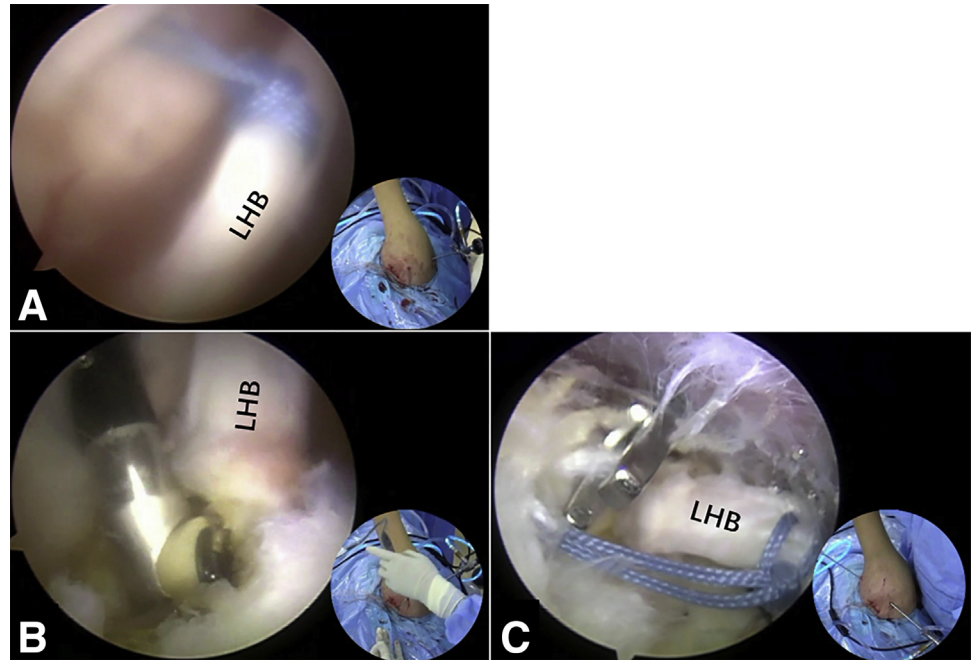
**Table 2.** Step-By-Step Procedure of Double-Sling Augmentation for Anterior Shoulder Dislocation

1. A 2 to 3 cm–long longitudinal incision (anterior incision) is made on the lateral side of the coracoid tip. The CTCTC is exposed.
2. The coracoid osteotomy is performed at a site 8 mm proximal from the coracoid tip. The CTCTC is pulled out of the incision.
3. A hole is drilled through the middle of the coracoid tip. The bony end of the coracoid tip is flattened.
4. The conjoined tendon is braided with two no. 2 UHMWPE sutures, with all the suture ends passing through the coracoid hole.
5. A self-made double-plate adjustable loop is passed through the coracoid hole to set coracoid plate over the anterior orifice.
6. The braiding sutures are passed through the middle two holes of the glenoid plate.
7. The anterior incision is temporarily closed.
8. A folded no. 2 polyethylene suture is passed through the intra-articular part of the long head of biceps brachii (LHB) to ligate it. The LHB is cut near its conjunction with the superior labrum.
9. The LHB is detected and exposed at the superior edge of the pectoralis major.
10. The LHB is pulled out of the joint and bicipital groove to the anterior subdeltoid space, and then out of the far anterior portal.
11. The LHB is braided with three No. 2 UHMWPE sutures. The braiding sutures are tied to an adjustable loop with miniplate to form an LHB complex.
12. Two trans-glenoid tunnels are created, with the lower one to accommodate the transferred LHB and the higher one to accommodate the transferred CTCTC. One guide suture is placed through each tunnel.
13. The guide suture for LHB transfer is passed anteriorly through the subscapularis.
14. The guide suture passed through the subscapularis is found at the anterior side of the subscapularis and retrieved out of the anterior superior portal. The guide suture is rerouted with the LHB through the same canula.
15. The LHB complex is pulled through the subscapularis and glenoid tunnel till the miniplate is out of the posterior orifice of the inferior glenoid tunnel and flipped.
16. The LHB is pulled into the glenoid tunnel by reducing the adjustable loop.
17. The guide suture for the combined CTCTC structure is passed through the subscapularis at the 3:00 position of the glenoid.
18. The guide suture for CTCTC transfer is found at the anterior side of the subscapularis and pulled out of the anterior superior portal.
19. The anterior incision is reopened. The guide suture is rerouted through the anterior incision along with the combined CTCTC structure.
20. The suture ends from combined-CTCTC structure are pulled through the subscapularis and glenoid tunnel and out of the posterior portal.
21. With constant pulling on the combined CTCTC structure, the subscapularis muscle around the CTCTC is pushed anteriorly to make sure the CTCTC is passed through the subscapularis and can be attached to the glenoid.
22. The adjustable loop of in the CTCTC complex is reduced. All sutures passing through the glenoid min plate are tied on the miniplate to fix the transferred CTCTC.

CTCTC, conjoined tendon–coracoid tip complex; LHB, long head of biceps brachii.

edge of the pectoralis major. A far anterior portal, which is located at the level of the distal edge of the pectoralis major and just over the route of the LHB, is created.

**Fig 2.** Detachment and extraction of the long head of biceps brachii (LHB). (A) The LHB is ligated (intraarticular view of right shoulder in lateral decubitus position through the posterior portal). (B) The LHB is detached (intraarticular view of right shoulder in lateral decubitus position through the posterior portal). The LHB is pulled out of the joint and the bicipital groove to the anterior subdeltoid space (anterior subdeltoid view of right shoulder in lateral decubitus position through the far lateral portal).



The LHB is pulled out of the joint and bicipital groove to the anterior subdeltoid space (Fig 2) and then out of the far anterior portal (Fig 3). Three no. 2 UHMWPE sutures are used to braid the LHB in a whipstitch style. The width of the braided tendon segment is measured. Then the braiding sutures are tied to an adjustable loop with a miniplate (Rigid Loop; Arthrex) to form an LHB complex (Fig 3).

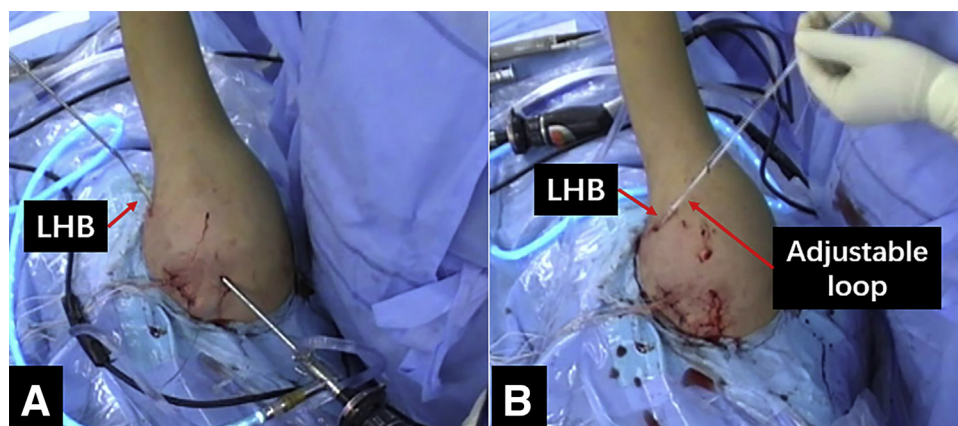
### Creating Glenoid Tunnels

Under observation through the anterior superior portal, a customized glenoid guide is placed in the joint through the posterior portal to create inferior glenoid tunnel from the 7:30 to 4:30 position of the glenoid

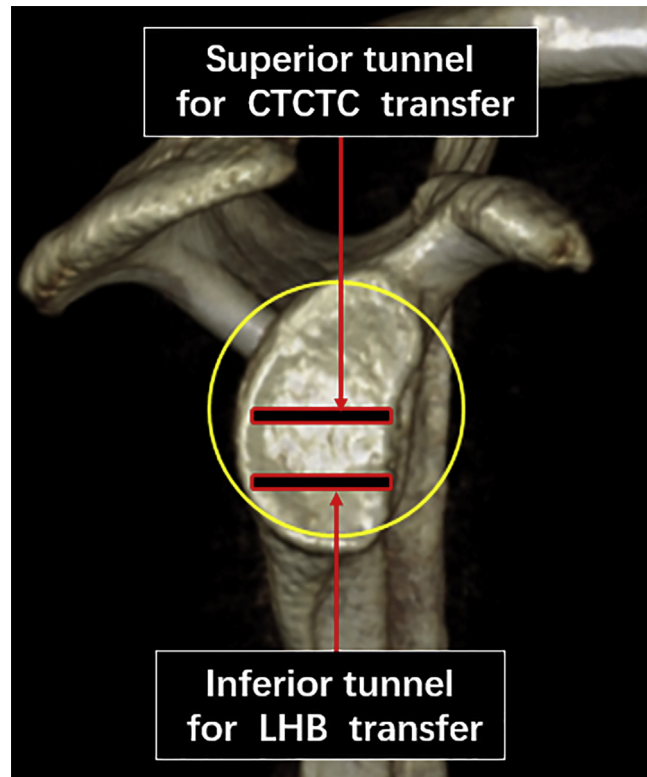
(right shoulder) using a K-wire, a 4.5 mm cannulated drill, and a retrograde drill (FlipCutter; Arthrex). One guide suture is placed through inferior tunnel (Figs 4 and 5). Then the superior tunnel is created from the 9 o'clock to 3 o'clock positions using a K-wire and a 4.5 mm cannulated drill. One guide suture is also placed through the superior tunnel (Figs 4 and 6). The tunnels are fashioned 7 mm below the glenoid surface, as parallel to each other as possible.

### Transfer of the LHB complex

Under observation through the anterior superior portal, a suture retriever is placed into the joint through the posterior portal to hold the anterior end of the guide



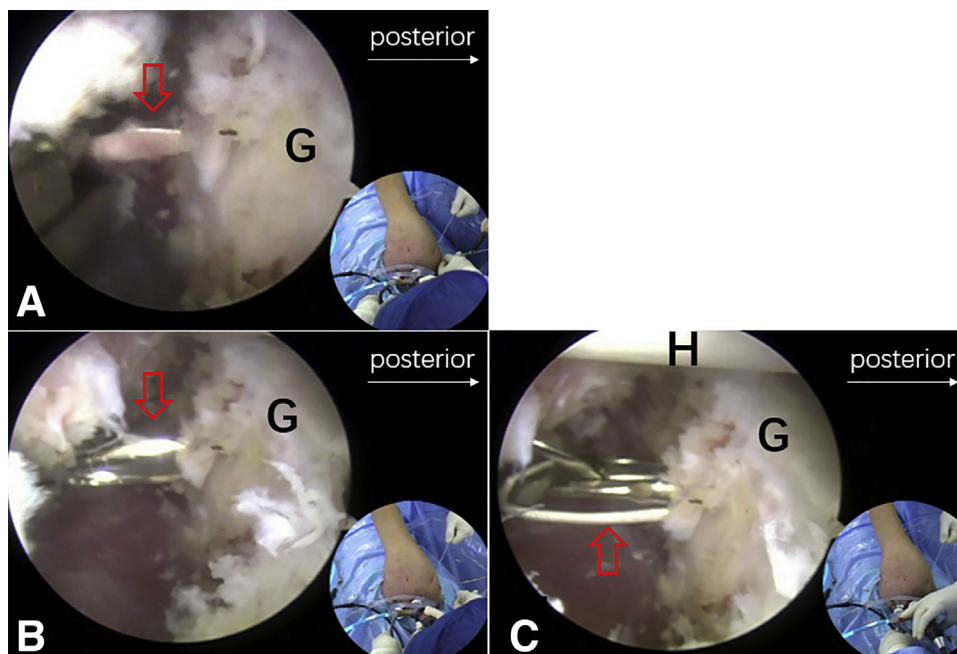
**Fig 3.** Fabrication of the complex of the long head of biceps brachii (LHB) (superior view of right shoulder in lateral decubitus position of the patient). (A) The LHB is pulled out of the far anterior portal. (B) The LHB is braided and tied on an adjustable loop with a miniplate to form an LHB complex.



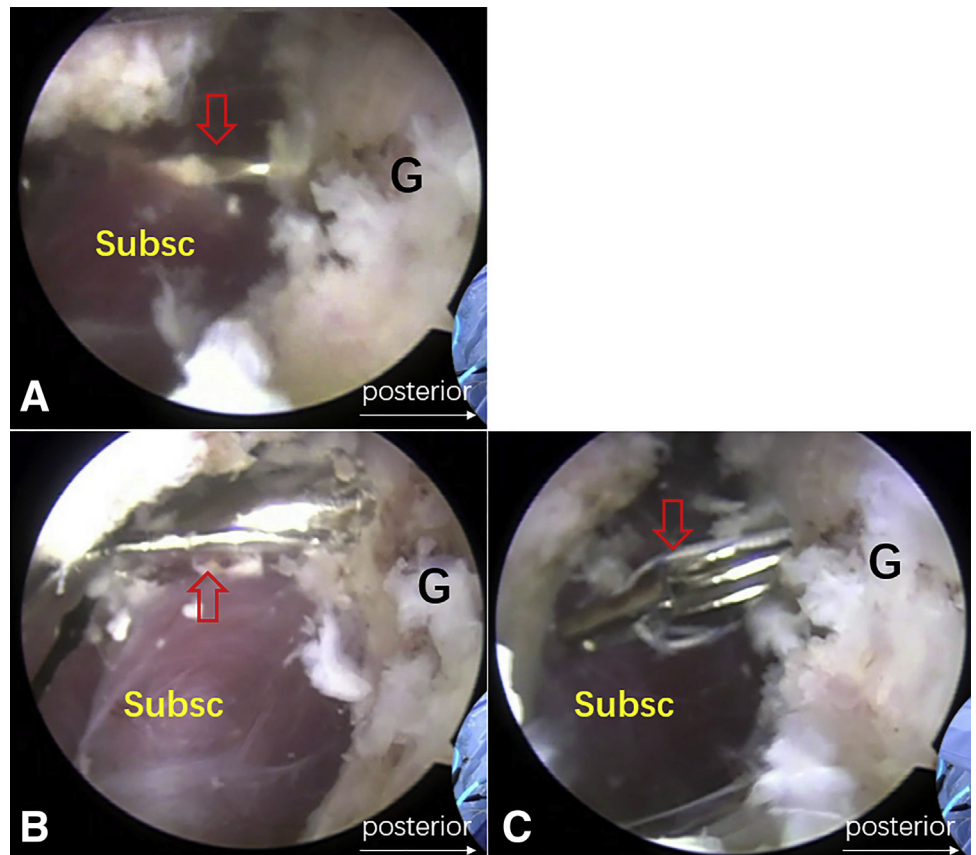
**Fig 4.** Illustration of the two transglenoid tunnels (right shoulder).

suture from the low glenoid tunnel and pass the guide suture anteriorly through the subscapularis at the 4:30 position of the glenoid (left shoulder) (Fig 7).

The arthroscope is placed through the far lateral portal to the anterior subdeltoid space and pushed along the anterior side of the subscapularis in an



**Fig 5.** Creating the inferior glenoid tunnel to accommodate the transferred long head of biceps brachii (intraarticular view of right shoulder in lateral decubitus position through the anterior superior portal). The glenoid tunnel is created with a K-wire (A), a 4.5 mm drill (B), and a retrograde drill. One guide suture is passed through the glenoid tunnel (C). G, glenoid; H, humeral head.



**Fig 6.** Creating the superior glenoid tunnel to fix the transferred conjoint tendon-coracoid tip complex (intraarticular view of right shoulder in lateral decubitus position through the anterior superior portal). The glenoid tunnel is created with a K-wire (A) and a 4.5 mm drill (B). One guide suture is passed through the glenoid tunnel (C). G, glenoid.

inferior-medial direction. The guide suture passed through the subscapularis is found (Fig 8) and retrieved out of the anterior superior portal.

A cannula is pushed into the anterior subdeltoid space over the LHB complex through the far anterior portal. A suture retriever is placed through this cannula to pull the guide suture out. With the guide suture, the LHB complex is pulled through the subscapularis (Fig 8) and glenoid tunnel until the miniplate is out of the posterior orifice of the inferior glenoid tunnel and flipped. With observation through the anterior superior portal, the anterior side of the glenoid is exposed to locate the LHB complex. The LHB is pulled into the glenoid tunnel by reducing the adjustable loop.

#### **Transfer of the combined-CTCTC structure**

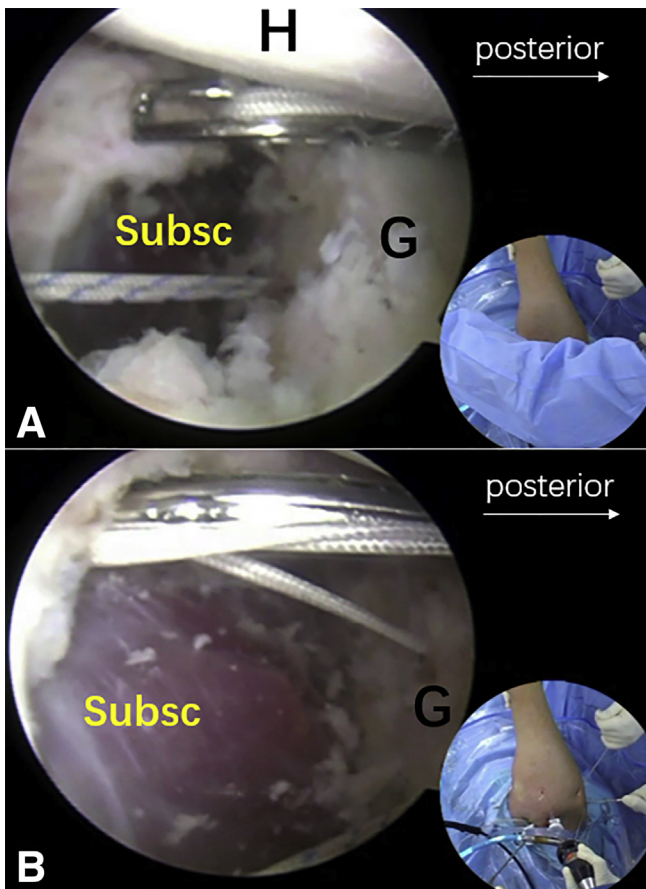
With observation through the anterior superior portal, a suture retriever is placed into the joint through

the posterior portal to hold the anterior end of the guide suture for the combined CTCTC structure and pass it through the subscapularis at the 3:00 position of the glenoid (Fig 9).

The arthroscope is placed through the anterolateral portal and pushed along the anterior side of the subscapularis in an inferior medial direction. The guide suture for CTCTC transfer is found (Fig 9) and pulled out of the anterior superior portal.

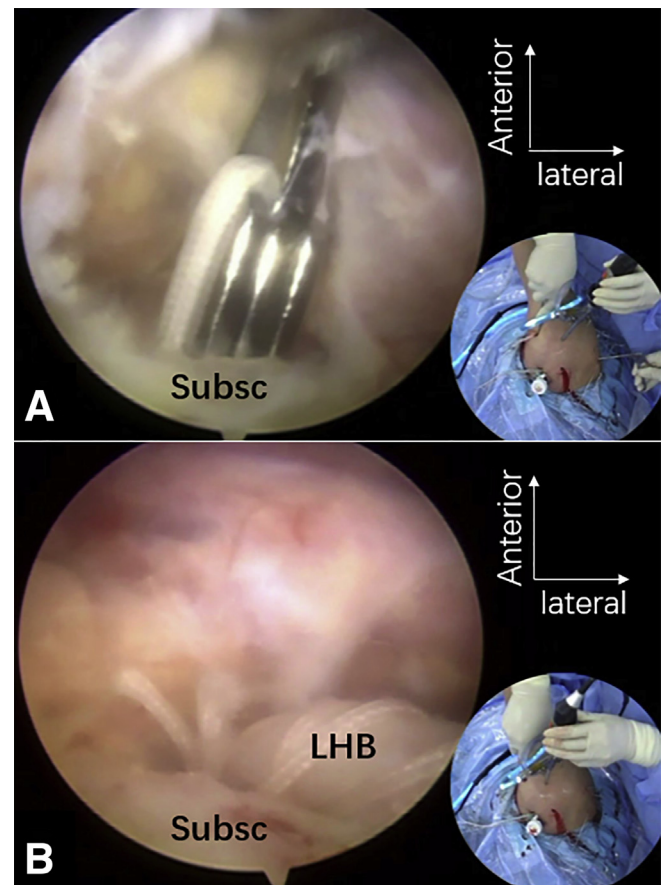
The anterior incision is opened. The guide suture is rerouted through the anterior incision along with the combined CTCTC structure. By pulling the guide suture back, the suture ends from combined CTCTC structure are pulled through the subscapularis (Fig 9) and glenoid tunnel and out of the posterior portal.

Under observation through the anterior superior portal, the anterior side of the glenoid is exposed to locate the combined CTCTC structure. A switching stick is placed



**Fig 7.** Holding (A) and passing (B) the guide suture from the inferior glenoid tunnel through the subscapularis (intra-articular view of right shoulder in lateral decubitus position through the anterior superior portal). G, glenoid; H, humeral head.

through the anterior portal. With constant backward pulling of the combined CTCTC structure, the subscapularis muscle around the CTCTC is pushed anteriorly to ensure the CTCTC is passed through the subscapularis and can be attached to the glenoid (Figs 10 and 11). The miniplate on the combined CTCTC structure is flipped, and the adjustable loop is reduced to fix the CTCTC to the glenoid. All sutures passing through the glenoid miniplate are tied on the miniplate.

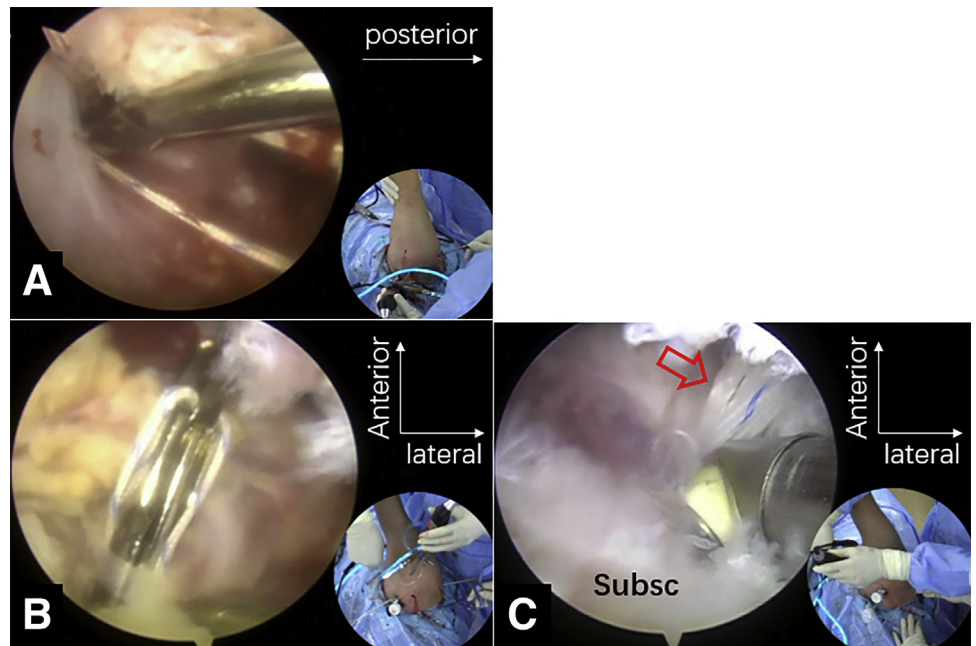


**Fig 8.** Finding the guide suture at the anterior side of the subscapularis (A) and pull the complex of the long head of the biceps brachii through the subscapularis (B) (anterior-to-subscapularis view of the right shoulder in the lateral decubitus position through the far lateral portal). LHB, the long head of the biceps brachii; Subsc, subscapularis.

## Discussion

Capsule ligament deficiency is quite common in complicated anterior shoulder instability. Glenoid bone grafting through Eden-Hybbinette procedure is a salvaging, nonanatomic reconstruction technique to deal with this condition and has with unpredictable results.<sup>6,7</sup> Sling augmentation through the Bristow-Latarjet procedure is biomechanically and clinically helpful.

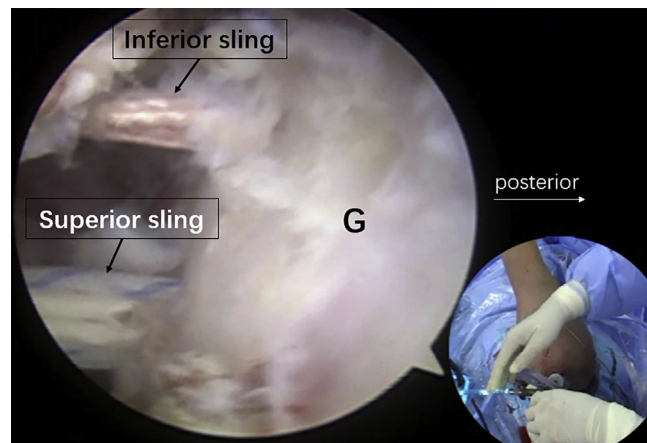
**Fig 9.** Transfer of the conjoint tendon-coracoid tip complex (CTCTC). (A) The guide suture from the superior glenoid tunnel is passed through the subscapularis (intraarticular view of right shoulder in lateral decubitus position through the anterior superior portal). (B) The guide suture is found at the anterior side of the subscapularis (anterior-to-subscapularis view of right shoulder in lateral decubitus position through the far lateral portal). (C) The CTCTC is pulled through the subscapularis (arrow) (anterior-to-subscapularis view of right shoulder in lateral decubitus position through the far lateral portal). Subsc, subscapularis.



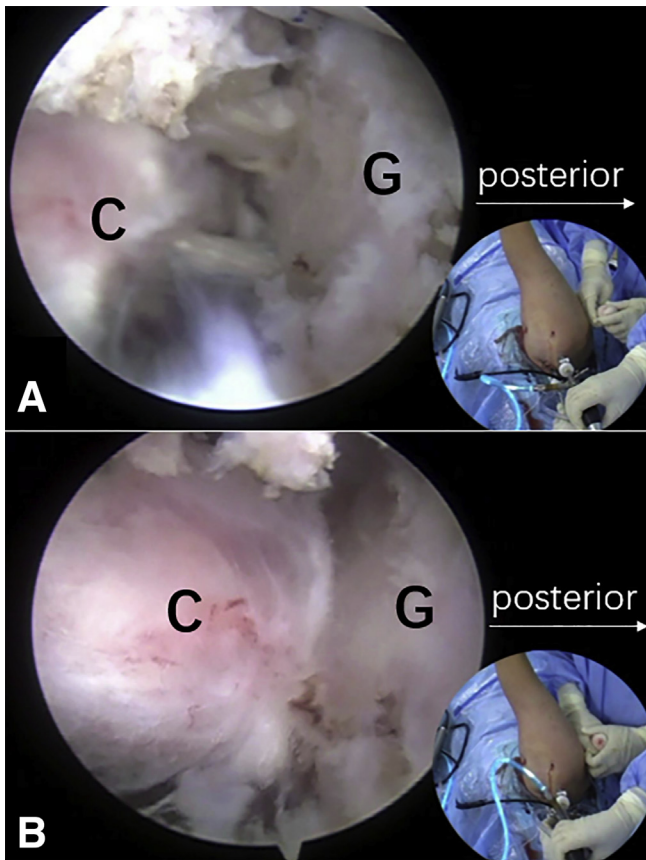
The reason to use double-sling augmentation to address anterior capsule deficiency is first because single-sling augmentation by the transferred conjoint tendon alone was reported to be not enough to prevent recurrence. The second reason is that LHB transfer can really help to augment the shoulder and reduce

instability.<sup>3</sup> Thus we hope that by combined conjoint tendon and LHB transfer, we can enhance the stability of the shoulder to the most.

This technique is especially indicated for patients with epilepsy because recurrent anterior dislocation with epilepsy is a serious condition with a high failure rate after

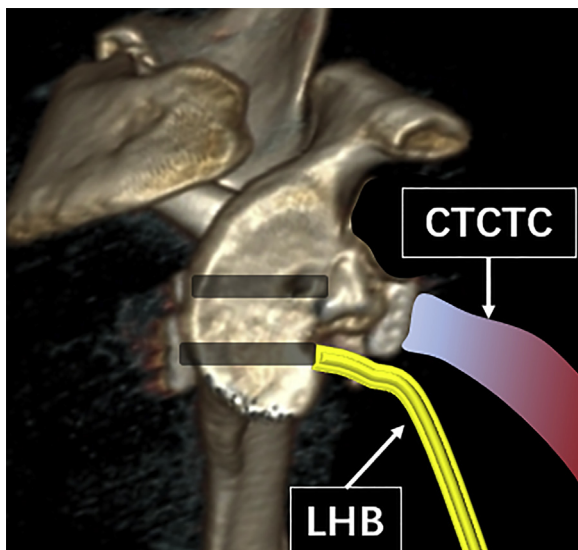


**Fig 10.** The adjustable loop to fix the inferior sling and the adjustable loop and braiding sutures to fix the superior sling (intraarticular view of right shoulder in lateral decubitus position through the anterior superior portal).



**Fig 11.** The coracoid tip is passed through the subscapularis (A) and attached to the glenoid (B) (intraarticular view of right shoulder in lateral decubitus position through the anterior superior portal). G, glenoid; C, coracoid tip.

surgical treatment, even after the Latarjet procedure.<sup>8,9</sup> We hope that using two slings would reduce the failure rate. Our small series clinical results are promising.



**Fig 12.** Illustration of the two slings after transfer of the long head of the biceps brachii (LHB) and the conjoint tendon-coracoid tip complex (CTCT) (right shoulder).

**Table 3.** Pearls and pitfall of double-sling augmentation for anterior shoulder dislocation

1. The surgeon should make sure the pectoralis minor muscle is fully detached from the medial side of the coracoid tip. Otherwise, the transfer of the CTCTC will be hindered.
2. In braiding the CTCTC, the surgeon should make sure to wrap only the superior tendon part. Suture wrapping that is too deep will cut the muscle part of the conjoined tendon.
3. Make sure the LHB is fully detached from the superior labrum and separated from the neighboring tissue. Otherwise, outpulling will be hindered.
4. In the anterior subdeltoid space, locating the superior edge of the pectoralis major first will facilitate locating the LHB distal to the bicipital groove.
5. In creating the glenoid tunnel, it should not be too shallow; otherwise, the glenoid surface may be broken.
6. Measure the width of the glenoid to calculate the tunnel length and ensure a 5 mm long nonenlarged part is left at the posterior side. Whole-tunnel enlargement will make suspension fixation with a miniplate impossible.
7. Pass the guide suture through the subscapularis using a suture retriever along the glenoid surface to prevent too medial penetration.
8. Using an instrument to detect the hard point at the anterior side of the subscapularis will facilitate locating the subscapularis-penetrating suture retriever.
9. When tying the braiding sutures onto the miniplate over the posterior orifice of the glenoid tunnel, make sure to push the miniplate tightly against the glenoid bone.
10. When there is thick scar tissue around the penetrating point of the subscapularis muscle, it should be released. Otherwise, passing the CTCTC through the subscapularis muscle will be hindered.

CTCTC, conjoined tendon-coracoid tip complex; LHB, long head of biceps brachii.

This procedure is a combination of arthroscopic CTCTC transfer and LHB transfer (Fig 12). In this procedure, the most difficult manipulation is to find the guide sutures at the anterior side of the subscapularis for the transfer of the CTCTC and the LHB (Table 3), and the main disadvantage of this technique

**Table 4.** Risks and limitations of this technique

1. This technique is designed for capsule ligament defect in case of anterior shoulder dislocation. It is not suitable for patients with severe glenoid defect, for which glenoid amendment should be the main consideration.
2. This technique relies on the anchorage of both slings to the glenoid. In case of severe glenoid defect or osteoporosis, or too shallow glenoid tunnels, the anchorage may fail.
3. When passing the guide suture through the inferior glenoid tunnel through the subscapularis, the penetrating site is close to the axillary nerve, which makes the penetrating manipulation endangering the axillary nerve. Care should be taken to lever the suture retriever to the lateral side of the shoulder during the penetrating manipulation to reduce the risks.
4. In case of wide coracoid tip, pulling it through the subscapularis may be difficult without splitting the subscapularis first. Splitting the subscapularis with radiofrequency probe may also endanger the axillary nerve. Expose the axillary nerve and protect it during splitting the subscapularis is critical.



is that the axillary nerve may be endangered (Table 4). However, compared with the arthroscopic Latarjet procedure, in which the subscapularis must be split vigorously for the passage of a larger coracoid fragment, both CTCTC and LHB transfer are much easier.

### References

1. Dewing CB, Horan MP, Millett PJ. Two-year outcomes of open shoulder anterior capsular reconstruction for instability from severe capsular deficiency. *Arthroscopy* 2012;28:43-51.
2. DeFroda SF, Gil JA, Owens BD. Recurrent shoulder stabilization with open Bankart repair and long head biceps transfer. *J Orthop* 2018;15:401-403.
3. Bokshan SL, Gil JA, DeFroda SF, Badida R, Crisco JJ, Owens BD. Biomechanical comparison of the long head of the biceps tendon versus conjoint tendon transfer in a bone loss shoulder instability model. *Orthop J Sports Med* 2019;7:2325967119883549.
4. Tang J, Zhao J. Arthroscopic transfer of the conjoined tendon-coracoid tip complex for anterior shoulder instability. *Arthrosc Tech* 2017;7:e33-e38.
5. Tang J, Zhao J. Arthroscopic transfer of the long head of the biceps brachii for anterior shoulder instability. *Arthrosc Tech* 2017;6:e1911-e1917.
6. Boileau P, Duysens C, Saliken D, Lemmex DB, Bonneville N. All-arthroscopic, guided Eden-Hybinette procedure using suture-button fixation for revision of failed Latarjet. *J Shoulder Elbow Surg* 2019;28:e377-e388.
7. Giannakos A, Vezeridis PS, Schwartz DG, Jany R, Lafosse L. All-arthroscopic revision Eden-Hybinette procedure for failed instability surgery: Technique and preliminary results. *Arthroscopy* 2017;33:39-48.
8. Erşen A, Bayram S, Birişik F, Atalar AC, Demirhan M. The effectiveness of the Latarjet procedure for shoulder instability in patients with epilepsy. *Orthop Traumatol Surg Res* 2017;103:1277-1282.
9. Khater AH, Sobhy MH, Said HG, et al. Latarjet procedure for anterior shoulder instability due to Tramadol-induced seizures: a multicenter study. *Am J Sports Med* 2016;44:957-962.