


CLINICAL ARTICLE

Percutaneous Endoscopic Transforaminal Lumbar Discectomy *via* Eccentric Trepan foraminoplasty Technology for Unilateral Stenosed Nerve Root Canals

Hong-jun Zou, MSc, Yong Hu, MSc, Jin-bo Liu, PhD , Jun Wu, PhD

Department of Spinal Surgery, The Third Affiliated Hospital of Soochow University, Changzhou, China

Objective: To evaluate the clinical outcomes of percutaneous lumbar foraminoplasty for unilateral stenosed nerve root canals.

Methods: The article is a retrospective analysis. From May 2016 to April 2017, 32 patients with lumbar spinal stenosis syndrome (unilateral stenosed nerve root canals) were treated with percutaneous endoscopic transforaminal lumbar discectomy (PETLD). The study included 15 men and 17 women, with an average age of 53.8 ± 15.4 years, ranging from 24 to 78 years. The indexes used for preoperative and postoperative 1 day, 3 months, and final follow up were the visual analogue scale (VAS) for lumbar and leg, the Oswestry disability index (ODI), and the modified Macnab criteria. All patients were followed up for an average 6 months after the operation.

Results: The average operative time was 75.82 ± 10.58 min, the average blood loss was 15.83 ± 3.75 mL, and the average hospital stay after surgery was 6.2 ± 4.6 days. The VAS score (leg) decreased from 6.94 ± 0.50 preoperatively to 1.16 ± 0.45 at the final follow up ($P < 0.05$) and ODI were obviously improved, from preoperative evaluation of 80.19 ± 5.55 to 9.44 ± 1.16 at the final follow up ($P < 0.05$). However, the postoperative VAS score (lumbar) did not show an improvement, reducing from 1.78 ± 0.49 preoperatively to 1.62 ± 0.55 at the final follow-up ($P > 0.05$). According to the modified Macnab criteria, the outcome showed that the excellent and good rate was 90.6%. There were three patients with hip soreness, and nerve root symptoms were relieved.

Conclusion: Percutaneous endoscopic transforaminal lumbar discectomy has a satisfactory clinical effect in the treatment of lumbar spinal stenosis syndrome, especially for unilateral stenosed nerve root canals, and in decompressing the lateral recess and relieving the nerve root symptoms.

Key words: Eccentric trepan foraminoplasty technology; Lumbar spinal stenosis syndrome; PTED; Unilateral stenosed nerve root canals

Introduction

Lumbar spinal stenosis is a frequently-occurring disease, which can lead to leg pain and low back pain, especially when walking¹. This degenerative condition severely affects the walking ability of patients, thereby resulting in poor

quality of life². The most common causes of pain are the herniation of intervertebral discs, the gradual narrowing of the spinal canal, and the hypertrophy of vertebral plates¹. Lumbar spinal stenosis is usually manifested as nerve root canal stenosis. Effectively decompressing the nerve root

Address correspondence: Jin-bo Liu, PhD, Department of Spinal Surgery, The Third Affiliated Hospital of Soochow University, No. 185 Juqian street, Changzhou, Jiangsu, China 213003 Tel: +86-0519-68872161; Fax: +86 519 68870000; Email: liujinbo2017@126.com

Disclosure: Each author certifies that he or she has no commercial association that might pose a conflict of interest in connection with the submitted manuscript.

Received 18 January 2020; accepted 3 June 2020



canal can be an optional treatment for lumbar spinal stenosis.

For an isolated lumbar lateral recess stenosis, traditionally posterior direct decompression with or without fusion is the best available treatment^{3,4}. However, this involves significant disruption to the posterior elements, causing postoperative segmental instability and scar formation. In addition, the scar formation and denervation can cause chronic low back pain. Compared with traditional discectomy, percutaneous endoscopic transforaminal lumbar discectomy (PETLD) has some advantages, such as a clearer operative field, less trauma, and quick recovery. It is a safe and effective minimally invasive surgery that can be used for decompression of nerve tissue without destroying the stability of the spinal posterior structure^{5,6}.

Currently, PETLD decompression for lateral recess stenosis is still a challenge. Lateral and ventral structures, such as the ventral of the superior articular process (SAP) and herniated discs (HD) are hard to remove, and reduction of the superior endplate is difficult⁷⁻⁹. Moreover, it is difficult to deal with dorsal compression arising from hypertrophied SAP and flavum ligament^{10,11}. To achieve effective dorsal decompression of the lateral recess, we use eccentric trepan foraminoplasty technology for hypertrophied SAP and flavum ligament. From May 2016 to April 2017, a total of 32 patients with lateral recess stenosis were treated with PETLD under fluoroscopic guidance with eccentric trepan foraminoplasty technology and were followed up to an average of 6 months after the operation. Notes on the technique and outcome at 6 months follow-up are included in this report.

Materials and Methods

Inclusion Criteria and Exclusion Criteria

Inclusion criteria were: (i) clinical signs of neurogenic claudication with or without sciatica; (ii) patients who presented with recurrent low back pain or lower limb symptoms due to unilateral lumbar stenosis; (iii) concordant imaging evidence of lateral recess stenosis (the anteroposterior diameter of the lateral recess was less than 4 mm) with or without HD at the same level demonstrated on preoperative MRI and/or CT scans; (iv) conservative treatment failed to relieve recurrent pain; and (v) PETLD was received.

Exclusion criteria were: (i) segmental instability on preoperative extension-flexion radiographs; (ii) severe central stenosis on preoperative MRI or CT; (iii) cauda equina syndrome; (iv) combined very highly migrated HD beyond the low rims of adjacent pedicles; (v) iliac crest higher than L5 transverse process without enough space for extreme lateral approach to L5S1 foramen.

This study was approved by the ethics committee of our hospital.

Methods

Preoperative Preparation

Dynamic X-ray scattering, MRI, or CT scans were performed before the operation to define the pathological type and

diseased region. The intervertebral space was positioned using X-ray C-arm systems with anteroposterior perspective, and then a cross or oblique line parallel to the intervertebral space was marked 12 to 16 cm away from the posterior midline using Kirschner wire, which determined the puncture position (12 to 14 cm at the L₄₋₅; 14 to 16 cm at the L_{5-S1}). A solution of 3000 mL normal saline was prepared for intraoperative continuous irrigation through the endoscope.

Anesthesia Positions

All patients were placed on the operating bed in the prone position. A chest pillow was used to make abdominal dangling. The surgical bed was folded to maintain a bend in the knee and coxa. All patients were given 1% lidocaine as selective local anesthesia.

Surgical Procedure

Under direct fluoroscopic visualization, a #15 spinal needle was used to infiltrate the local anesthetic to the facet joint, such that the spinal needle was left in place as a guide. The correct position of the needle tip was confirmed using both anteroposterior and lateral projections. The needle was parallel to the disc space, midway between the endplates, proximal to the annulus, with the tip lateral to the medial border of the pedicles. A 3 to 5-mm stab incision was made at the entry site of the needle. The flexible guide wire was then placed through the spinal needle. The smallest cannulated dilator (the diameter was 2.5 mm) was used to slip into the ventral of the SAP *via* the guide wire (floating guide rod technology). The spinal needle was withdrawn. The larger cannulated dilator expands step by step to subsequently expand the soft tissues. Subsequently larger diameters of trepans (the diameter was 7.6 mm) trim targeted osteophyte. The tail of the trepan is moved to the ventral side, so that the head of the trepan is attached to the SAP. In this way, the SAP osteophyte was removed. A working tube with a diameter of 7.5 mm was inserted into the target disc tissue, and an endoscope was placed in the working one. (Fig. 1 shows the operation schematic diagram).

Postoperative Management

Patients were discharged 2 to 3 days after surgery and performed strength exercises.

Outcome Measures

Visual Analogue Scale

The visual analogue scale (VAS) score system is used in the social and behavioral sciences to measure low back pain and leg pain. A 10-cm line is drawn on the paper. The end of the line is 0, indicating no pain. The other end is 10, indicating severe pain; the middle part represents different levels of pain. The patient is asked to mark the level of pain on the line according to how they feel: 0 means painless; 1-3 means mild pain that the patient could endure; 4-6 means the patient was in pain that could be endured and was able to

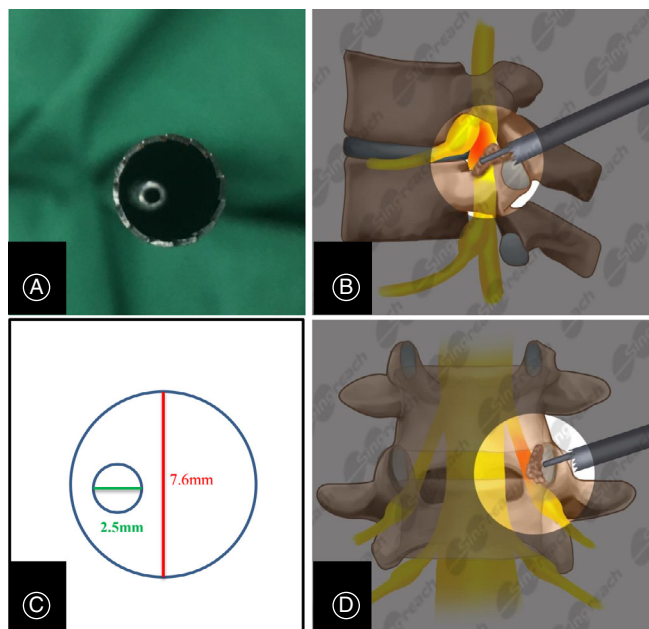


Fig 1 (A, B) Segmental stability on postoperative extension–flexion radiographs; preoperative (C) and postoperative (D) axial CT scan showing the lateral recess at the L₅ upper endplate level.

sleep; and 7–10 means the patient had intense pain and was unable to tolerate the pain.

Oswestry Disability Index

The Oswestry disability index (ODI) is a principal condition-specific outcome measure used in the management of spinal disorders and to assess patient progress in routine clinical practice. The ODI score system includes 10 sections: pain intensity, personal care, lifting, walking, sitting, standing, sleeping, sex life, social life, and traveling. For each section of six statements the total score is 5. Intervening statements are scored according to rank. If more than one box is marked in each section, take the highest score. If all 10 sections are completed the score is calculated as follows: total scored out of total possible score $\times 100$. If one section is missed (or not applicable) the score is calculated as (total score/(5 \times number of questions answered)) $\times 100\%$, where 0%–20% is considered mild dysfunction, 21%–40% is moderate dysfunction, 41%–60% is severe dysfunction, and 61%–80% is considered as disability. For cases with a score of 81%–100%, patients are either long-term bedridden or exaggerating the impact of pain on their life.

The Modified Macnab Criteria

The modified Macnab criteria were applied to evaluate the surgical outcome. The modified Macnab criteria contains four aspects: Excellent, where the symptoms completely

disappear and individuals return to their original work and life; Good, with slight symptoms, slightly restricted activities, and no impact on work and life; Fair, with alleviated symptoms, limited activities, and normal work and life affected; and Poor, with no difference before and after treatment, and possibly worse symptoms.

Statistical Analysis

Data were analyzed using SPSS 19.0 statistical analysis software (IBM, New York, NY). The continuous variables were expressed as mean \pm standard deviation and analyzed using the paired *t*-test and the rank-sum test. A value of *P* < 0.05 was considered significant.

Results

Demographic and Clinical Characteristics

This study was approved by our institutional review board and informed consent was obtained from each patient. Thirty-two consecutive patients undergoing PETLD under fluoroscopic guidance with eccentric trepan foraminoplasty technology for lumbar spinal stenosis between May 2016 to April 2017 were enrolled. A total of 32 patients with lumbar spinal stenosis syndrome were treated with PETLD, including 15 men and 17 women, with an average age of 53.8 ± 15.4 years, ranging from 24 to 78 years. All patients

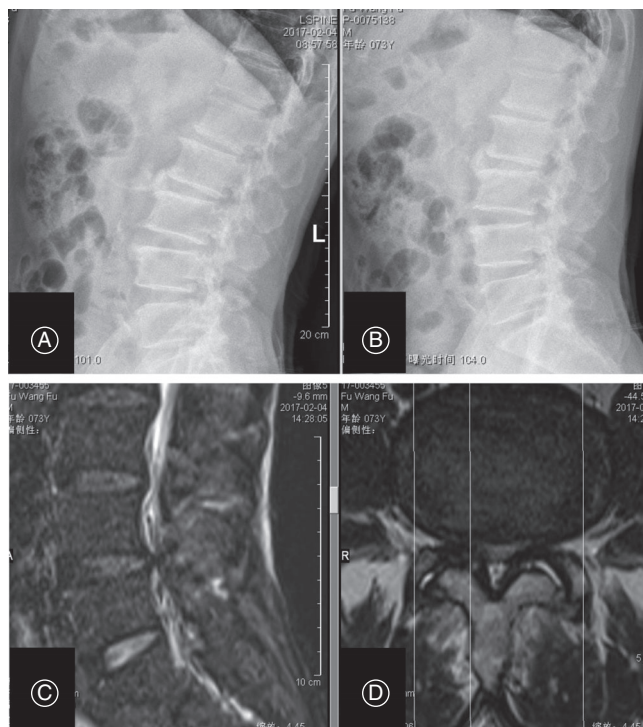


Fig 2 (A, B) Schematic diagram of the modified eccentric trepan foraminoplasty technology. (C, D) operation schematic diagram.

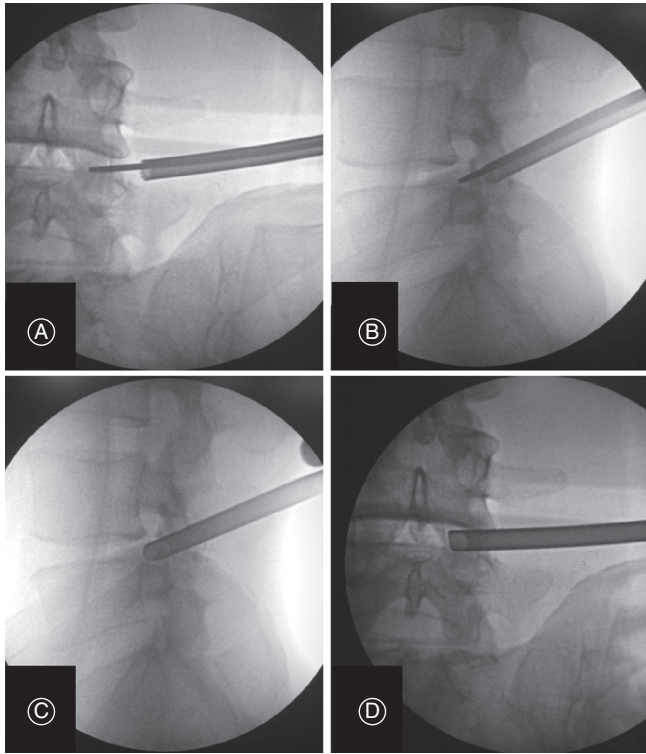


Fig 3 Preoperative extension–flexion radiographs and MRI of one patient (a 73-year-old man) with intermittent claudication. (A, B) Segmental stability on preoperative extension–flexion radiographs showed no instability; (C, D) Preoperative sagittal T2 MRI showing the pathology of L_{4/5} lumbar spinal stenosis.

were followed up for an average 6 months after the operation. All 32 patients suffered unilateral stenosed nerve root canals and underwent a single-level operation. The L_{4–5} segment was the most commonly involved level (24 levels), followed by L_{5–S₁} (6 levels), and L_{3–4} (2 levels).

General Results

The average operative time was 75.82 ± 10.58 min, the average blood loss was 15.83 ± 3.75 mL, and the average hospital stay after surgery was 6.31 ± 4.50 days. The typical case is seen in Figs 2–4. A 72-year-old male patient presented with intermittent claudication. Preoperative extension–flexion radiographs show stability (Fig. 2A,B). Preoperative lumbar CT (Fig. 4C) and MRI (Fig. 2C,D) suggested lateral recess stenosis (the anteroposterior diameter of the lateral recess was less than 4 mm). Postoperative extension–flexion radiographs show that PETLD has no effect on lumbar stability (Fig. 4A,B). Postoperative lumbar CT show that the lateral recess at the L₅ upper endplate level has been enlarged (Fig. 4D).

Visual Analogue Scale Score

The postoperative VAS score (lumbar) was not improved, declining from 1.78 ± 0.49 preoperatively to 1.62 ± 0.55 at the final follow-up. (Table 1) The postoperative VAS score (leg) decreased from 6.94 ± 0.50 preoperatively to 1.16 ± 0.45 at the final follow-up. All patients experienced significant relief from leg pain immediately after surgery. (Table 2).

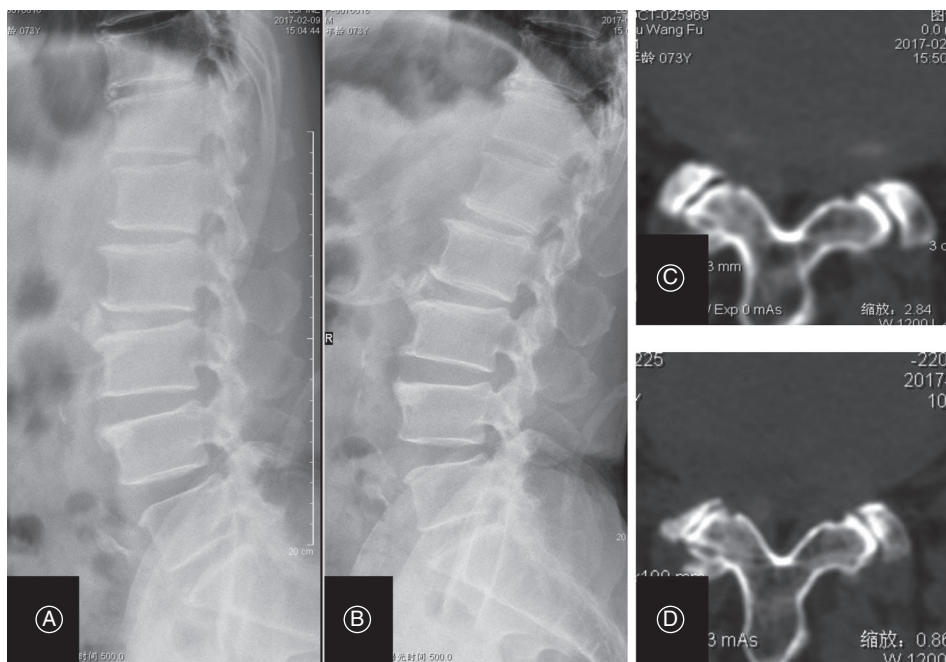


Fig 4 (A, B) Eccentric trepan foraminoplasty: the smallest cannulated dilator (the diameter was 2.5 mm) slipping into the ventral of the superior articular process (SAP) via the guide wire; larger diameters of trepans (the diameter was 7.6 mm) trim targeted osteophyte. The caudal of the trepan force to the ventral side, which causes the head side to attach to the SAP. (C, D) A working tube with a diameter of 7.5 mm was inserted into the target disc tissue.

TABLE 1 Visual analogue scale (VAS) of low back pain after surgery at 1 day, 3 months, and final follow-up

Time point	Preoperation	1 day postoperation	3 months postoperation	Final follow-up
VAS of low back pain	1.78 ± 0.49	1.62 ± 0.55	1.65 ± 0.54	1.62 ± 0.55
t	—	1.22	0.94	1.15
P	—	>0.05	>0.05	>0.05

Oswestry Disability Index Score

When compared with the preoperative evaluation (80.19 ± 5.55), the ODI score had obviously improved at 1 day postoperatively (29.63 ± 2.24), at 3 months (17.75 ± 2.26), and at final follow up (9.44 ± 1.16) (Table 3).

The Modified Macnab Criteria

According to the modified Macnab criteria, the outcome showed that the excellent and good rate was 90.6%. There were three patients with hip soreness, and the nerve root symptoms were relieved (Table 4).

Reoperations and Complications

There were no serious complications related to approach. No perioperative deaths were found in this study. Intraoperative dural laceration was found in one patient who complained of postoperative headache and neck pain, which was managed by removing the pillow from the horizontal position for 6 h after surgery, and healed on its own without other treatment. Exiting nerve roots could be irritated during PETLD. Postoperative dysesthesia due to existing dorsal root ganglion (DRG) injury or compression is a unique complication of PETLD. Among the 32 patients, postoperative dysesthesia manifested as hip soreness. Transient soreness of the hip occurred in three patients, which was not resolved even with lidocaine as a local block injection. All three patients obtained satisfactory results without nerve root symptoms. However, they all complained about the hip soreness until 3 months after surgery. Postoperative tissue swelling developed in one patient after using a large volume of irrigation fluid (6 L), with conditions spontaneously improving with conservative management. During the follow-up period, no patient relapsed, and no complications such as permanent nerve root damage, epidural hematoma, iatrogenic segmental instability, or superficial infection were found.

Discussion**Eccentric Trepan Foraminoplasty Technology**

Eccentric trepan foraminoplasty technology requires the smallest cannulated dilator (the diameter was 2.5 mm), slipping into the ventral of SAP via the guide wire (floating guide rod technology). Then, the larger cannulated dilator expands step by step to subsequently expand the soft tissues. Subsequently larger diameters of trepans (the diameter was 7.6 mm) trim the targeted osteophyte. The tail of the trepan is moved to the ventral side, so that the head of the trepan is attached to the SAP. In this way, the SAP osteophyte is removed (Fig. 3). Zhu *et al.*¹² report an eccentric technique for foraminoplasty in percutaneous endoscopy using a Kirschner wire inserted into the SAP to avoid slippage when the targeted bony structure is trimmed. Li *et al.*¹³ report that percutaneous lumbar foraminoplasty and PELD with a specially designed instrument is a less invasive, effective, and safe surgery for lumbar lateral recess stenosis with/without combined HD. The difference between the studies is that we use the floating guide rod technology to find the ventral side of the SAP and remove the osteophyte without taking out the inferior articular process so as to reduce the factors influencing the stability of the lumbar segment.

Influence of Eccentric Trepan Foraminoplasty Technology on the Stability of the Lumbar Segment

Osman *et al.*¹⁴ confirmed that endoscopic transforaminal decompression is a feasible alternative to current approaches. In their study, two-vertebra functional spinal units from 10 fresh cadaveric specimens were used to verify that transforaminal decompression produced a significantly larger increase in the intervertebral foraminal area than posterior decompression, without increasing the range of motion or neutral zone in any direction. Because there was no violation of the anatomic integrity of the spine in the transforaminal approach, the risk of surgically induced instability was minimized. The surgical technique used in this study is just like

TABLE 2 Visual analogue scale (VAS) of leg pain after surgery at 1 day, 3 months, and final follow up

Time point	Preoperation	1 day postoperation	3 months postoperation	Final follow up
VAS of leg pain	6.94 ± 0.50	2.47 ± 0.51	2.09 ± 0.39	1.16 ± 0.45
t	—	31.50	37.88	46.30
P	—	<0.05	<0.05	<0.05

TABLE 3 Oswestry disability index (ODI) score after surgery at 1 day; 3 months, and final follow up

Time point	Preoperation	1 day postoperation	3 months postoperation	Final follow up
ODI	80.19 ± 5.55	29.63 ± 2.24	17.75 ± 2.26	9.44 ± 1.16
t	—	51.35	58.40	74.86
p	—	<0.05	<0.05	<0.05

TABLE 4 Demographic data

Characteristics	No.
Patients	32 (100%)
Gender	
Male	15 (46.9%)
Female	17 (53.1%)
Age groups (years)	
0–39	7 (21.87%)
40–49	7 (21.87%)
50–59	2 (6.25%)
60–69	12 (37.5%)
70–79	4 (12.5%)
Average age (years)	53.8 ± 15.4
Level of lumbar	
L ₃₋₄	2 (6.25%)
L ₄₋₅	24 (75%)
L _{5-S₁}	6 (18.75%)
Symptom side	
Left	10 (31.25%)
Right	22 (68.75%)

that used by Osman *et al.* So there was no violation of the anatomic integrity of the spine in the transforaminal approach, the risk of surgically induced instability was minimized. No postoperative iatrogenic segmental instability was found in this study on postoperative extension–flexion radiographs.

Outcomes of Percutaneous Endoscopic Transforaminal Lumbar Discectomy via Eccentric Trepan Foraminoplasty

In previous studies, 69%–83% of patients reported the outcome as satisfactory, with a complication rate of 0–8.3% for transforaminal endoscopic surgery for lumbar stenosis^{15,16}. Our study found a 90.6% excellent and good rate in patients with lumbar

spinal stenosis who underwent PETLD *via* MacNab standard assessment. There were three patients with hip soreness after the operation, and nerve root symptoms were relieved.

These results are better than those of previous studies on endoscopic foraminoplasty. One of the reasons might be that eccentric trepan foraminoplasty technology can effectively improve foraminoplasty to protect nerve roots and ganglion.

This is an observational clinical case series study without control or comparison groups. Randomized controlled trials with long-term follow up comparing transforaminal endoscopic surgery with other surgical techniques are needed.

Conclusion

Percutaneous endoscopic transforaminal lumbar discectomy has a satisfactory clinical effect in the treatment of lumbar spinal stenosis syndrome, especially for unilateral stenosed nerve root canals, and in decompressing the lateral recess and relieving the nerve root symptoms. Eccentric trepan foraminoplasty technology can improve foraminoplasty efficiency without reducing the lumbar stability. However, treatment is still a challenge for patients with bilateral spinal stenosis syndrome.

Acknowledgments

This study was supported by grants from the National Health and Family Planning Commission of Changzhou (QN201704) PR China and the Scientific Research Project of the Health Commission of Jiangsu (Z2019014) PR China. The abstract of the manuscript was presented at The 20th Osteoscience conference of the Chinese Medical Association and the 13th COA Academic Conference.

References

1. Feeney R. Lumbar spinal stenosis. *J Pain Palliat Care Pharmacother*, 2016, 30: 150–152.
2. Deyo RA, Mirza SK, Martin BI, Kreuter W, Goodman DC, Jarvik JG. Trends, major medical complications, and charges associated with surgery for lumbar spinal stenosis in older adults. *JAMA*, 2010, 303: 1259–1265.
3. Weinstein JN, Tosteson TD, Lurie JD, *et al.* Surgical versus nonsurgical therapy for lumbar spinal stenosis. *N Engl J Med*, 2008, 358: 794–810.
4. Smorgick Y, Park DK, Baker KC, *et al.* Single- versus multilevel fusion for single-level degenerative spondylolisthesis and multilevel lumbar stenosis: four-year results of the spine patient outcomes research trial. *Spine*, 2013, 38: 797–805.
5. Tzaan WC. Transforaminal percutaneous endoscopic lumbar discectomy. *Chang Gung Med J*, 2007, 30: 226–234.
6. Lee DY, Lee SH. Learning curve for percutaneous endoscopic lumbar discectomy. *Neurol Med Chir*, 2008, 48: 383–388.
7. Jasper GP, Francisco GM, Telfeian AE. Transforaminal endoscopic discectomy with foraminoplasty for the treatment of spondylolisthesis. *Pain Physician*, 2014, 17: E703–E708.
8. Jasper GP, Francisco GM, Aghion D, Telfeian AE. Technical considerations in transforaminal endoscopic discectomy with foraminoplasty for the treatment of spondylolisthesis: case report. *Clin Neurol Neurosurg*, 2014, 119: 84–87.
9. Kitahama Y, Sairyo K, Dezawa A. Percutaneous endoscopic transforaminal approach to decompress the lateral recess in an elderly patient with spinal canal stenosis, herniated nucleus pulposus and pulmonary comorbidities. *Asian J Endosc Surg*, 2013, 6: 130–133.
10. Choi G, Lee SH, Lokhande P, *et al.* Percutaneous endoscopic approach for highly migrated intracanal disc herniations by foraminoplasty technique using rigid working channel endoscope. *Spine (Phila Pa 1976)*, 2008, 33: E508–E515.

- 11.** Lewandrowski KU. "Outside-in" technique, clinical results, and indications with transforaminal lumbar endoscopic surgery: a retrospective study on 220 patients on applied radiographic classification of foraminal spinal stenosis. *Int J Spine Surg*, 2014, 8: 26.
- 12.** Ba Z, Li Z, Liu Z, Li H, Wu D, Zhu J. Eccentric technique for foraminoplasty in percutaneous endoscopic transforaminal procedure: a technical note. *Int J Surg*, 2017, 46: 110–113.
- 13.** Li ZZ, Hou SX, Shang WL, Cao Z, Zhao HL. Percutaneous lumbar foraminoplasty and percutaneous endoscopic lumbar decompression for lateral recess stenosis through transforaminal approach: technique notes and 2 years follow-up. *Clin Neurol Neurosurg*, 2016, 143: 90–94.
- 14.** Osman SG, Nibu K, Panjabi MM, *et al.* Transforaminal and posterior decompressions of the lumbar spine. A comparative study of stability and intervertebral foramen area. *Spine (Phila Pa 1976)*, 1997, 22: 1690–1695.
- 15.** Nellensteijn J, Ostelo R, Bartels R, Peul W, van Royen B, van Tulder M. Transforaminal endoscopic surgery for lumbar stenosis: a systematic review. *Eur Spine J*, 2010, 19: 879–886.
- 16.** Kambin P, Casey K, O'Brien E, Zhou L. Transforaminal arthroscopic decompression of lateral recess stenosis. *J Neurosurg*, 1996, 84: 462–467.